

## Campylobacter Species and Neutrophilic Inflammatory Bowel Disease in Cats

C.L. Maunder, Z.F. Reynolds, L. Peacock, E.J. Hall, M.J. Day, and T.A. Cogan

**Background:** Inflammatory bowel disease (IBD) is a common cause of signs of gastrointestinal disease in cats. A subset of cats with IBD has neutrophilic inflammation of the intestinal mucosa.

**Hypothesis:** Neutrophilic enteritis in cats is associated with mucosal invasion by microorganisms, and specifically *Campylobacter* spp.

**Animals:** Seven cats with neutrophilic IBD and 8 cats with lymphoplasmacytic IBD.

**Methods:** Retrospective review of duodenal biopsy specimens that were collected endoscopically for histologic examination. Cases were identified and selected by searching the histopathology archive for cats with a diagnosis of neutrophilic and lymphoplasmacytic IBD. Fluorescence *in situ* hybridization (FISH) targeting either all eubacteria or individual *Campylobacter* spp. was performed on archived samples. Neutrophils were detected on the same samples using a FISH probe for neutrophil elastase.

**Results:** *Campylobacter coli* was present in (6/7) cats with neutrophilic IBD and in (1/8) cats with lymphoplasmacytic IBD ( $P = .009$ ). Cats with neutrophilic IBD had significantly higher number of *C. coli* (median bacteria 0.7/hpf) in the mucosa than cats with lymphoplasmacytic IBD (median bacteria 0/hpf) ( $P = 0.002$ ). Colocalization of neutrophils and *C. coli* was demonstrated, with *C. coli* closer to the neutrophils than any other bacteria ( $P < .001$ ).

**Conclusions and clinical importance:** Identification of *C. coli* associated with neutrophilic inflammation suggests that *C. coli* is able either to produce compounds which stimulate neutrophils or to induce feline intestinal cells to produce neutrophil chemoattractants. This association should allow a directed therapeutic approach in cats with neutrophilic IBD, potentially improving outcome and reducing any zoonotic risk.

**Key words:** Duodenum; Endoscopy; Enteritis; FISH; Histopathology.

Inflammatory bowel disease (IBD) is a common cause of chronic signs in cats with gastrointestinal disease.<sup>1</sup> Intestinal biopsies are needed to confirm intestinal inflammation, but cases are deemed idiopathic if no underlying cause is found.<sup>1–3</sup> Typically, lymphoplasmacytic inflammation is found in biopsy specimens, but a subset of cats with IBD has neutrophilic inflammation of the intestinal mucosa. The clinical relevance of neutrophilic infiltration is unclear. It might be secondary to bacterial infection, but neutrophilic colitis is seen with *Tritrichomonas foetus* infection<sup>4</sup> and a case of suppurative colitis in a cat was described<sup>5</sup>, where no bacterial infection could be identified. Mucosal friability and erosions might also induce neutrophilic infiltrates because of the loss of mucosal barrier integrity. If no etiological agent is identified, directed or appropriate treatment is

### Abbreviations:

12-LOX	12-lipoxygenase
AIEC	attaching and invasive <i>E. coli</i>
DNA	deoxyribonucleic acid
FCEAI	feline chronic enteropathy activity index
FISH	fluorescence in situ hybridization
H & E	hematoxylin and eosin
HPF	high-powered field
IBD	inflammatory bowel disease
IL-8	interleukin 8
NF-κB	nuclear factor kappa beta
PCR	polymerase chain reaction
rRNA	16S ribosomal ribonucleic acid
WSAVA	World Small Animal Veterinary Association

unclear and empirical antibacterial treatment might be prescribed.

Using more traditional diagnostic techniques, the evidence for infectious agents causing neutrophilic intestinal inflammation is poor. The clinical relevance of identifying bacteria in fecal samples is unclear as they might be found in the feces of healthy cats as well as in those with diarrhea.<sup>6–9</sup>

The use of fluorescent *in situ* hybridization (FISH) has enabled detection and visualization of intact bacteria within tissues and their localization as part of understanding the ecology of a disease process.<sup>10</sup> In small animal gastrointestinal research, FISH has been used to demonstrate gastric *Helicobacter* spp. infections and clearance of these bacteria with treatment,<sup>11</sup> and that attaching and invasive *E. coli* (AIEC) are associated with granulomatous colitis in Boxers and can be eradicated with prolonged antibiotics.<sup>12,13</sup> Janeczko<sup>14</sup> used FISH and showed higher number of mucosa-associated

From the School of Veterinary Sciences, University of Bristol, Langford, UK (Maunder, Reynolds, Peacock, Hall, Day, Cogan).

The work in this study was performed at the School of Veterinary Sciences, University of Bristol and supported by a grant from the Langford Trust. The abstract from this paper was presented at the European College of Veterinary Internal Medicine Congress in Lisbon, Portugal 2015.

Corresponding author: C. Maunder, Small Animal Hospital, School of Veterinary Sciences, University of Bristol, Langford House, Langford, Bristol, BS40 5DU, UK; e-mail: C.Maunder@bristol.ac.uk

Submitted October 21, 2015; Revised February 19, 2016; Accepted June 11, 2016.

Copyright © 2016 The Authors. Journal of Veterinary Internal Medicine published by Wiley Periodicals, Inc. on behalf of the American College of Veterinary Internal Medicine.

This is an open access article under the terms of the Creative Commons Attribution-NonCommercial License, which permits use, distribution and reproduction in any medium, provided the original work is properly cited and is not used for commercial purposes.

DOI: 10.1111/jvim.14374

Enterobacteriaceae in cats with gastrointestinal signs compared with healthy cats, although it was not clear whether this association was the cause of the inflammation or a consequence of the mucosal disruption and altered environment selecting for bacterial dysbiosis.

The aims of this study were: (1) to determine the presence, and identity of intact bacteria within feline intestinal biopsy specimens using FISH and (2) to determine the location of neutrophils and their proximity to any bacteria to demonstrate an association and possible bacterial etiology.

## Materials & Methods

### Study Population

Cases from which there was histopathologic assessment of endoscopic intestinal biopsy specimens at the University of Bristol, School of Veterinary Sciences, were identified from the pathology archive and the biopsy specimens were reviewed. The inclusion criteria were that duodenal biopsy specimens had a diagnosis of neutrophilic or lymphoplasmacytic inflammation and were of adequate quality and size for FISH to be performed requiring at least 3 well-oriented villi with subvillus lamina propria extending to the muscularis mucosa in each section.

Samples from 15 cats (7 with neutrophilic IBD and 8 with lymphoplasmacytic IBD) met the inclusion criteria for the study and also had sufficient intestinal tissue archived as formalin-fixed and paraffin wax-embedded material. The signalment of these cats was documented, but the clinical severity and response to treatment was not uniformly reported. Ethical approval for the study was granted by the University of Bristol Ethics Committee. Samples from all cats were retrospectively analyzed for intestinal bacterial pathogens by PCR as detailed below.

### Histopathologic Analysis

In every case, hematoxylin and eosin-stained sections of the duodenal biopsy specimens were reviewed, without knowledge of the case history, by a Board-certified veterinary pathologist (MJD). The histopathologic changes were graded according to the scoring system developed by the World Small Animal Veterinary Association (WSAVA) Gastrointestinal Standardization Group.<sup>15</sup> Five parameters of inflammation (ie, intraepithelial lymphocytes, lamina propria lymphocytes, plasma cells, eosinophils and neutrophils, and other inflammatory cell types within the lamina propria) were evaluated. Morphologic features of mucosal inflammation (villus stunting, epithelial injury, crypt dilatation/distortion, lacteal dilatation, and mucosal fibrosis) were also evaluated. Changes in morphological features were noted, but there was

no appreciable difference between groups, with a range of none-moderate within each group. The final diagnosis was categorized as 1 of 8 different histopathologic diagnoses: no abnormalities detected (NAD), lymphoplasmacytic inflammatory, eosinophilic inflammatory, neutrophilic inflammatory, lymphangiectasia, lymphoma, mucosal atrophy/fibrosis (noninflammatory) and other. Only samples from cats with lymphoplasmacytic inflammatory histopathologic changes and neutrophilic inflammatory histopathologic changes were included in the study.

### Fluorescence In Situ Hybridization—Bacteria

Fluorescence in situ hybridization (FISH) was performed on formalin-fixed and paraffin wax-embedded duodenal biopsy specimens using a method slightly modified from that previously reported in the literature, in that hybridization buffer containing 25% formamide was used as opposed to buffer containing 30% formamide in the previous study.<sup>16</sup>

16S ribosomal RNA (rRNA)-directed fluorescence-labeled oligonucleotide probes were used (Table 1). Successive sections from each biopsy specimen were analyzed in steps, each employing a different probe mix. Steps one and two were general probes for Eubacteria and Firmicutes using three different probes for each bacterial group. A mixture of probes with slight base variations were used to maximize the spectrum of coverage of each probe mix. The third step used specific probes for *Campylobacter* species. These were used in combination with one probe labeling *C. upsaliensis*, another probe for *C. jejuni*, and a final probe labeling all thermophilic *Campylobacter* spp. Bacteria labeled solely by this last probe could either be *C. lari* or *C. coli* and were speciated by subsequent polymerase chain reaction (PCR). We did not examine the sections for *E. coli* and would not, using these methods, have been able to detect AIEC.

Processed slides were mounted with glass cover slips with hard-set Vectashield mounting medium containing DAPI. Once set, slides were examined with a Leica DMR-A Microscope equipped with a monochrome Hamamatsu 8-bit digital camera. Bacterial cells in the epithelium and lamina propria were counted at  $\times 400$  magnification by a single blinded observer across 10 fields of view, and an average count was obtained. Fields of view were chosen as being central to a biopsy and including epithelium and so that not more than 2 were viewed for a single biopsy.

### Polymerase Chain Reaction (PCR)

DNA was extracted from pooled multiple sections of tissue using a DNeasy™ blood and tissue kit (Qiagen, Manchester, UK). This was screened by Langford Veterinary Services (Bristol, UK) for the presence of *Salmonella*, pathogenic *E. coli*, *Campylobacter* spp., and *Clostridium* spp. A 153-bp DNA fragment unique to *Campylobacter* was amplified by PCR<sup>17</sup> and sequenced to confirm the *Campylobacter* species present.

**Table 1.** FISH oligonucleotide probes. Details of sequences of oligonucleotide probes used for in situ localization of bacterial species within duodenal biopsy tissues.

Probe name	Bacterial target	Sequence (5'→3')	5'-Modification	
EUB338	Eubacteria	GCTGCCTCCCCTAGGAGT	FITC	Step 1
EUB338-II	Eubacteria	GCAGCCACCCGTAGGTGT	FITC	Step 1
EUB338-III	Eubacteria	GCTGCCACCCGTAGGTGT	FITC	Step 1
LGC354A	Firmicutes	TGGAAGATTCCTACTGC	Texas Red	Step 2
LGC354B	Firmicutes	CGGAAGATTCCTACTGC	Texas Red	Step 2
LGC354C	Firmicutes	CCGAAGATTCCTACTGC	Texas Red	Step 2
Catherm	Thermophilic <i>Campylobacter</i>	GCCCTAAGCGTCCTTCCA	Texas Red	Step 3
Cajej	<i>Campylobacter jejuni</i>	AGCTAACACACCTTATACCG	FITC	Step 3
CaUp	<i>Campylobacter upsaliensis</i>	CTCTACAGAATTTGTTGGAT	AF350	Step 3

### Fluorescent In Situ Hybridization—Colocalization of Bacteria and Neutrophils

*Campylobacter jejuni* and thermophilic *Campylobacter* spp. probes were used in combination with a FISH probe designed to detect feline neutrophil elastase mRNA. The feline neutrophil elastase probe 5'CAGAGGCTGCTGAACGACATCGTGATTCTC CAGCTCAAT3' was used concurrently with *Campylobacter* spp. probes (Thermophilic *Campylobacter* spp. 5'GCCCTAAGCGTCC TTCCA 3' and *C. jejuni* 5'AGCTAACCACACCTTATACCG 3').

Slides were viewed under fluorescence using a DMRB microscope (Leica) equipped with a Retiga EXi camera (QImaging) and Volocity imaging software (PerkinElmer) and searched for the expression of feline neutrophil elastase and *Campylobacter*. Images were taken when a field of view ( $\times 400$  objective) contained a neutrophil elastase expressor and one or both of the *Campylobacter* expressors. A record was made of any neutrophil elastase expressors that did not have a *Campylobacter* expressor in the same field, as well as the overall presence of *C. jejuni* and thermophilic *Campylobacter*. Image J software (<http://rsb.info.nih.gov/ij>) was used after images had been captured to allow automated measurement of the distance between two points selected by the user—neutrophil and *Campylobacter*. The distance was measured in pixels on the digital images. The maximum field size used was 1850 pixels. The use of this software allowed multiple accurate measurements to be taken and compiled for statistical analysis.

### Statistics

Analysis was performed using statistical software; GraphPad Prism version 5.03. The presence of bacteria in the cats with neutrophilic and lymphoplasmacytic IBD was compared and tested for statistical significance using Chi-squared testing.

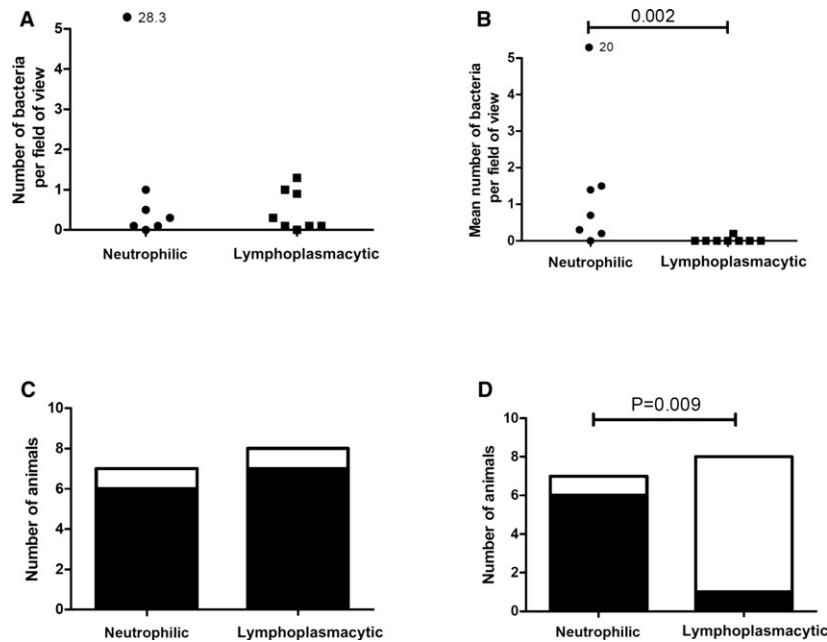
Differences between the group with neutrophilic inflammation and the group with lymphoplasmacytic inflammation in the number of bacteria of different species found in tissue were analyzed using a Mann-Whitney *U*-test. Similarly, differences in the pixel distance between *C. jejuni* and neutrophils or *C. coli* and neutrophils were analyzed using the same test.

### Results

Fifteen cats met the inclusion criteria: 8 were domestic short hair (DSH), 1 was domestic long hair (DLH), and 5 were pure breeds (Maine Coon, Birman, Oriental, and 2 Siamese). There was no breed recorded for one of the biopsy specimens. The age range was 2–15 years (median 9 years). There were 11 male cats and 4 female cats. Bacterial DNA extraction results for all the cats showed that none were positive for *Salmonella* or pathogenic genotypes of *E. coli* (a definition which excludes AIEC). One animal in each group was positive for *Clostridium* spp. All were *Campylobacter* positive. Sequencing for *Campylobacter* to separate the thermophilic species showed that *C. lari* and *C. upsaliensis* could not be detected in tissues (data not shown). Only the species *C. coli* and *C. jejuni* were present in tissues. The PCR speciation results concurred with FISH results (Fig 1).

### Presence of Bacteria in the Cats with Neutrophilic IBD and the Cats with Lymphoplasmacytic IBD

Bacteria were identified within the mucosa of cats with either neutrophilic or lymphoplasmacytic



**Fig 1.** A Shows the number of *C. jejuni* within the mucosa of the cats with neutrophilic inflammatory bowel disease (IBD) and the cats with lymphoplasmacytic IBD. B Shows the number of *C. coli* within the mucosa of the cats with neutrophilic IBD and the cats with lymphoplasmacytic IBD. C Frequency of finding *C. jejuni* within the mucosa of the cats with neutrophilic IBD and the cats with lymphoplasmacytic IBD. D Frequency of finding *C. coli* within the mucosa of the cats with neutrophilic IBD and the cats with lymphoplasmacytic IBD

inflammation. There was no significant difference in the number of Eubacteria seen in specimens from either of the two groups. There were few *C. upsaliensis* and further statistical analysis was not possible. *C. jejuni* and *C. coli* were present in greater number and so the distribution of these organisms between the neutrophilic group and lymphoplasmacytic group of cats was compared. There was no significant difference between the presence of *C. jejuni* within the mucosa of the cats with neutrophilic or lymphoplasmacytic inflammation. However, *C. coli* was more prevalent in the mucosa of cats with neutrophilic inflammation (6/7) compared with cats with lymphoplasmacytic inflammation (1/8) and this distribution was significant ( $P = .009$ ) (Fig 1).

#### Number of Bacteria in the Cats with Neutrophilic IBD and the Cats with Lymphoplasmacytic IBD

The number of *C. jejuni* and *C. coli* within the mucosa of the cats with neutrophilic inflammation and cats with lymphoplasmacytic inflammation were then compared. For *C. jejuni* the numbers were similar in both groups and there was no significant difference in distribution. However, for *C. coli* the numbers were greater within the cats with neutrophilic inflammation (median number of bacteria per high-powered field of view [ $\times 400$  magnification] was 0.7) compared to the cats with lymphoplasmacytic inflammation (median number of bacteria per high-powered field of view was 0) and this difference was significant ( $P = 0.002$ ). (Fig 1).

#### Coccolocalization of Bacteria with Neutrophils

There was an insufficient number of neutrophils within the mucosa of cats with lymphoplasmacytic inflammation to investigate the association with microorganisms, as 62 of the 63 fields of view examined did not show *Campylobacter* and a neutrophil in the same field of view. Within the mucosa of cats with neutrophilic inflammation, only 6 of the 63 fields of view examined did not show *Campylobacter* and a neutrophil in the same field of view. Cells expressing neutrophil elastase had typical PMN morphology on light microscopy.

Within the mucosa of cats with neutrophilic inflammation the colocalization of *C. jejuni* and *C. coli* was analyzed; *C. upsaliensis* numbers were again too few for statistical analysis. For *C. jejuni* there was no evidence of an association between location of the bacteria and that of the neutrophils and often no organism was seen within the same field of view as a neutrophil ( $>1850$  pixels). For *C. coli*, there was an association between the location of the organism and that of the neutrophils ( $P < .001$ ) (Fig 2).

### Discussion

Inflammatory bowel disease is one cause of chronic signs of gastrointestinal disease in cats, others include adverse food reactions, antibiotic responsive enteropathy, and infection (virus, fungi, bacterial, protozoal, or

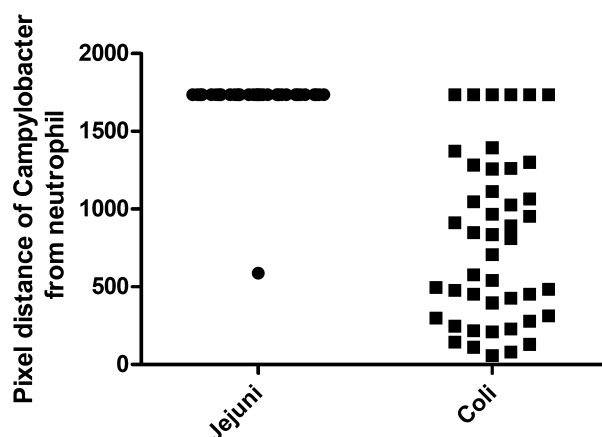
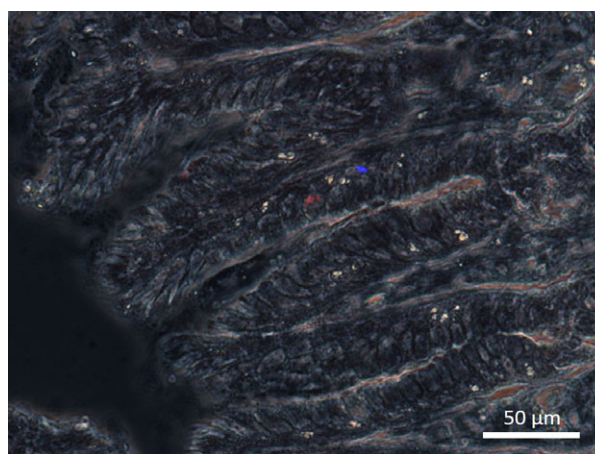


Fig 2. Proximity of *Campylobacter coli* is closer to neutrophils as compared to *C. jejuni*. Data show pixel distance of neutrophils to *Campylobacter* as measured by ImageJ software. The maximal pixel distance per field is 1850 pixels; when a field of view did not contain both a *Campylobacter* and a neutrophil distance was recorded as 1850 pixels.

parasitic). Cases with histopathologic changes consistent with neutrophilic inflammation may result from mucosal invasion by microorganisms, develop secondary to mucosal defects, or *Tritrichomonas foetus* infection or be idiopathic. The aims of this study were to use FISH to elucidate the presence of mucosal bacterial invasion in feline IBD, and to identify any association between *Campylobacter* invasion and neutrophilic inflammation (Picture 1).

Bacteria were identified within the mucosa of cats with both neutrophilic and lymphoplasmacytic inflammation, suggesting mucosal disruption. There was no clear pattern to their localization (mucosa/submucosa/lamina propria) within the tissue. The total numbers of bacteria did not differ between groups and for two



Picture 1. Fluorescence *in situ* hybridization (FISH) demonstrating red fluorescence for a thermophilic *Campylobacter* species (*C. coli*) and blue fluorescence for neutrophil elastase. Not all bacteria are highlighted in a single sectional view as organisms outside the plane of focus are not visible in a single image.

bacterial species (*C. jejuni* and *C. upsaliensis*) there was also no difference in distribution between the two groups. A significant difference was found between the two groups regarding the presence of *C. coli*. This in itself is simply an observation and merely demonstrates an increased presence of *C. coli* in cats with neutrophilic inflammation. However, FISH neutrophil elastase probes demonstrated close proximity to neutrophils and confirmed the possible association with *C. coli*. No association between neutrophil location and other species of bacteria was demonstrated. This association supports the hypothesis that *C. coli* is particularly associated with a specific neutrophilic form of inflammation in the duodenal mucosa of cats with enteric disease compared with other microorganisms.

*Campylobacter* species are known to be powerful chemoattractants for neutrophils. Previous in vitro studies with porcine and human epithelial cells have shown that *C. jejuni* and *C. coli* induce neutrophilic intestinal inflammation via activation of NF- $\kappa$ B and subsequent production of the neutrophil chemokine IL-8 and also induce migration of neutrophils across the epithelium via the production of chemotactic n-formyl peptides in concert with metabolites of 12-LOX.<sup>18,19</sup> In the present retrospective study there was evidence that *C. coli*, but not *C. jejuni*, appears to colocalize with neutrophils and therefore might be acting as the etiological agent in this particular subset of feline inflammatory bowel disease, although other cell types and mechanisms could be involved. In vitro studies using feline neutrophils similarly to previous work on porcine neutrophils<sup>18,19</sup> would be necessary to determine a mechanism for chemoattraction.

Limitations of the study mostly relate to its retrospective nature and the lack of clinical data. Once the inclusion criteria were met, the numbers recruited to each group were small because samples had to be of sufficient quality for histopathological review and of adequate volume for the subsequent molecular diagnostic tests to be performed.

We were unable to document any differences in clinical presentation between the two groups or to assess data relating to treatment and outcome as the cases were not always treated in our hospital; these were drawn from a pathology archive so the remit of this study is specifically to associate bacteria with pathology. The lack of clinical data means we are unable to determine if any of the cats received antibiotic treatment before endoscopic biopsy collection. This is a potential confounding effect but prior antibiotic treatment would be expected to reduce bacterial numbers and the likelihood of finding a significant difference between the groups, except in the unlikely event that all the cats with lymphoplasmacytic IBD were treated with antibiotics and none of the cats with neutrophilic IBD were. Fecal analysis from each cat might also have been useful to determine whether *Campylobacter* spp. had been identified on culture. A prospective study based on the findings of this work would be necessary to evaluate clinical and treatment factors.

The histopathologic classification and subsequent analysis was performed on duodenal biopsy specimens and these may not reflect the nature of the inflammatory changes elsewhere in the gastrointestinal tract. A previous study<sup>20</sup> showed that in dogs with enteropathy that there was poor agreement between histopathologic findings in ileal and duodenal biopsy specimens. Another study<sup>21</sup> also showed poor agreement on diagnosis between duodenal and ileal biopsy specimens in cats; although this distinction, between lymphoplasmacytic inflammation and small cell lymphoma, is more problematic than simply identifying neutrophilic inflammation. Although it is possible that inflammatory changes elsewhere in the gastrointestinal tract were different to the duodenum, our hypothesis related to an infectious etiology for the localized neutrophilic inflammation and so our findings remain valid.

The preliminary findings from this retrospective study highlight a need for prospective investigation to understand the relevance of the *C. coli* tissue localization. This would allow investigation into whether this subset of cats have a different clinical presentation and FCEAI score or different endoscopic lesions identified on endoscopy. Identification of *C. coli* as a potential etiological agent for this subset of cats would allow directed treatment and would potentially improve the outcome and also reduce any zoonotic risk.<sup>8,22</sup> Further in vitro molecular studies would also help determine by what means *C. coli* induces the neutrophilic response: whether it produces compounds which stimulate neutrophils or induces feline intestinal cells to produce neutrophil chemoattractants. A prospective study would also allow an epidemiological study of risk factors and the interaction of these cats with their owners.

## Acknowledgments

*Conflict of Interest declaration:* Authors declare no conflict of interest.

*Off-label Antimicrobial Declaration:* Authors declare no off-label use of antimicrobials.

## References

1. Hall EJ, German AJ. Diseases of the small intestine. In: Ettinger SJ, Feldman EC, eds. Textbook of Veterinary Internal Medicine, 7th ed. St. Louis, MO: Elsevier Saunders; 2010:1526–1572.
2. Washabau RJ, Day MJ, Willard MD, et al. Endoscopic, biopsy, and histopathological guidelines for the evaluation of gastrointestinal inflammation in companion animals. *J Vet Intern Med* 2010;24:10–26.
3. Willard MD. Feline inflammatory bowel disease: A review. *J Feline Med Surg* 1999;1:155–164.
4. Yaegar MJ, Gookin JL. Histologic features associated with *Tritrichomonas foetus*-induced colitis in domestic cats. *Vet Pathol* 2005;42:797–804.
5. Leib MS, Sponenberg DP, Wilcke JR, et al. Suppurative colitis in a cat. *J Am Vet Med Assoc* 1986;188:739–741.
6. Acke E, Whyte P, Jones BR, et al. Prevalence of thermophilic *Campylobacter* species in cats and dogs in two animal shelters in Ireland. *Vet Rec* 2006;158:51–54.

7. Hill SL, Cheney JM, Taton-Allen GF, et al. Prevalence of enteric zoonotic organisms in cats. *J Am Vet Med Assoc* 2000;216:687–692.
8. Marks SL, Rankin SC, Byrne BA, et al. Enteropathogenic bacteria in dogs and cats: Diagnosis, epidemiology, treatment and control. ACVIM Consensus statement. *J Vet Intern Med* 2011;25:1195–1208.
9. Rossi M, Hänninen ML, Revez J, et al. Occurrence and species level diagnostics of *Campylobacter* spp., enteric *Helicobacter* spp. and *Anaerobiospirillum* spp. in healthy and diarrheic dogs and cats. *Vet Microbiol* 2008;129:304–314.
10. Simpson KW. Bacteria and inflammatory bowel disease: causes and consequences. Proceedings of the 33rd World Small Animal Veterinary Association Congress Dublin, Ireland 2008. Available at: <http://www.vin.com/members/cms/project/defaultadv1.aspx?pld=11268&meta=VIN&catId=32729&id=3866515>. Accessed April 15, 2015.
11. Jergens A, Pressel M, Crandell J, et al. Fluorescence in situ hybridization confirms clearance of visible *Helicobacter* spp. associated with gastritis in dogs and cats. *J Vet Intern Med* 2009;23:16–23.
12. Simpson KW, Dogan B, Rishniw M, et al. Adherent and invasive *Escherichia coli* is associated with granulomatous colitis in boxer dogs. *Infect Immun* 2006;74:4778–4792.
13. Mansfield CS, James FE, Craven M, et al. Remission of histiocytic ulcerative colitis in Boxer dogs correlates with eradication of invasive intramucosal *Escherichia coli*. *J Vet Intern Med* 2009;23:964–969.
14. Janeczko S, Atwater D, Bogel E, et al. The relationship of mucosal bacteria to duodenal histopathology, cytokine mRNA and clinical disease activity in cats with inflammatory bowel disease. *Vet Microbiol* 2008;128:178–193.
15. Day MJ, Bilzer T, Mansell J, et al. Histopathological standards for the diagnosis of gastrointestinal inflammation in endoscopic biopsy samples from the dog and cat: A report from the World Small Animal Veterinary Association gastrointestinal standardization group. *J Comp Pathol* 2008;138(Supplement 1):S1–S43.
16. Jennings JL, Sait LC, Perrett CA, et al. *Campylobacter jejuni* is associated with, but not sufficient to cause vibronic hepatitis in chickens. *Vet Microbiol* 2011;149:193–199.
17. Van Doorn LJ, Verschuuren-van Haperen A, Burnens A, et al. Rapid identification of thermotolerant *Campylobacter jejuni*, *Campylobacter coli*, *Campylobacter lari*, and *Campylobacter upsaliensis* from various geographic locations by a GTPase-based PCR-reverse hybridization assay. *J Clin Microbiol* 1999;37:1790–1796.
18. Murphy H, Cogan T, Hughes R, et al. Porcine intestinal epithelial responses to *Campylobacter* infection. *Comp Immunol Microbiol Infect Dis* 2011;34:489–495.
19. Murphy H, Cogan T, Humphrey. Direction of neutrophil movements by *Campylobacter*-infected intestinal epithelium. *Microbes Infect* 2011;13:42–48.
20. Casamian-Sorrosal D, Willard MD, Murray JK, et al. Comparison of the histopathologic findings in biopsies from the duodenum and ileum of dogs with enteropathy. *J Vet Intern Med* 2010;2010:80–83.
21. Scott KD, Zoran DL, Mansell J, et al. Utility of endoscopic biopsies of the duodenum and ileum for diagnosis of inflammatory bowel disease and small cell lymphoma in cats. *J Vet Intern Med* 2011;25:1253–1257.
22. Fox JG. Enteric bacterial infections: *Campylobacter*. In: Greene CE, ed. *Infectious Diseases of the Dog and Cat*, 3rd ed. St.Louis, MO: Elsevier Saunders; 2006:339–343.