

# Flow Alteration Therapy for Ruptured Vertebral Artery Dissecting Aneurysms Involving the Posterior Inferior Cerebellar Artery

Yasuhisa KANEMATSU,<sup>1</sup> Junichiro SATOMI,<sup>1</sup> Masaaki KORAI,<sup>1</sup>  
Toshiyuki OKAZAKI,<sup>1</sup> Izumi YAMAGUCHI,<sup>1</sup> Yoshiteru TADA,<sup>1</sup> Masaaki UNO,<sup>2</sup>  
Shinji NAGAIHIRO,<sup>1</sup> and Yasushi TAKAGI<sup>1</sup>

<sup>1</sup>Department of Neurosurgery, Tokushima University, Tokushima, Tokushima, Japan;

<sup>2</sup>Department of Neurosurgery, Kawasaki Medical School, Kurashiki, Okayama, Japan

## Abstract

Surgery for- and endovascular treatment of vertebral artery (VA) dissecting aneurysms involving the origin of the posterior inferior cerebellar artery (PICA) remain challenging. Their ideal treatment is complete isolation of the aneurysm by surgical or endovascular trapping plus PICA reconstruction. However, post-operative lower cranial nerve palsy and medullary infarction are potential complications. We report four patients with VA dissecting aneurysms involving the PICA origin who were treated by occipital artery (OA)-PICA bypass followed by proximal occlusion of the VA and clip ligation of the PICA origin instead of trapping. There were no procedural or ischemic complications. In all patients, angiography performed 2–3 weeks later showed good patency of the bypass graft and complete obliteration of the aneurysm. During the follow-up period ranging from 1 to 14 years, none experienced bleeding. Although retrograde blood flow to the dissecting aneurysm persisted in the absence of trapping, iatrogenic lower cranial nerve injury could be avoided. The decrease in aneurysmal flow might elicit spontaneous thrombosis and prevent aneurysmal rerupture. Our technique might be less invasive than aneurysmal trapping and help to prevent rebleeding.

Key words: flow alteration, vertebral artery dissecting aneurysm, posterior inferior cerebellar artery

## Introduction

The bleeding- and mortality rates are high in patients with ruptured vertebral artery (VA) dissecting aneurysms;<sup>1,2</sup> their surgical or endovascular treatment has been reported.<sup>3,4</sup> Obliteration of the whole dissecting segment by surgical trapping or internal endovascular trapping prevents rebleeding. As it is minimally invasive and can be performed promptly, in patients with angiographically confirmed VA dissecting aneurysms, internal endovascular trapping is the first-line treatment.<sup>5–8</sup> However, because surgical- and internal endovascular trapping obstruct the blood flow to the posterior inferior cerebellar artery (PICA), these procedures are not appropriate in patients with dissecting VA aneurysms involving the origin of the PICA. Rather, trapping of the dissecting segment and revascularization of the PICA have been suggested to

address such aneurysms<sup>9,10</sup> although some patients developed lower cranial nerve palsy and medullary or cerebellar infarction postoperatively.<sup>3,10–12</sup> Stenting or stent-assisted coiling has been reported,<sup>5,6,13–20</sup> and although these procedures preserve the blood flow in the VA or PICA, they raise the risk for hemorrhagic complications due to incomplete obliteration and the need for antiplatelet therapy. Consequently, obliteration of the dissecting segment combined with reconstructive procedures such as trapping of the dissecting aneurysm with the PICA revascularization has remained the treatment of choice.

We report our experience with four patients harboring VA dissecting aneurysms involving the PICA origin. They were treated with an occipital artery (OA)-PICA bypass followed by proximal occlusion of the VA and clip ligation of the PICA origin instead of trapping. We encountered neither surgical complications or rebleeding, suggesting that our treatment is safe and effective for the prevention of rebleeding because it involves less surgical manipulation of the lower cranial nerves than trapping and avoids obstruction of the perforating artery to the brainstem.

Received March 16, 2018; Accepted May 17, 2018

Copyright© 2018 by The Japan Neurosurgical Society  
This work is licensed under a Creative Commons Attribution-NonCommercial-NoDerivatives International License.

## Materials and Methods

This study was approved by the Ethics Committee of our institution. Prior patient or proxy informed consent for treatment was obtained.

**Patients.** This is a retrospective study of four patients with ruptured VA dissecting aneurysms involving the PICA origin who were treated in our institute between 2003 and 2015. All were males ranging in age from 43 to 60 years (mean 52 years) and all underwent proximal occlusion of the VA and clip ligation of the origin of the PICA combined with OA-PICA bypass. Their Hunt and Hess (H&H) grade at the time of admission, and the follow-up period are shown in Table 1. The aneurysmal morphology was assessed preoperatively on conventional angiography images and the surgical outcomes were recorded. The outcome was evaluated on conventional angiographs obtained 2–3 weeks after treatment. The appearance of new ischemic lesions, the patency of the bypass grafts, and aneurysmal obliteration were assessed on magnetic resonance images (MRI) acquired within 7 days after treatment. The clinical outcome was determined based on the patients' modified Rankin Scale (mRS) 3 months after treatment. All patients underwent outpatient monitoring using magnetic resonance angiography (MRA).

**Treatment.** Inclusion criteria for our treatment was: (1) Preoperative MRA and conventional angiography revealed the pearl-and-string sign or aneurysmal dilation on the VA involving the PICA origin. (2) Intraoperative findings of the VA involving the PICA origin showed a dissecting aneurysmal change such as dark purplish or sausage-like swelling. (3) Intraoperative findings of the distal site of the dissected VA segment were large or extended to the contralateral side, it is considered hard to observe the distal terminus of the dissecting aneurysm. One patient (case 1) underwent preoperative proximal occlusion of the VA by endovascular coiling. With the patients in the park bench position, a hockey stick-shaped skin incision was made. The OA was separated from the subcutaneous layer to obtain the OA graft. After subperiosteal muscle dissection, suboccipital craniectomy, and C1 laminectomy were performed. After incision of the dura, the arachnoid membrane was opened and the cerebellum was retracted to expose the PICA. The caudal PICA loop was the anastomosis site. OA-PICA anastomosis was performed using 10-0 nylon stitches. The patency of the bypass graft was confirmed by intraoperative micro-Doppler ultrasound or indocyanine green (ICG) video angiography. Then the proximal terminus of the aneurysmal dilation and the origin of the PICA were clipped. Electrophysiologic monitoring included

the interoperative recording of somatosensory evoked potentials. In case of rebleeding occurred, any perioperative antithrombotic treatment was not performed in the perioperative period.

## Results

The H&H grade was I in one patient, III in one patient, and IV in two patients. MRI performed within 7 days after treatment did not detect new ischemic lesions and angiographs obtained 2–3 weeks after the operation revealed good patency of the bypass grafts and complete aneurysmal obliteration in all patients; none manifested postoperative neurological degradation. The mRS 3 months after treatment was 0, 1, 3, and 4 in one patient each. Despite their good surgical outcomes, two patients were disabled due to damage present upon their admission (H&H grade IV). During the follow-up period ranging from 1 to 14 years, no patient experienced rebleeding (Table 1).

**Case 1.** This 43-year-old male presented with subarachnoid hemorrhage (SAH, H&H grade III) in the pontine and medullary cistern, confirmed on the admission brain CT scan. Angiography revealed a PICA dissecting aneurysm in the left VA (Figs. 1a and 1b). On the day after the insult, he underwent proximal occlusion of the left VA with endovascular coiling. Contralateral VA angiography showed good supply to the PICA and slight filling of the residual dissecting aneurysm (Figs. 1c and 1d). Follow-up angiography performed 6 months later revealed enlargement of the residual dissecting aneurysm due to filling from the contralateral VA (Figs. 1e and 1f) and he underwent direct surgery via the left lateral suboccipital approach and C1 laminectomy. The tonsillomedullary segment of the left PICA was the anastomosis site. OA-PICA anastomosis was performed using 10-0 nylon stitches (Fig. 2a) followed by clipping of the origin of the PICA (Fig. 2b). The VA distal to the aneurysms could not be observed. No perforator was found within sight of the VA. As the cessation of flow to the aneurysm was confirmed by micro-Doppler ultrasound, the aneurysm was not trapped. Follow-up angiography performed 14 days later revealed complete thrombosis of the residual dissecting aneurysm and good patency of the bypass graft (Figs. 2c and 2d).

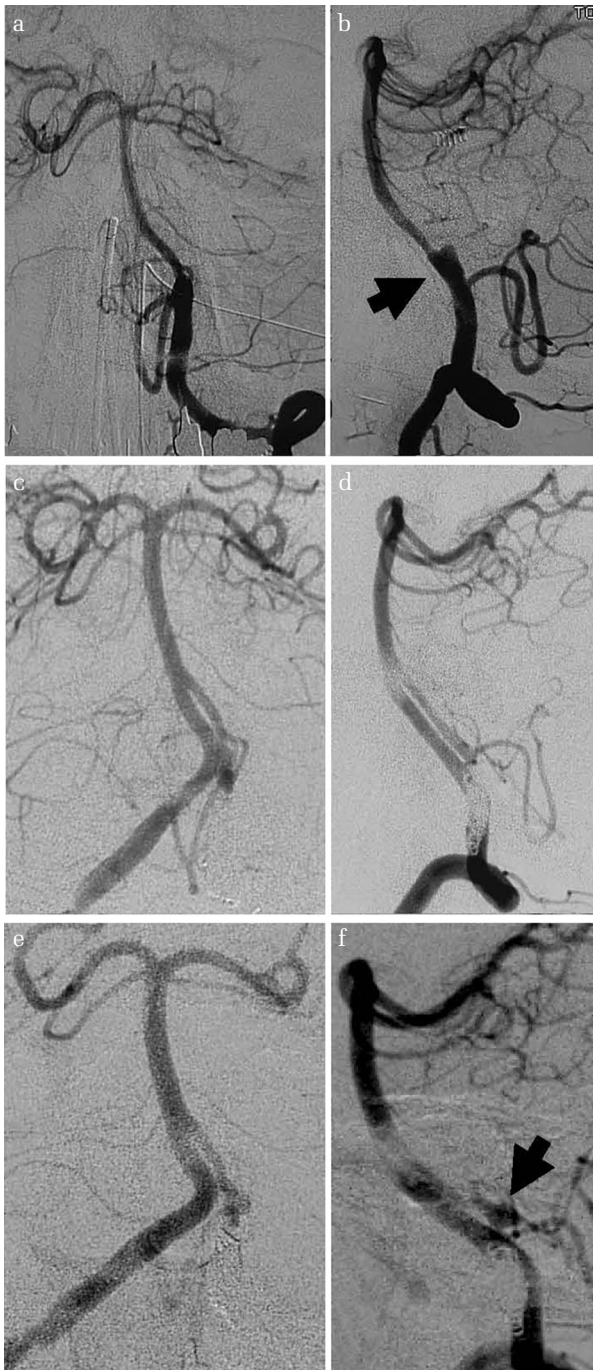**Case 2.** A 52-year-old man reported sudden occipital headache. A brain CT scan acquired at the time of admission revealed SAH in the pontine cistern. The H&H grade was I. MRA and conventional angiography revealed the pearl-and-string sign in the right VA and at the origin of the right PICA (Figs. 3a and 3b). He underwent direct surgery 14

**Table 1** Characteristics of four patients with ruptured VA dissecting aneurysm involving the PICA origin

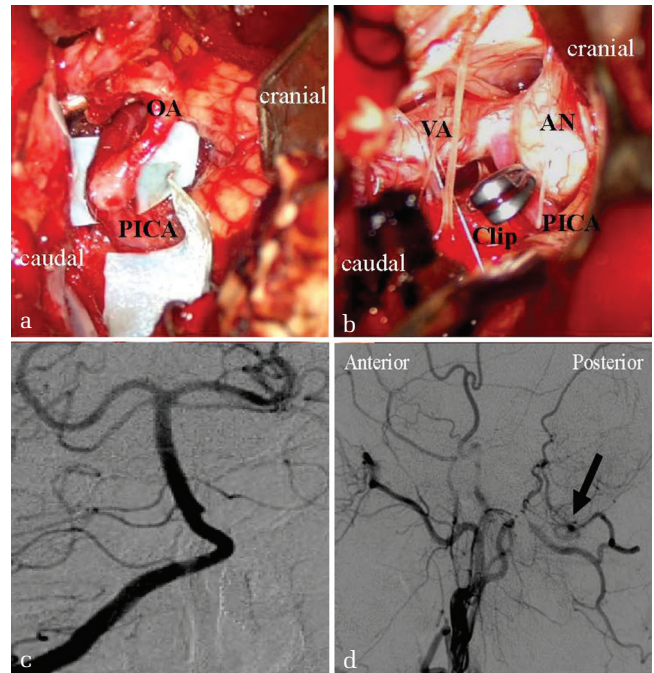
Case	Age	Sex	H&H grade	Side	Previous treatment	Treatment	Treatment day post SAH (Days)	Procedural complication	Post-procedural ischemic lesion	Graft patency	Aneurysm obliteration	mRS 3 months	Rebleeding	Follow-up period (year)
1	43	M	III	Lt.	Lt. VA proximal occlusion with coil	Lt. OA-PICA anastomosis, Lt. PICA origin clip ligation	191	None	None	Good	Complete	1	-	14
2	52	M	I	Rt.	None	Rt. OA-PICA anastomosis, Rt. PICA origin clip ligation, Rt. VA proximal clip ligation	14	None	None	Good	Complete	0	-	10
3	60	M	IV	Lt.	None	Lt. OA-PICA anastomosis, Lt. PICA origin clip ligation, Lt. VA proximal clip ligation	2	None	None	Good	Complete	3	-	3
4	54	M	IV	Rt.	None	Rt. OA-PICA anastomosis, Rt. PICA origin clip ligation, Rt. VA proximal clip ligation	14	None	None	Good	Complete	4	-	1

F: female, H&H: Hunt and Hess grade, Lt.: left, M: male, mRS: modified Rankin Scale, OA: occipital artery, PICA: posterior inferior cerebellar artery, rt.: right, SAH: subarachnoid hemorrhage, VA: vertebral artery.



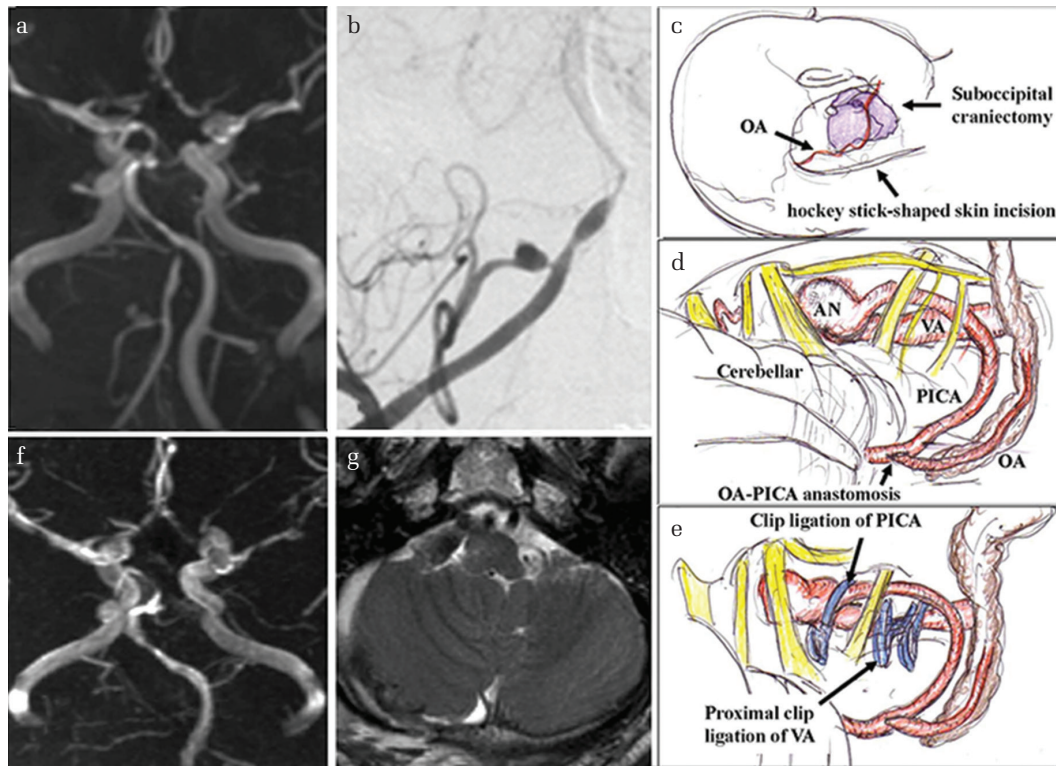


**Fig. 1** Case 1: Conventional angiography of the left VA performed at the time of admission showed aneurysmal dilation on the left VA involving the PICA origin (a: frontal view, b: lateral view, *arrow*: dilation). Conventional angiography of the right VA after proximal occlusion of the left VA and endovascular coiling showed persistent retrograde flow to the residual aneurysm and left PICA (c: frontal view, d: lateral view). Follow-up angiography of the right VA performed 6 months later revealed enlargement of the residual aneurysm (*arrow*). Filling was via the contralateral right VA (e: frontal view, f: lateral view). VA: vertebral artery, PICA: posterior inferior cerebellar artery.



**Fig. 2** Case 1: A tonsillomedullary segment of the left PICA was used for left OA-PICA anastomosis (a). Then the origin of the left PICA was surgically clipped (b). Follow-up angiography of the right VA performed 14 days later revealed complete thrombosis of the residual dissecting aneurysm (c: frontal view). Angiography of the left ECA showed good patency of the bypass graft (d: lateral view). OA: occipital artery, PICA: posterior inferior cerebellar artery, AN: aneurysmal dilation, VA: vertebral artery, ECA: external cervical artery.

days after the insult via the right lateral suboccipital approach (Fig. 3c). An OA-PICA bypass was placed (Fig. 3d) followed by surgical clipping of the PICA at a site distal to the aneurysmal dilation. Because the distal site of the dissected VA segment extended to the contralateral side, it was difficult to observe the distal terminus of the dissecting aneurysm. No perforator was found within sight of the VA. Therefore, we clipped the right VA at the site proximal to the aneurysm instead of trapping the aneurysm (Fig. 3e). Micro-Doppler ultrasound confirmed the cessation of intra-aneurysmal blood flow from the contralateral VA. MRI and angiography performed on the 7th postoperative day showed complete aneurysmal obliteration without brainstem or cerebellar infarction (Figs. 3f and 3g). Angiographs acquired on the 14th postoperative day confirmed good patency of the bypass graft, and complete aneurysmal obliteration. His neurological condition was normal and the patient was discharged on the 21st postoperative day. CTA performed 6 months after surgery showed good patency of the bypass graft and no evidence of recurrence. His neurologic



**Fig. 3** Case 2: Magnetic resonance angiography (a: frontal view) and conventional angiography of the right VA (b: lateral view) showed a pearl-and-string sign at the right VA and the right PICA origin. Via the right lateral suboccipital approach (c), we performed a right OA-PICA bypass (d) followed by surgical clipping of the right PICA at the distal site of the aneurysmal dilation and the right VA at a site proximal to the dissecting aneurysm (e). Postoperative magnetic resonance angiography- (f) and magnetic resonance imaging studies (g) confirm complete aneurysmal obliteration without brain stem- or cerebellar infarction. OA: occipital artery, PICA: posterior inferior cerebellar artery, VA: vertebral artery.

condition remained normal in the course of regular follow-up at the outpatient clinic.

## Discussion

Despite surgical and endovascular advances, the treatment of VA dissecting aneurysms involving the PICA origin remains challenging. Obliteration of the whole dissecting segment by surgical- or internal endovascular trapping is thought to effectively prevent rebleeding. However, these methods result in the obliteration of branches from the VA or the proximal segment of PICA that perforate the brainstem.<sup>5,13,18,20</sup> Consequently, complete isolation of the VA dissecting aneurysm by trapping, and reconstruction of the PICA are thought to be preferable. Although this technique can prevent both recurrent hemorrhage and cerebellar infarction, procedural complications have been reported.<sup>3,10–12</sup> Because the dissected artery is close to the lower brainstem and lower cranial nerves, its surgical manipulation may result in their iatrogenic injury.<sup>21</sup> Also, when the dissection extends close to the vertebrobasilar

junction, clipping of the distal site of the dissection is anatomically difficult and may obliterate the artery perforating the brainstem.

Postoperative medullary infarction is a complication of internal endovascular trapping after PICA revascularization. Procedural complications of endovascular treatment occurred in 14–57% of patients with ruptured VA dissecting aneurysms involving the PICA origin.<sup>5,13,18,20</sup> According to Endo et al.,<sup>12</sup> when the perforators arose from the PICA, some patients suffered medullary infarcts after internal coil trapping and OA-PICA anastomosis.

Reconstructive endovascular treatment using a stent to address VA dissecting aneurysm has been reported.<sup>5,13,14,16–19</sup> To preserve PICA patency, stenting with or without coil embolization has been considered one of the best management strategies for VA dissecting aneurysms involving the PICA origin. However, complete obliteration can be achieved in only a small number of patients and many suffer recurrence.<sup>13,16</sup> Ahn et al.<sup>13</sup> reported that the incomplete obliteration rate was 60% and



Kim et al.<sup>16)</sup> documented that involvement of the PICA origin was the only independent risk factor for recurrence after the endovascular treatment of VA dissecting aneurysms because the blood flow to the PICA was preserved. They suggested that persistent flow through the unprotected remnant of the dissecting aneurysm toward the PICA may be responsible.

Proximal occlusion of the VA risks rebleeding due to retrograde blood flow from the contralateral VA to the PICA.<sup>2,22–24)</sup> If persistent retrograde flow to the PICA is one of the main reasons for rebleeding or recurrence in patients treated with proximal occlusion of the ipsilateral VA, then clip ligation of the PICA origin after revascularization may reduce these risks. Rebleeding after the proximal occlusion of VA dissecting aneurysms involving the PICA origin occurred 18 and 23 days post-treatment,<sup>22,23)</sup> indicating that it is an option for preventing rebleeding in patients with acute SAH. However, to prevent recurrence in the chronic phase of SAH, additional procedures such as trapping of the aneurysm or clipping of the PICA origin must be performed to reduce the retrograde blood flow to the PICA.<sup>3)</sup>

We hypothesized that as antegrade flow to the aneurysm was stopped by proximal occlusion of the VA and retrograde flow by clip ligation of the PICA

origin, the reduction in aneurysmal flow encourages spontaneous thrombosis of the dissecting aneurysm. Although retrograde blood flow persisted in the absence of trapping, the reduction in outflow through the remnant dissecting aneurysm may decrease the intraluminal pressure and prevent aneurysm rupture. This outflow reduction concept has been applied in the treatment of unclippable giant fusiform middle cerebral artery (MCA) aneurysms<sup>25–29)</sup> because the strategy of combining extracranial–intracranial bypass with distal parent vessel occlusion encouraged spontaneous aneurysm thrombosis. Horowitz et al.<sup>25)</sup> suggested that, based on the Bernoulli equation, the magnitude of intraluminal pressure after the distal outflow occlusion of aneurysms was less than the normal variation. They concluded that the pursuance of daily activities did not significantly raise the risk for aneurysm rupture due to flow stagnation and consequent clot formation within the aneurysm.

In review of the literature, 20 ruptured VA dissecting aneurysms involving the PICA were treated by trapping plus PICA reconstruction (Table 2). The six out of the 20 previously reported patients were treated by internal coil trapping,<sup>9,12)</sup> 14 were treated by trapping with surgical clip.<sup>4,10,30–33)</sup> In 16 out of the 21 patients, OA-PICA anastomosis was performed for PICA reconstruction.<sup>4,9,10,12,30)</sup>

**Table 2 Clinical summary of the patients with ruptured VA dissecting aneurysm involving the PICA origin treated by trapping plus PICA reconstruction**

Series	Number of cases	Treatment	Procedural complication	Procedural complication rate	Graft patency	Aneurysm obliteration
Wang et al. (2014) <sup>10)</sup>	5	Trapping with clip + OA-PICA anastomosis	Transient lower cranial nerve palsy ( $n = 3$ )	60%	Good	Complete
Park et al. (2014) <sup>9)</sup>	1	Internal coil trapping + OA-PICA anastomosis	None	0%	Good	Complete
Hamasaki et al. (2014) <sup>30)</sup>	1	Trapping with clip + OA-PICA anastomosis	None	0%	Occluded (asymptomatic)	Complete
Endo et al. (2013) <sup>12)</sup>	5	Internal coil trapping + OA-PICA anastomosis	Medullary infarction ( $n = 3$ )	60%	Good	Complete
Czabanka et al. (2011) <sup>31)</sup>	1	Trapping with clip + VA-PICA anastomosis with radial artery graft	None	0%	Good	Complete
Ogasawara et al. (2006) <sup>32)</sup>	2	Trapping with clip + Transposition of PICA to VA	Transient lower cranial nerve palsy ( $n = 1$ )	50%	Good	Complete
Hamada et al. (2003) <sup>4)</sup>	4	Trapping with clip + OA-PICA anastomosis	Transient lateral medullary syndrome ( $n = 2$ )	50%	Good	Complete
Durward (1995) <sup>33)</sup>	1	Trapping with clip + Transposition of PICA to VA	None	0%	Good	Complete
Total	20		9	45%		

OA: occipital artery, PICA: posterior inferior cerebellar artery, VA: vertebral artery.

Transposition of PICA to VA was performed in three patients,<sup>32,33)</sup> and VA-PICA anastomosis with radial artery graft in one patient.<sup>31)</sup> Although complete aneurysm obliteration was achieved by trapping in all patients, nine (45%) of the 20 patients had treatment-related complications. Lower cranial nerve palsy and medullary infarction were treatment-related complications. These findings suggest that surgical or internal trapping of the dissecting segment are optimal for the complete obliteration of the dissecting aneurysms, but not always safe treatment option for ruptured VA dissecting aneurysms involving the PICA. As a practical matter, it can be difficult to achieve complete trapping because some dissecting aneurysms in this region are large and extend to the midline. Surgical manipulations in the insufficient working space may result in iatrogenic damage of lower cranial nerves, while blind clipping at a site distal to the dissecting aneurysm may obliterate the perforating artery.

We considered our treatment strategy could reduce surgical manipulation by not conducting complete trapping of dissecting aneurysms. None of our four patients suffered rebleeding and we encountered no surgical complications. On follow-up angiograms performed 2–3 weeks after treatment, all dissecting aneurysms were thrombosed and despite thrombosis in the dissecting segment, no ischemic complications involving the perforating artery were observed. We attribute their absence to the persistence of blood flow to the perforating artery although the dissecting aneurysm had disappeared on postoperative angiographs, or there was originally no perforator in the lesion site of VA. An alternative explanation may be the formation of collateral circulation associated with gradual clot formation in the dissecting aneurysm. Such events were observed in patients with unclippable giant MCA aneurysms when lenticulostriate perforators were involved.<sup>25,28,29)</sup> Their treatment by EC-IC bypass and distal parent vessel occlusion did not elicit ischemic complications.

Flow-diverter stenting has been used for the successful treatment of VA dissecting aneurysms.<sup>34–37)</sup> As the pipeline stent is far less porous than conventional stents, its use may help to reduce the rate of rebleeding and of ischemic complications.

Our study has some limitations. The study population was small and originated from a single institution. This limits the evaluation of the surgical outcomes, complications, and the long-term prevention of recurrence. Also, our strategy is applicable only in patients able to tolerate VA occlusion. In patients with a single vertebral artery and insufficient posterior communicating arteries, stent-assisted coiling remains indicated.<sup>6)</sup>

## Conclusion

We report four patients with dissecting VA aneurysms involving the PICA origin who were treated by proximal occlusion of the VA and clip-ligation of the origin of the PICA combined with PICA revascularization. This treatment was successful in all patients and none experienced neurological deterioration or recurrence. We suggest this technique as an alternative strategy to address VA dissecting aneurysms involving the PICA origin because it may reduce the complication rate associated with aneurysmal trapping.

## Author Contributions

All authors accept equal responsibility for the content of this report. None has any financial interests concerning this manuscript.

## Conflicts of Interest Disclosure

The authors report no conflict of interest concerning the materials or methods used in this study or the findings reported. All authors have completed the on-line self-reported COI disclosure statement on the website of The Japan Neurosurgical Society.

## References

- 1) Yamaura A, Watanabe Y, Saeki N: Dissecting aneurysms of the intracranial vertebral artery. *J Neurosurg* 72: 183–188, 1990
- 2) Mizutani T, Aruga T, Kirino T, Miki Y, Saito I, Tsuchida T: Recurrent subarachnoid hemorrhage from untreated ruptured vertebrobasilar dissecting aneurysms. *Neurosurgery* 36: 905–911; discussion 912–913, 1995
- 3) Iihara K, Sakai N, Murao K, et al.: Dissecting aneurysms of the vertebral artery: a management strategy. *J Neurosurg* 97: 259–267, 2002
- 4) Hamada J, Kai Y, Morioka M, Yano S, Todaka T, Ushio Y: Multimodal treatment of ruptured dissecting aneurysms of the vertebral artery during the acute stage. *J Neurosurg* 99: 960–966, 2003
- 5) Lee JM, Kim TS, Joo SP, Yoon W, Choi HY: Endovascular treatment of ruptured dissecting vertebral artery aneurysms—long-term follow-up results, benefits of early embolization, and predictors of outcome. *Acta Neurochir (Wien)* 152: 1455–1465, 2010
- 6) Peluso JP, van Rooij WJ, Sluzewski M, Beute GN, Majoie CB: Endovascular treatment of symptomatic intradural vertebral dissecting aneurysms. *AJNR Am J Neuroradiol* 29: 102–106, 2008
- 7) Rabinov JD, Hellinger FR, Morris PP, Ogilvy CS, Putman CM: Endovascular management of vertebrobasilar

- dissecting aneurysms. *AJNR Am J Neuroradiol* 24: 1421–1428, 2003
- 8) Sugi K, Tokunaga K, Watanabe K, et al.: Emergent endovascular treatment of ruptured vertebral artery dissecting aneurysms. *Neuroradiol* 47: 158–164, 2005
  - 9) Park W, Ahn JS, Park JC, Kwun BD, Kim CJ: Occipital artery-posterior inferior cerebellar artery bypass for the treatment of aneurysms arising from the vertebral artery and its branches. *World Neurosurg* 82: 714–721, 2014
  - 10) Wang C, Shi XE, Wang J, Wang B, Tang Z: Long-term outcomes of trapping vertebral artery-posterior inferior cerebellar artery dissecting aneurysms after revascularization. *Neurol India* 62: 15–18, 2014
  - 11) Takikawa S, Kamiyama H, Nomura M, Abe H, Saitoh H: [Vertebral dissecting aneurysm treated with trapping and bilateral posterior inferior cerebellar artery side-to-side anastomosis; case report]. *No Shinkei Geka* 19: 571–576, 1991 (Japanese)
  - 12) Endo H, Matsumoto Y, Kondo R, et al.: Medullary infarction as a poor prognostic factor after internal coil trapping of a ruptured vertebral artery dissection. *J Neurosurg* 118: 131–139, 2013
  - 13) Ahn JY, Han IB, Kim TG, et al.: Endovascular treatment of intracranial vertebral artery dissections with stent placement or stent-assisted coiling. *AJNR Am J Neuroradiol* 27: 1514–1520, 2006
  - 14) Lv X, Jiang C, Li Y, Wu Z: Clinical outcomes of ruptured and unruptured vertebral artery-posterior inferior cerebellar artery complex dissecting aneurysms after endovascular embolization. *AJNR Am J Neuroradiol* 31: 1232–1235, 2010
  - 15) Su W, Gou S, Ni S, et al.: Management of ruptured and unruptured intracranial vertebral artery dissecting aneurysms. *J Clin Neurosci* 18: 1639–1644, 2011
  - 16) Kim BM, Shin YS, Kim SH, et al.: Incidence and risk factors of recurrence after endovascular treatment of intracranial vertebrobasilar dissecting aneurysms. *Stroke* 42: 2425–2430, 2011
  - 17) Zhao KJ, Fang YB, Huang QH, et al.: Reconstructive treatment of ruptured intracranial spontaneous vertebral artery dissection aneurysms: long-term results and predictors of unfavorable outcomes. *PLoS ONE* 8: e67169, 2013
  - 18) Chen YA, Qu RB, Bian YS, Zhu W, Zhang KP, Pang Q: Stent placement to treat ruptured vertebral dissecting aneurysms. *Interv Neuroradiol* 19: 479–482, 2013
  - 19) Ota T, Sato M, Amano T, Saito A, Matsumaru Y: Reconstructive endovascular treatment of ruptured vertebral artery dissection involving the posterior inferior cerebellar artery. *Acta Neurochir (Wien)* 158: 1089–1093, 2016
  - 20) Aihara M, Naito I, Shimizu T, et al.: Predictive factors of medullary infarction after endovascular internal trapping using coils for vertebral artery dissecting aneurysms. *J Neurosurg* 11: 1–7, 2017
  - 21) Al-khayat H, Al-Khayat H, Beshay J, Manner D, White J: Vertebral artery-posteroinferior cerebellar artery aneurysms: clinical and lower cranial nerve outcomes in 52 patients. *Neurosurgery* 56: 2–10; discussion 11, 2005
  - 22) Kitanaka C, Morimoto T, Sasaki T, Takakura K: Rebleeding from vertebral artery dissection after proximal clipping. Case report. *J Neurosurg* 77: 466–468, 1992
  - 23) Takai N, Ezuka I, Sorimachi T, Kumagai T, Sano K: Vertebral artery dissecting aneurysm rebleeding after proximal occlusion—case report. *Neurol Med Chir (Tokyo)* 33: 765–768, 1993
  - 24) Kitanaka C, Sasaki T, Eguchi T, Teraoka A, Nakane M, Hoya K: Intracranial vertebral artery dissections: clinical, radiological features, and surgical considerations. *Neurosurgery* 34: 620–626; discussion 626–627, 1994
  - 25) Horowitz MB, Yonas H, Jungreis C, Hung TK: Management of a giant middle cerebral artery fusiform serpentine aneurysm with distal clip application and retrograde thrombosis: case report and review of the literature. *Surg Neurol* 41: 221–225, 1994
  - 26) Karnchanapandh K, Imizu M, Kato Y, Sano H, Hayakawa M, Kanno T: Successful obliteration of a ruptured partially thrombosed giant m1 fusiform aneurysm with coil embolization at distal m1 after extracranial-intracranial bypass. *Minim Invasive Neurosurg* 45: 245–250, 2002
  - 27) Ferroli P, Ciceri E, Parati E, Minati L, Broggi G: Obliteration of a giant fusiform carotid terminus-M1 aneurysm after distal clip application and extracranial-intracranial bypass. Case report. *J Neurosurg Sci* 51: 71–76, 2007
  - 28) Yoon WK, Jung YJ, Ahn JS, Kwun BD: Successful obliteration of unclippable large and giant middle cerebral artery aneurysms following extracranial-intracranial bypass and distal clip application. *J Korean Neurosurg Soc* 48: 259–262, 2010
  - 29) Kalani MY, Zabramski JM, Hu YC, Spetzler RF: Extracranial-intracranial bypass and vessel occlusion for the treatment of unclippable giant middle cerebral artery aneurysms. *Neurosurgery* 72: 428–435; discussion 435–436, 2013
  - 30) Hamasaki O, Ikawa F, Hidaka T, Kurokawa Y, Yonezawa U: Treatment of ruptured vertebral artery dissecting aneurysms. A short report. *Interv Neuroradiol* 20: 304–311, 2014
  - 31) Czabanka M, Ali M, Schmiedek P, Vajkoczy P, Lawton MT: Vertebral artery-posterior inferior cerebellar artery bypass using a radial artery graft for hemorrhagic dissecting vertebral artery aneurysms: surgical technique and report of 2 cases. *J Neurosurg* 114: 1074–1079, 2011
  - 32) Ogasawara K, Kubo Y, Tomitsuka N, et al.: Treatment of vertebral artery aneurysms with transposition of the posterior inferior cerebellar artery to the vertebral artery combined with parent artery occlusion. Technical note. *J Neurosurg* 105: 781–784, 2006
  - 33) Durward QJ: Treatment of vertebral artery dissecting aneurysm by aneurysm trapping and posterior inferior cerebellar artery reimplantation. Case report. *J Neurosurg* 82: 137–139, 1995



- 34) Chalouhi N, Tjoumakaris S, Dumont AS, et al.: Treatment of posterior circulation aneurysms with the pipeline embolization device. *Neurosurgery* 72: 883–889, 2013
- 35) Ducruet AF, Crowley RW, Albuquerque FC, McDougall CG: Reconstructive endovascular treatment of a ruptured vertebral artery dissecting aneurysm using the pipeline embolization device. *J Neurointerv Surg* 5: e20, 2013
- 36) Narata AP, Yilmaz H, Schaller K, Lovblad KO, Pereira VM: Flow-diverting stent for ruptured intracranial dissecting aneurysm of vertebral artery. *Neurosurgery* 70: 982–988; discussion 988–989, 2012
- 37) Yeung TW, Lai V, Lau HY, Poon WL, Tan CB, Wong YC: Long-term outcome of endovascular reconstruction with the pipeline embolization device in the management of unruptured dissecting aneurysms of the intracranial vertebral artery. *J Neurosurg* 116: 882–887, 2012

---

*Address reprint requests to:* Yasushi Takagi, MD, PhD,  
Department of Neurosurgery Tokushima University,  
3-18-15 Kuramoto-cho, Tokushima, Tokushima  
770-8503, Japan.  
*e-mail:* ytakagi@tokushima-u.ac.jp