

Correlation Between the Sites of Onset of Basal Cell Carcinoma and the Embryonic Fusion Planes in the Auricle

Clinical Medicine Insights: Oncology
Volume 12: 1–5
© The Author(s) 2018
Article reuse guidelines:
sagepub.com/journals-permissions
DOI: 10.1177/1179554918817328



Giovanni Nicoletti^{1,2,3} , Marco Mario Tresoldi^{1,3}, Alberto Malovini⁴, Sebastien Prigent¹, Manuela Agozzino⁵ and Angela Faga^{2,3,6}

¹Plastic and Reconstructive Surgery, Department of Clinical, Surgical, Diagnostic and Pediatric Sciences, University of Pavia, Pavia, Italy. ²Advanced Technologies for Regenerative Medicine and Inductive Surgery Research Center, University of Pavia, Pavia, Italy. ³Plastic and Reconstructive Surgery Unit, Istituti Clinici Scientifici Maugeri, Pavia, Italy. ⁴Laboratory of Informatics and Systems Engineering for Clinical Research, Istituti Clinici Scientifici Maugeri, Pavia, Italy. ⁵Pathological Anatomy and Histology Unit, Istituti Clinici Scientifici Maugeri, Pavia, Italy. ⁶Department of Molecular Medicine, University of Pavia, Pavia, Italy.

ABSTRACT

OBJECTIVES: This study aims at the identification of the distribution of basal cell carcinomas (BCCs) in the auricle in correlation with the currently most credited sites of the embryonic fusion planes of the auricle.

METHODS: An overall number of 69 patients with 72 BCCs of the auricle were enrolled in the study over a period of 14 years, from June 2003 to October 2017. All the cases underwent medical preoperative digital photography and the specific location of each BCC was coded on an original full-size anatomical diagram of the auricle derived from the reports by Streeter, Wood-Jones, Park, Porter, and Minoux showing the currently most credited sites of the embryonic fusion planes arbitrarily featured as two 5-mm-wide ribbon-like areas: (1) the hyoid-mandibular fusion plane (HM-FP) running from the upper margin of the tragus toward the concha and then deflecting toward the lower margin of the tragus and (2) the free ear fold-hyoid fusion plane (FEFH-FP) running from the cranial-most portion of the helix to the mid-portion of the ascending helix. The latter fusion planes were comprehensively termed embryological fusion planes (EFP) while all of the remaining surface of the auricle was comprehensively termed non-fusion area (NFA). The surfaces of all of the latter areas were calculated using the ImageJ software.

RESULTS: According to our data, the greatest number of BCCs was observed within the currently most credited sites of the embryonic fusion planes of the auricle. The latter sites displayed a 12-fold increased tumor incidence in comparison with the remaining surface of the ear.

CONCLUSIONS: A correspondence between the sites of onset of BCCs and the sites of merging and/or fusion of embryonal processes was demonstrated in the auricle. Therefore, the latter sites might be considered as high-risk areas for the development of a BCC. Such an evidence provides further support to the hypothesis of an embryological pathogenesis of BCC.

KEYWORDS: head and neck cancer, epidemiology, skin cancer, embryology, basal cell carcinoma, fusion plane, ear

RECEIVED: May 24, 2018. **ACCEPTED:** November 2, 2018.

TYPE: Original Research

FUNDING: The author(s) received no financial support for the research, authorship, and/or publication of this article.

DECLARATION OF CONFLICTING INTERESTS: The author(s) declared no potential conflicts of interest with respect to the research, authorship, and/or publication of this article.

CORRESPONDING AUTHOR: Giovanni Nicoletti, Plastic and Reconstructive Surgery, Department of Clinical, Surgical, Diagnostic and Pediatric Sciences, University of Pavia, Via Alessandro Brambilla, 74, 27100 Pavia, Italy. Email: giovanni.nicoletti@unipv.it

Introduction

A recent report of ours demonstrated a significantly high correlation between the distribution of the basal cell carcinomas (BCCs) and the sites of congenital clefts of the head and neck assumed as the anatomical markers in the live born of the sites of fusion and/or merging of embryonic processes.¹ Such an evidence supported the hypothesis of an embryological role in the pathogenesis of BCC.

This previous research deliberately did not include the BCCs of the auricle because of the lack of unanimous consensus on the topography of the embryonic fusion planes in this anatomical site. This study aims at the identification of the distribution of BCCs in the auricle in correlation with the currently most credited sites of the embryonic fusion planes of the auricle according

to the reports by Streeter,² Wood-Jones and I-Chuan,³ Park and Roh,⁴ Porter and Tan,⁵ and Minoux et al.⁶

Materials and Methods

An overall number of 69 patients with 72 BCCs of the auricle were admitted at the Plastic and Reconstructive Surgery Unit of the University of Pavia, Istituti Clinici Scientifici Maugeri Research and Care Institute, Pavia (Italy), over a period of 14 years, from June 2003 to October 2017.

For each patient, data on gender, age at diagnosis, localization of the tumor, and side of the affected ear were recorded.

In our study, the whole auricular cartilage framework covered by skin and the ear-lobule were conventionally assumed as the auricle.



Creative Commons Non Commercial CC BY-NC: This article is distributed under the terms of the Creative Commons Attribution-NonCommercial 4.0 License (<http://www.creativecommons.org/licenses/by-nc/4.0/>) which permits non-commercial use, reproduction and distribution of the work without further permission provided the original work is attributed as specified on the SAGE and Open Access pages (<https://us.sagepub.com/en-us/nam/open-access-at-sage>).

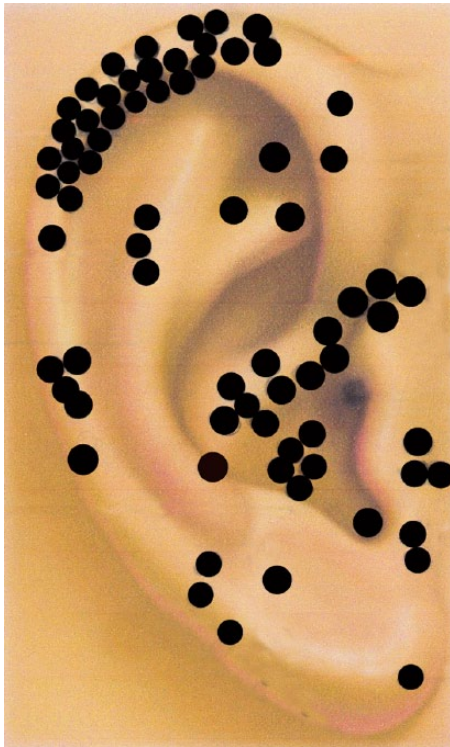


Figure 1. Site of each BCC coded according to its approximate center on a full size anatomical diagram of the auricle. BCC indicates basal cell carcinoma.

Multiple lesions from individual patients were considered as separate cases.

The study only included histologically diagnosed BCC and, according to the Sexton et al⁷ histopathological classification, the sample was divided into 2 groups: one including the aggressive BCCs and another including the non-aggressive ones. The aggressive group included the following histological types: morphea-like, infiltrative, basal squamous, micronodular, and mixed (superficial multifocal and micronodular, adenoid and morphea-like, superficial multifocal and morphea-like, nodular and morphea-like, and nodular and micronodular). The non-aggressive group included adenoid, nodular, superficial multifocal, and mixed (nodular and adenoid, superficial multifocal and nodular). Ulceration and pigmentation were considered as unimportant features in terms of histological aggressiveness.

All of the cases underwent medical preoperative digital photography and the records were stored in the Unit's dedicated master file.

The archived digital images were coded according to the specific location of each BCC using an original anatomical diagram derived from the reports by Streeter,² Wood-Jones and I-Chuan,³ Park and Roh,⁴ Porter and Tan,⁵ and Minoux et al⁶ showing the currently most credited sites of the embryonic fusion planes of the auricle. Considering the morphological complexity of such an anatomical structure, the precise site of each BCC was coded according to its approximate center (Figure 1). According to the reported literature, 2 sites of supposed fusion and/or merging of embryonic processes were

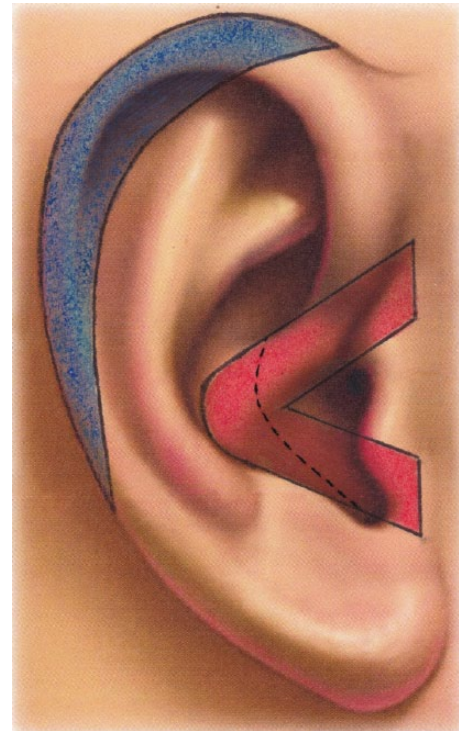


Figure 2. Original full-size anatomical diagram showing the sites of the embryonic fusion planes of the auricle according to Streeter, Wood-Jones, Park, Porter, and Minoux. The hyoid-mandibular fusion plane (HM-FP) is featured in red and the free ear fold-hyoid fusion plane (FEFH-FP) in blue.

identified on a full-size anatomical diagram of the auricle (Figure 2): the first was represented by a broken line running from the upper margin of the tragus toward the concha and then deflecting toward the lower margin of the tragus; the second by a line running from the cranial-most portion of the helix to the mid-portion of the ascending helix. To provide a realistic approximation of these sites on the adult auricle, the latter lines were arbitrarily represented as two 5-mm-wide ribbon-like areas on the full-size anatomical diagram, respectively, termed hyoid-mandibular fusion plane (HM-FP) and free ear fold-hyoid fusion plane (FEFH-FP) and comprehensively termed embryological fusion planes (EFP). All of the remaining surface of the auricle was comprehensively termed non-fusion area (NFA). The surface of each area on the full-size diagram of the auricle was calculated using the ImageJ software. The percentage of the auricle's surface covered by the fusion planes was calculated, too.

All of the cases were divided into 2 groups: one including all the BCCs sitting on the fusion planes and another including all the tumors sitting within the NFA. The first group was then divided into 2 subgroups corresponding to the HM-FP and FEFH-FP, respectively (Figure 3). The BCCs in each group and subgroup were further divided into aggressive and non-aggressive ones.

A formal informed written consent was obtained from all the patients and the study conformed to the Declaration of Helsinki.

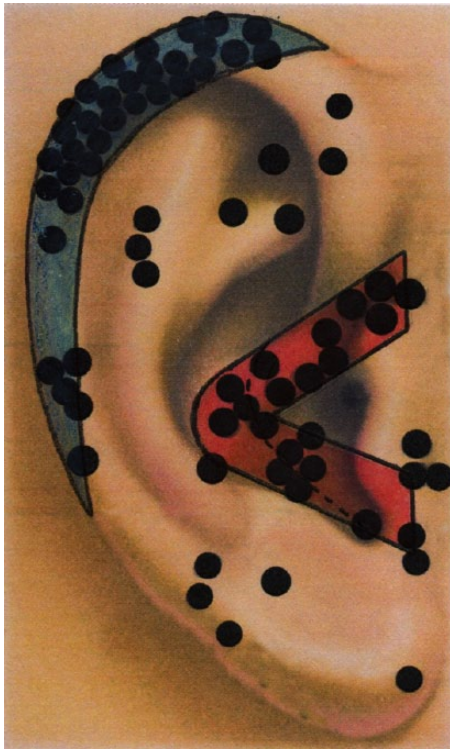


Figure 3. Site of each BCC coded according to its approximate center on a full-size anatomical diagram of the auricle showing the embryonic fusion planes according to Streeter, Wood-Jones, Park, Porter, and Minoux. The hyoid-mandibular fusion plane (HM-FP) is featured in red and the free ear fold-hyoid fusion plane (FEFH-FP) in blue. BCC indicates basal cell carcinoma.

Statistical analysis

Categorical variables' distribution was described in terms of counts and frequencies (%).

The exact binomial test was applied to verify whether the frequency of tumors observed in the examined surfaces was significantly different from the following expected estimates:

The probability of observing tumors in EFP areas "by chance" assumed corresponding to 50%;

The percentage of surface area occupied by each fusion plane;

The relative tumor density (RTD) was estimated for each anatomical site as reported below

$$RTD = \frac{\left[\frac{\text{(number of site-specific tumors)}}{\text{(total number of tumors of the ear)}} \right]}{\left[\frac{\text{(site-specific area)}}{\text{(total area of the ear)}} \right]}$$

According to this formula:

RTD = 1: density of tumors on the whole ear;

RTD > 1: higher density of tumors in the specific site;

RTD < 1: lower density of tumors in the specific site.

The RTD values corresponding to different sites were compared as the ratio between site-specific RTDs.

Pearson chi-square test or Fisher exact test (when the contingency tables' counts were <5 observations in at least 1 cell) was applied to test for the presence of statistically significant differences in terms of aggressiveness' distribution between EFP areas and NFA.

Statistical analyses were performed by the R software (www.r-project.org).

Results

A total number of 72 BCC samples deriving from 69 patients (55 males, 14 females) were analyzed. In total, 57 BCCs (79.17%) derived from male patients and 15 (20.83%) from females. A total of 40 (55.55%) cases involved the left auricle and 32 (44.45%) the right one. Within the male patients, 31 (54.39%) BCCs involved the left auricle and 26 the right one (45.61%). In females, the distribution was 9 (60.00%) on the left and 6 (40.00%) on the right. The mean age at diagnosis was 76 (77 in males, 73 in females), and the median age was 79 (minimum 27, maximum 95).

The fusion planes comprehensively accounted for 23.22% of the whole surface of the auricle while the NFA accounted for the remaining 76.78%. In total, 57 (79.17%, 95% CI=67.98–87.84) out of 72 BCCs were localized within the EFP.

The exact binomial test demonstrated that both the percentage of BCCs within the EFP areas (79.17% vs 50%, $P < .001$) and the percentage of surface area occupied by the EFP (79.17% vs 23.22%, $P < .001$) were significantly different from the expected estimates.

The RTD in the EFP was 3.41 while the RTD in the NFA was 0.27. The RTD ratio between the RTD within the EFP and the RTD in the NFA was 12.63 (Table 1).

No statistically significant differences in terms of aggressiveness were observed among HM-FP, FEFH-FP, and NFA (P -value >.20) or when HM-FP and FEFH-FP were pooled into EFP and compared to NFA (P -value >.14; Table 2).

Discussion

BCC is traditionally believed as an ultra-violet (UV)-dependent skin malignancy with an increased incidence in the elderly. Although evidence shows a direct correlation between the amount of sun exposure and incidence of BCC, there is a discrepancy between the sites of highest exposure to sunlight and the sites of onset of BCCs. Such a figure casts doubt on the traditional environmental theory stating that BCCs are mainly ultra-violet light-related skin malignancies. Actually, the embryologic fusion planes have been correlated with the sites of onset and spread paths of BCCs, thus suggesting an embryologic pathogenesis in such a peculiar tumor.⁸ The latter hypothesis is further supported by recent reports on the Hedgehog signaling pathway that plays a

Table 1. Distribution of the BCCs within the embryological fusion planes and the non-fusion areas.

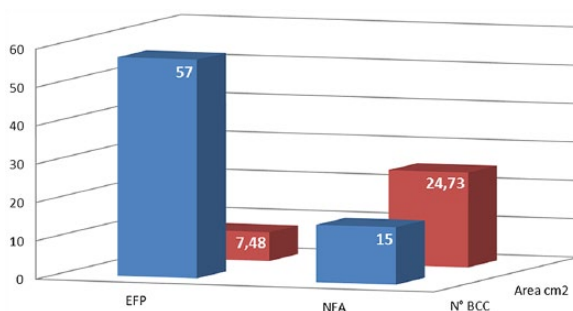
	EFP	HM-FP	FEFH-FP	NFA	TOTAL
Number of BCC	57*	22	35	15	72
Male	45	16	29	12	57
Female	12	6	6	3	15
Left ear (F/M)	29	10	19	11	40 (9/31)
Right ear (F/M)	28	12	16	4	32 (6/26)
Area (mm ²)	748	318	430	2473	3221
RTD EFP/NFA RTD ratio	3.41	2.96	3.72	0.27	1 12.63
% area	23.22%*	9.87%	13.35%	76.78%	100%
BCC frequency	79.17%*	30.56%	48.61%	20.83%	100%

Abbreviations: BCC, basal cell carcinoma; EFP, embryological fusion planes; F, female; FEFH-FP, free ear fold-hyoid fusion plane; HM-FP, hyoid-mandibular fusion plane; M, male; NFA, non-fusion area; RTD, relative tumor density.
* $P < .001$.

Table 2. BCC aggressiveness distribution by site.

VARIABLE	HM-FP VS FEFH-FP VS NFA						EFP VS NFA					
	HM-FP		FEFH-FP		NFA		P-VALUE	EFP		NFA		P-VALUE
	N	%	N	%	N	%		N	%	N	%	
Aggressiveness							.505					.735
Aggressive	13	59.09	16	45.71	9	60		29	50.88	9	60	
Non-aggressive	9	40.91	19	54.29	6	40		28	49.12	6	40	

Abbreviations: BCC, basal cell carcinoma; EFP, embryological fusion planes; FEFH-FP, free ear fold-hyoid fusion plane; HM-FP, hyoid-mandibular fusion plane; n, number of observations by site; NFA, non-fusion area; P , P -value expressing the presence of statistically significant differences in terms of variables' distribution across different sites; %, frequency (%) of observations by site.

**Figure 4.** Comparison between tumor incidence and surface of the embryological fusion planes and non-fusion area. BCC indicates basal cell carcinoma; EFP, embryological fusion planes; NFA, non-fusion area.

relevant role in human embryogenesis and whose activity is reduced or absent in adult individuals. Experimental animal studies⁹ and clinical translational investigations demonstrated that aberrant reactivation of this pathway is involved in the development of BCC and other malignancies.¹⁰⁻¹³ Further support to the hypothesis of an embryologic role for the pathogenesis of BCC was provided by a recently published study of ours demonstrating a topographic correspondence between the sites of BCCs and the

sites of congenital clefts in the head and neck, the latter being assumed as the anatomical markers in the live born of the sites of fusion and/or merging of embryonic processes.¹

The embryological development of the auricle is extremely complex and, to date, it is still poorly understood as demonstrated by the different and somewhat conflicting theories on its embryogenesis.

His^{14,15} in 1882 first suggested that the whole auricle derived from the merging of 6 hillocks along the margins of the first ectodermal fissure. Nevertheless, other authors¹⁶⁻¹⁸ at that time already highlighted the contribution of other structures, like the helix mandibularis and the helix hyoidalis, to the development of the ear. Further studies³ carried out accurate comparative observations between human embryos and patients suffering from congenital cleft malformations involving the external ear, thus crediting the hyoid and mandibular arches with the most relevant role in the development of the auricle and putting the hillocks back in the perspective of temporary structures with limited importance. Nowadays, studies based on the distribution of the vascular territories^{4,19,20} of the ear and on the topographic distribution of the specific Hoxa-2

gene^{6,21–23} demonstrate that the tissues participating in the development of the external ear are the mandibular arch, the hyoid arch, and the “Free Ear Fold,” a tissue separated from the hillock region, posterior to the hyoid arch.⁵

According to our data, the greatest number of BCCs was observed within the currently most credited sites of the embryonic fusion planes of the auricle (Figure 4). The latter sites displayed a 12-fold increased tumor incidence in comparison with the remaining surface of the ear; therefore, they might be considered as high-risk areas for the development of a BCC, irrespective of the tumor aggressiveness.

Our study had 2 intrinsic methodologic limitations: first, all of the surface measurements were calculated on a 2-dimensional anatomical model that inevitably did not take into precise account all of the concavities and convexities of a 3-dimensional ear model; second, the embryonic fusion planes were arbitrarily considered as a 5-mm-wide ribbon-like areas rather than sharp lines. Nevertheless, such a pattern was considered a reasonably tolerable approximation in the location of an embryological boundary in a fully developed adult auricle. Indeed, the small-sized sample failed to demonstrate any statistically significant correlation between the site of onset of BCCs and other reported parameters such as age at diagnosis and gender.

The presence of un-regressed signaling activities along the boundaries between different embryonal processes might be a research hypothesis to be further investigated.

Conclusions

Not surprisingly, like in the face and the neck, a correspondence between the sites of onset of BCCs and the sites of merging and/or fusion of embryonal processes was demonstrated in the auricle, too. The aberrant uncontrolled reactivation of the Hedgehog Pathway in such specific anatomical sites might be supposed to be the key event in the development of such a unique and peculiar tumor.

Our research provides further support to the hypothesis of an embryological pathogenesis of BCC and encourages future research in this incompletely explored field.

The clear identification of sensitive sites might promote the development of new strategies in prevention and therapy of BCC, with development of specific tools useful to shelter the latter sites from the environmental triggers and of target therapies suppressing the aberrant cell activities.

Author Contributions

GN conceived the study, analyzed the data and wrote the article.

MMT supervised the data collection, and contributed to the data analysis and to the writing of the article.

AM conceived the statistical methods, performed the statistical analysis and analyzed the data.

SP gathered the data and performed the literature review.

MA supervised, coordinated and performed the histological assessments.

AF conceived the study, analyzed the data and wrote the article.

ORCID iD

Giovanni Nicoletti  <https://orcid.org/0000-0002-1507-4067>

REFERENCES

- Nicoletti G, Brenta F, Malovini A, Jaber O, Faga A. Sites of Basal cell carcinomas and head and neck congenital clefts: topographic correlation. *Plast Reconstr Surg Glob Open*. 2014;2:e164. doi:10.1097/GOX.0000000000000119.
- Streeter GL. Development of the auricle in the human embryo. *Contrib Embryol*. 1922; 69:111.
- Wood-Jones F, I-Chuan W. The development of the external ear. *J Anat*. 1934;68:525–533.
- Park C, Roh TS. Anatomy and embryology of the external ear and their clinical correlation. *Clin Plast Surg*. 2002;29:155–174. doi:10.1016/S0094-1298(01)00008-6.
- Porter CJW, Tan ST. Congenital auricular anomalies: topographic anatomy, embryology, classification, and treatment strategies. *Plast Reconstr Surg*. 2005;115:1701–1712. doi:10.1097/01.PRS.0000161454.08384.0A.
- Minoux M, Kratochwil CF, Ducret S, et al. Mouse Hoxa2 mutations provide a model for microtia and auricle duplication. *Development*. 2013;140:4386–4397. doi:10.1242/dev.098046.
- Sexton M, Jones DB, Maloney ME. Histologic pattern analysis of basal cell carcinoma. Study of a series of 1039 consecutive neoplasms. *J Am Acad Dermatol*. 1990;23:1118–1126.
- Newman JC, Leffell DJ. Correlation of embryonic fusion planes with the anatomical distribution of basal cell carcinoma. *Dermatologic Surg*. 2007;33:957–965. doi:10.1111/j.1524-4725.2007.33198.x.
- Grachtchouk M, Pero J, Yang SH, et al. Basal cell carcinomas in mice arise from hair follicle stem cells and multiple epithelial progenitor populations. *J Clin Invest*. 2011;121:1768–1781. doi:10.1172/JCI46307.
- Epstein EH. Basal cell carcinomas: attack of the hedgehog. *Nat Rev Cancer*. 2008;8:743–754. doi:10.1038/nrc2503.
- Callahan CA, Oro AE. Monstrous attempts at adnexogenesis: regulating hair follicle progenitors through Sonic hedgehog signaling. *Curr Opin Genet Dev*. 2001;11:541–546.
- Hutchin ME, Kariapper MS, Grachtchouk M, et al. Sustained Hedgehog signaling is required for basal cell carcinoma proliferation and survival: conditional skin tumorigenesis recapitulates the hair growth cycle. *Genes Dev*. 2005;19:214–223. doi:10.1101/gad.1258705.
- Caro I, Low JA. The role of the hedgehog signaling pathway in the development of basal cell carcinoma and opportunities for treatment. *Clin Cancer Res*. 2010;16:3335–3339. doi:10.1158/1078-0432.CCR-09-2570.
- His W. Auf Stellung von Entwicklungsnormen: Zweiter Monat, Anatomie menschlicher Embryonen, Leipzig, F. C. W. Vogel. 1882:55–60.
- His W. Die formentwicklung des ausseren ohres: Anatomie menschlicher embryonen, part III. Leipzig: FCW Vogel. 1885.
- Gradenigo G. Die Formentwicklung der Ohrmuschel, niit Riicksicht auf die Morphologie und Teratologie derselben. *Centralbl Med Wiss*. 1888;26:82–117.
- Schwalbe G. *Das aussere Obr: Handb d Anat d Menschen* (ed. Von Bardeleben K), vol. 5. 1897:125–131.
- Schwalbe G. Beiträge zur Kenntnis des äusseren Ohres der Primaten. *Zeitschrift für Morphologie und Anthropologie. E. Schweizerbart'sche Verlagsbuchhandlung*. 1916; H.3:545–668.
- Park C. Correction of the unilateral question mark ear. *Plast Reconstr Surg*. 1998;101:1620–1623. doi:10.1097/01.prs.0000279556.11710.45.
- Park C. Congenital upper auricular detachment. *Plast Reconstr Surg*. 1999;104:488–490.
- Santagati F, Minoux M, Ren S-Y, Rijli FM. Temporal requirement of Hoxa2 in cranial neural crest skeletal morphogenesis. *Development*. 2005;132:4927–4936. doi:10.1242/dev.02078.
- Brown KK, Viana LM, Helwig CC, et al. HOXA2 haploinsufficiency in dominant bilateral microtia and hearing loss. *Hum Mutat*. 2013;34:1347–1351. doi:10.1002/humu.22367.
- Cox TC, Camci ED, Vora S, Luquetti DV, Turner EE. The genetics of auricular development and malformation: new findings in model systems driving future directions for microtia research. *J Med Genet*. 2014;57:394–401. doi:10.1016/j.ejmg.2014.05.003.