

[ PICTURES IN CLINICAL MEDICINE ]

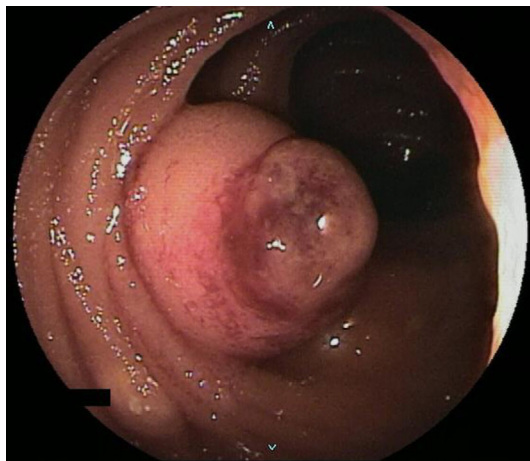
## Venous Aneurysm of the Jejunum

Kenta Kumagai, Masato Yoshioka, Naohiko Otsuka and Yuzo Yamamoto

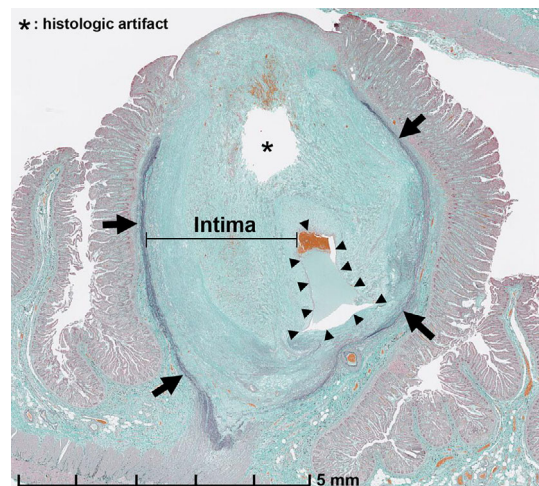
**Key words:** venous aneurysm, jejunum, intestinal bleeding

(Intern Med 58: 1517, 2019)

(DOI: 10.2169/internalmedicine.2213-18)



**Picture 1.**



**Picture 2.**

A 29-year-old woman repeatedly developed bloody stool. Esophagogastroduodenoscopy and total colonoscopy failed to detect the bleeding source. Double-balloon enteroscopy revealed a protruding tumor in the jejunum (Picture 1). The tumor was reddish brown and edematous and appeared to protrude from the mucosa. Partial resection of the jejunum was performed laparoscopically. A histological evaluation with Elastica-Masson staining revealed that the main part was occupied by fibrotic intimal hyperplasia in the submucosal tissue (Picture 2), narrowing the vascular lumen (arrowheads). The thickness of the tunica media remained normal (arrows). As there were no other enlarged veins around this tumor, it was diagnosed as a venous aneurysm. Venous aneurysm is a rare vascular abnormality that can develop anywhere in the body (1). It is a locally expanded segment of a vein showing a saccular shape and is clearly distinguished from varicose veins, in which varying degrees of continuously dilated veins run as meandering and/or bending vessels. With respect to intraperitoneal development, deaths due to rupture of the portal vein, spleen, and superior mesenteric venous aneurysm have been reported (2). However,

there has been no report on the development of this lesion in the digestive tract, as in our patient. When clinicians note similar findings, the possibility of a venous aneurysm should be considered, and surgery should be considered in order to prevent intestinal bleeding.

**The authors state that they have no Conflict of Interest (COI).**

### References

1. Teter KA, Maldonado TM, Adelman MA. A systematic review of venous aneurysms by anatomic location. *J Vasc Surg Venous Lymphat Disord* **6**: 408-413, 2018.
2. Calligaro KD, Ahmad S, Dandora R, et al. Venous aneurysms: surgical indications and review of the literature. *Surgery* **117**: 1-6, 1995.

The Internal Medicine is an Open Access journal distributed under the Creative Commons Attribution-NonCommercial-NoDerivatives 4.0 International License. To view the details of this license, please visit (<https://creativecommons.org/licenses/by-nc-nd/4.0/>).

Department of Gastroenterological Surgery, Akita University Graduate School of Medicine, Japan

Received: October 1, 2018; Accepted: October 22, 2018; Advance Publication by J-STAGE: January 10, 2019

Correspondence to Dr. Masato Yoshioka, [masato@gipc.akita-u.ac.jp](mailto:masato@gipc.akita-u.ac.jp)

© 2019 The Japanese Society of Internal Medicine. *Intern Med* 58: 1517, 2019