

Large Abdominal Wall Endometrioma Following Laparoscopic Hysterectomy

Jonathan Y. Song, MD, Erik Borncamp, MD, Philip Mehaffey, MD, Carlos Rotman, MD

ABSTRACT

Background: Endometriosis is a common condition in women that affects up to 45% of patients in the reproductive age group by causing pelvic pain. It is characterized by the presence of endometrial tissue outside the uterine cavity and is rarely found subcutaneously or in abdominal incisions, causing it to be overlooked in patients with abdominal pain.

Methods: A 45-year-old woman presented with lower abdominal pain 2 years following a laparoscopic supracervical hysterectomy. She was found to have incidental cholelithiasis and a large abdominal mass suggestive of a significant ventral hernia on CT scan.

Results: Due to the peculiar presentation, surgical intervention took place that revealed a large 9cm×7.6cm×6.2cm abdominal wall endometrioma.

Conclusion: Although extrapelvic endometriosis is rare, it should be entertained in the differential diagnosis for the female patient who presents with an abdominal mass and pain and has a previous surgical history.

Key Words: Laparoscopy, Abdominal wall, Endometrioma, Endometriosis, Hysterectomy.

INTRODUCTION

In spite of being a common cause for pelvic pain in women, endometriosis remains a diagnostic and sometimes a therapeutic challenge due to its variability in clinical presentation.¹⁻⁴ The pelvis is the most common site for disease occurrence, thus manifesting in pelvic pain, dyspareunia, dysmenorrhea, infertility, and cyclical bowel or bladder symptoms. Extrapelvic endometriosis however is quite rare, with an incidence of 0.03% to 0.47%,⁵⁻⁷ and more commonly found in cesarean delivery scars as incisional or cutaneous endometriosis.⁸ Although abdominal wall endometrioma (AWE) is associated with laparotomy incisions, a comprehensive literature review revealed this relationship involving laparoscopy scars to be extremely rare.⁹⁻¹² This article describes an interesting presentation that was first interpreted as a ventral hernia by the radiologist, but due to its questionable presentation, a surgical intervention revealed the contrary, ironically yielding possibly the largest AWE originating from a laparoscopy incision reported in the literature.

CASE REPORT

A 43-year-old nulligravida women with no significant medical history experienced menometrorrhagia resulting in anemia. The patient had multiple small uterine fibroids with no pelvic pain. After exhausting all conservative measures, the patient, who was not married and had no desire to bear children, declined an endometrial ablation and preferred to undergo definitive surgical management. The patient desired to keep her cervix and based on her age, the decision was made to preserve her ovaries. The patient underwent an uneventful outpatient laparoscopic supracervical hysterectomy. A small 12-week size, multi-leiomyomatous uterus was removed through the suprapubic port after the incision was extended, following our simplified laparoscopic abdominal morcellation (SLAM) technique where the specimen was cut into longitudinal strips. No endometrial lesions were seen. The pathology revealed multiple small fibroids and adenomyosis. The patient recovered without issues and presented 2 years later with abdominal pain. Examination revealed a mass cephalad to the suprapubic incision, and a CT of the abdomen and pelvis was suggestive of a large ventral

TLC Medical Group, SC, St. Charles, Illinois, Delnor Hospital, Geneva, Illinois, Rush University Medical Center, Chicago, Illinois, USA (Dr Song).

Central DuPage Hospital Winfield, Illinois, USA (Drs Borncamp, Mehaffey).

Oakbrook Institute of Endoscopy Oakbrook, Illinois, USA (Dr Rotman).

Address correspondence to: Jonathan Y. Song, MD, FACOG, FACS, 2455 Dean St., Suite A, St. Charles, Illinois 60175, USA. Telephone: (630) 513-9160, Fax (630) 513-9617.

DOI: 10.4293/108680811X13071180407078

© 2011 by JSLs, *Journal of the Society of Laparoendoscopic Surgeons*. Published by the Society of Laparoendoscopic Surgeons, Inc.

hernia (**Figure 1**). Incidentally, the patient was found to have extensive gallstones. Subsequently, the patient underwent a laparoscopic cholecystectomy that provided the opportunity to assess the abdominal wall; no hernia was seen. Due to the palpable mass and the possibility of a Desmoid tumor, a mini-laparotomy was performed, and a 4cm×4.1cm×3.7cm firm mass was resected and sent for a frozen section that revealed endometriosis (**Figures 2 and 3**). The resection was then completed, and an additional 5cm×3.5cm×2.5cm mass was resected, which was again confirmed to be endometriosis. The patient recovered uneventfully and was sent home the following day. The patient has done well since.

DISCUSSION

Present day theories regarding endometriosis pathogenesis include: endometrium implantation theory, coelomic metaplasia epithelioid theory, lympho-vascular dissemination

theory, and immunologic theory.^{13,14} Endometriosis occurring in different parts of the body may be attributed to different pathogeneses, but inadvertent, iatrogenic transfer of endometrial tissue is the most likely reason that results in abdominal incision endometriosis, and typical cases appear following cesarean deliveries.¹⁵ In our case, a similar theory is speculated. The morcellated uterus was removed from the body through the suprapubic incision after it was extended, allowing the adenomyosis to come in contact with the abdominal wall. Nothing during the initial surgery produced any suspicion of endometriosis, and we have utilized this morcellation technique in close to 1000 cases cumulatively by the authors, including but not limited to myomectomy, hysterectomy, and ovarian cystectomy specimens both large and small. This is the first time we have encountered such a finding in all of our surgeries. Why certain specimens can successfully inoculate the abdominal wall and others do not, even if some are obvious for endometriosis and adenomyosis, still remains to be answered.

Extrapelvic endometriosis in general is very difficult to diagnose due to its rarity; the possibility does not readily come into the minds of the treating physicians. The most common differential diagnoses include stitch granuloma, cellulitis, and hernia. Umbilical endometriosis can pose a diagnostic quandary, because it can mimic a malignant melanoma or the “sister Mary Joseph nodule” associated with intraabdominal malignancies. Although sonography can also be used to facilitate the process of making the diagnosis in addition to CT and MRI, no pathognomonic radiological findings exist for an AWE.¹⁶ Some literature suggests that there may be cyclical abdominal pain in

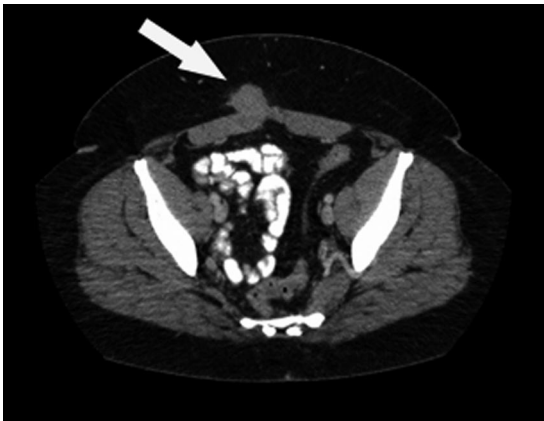

Figure 1. CT of the abdomen reveals a mass suggestive of a ventral hernia.

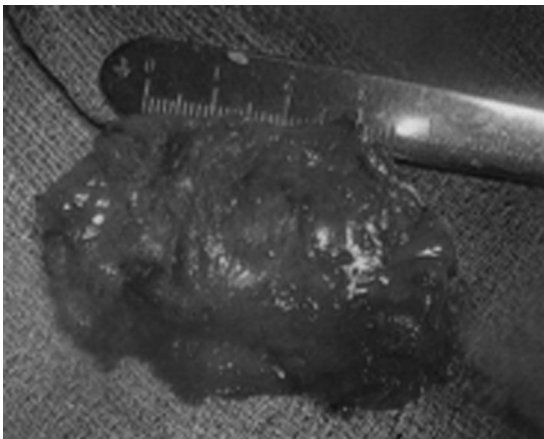


Figure 2. Resected abdominal mass sent for frozen section.

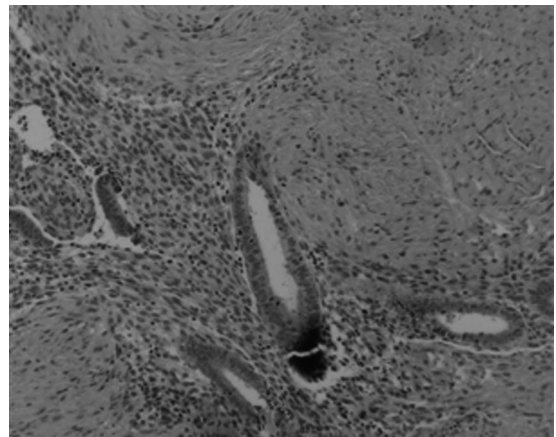


Figure 3. Hematoxylin and eosin stains reveal presence of benign endometrial glands and stroma with blood, embedded in unremarkable soft tissue. No features were present to suggest a malignant process.

patients who still have ovaries,¹⁷ but this was not the case in our patient. We believe clinical suspicion and examination remain the mainstay for intervention and treatment. A needle aspiration may be considered for confirming the diagnosis, but if the patient is experiencing pain, excision of the mass will be both therapeutic and diagnostic.

CONCLUSION

Based on a comprehensive review of the literature, as Garg et al⁴ and Poli-Neto et al⁷ mentioned in their findings, endometriosis is a complex disease, and existing theories are not sufficient to explain its pathophysiology or its site of occurrence. As in our case report, in a patient with no evidence, symptoms, or history of endometriosis with an incidental finding of adenomyosis on subsequent pathology, the presentation may not seem sufficient enough to entertain the diagnosis of AWE. However, as stated earlier, the AWE in our patient is most likely the result of inoculation of the abdominal wall via direct contact with the specimen during its extraction. Even the utilization of automatic morcellators, however, does not provide complete immunity to inadvertent inoculation as described by Sepilian's group,¹⁸ supporting the notion that we still do not have a complete understanding of this disease. Based on our experience, vigorous irrigation of the abdomen, pelvis, and abdominal wall should take place prior to closure, and all surgeons should include AWE in their differential diagnosis for the female patient who presents with an abdominal mass and pain and has a previous surgical history.

References:

1. Volpi E, Peano E, Ferrero A, Mosso L, Daniele A, Sismondi P. Association between ovarian endometriosis and malignancy in the peri-menopausal period: report of two cases and review of the literature. *Gynecol Surg*. 2010;7(1):13–17.
2. Steck W, Helwig E. Cutaneous endometriosis. *Clin Obstet Gynecol*. 1966;9:373–383.
3. Apostolidis S, Michalopoulos A, Papavramidis T, Papadopoulos V, Paramythiotis D, Harlaftis N. Inguinal endometriosis: three cases and literature review. *Southern Med J*. 2009;102(2):207–207.
4. Garg N, Bagul N, Doughan S, Rowe P. Intestinal endometriosis—a rare cause of colonic perforation. *World J Gastroenterol*. 2009;15(5):612–614.
5. Field C, Banner E, Symmonds R. Endometriosis of abdominal scar after cesarean section. *Proc Mayo Clinic*. 1962;37:12–15.
6. Chatterjee S. Scar endometriosis: a clinicopathologic study of 17 cases. *Obstet Gynecol*. 1980;56:81–84.
7. Poli-Neto O, Rosa-e-Silva J, Barbosa H, Candido-dos-Reis F, Nogueira A. Endometriosis of the soleus and gastrocnemius muscles: a case report. *Fertil Steril*. 2009;91(4):1294.e13–15. Epub 2009 Jan 18.
8. Kesterson J, Justice T, Terrassa M, Cook C. Abdominal wall endometrioma following cesarean delivery: a case report. *J Reprod Med*. 2008;53:881–882.
9. Matthes G, Zabel D, Nastala C, Shestak K. Endometrioma of the abdominal wall following combined abdominoplasty and hysterectomy: case report and review of the literature. *Ann Plast Surg*. 1998;40(6):672–675.
10. Farace F, Gallo A, Rubino C, Manca A, Campus G. Endometriosis in a trocar tract: is it really a rare condition? A case report. *Minerva Chir*. 2005;60(1):67–69.
11. Healy J, Wilkinson N, Sawyer M. Abdominal wall endometrioma in a laparoscopic trocar tract: a case report. *Am Surg*. 1995;61(11):962–963.
12. Patterson G, Winbum G. Abdominal wall endometriomas: report of eight cases. *Am Surg*. 1999;65(1):36–39.
13. Francica G. Sonographic features of abdominal wall endometrioma. *Am J Roentg*. 2006;187:W127.
14. Zhu Z, Al-Beiti A, Tang L, Liu X, Lu X. Clinical characteristic analysis of 32 patients with abdominal incision endometriosis. *J Obstet Gynaecol*. 2008;28(7):742–745.
15. Gunes M, Kayikcioglu F, Ozturkoglu E, Haberal A. Incisional endometriosis after cesarean section, episiotomy and other gynecologic procedures. *J Obstet Gynaecol Res*. 2005;31(5):471–475.
16. Agarwal A, Fong YF. Cutaneous endometriosis. *Singapore Med J*. 2008;49(9):704–709.
17. Horton J, DeZee K, Ahnfeldt E, Wagner M. Abdominal wall endometriosis: a surgeon's perspective and review of 445 cases. *Am J Surg*. 2008;196:207–212.
18. Sepilian V, Badia C. Iatrogenic endometriosis caused by uterine morcellation during a supracervical hysterectomy. *Obstet Gynecol*. 2003;102:1125–1127.