

# Hybrid treatment of a true thyrocervical trunk aneurysm in a patient with Type B aortic dissection

Nikolaos G. Baikoussis, Orestis Argiriou<sup>1</sup>, Michalis Argiriou, Aikaterini Psevdi<sup>2</sup>, Theodoros Kratimenos<sup>3</sup>, Panagiotis Dedeilias

Departments of Cardiovascular Surgery, <sup>2</sup>Anaesthesiology and <sup>3</sup>Interventional Radiology, Evaggelismos General Hospital, Athens, <sup>1</sup>Department of Surgery, Metaxa General Hospital, Piraeus, Greece

## ABSTRACT

We would like to describe a case with a complex aortic disease treated in hybrid fashion. We present an interesting case of a 65-year-old man with a medical history of hypertension, hyperlipidemia, and coronary artery disease percutaneously treated. An acute Type B aortic dissection occurred and treated with the implantation of a stent-graft which occluded the left subclavian artery due to its extension to the aortic arch. This event required a carotid-subclavian artery bypass due to ischemia of the left arm. An aneurysm in the innominate artery also detected, was treated with another stent-graft implantation 3 months later. At 5-year follow-up, an aneurysm of the thyrocervical trunk was found while the stent-graft of the aorta was well-tolerated without endoleak and the carotid-subclavian graft was patent. The aneurysm was asymptomatic but considering the risk of spontaneous rupture of an aneurysm of this size, elective surgery was indicated. Because the aneurysm was very close to the brachiocephalic bifurcation, open surgical repair would require a sternotomy. The right common carotid artery and right subclavian artery were exposed. The thyrocervical trunk, right internal mammary artery and right vertebral artery were occluded by ligations to isolate the aneurysm. An 8-mm Dacron graft was anastomosed end-to-end to the distal part of subclavian artery. We would like through this case, discuss the role of the hybrid cardiovascular surgery to minimize the postoperative complications in complex cardiovascular pathology. We also discuss the international bibliography about the thyrocervical trunk aneurysm and the treatment options.

**Key words:** Acute aortic syndrome; Aortic dissection; Cerebral artery perfusion; Hybrid aortic surgery; Hybrid cardiovascular surgery; Hypoplastic vertebral artery; Subclavian artery aneurysm; Thyrocervical trunk aneurysm; Type B aortic dissection

Received: 01-12-15

Accepted: 29-02-16

## INTRODUCTION

Hybrid cardiovascular surgery is a new way of treatment for some complex pathologies of the aorta to minimize the complications and the risk of death. Despite advances in surgical techniques, cerebral protection methods and postoperative management, the in-hospital mortality rate for patients undergoing conventional open surgical repair for Type B dissections is still high.<sup>[1]</sup> In the era of the minimally invasive surgery also, the hybrid and the endovascular approach are applied when possible. The less invasive surgical procedure for acute Type B aortic dissections, called thoracic endovascular aortic repair (TEVAR), was word-wide

developed. Usually, the entry point - tear of the intimal layer in Type B aortic dissection is located in the vicinity of the orifice of the left subclavian artery (LSA).<sup>[1]</sup> In some cases,

**Address for correspondence:** Dr. Nikolaos G. Baikoussis, Department of Cardiovascular Surgery, Evaggelismos General Hospital, Athens, Greece.  
E-mail: nikolaos.baikoussis@gmail.com

This is an open access article distributed under the terms of the Creative Commons Attribution-NonCommercial-ShareAlike 3.0 License, which allows others to remix, tweak, and build upon the work non-commercially, as long as the author is credited and the new creations are licensed under the identical terms.

**For reprints contact:** reprints@medknow.com

**Cite this article as:** Baikoussis NG, Argiriou O, Argiriou M, Psevdi A, Kratimenos T, Dedeilias P. Hybrid treatment of a true thyrocervical trunk aneurysm in a patient with Type B aortic dissection. *Ann Card Anaesth* 2016;19:363-6.

Access this article online

Website: [www.annals.in](http://www.annals.in)

DOI:  
10.4103/0971-9784.179621

Quick Response Code:



during the endovascular treatment of the Type B aortic dissection, the LSA must be occluded to secure as better as we can the proximal landing zone.<sup>[1-3]</sup> The proximal landing zone in the aortic arch must be secured as long as the aim of TEVAR for Type B dissection is primary entry closure. This may require hybrid procedure to vascularize the aortic arch branches. Usually, if LSA occlusion occurred, a left carotid artery-LSA bypass is enough for complete aortic arch revascularization. This requires hybrid surgery that includes the use of open surgical procedures, such as debranching for revascularization of cervical branches and the endovascular stent graft implantation through the right femoral artery. In this article, we describe the current status of this procedure for Type B aortic dissections-in particular, debranching TEVAR for cases that need to extend to the aortic arch. In our case, an aneurysm of the innominate artery occurred, treated with a second stent graft implantation and then, 8 years later, a true thyrocervical trunk aneurysm detected at follow-up, treated successfully with open surgical intervention. True subclavian artery aneurysms are rare comparatively with other peripheral aneurysms but is potentially life-threatening because of the risk of rupture, distal embolization and thrombosis.<sup>[4,5]</sup> We present this interesting case and the open surgery procedure for the treatment of the thyrocervical aneurysm.

## CASE REPORT

We present in this paper an interesting case of a 65-year-old man with a medical history of hypertension, hyperlipidemia, and coronary artery disease percutaneously treated. An acute Type B aortic dissection occurred and it has been treated with the implantation of a stent-graft which occluded the LSA. This event required a carotid-subclavian bypass due to ischemia of the left arm [Figure 1]. The procedure above

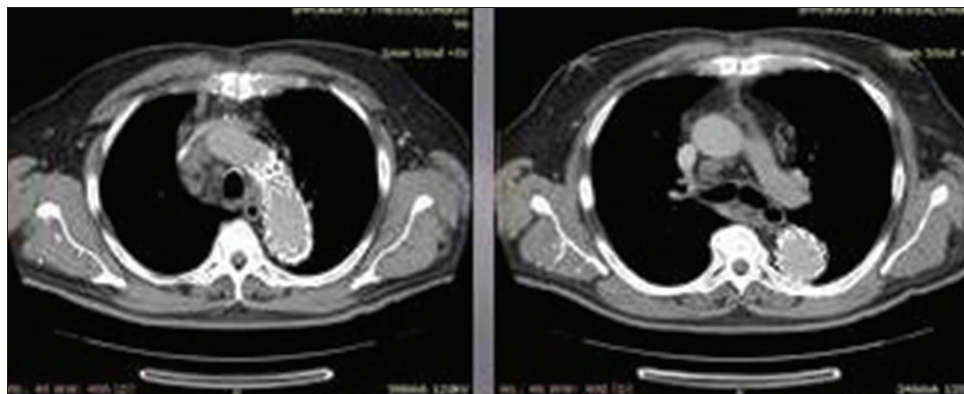
described was carried out under local anesthesia and in the supine position. The aneurysm found also in the innominate artery was treated with another stent-graft implantation 3 months later [Figure 2].

At 5-year follow-up, the stent-graft implanted into the descending aorta was well inserted without any endoleak. The carotid-subclavian graft was found also patent, but an aneurysm of the thyrocervical trunk of the diameter of 44 mm was identified. Initially, this finding was called aneurysm of the innominate artery but after sternotomy and preparation it was found that is an aneurysm of the thyrocervical trunk [Figure 3].

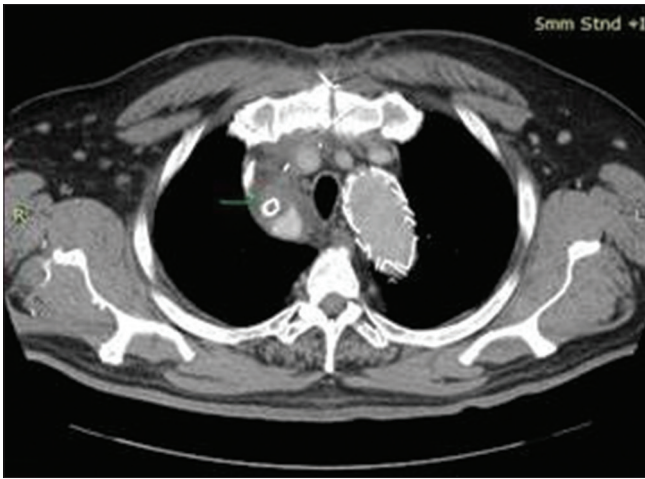
Open surgical repair is the standard way of treatment of subclavian artery aneurysms, but when located in the intrathoracic segment, it necessitates surgical treatment with sternotomy or lateral thoracotomy. The aneurysm was asymptomatic but considering the risk of spontaneous rupture of an aneurysm of this size, elective surgery was indicated. Because the aneurysm was very close to the brachiocephalic bifurcation, open surgical repair would require a sternotomy. The right common carotid artery and right subclavian artery were exposed. The thyrocervical trunk, right internal mammary artery and right vertebral artery were occluded due to the aneurysm. An 8-mm Dacron graft was anastomosed end-to-end to the distal part of the subclavian artery. The postoperative period was uneventful and at follow-up, patient was in optimal clinical status.

## DISCUSSION

In general, aortic dissections are categorized as acute (the period within 14 days of onset) and chronic (the period more than 14 days after onset).<sup>[1]</sup> Symptomatic cases (e.g., rupture, malperfusion, continuous pain, and refractory hypertension) are classified as complicated,



**Figure 1:** Computed tomography scan images showing the previously implanted stent graft (thoracic endovascular aortic repair) due to Type B thoracic aorta dissection with perfect dissolving thoracic aorta remodeling in current time

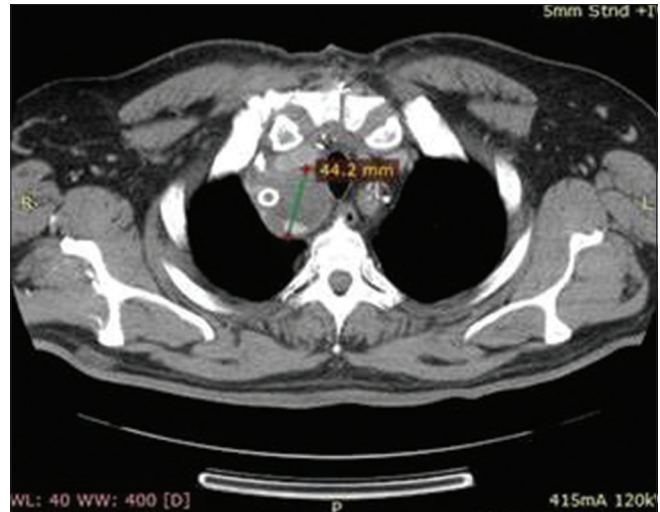

**Figure 2:** Computed tomography scan images showing previously implanted cover stent due to preexisting aneurysm of innominate artery

whereas those patients without such conditions are defined as uncomplicated.<sup>[1,2]</sup> The endovascular approach for Type B aortic dissections is to cover the entry tear and provide favorable aortic remodeling, thereby preventing early and late complications.<sup>[1-3,6,7]</sup> Given that the aim of TEVAR for Type B dissections is primary entry closure, the proximal landing zone in the aortic arch must be secured.<sup>[1,3]</sup> This requires hybrid surgery that involves the joint use of a surgical procedure; in particular, it requires debranching TEVAR that does not use extracorporeal circulation and involves reconstruction of cervical branches.<sup>[8,9]</sup> Becker *et al.*, in 1991 reported the first endovascular treatment of an accidental subclavian artery injury caused by cannulation of the subclavian vein.<sup>[10]</sup> Many authors have described modalities of interventional treatment for injured subclavian artery<sup>[11]</sup> or for subclavian artery pseudoaneurysm reconstruction.<sup>[12]</sup> In the era of minimally invasive and endovascular many reports are published in the international bibliography which describe the hybrid approach of such complex cardiovascular abnormalities.<sup>[13]</sup>

## CONCLUSION

To avoid an aortic arch and descending aorta replacement with cardiopulmonary bypass, total circulatory arrest, and deep hypothermia, the patient was offered a less invasive hybrid endovascular procedure. Despite these complex diseases, the patient was treated successfully, and this fact determines the utility of the endovascular and the hybrid cardiovascular surgery. This approach represents a valuable alternative and may help reduce



**Figure 3:** Computed tomography scan images demonstrating a new aneurysm of 4.4 cm max diameter beside the cover stent at the innominate artery

complications and mortality in comparison with conventional open surgery.

## Financial support and sponsorship

Nil.

## Conflicts of interest

There are no conflicts of interest.

## REFERENCES

1. Kuratani T. Best surgical option for arch extension of type B dissection: The endovascular approach. *Ann Cardiothorac Surg* 2014;3:292-9.
2. Trimarchi S, Nienaber CA, Rampoldi V, Myrmet T, Suzuki T, Bossone E, *et al.* Role and results of surgery in acute type B aortic dissection: Insights from the International registry of acute aortic dissection (IRAD). *Circulation* 2006;114 1 Suppl: I357-64.
3. Nienaber CA, Rousseau H, Eggebrecht H, Kische S, Fattori R, Rehders TC, *et al.* Randomized comparison of strategies for type B aortic dissection: The Investigation of STEnt grafts in aortic dissection (INSTEAD) trial. *Circulation* 2009;120:2519-28.
4. Takach TJ, Lalka SG. Innominate artery aneurysm: Axial reconstruction via a cervical approach. *J Vasc Surg* 2007;46:1267-9.
5. Ito H, Kurazumi H, Sakata K, Koabayashi Y. Successful surgical treatment of right subclavian artery aneurysm with a hypoplastic left vertebral artery using temporary cerebral perfusion to prevent cerebral ischemia. *Ann Vasc Dis* 2011;4:60-3.
6. Apostolakis E, Papakonstantinou NA, Baikoussis NG, Petrou A, Goudevenos J. Imaging of acute aortic syndrome: Advantages, dis-advantages and pitfalls. *Hellenic J Cardiol* 2015;56:169-80.
7. Apostolakis E, Baikoussis NG, Georgiopoulos M. Acute

- type-B aortic dissection: The treatment strategy. *Hellenic J Cardiol* 2010;51:338-47.
8. Erbel R, Aboyans V, Boileau C, Bossone E, Bartolomeo RD, Eggebrecht H, *et al.* 2014 ESC Guidelines on the diagnosis and treatment of aortic diseases: Document covering acute and chronic aortic diseases of the thoracic and abdominal aorta of the adult. The Task Force for the Diagnosis and Treatment of Aortic Diseases of the European society of cardiology (ESC). *Eur Heart J* 2014;35:2873-926.
  9. Ren C, Guo X, Sun L, Huang L, Lai Y, Xu S. One-stage hybrid procedure without sternotomy for treating thoracic aortic pathologies that involve distal aortic arch: A single-center preliminary study. *J Thorac Dis* 2015;7:861-7.
  10. Becker GJ, Benenati JF, Zemel G, Sallee DS, Suarez CA, Roeren TK, *et al.* Percutaneous placement of a balloon-expandable intraluminal graft for life-threatening subclavian arterial hemorrhage. *J Vasc Interv Radiol* 1991;2:225-9.
  11. Baikoussis NG, Siminelakis SN, Matsagas M, Michalis LK. Massive haemothorax due to subclavian artery rupture: Emergency thoracotomy or primary stent-grafting? *Heart Lung Circ* 2010;19:431.
  12. Xu GF, Suh DC, Pyun HW, Yoo H, Lee SW, Huh MO, *et al.* Covered stent application of a repeatedly regrowing iatrogenic subclavian artery pseudoaneurysm at the origin of the vertebral artery. *Interv Neuroradiol* 2007;13:185-9.
  13. Van Leemput A, Maleux G, Heye S, Nevelsteen A. Combined open and endovascular repair of a true right subclavian artery aneurysm without proximal neck. *Interact Cardiovasc Thorac Surg* 2007;6:406-8.