

ORIGINAL ARTICLE

Hypotrichosis with juvenile macular dystrophy: Combination of whole-genome sequencing and genome-wide homozygosity mapping identifies a large deletion in *CDH3* initially undetected by whole-exome sequencing—A lesson from next-generation sequencing

Amir Hossein Saeidian^{1,2*}  | Hassan Vahidnezhad^{1,3*}  | Leila Youssefian^{1,2,4*}  | Soheila Sotudeh⁵ | Meisam Sargazi⁶ | Sirous Zeinali^{3,7} | Jouni Uitto¹ 

¹Department of Dermatology and Cutaneous Biology, and Jefferson Institute of Molecular Medicine, Thomas Jefferson University, Philadelphia, PA, USA

²Genetics, Genomics and Cancer Biology Ph.D. Program, Thomas Jefferson University, Philadelphia, PA, USA

³Biotechnology Research Center, Department of Molecular Medicine, Pasteur Institute of Iran, Tehran, Iran

⁴Department of Medical Genetics, School of Medicine, Tehran University of Medical Sciences, Tehran, Iran

⁵Department of Dermatology, Children's Medical Center, Pediatric Center of Excellence, Tehran University of Medical Sciences, Tehran, Iran

⁶Alzahra Eye Hospital Research Center, Zahedan University of Medical Sciences, Zahedan, Iran

⁷Kawsar Human Genetics Research Center, Tehran, Iran

Correspondence

Jouni Uitto, Department of Dermatology and Cutaneous Biology, Sidney Kimmel Medical College at Thomas Jefferson University, 233 S. 10th Street, Suite 450 BLSB, Philadelphia, PA 19107, USA.
Email: Jouni.Uitto@jefferson.edu

Abstract

Background: Hypotrichosis with juvenile macular dystrophy (HJMD) is an autosomal recessive disorder characterized by abnormal growth of scalp hair and juvenile macular degeneration leading to blindness. We have explored the genetic basis of HJMD in a large consanguineous family with 12 affected patients, 1–76 years of age, with characteristic phenotypes.

Methods: We first applied genome-wide homozygosity mapping to 10 affected individuals for linkage analysis to identify the genomic region of the defective gene. All affected individuals shared a 7.2 Mb region of homozygosity on chromosome 16q21–22.3, which harbored 298 genes, including *CDH3*, previously associated with HJMD. However, whole-exome sequencing (WES) failed to identify the causative mutation in *CDH3*.

Results: Further investigation revealed a missense variant in a gene closely linked to *CDH3* (1.4 Mb distance: *FHOD1*: c.1306A>G, p.Arg436Gly). This variant was homozygous in all affected individuals and heterozygous in 18 out of 19 obligate carriers. While this variant was found by bioinformatics predictions to be likely pathogenic,

Abbreviations: HJMD, Hypotrichosis Juvenile Macular Dystrophy; HM, Homozygosity Mapping; SNV, Single Nucleotide Variant; WES, Whole-Exome Sequencing; WGS, Whole-Genome Sequencing.

*These authors contributed equally to this study.

This is an open access article under the terms of the Creative Commons Attribution-NonCommercial License, which permits use, distribution and reproduction in any medium, provided the original work is properly cited and is not used for commercial purposes.

© 2019 The Authors. *Molecular Genetics & Genomic Medicine* published by Wiley Periodicals, Inc.

a knock-in mouse for this variant, made by the CRISPR/Cas, showed no disease phenotype. However, using whole-genome sequencing (WGS), we were able to identify a novel *Alu* recombination-mediated deletion in *CDH3*:c.del161-811_246 + 1,044.

Conclusion: WGS was able to identify a deep intronic deletion mutation, not detected by WES.

KEYWORDS

Alu-mediated deletion mutation, hypotrichosis with juvenile macular dystrophy, next-generation sequencing

1 | INTRODUCTION

Hypotrichosis with juvenile macular dystrophy (HJMD; OMIM#601553) is a rare autosomal recessive disorder characterized by early hair loss associated with late-onset progressive macular degeneration leading in most patients to blindness (Indelman et al., 2002). Histopathology of the scalp skin of patients is largely unrevealing, but light and scanning electron microscopy have revealed a spectrum of hair shaft abnormalities, including pseudomonilethrix, pili torti, longitudinal ridging, as well as scaling and shedding of the hair shaft. While the hair loss is particularly severe during the early years of life, there is evidence of re-growth during puberty. The eye findings consist of reduced visual acuity and corneal dystrophy. The molecular basis of HJMD has been shown to reside in the *CDH3* gene, encoding P-cadherin, which is expressed in the retinal pigment epithelium and hair follicles (Basel-Vanagaite, Pasmanik-Chor, Lurie, Yeheskel, & Kjaer, 2010).

We have examined a large consanguineous family of Iranian ancestry with a total of 12 affected individuals with HJMD. The diagnosis was confirmed by hair phenotype and by eye examination, which established macular degeneration and late-onset loss of visual acuity. Initial attempts to identify mutations in the *CDH3* gene by whole-exome sequencing (WES) failed, but subsequent analysis by homozygosity mapping (HM) and whole-genome sequencing (WGS) identified a large, previously unreported genomic deletion, eliminating 1.8 kb of the genome containing exon 3 and flanking intronic sequences of *CDH3*.

2 | RESULTS

2.1 | Clinical diagnostics

A large Iranian family of Azeri ethnicity was diagnosed with diffuse hair loss and late-onset diminution of visual acuity, characteristics of HJMD. Extensive consanguinity was evident in this family (Figure 1a,b). The hair loss had

been noted as early as at birth but was highly variable in the severity. In some cases, hair growth was fairly normal at 17 years of age, while in some patients essentially all hair was lost by the age of 13. Scanning electron microscopy of the hair shaft demonstrated areas of longitudinal grooves, local shedding, and absence of the cuticle (Figure 1c). The ocular findings were characterized by visual acuity in the range of 20 out of 20 to 20 out of 400. Few of the patients had a history of nyctalopia. Anterior segment evaluation consisting of clinical examination with slit lamp bio-microscope and paraclinical corneal study, such as Scheimpflug imaging and corneal topography, was normal in all patients. Fundus examination revealed features of macular dystrophy including symmetrical areas of the retinal pigment epithelium (RPE) hypopigmentation extending from the optic disks to the temporal macula. There were small hyperpigmented RPE clumps centered on each fovea. In older patients, visual acuity had declined to 20 out of 400 and worse. There was clinical evidence of advanced macular atrophy, subretinal scarring, and pigment clumping involving the juxtafoveal zones in both eyes (Figure 1b, upper right panel). Thus, this family was diagnosed with HJMD with an unusually large number of affected individuals.

2.2 | Mutation analysis

Since families with HJMD have been previously shown to harbor mutations in the *CDH3* gene, which resides on chromosomal region 16q22.1, we first performed autosomal-wide homozygosity mapping (HM) with DNA by a single nucleotide polymorphism array from 10 affected individuals available for study to confirm the genomic location of the mutant gene (Vahidnezhad, Youssefian, Jazayeri, & Uitto, 2018). HM identified a number of genomic regions of homozygosity (ROH), but specifically, a 7.2 Mb DNA segment on chromosomal region 16q21-22.3 was shared by all 10 affected individuals (Figure 2a). This region, which harbored 298 distinct genes, included *CDH3*, giving us confidence of *CDH3* as the candidate gene of the

mutation(s) in this family. All 298 genes within the shared 7.2 Mb ROH were interrogated manually and *CDH3* was the only relevant candidate gene. However, subsequent analysis of DNA from three affected individuals by WES failed to identify a causative mutation in *CDH3*. Bioinformatics analysis of the WES data revealed, however, a missense variant in a closely linked gene (1.4 Mb distance), *FHOD1*: c.1306A>G, p.Arg436Gly. This variant was homozygous in all affected individuals and was found to be heterozygous in 18 out of the 19 obligate carriers. Bioinformatics predictions by ANNOVAR (Wang, Li, & Hakonarson, 2010) suggested this missense mutation to be pathogenic with a CADD score (Rentzsch, Witten, Cooper, Shendure, & Kircher, 2019) of 23.7 (for details of the methods, see Youssefian et al., 2019). This variant was also predicted

by MutationTaster as a disease-causing variant. In attempts to confirm the pathogenicity of this *FHOD1* mutation, a knock-in mouse for this variant was made by the CRISPR/Cas9 technique at The Jackson Laboratory (Bar Harbor, Maine). However, careful examination of the mice up to several months of age, followed by complete necropsies, including histopathologic analysis of the skin, hair, and eyes, did not reveal any evidence of a disease phenotype (J. P. Sundberg, personal communication).

In further attempts to pursue the pathogenicity of the *CDH3* gene whole-genome sequencing of DNA from the proband was performed, which identified a large deletion in *CDH3*: c.del161-811_246 + 1,044 (Figure 2b). This mutation deletes exon 3, which consists of 86 bp, predicting out of frame deletion of amino acids in the extracellular domain

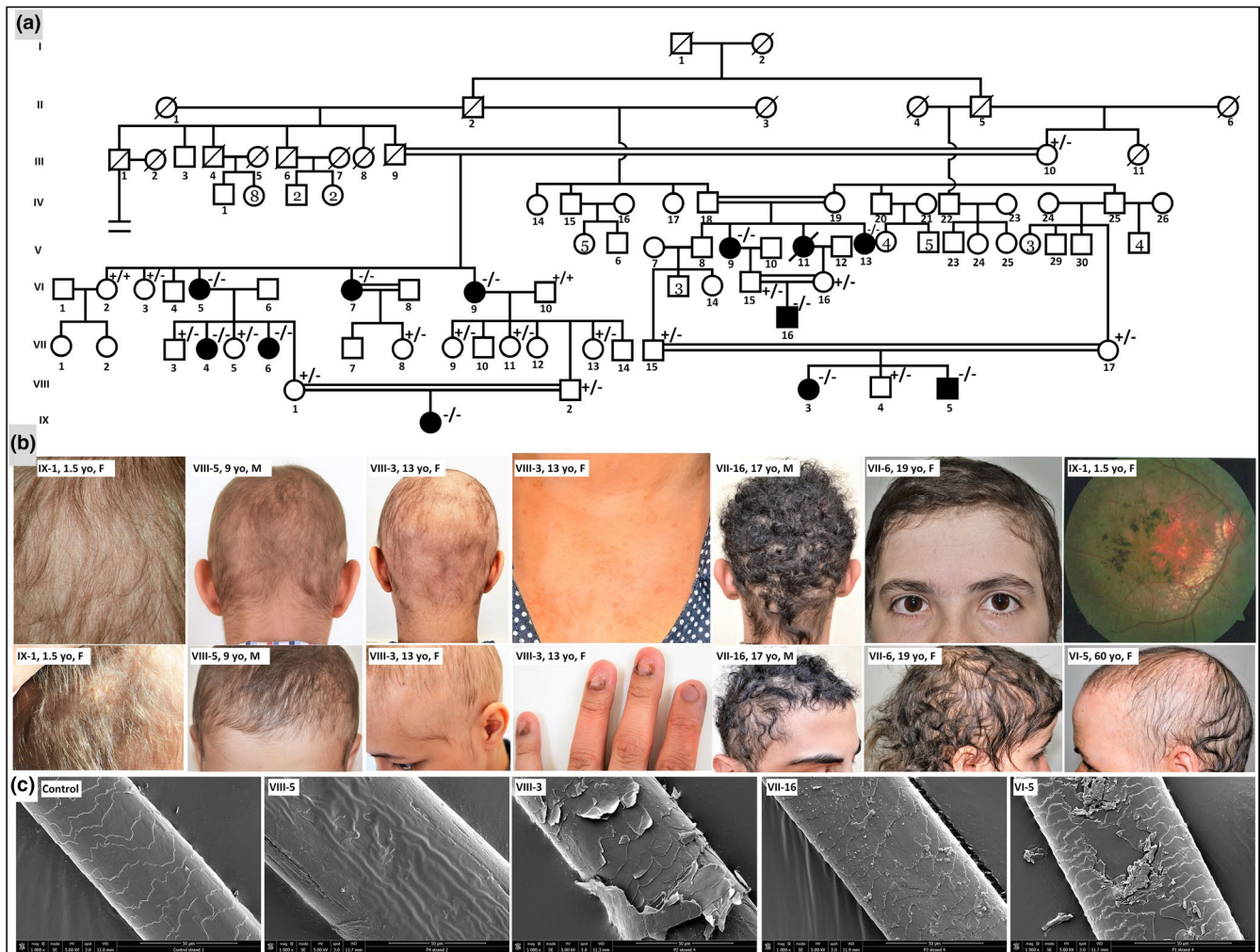


FIGURE 1 Inheritance and clinical features in a large family with hypotrichosis with juvenile macular dystrophy. (a) Note the extensive consanguinity in this multiplex family with 12 affected individuals. (b) Note the presence of hypotrichosis of varying degrees in individuals of different ages. In addition to hair loss, the patients demonstrate loss of visual acuity due to juvenile macular dystrophy with characteristics of ophthalmologic findings (upper right panel). Some patients demonstrated variably eczematous dermatitis and nail dystrophy (VII-3, middle panels). (c) Scanning electron microscopy of the hair shaft revealed longitudinal grooving, peeling and loss of cuticle, as compared to control hair (left panel)

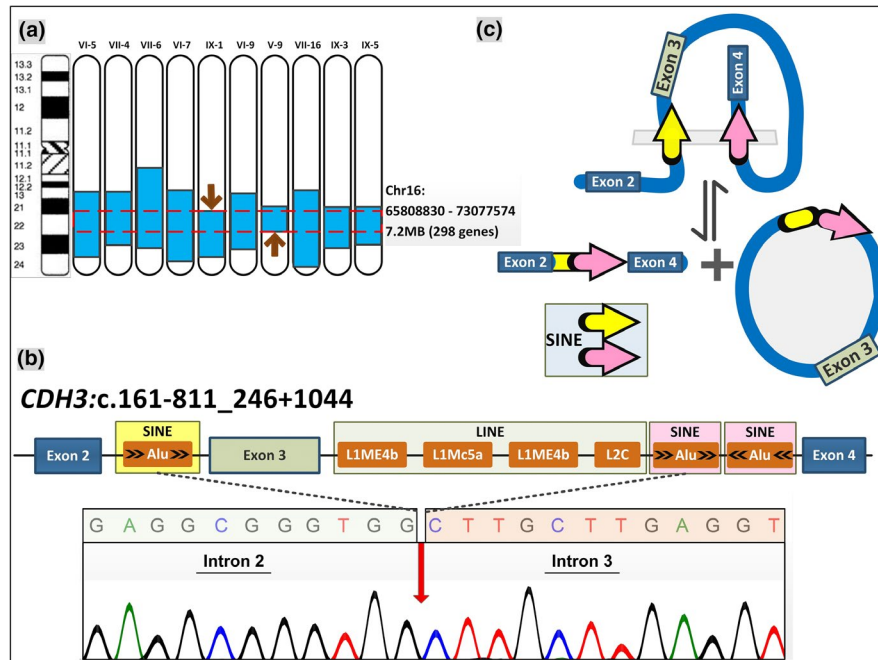


FIGURE 2 Identification of homozygous *Alu*-mediated deletion of exon 3 in the *CDH3* gene, encoding cadherin 3. (a) Genome-wide, single-nucleotide polymorphism–based homozygosity mapping in DNA from 10 affected individuals on the long arm of chromosome 16. The critical overlapping interval in all patients consisted of 7.2 Mb harboring 298 distinct genes (arrows). (b) Whole-genome sequencing identified a large deletion within *CDH3*, and Sanger sequencing revealed the absence of the entire exon 3 consisting of 86 bp. Sequencing of the intronic sequences at the breakpoints revealed multiple repeat sequences, and the breakpoints within intron 2 and intron 3 were shown to reside within *Alu* sequences. (c) It can be postulated that deletion of exon 3 is mediated by SINE *Alu* sequences within introns 2 and 3

of P-cadherin within the cadherin prodomain-like segment and presumably leading to nonsense-mediated mRNA decay. The segregation of this mutation in the affected individuals in this family was confirmed by Sanger sequencing (Figure 1a).

Examination of the genomic sequences surrounding the exon 3 which was deleted in the patients' DNA, revealed a number of repeat sequences, including *Alu* repeats within introns 2 and 3 (Figure 3b). Examination of the breakpoints by PCR demonstrated borders of the deletion within *Alu* repeats, suggesting that the genomic deletion was mediated by *Alu* recombination (Figure 2c). Thus, this report highlights the inability of WES to call a deletion of an entire exon(s) in *CDH3*, and it further demonstrates the utility of HM and WGS in identification of mutations initially missed by WES.

3 | DISCUSSION

Hypotrichosis with juvenile macular dystrophy is a rare congenital disease mainly found in the Druze population of Northern Israel and close by Mediterranean areas (Elfatoiki, Cordoliani, Pascal Regane, & Afforrit-Demoge, 2016). We report here, to our knowledge for the first time, an intragenic *Alu*-mediated deletion causing HJMD that results in the homozygous loss of the entire exon 3 in *CDH3*. The resultant transcript has exon 2 spliced directly to exon 4, and as it is out

of frame, potentially leading to nonsense-mediated mRNA decay as a result of the *CDH3* mutation.

Since the initial identification of a pathogenic *CDH3* mutation in several consanguineous and nonconsanguineous families, a total of 19 distinct mutations (Bergman, Sapir, & Sprecher, 2004; Indelman et al., 2002, 2003, 2007; Indelman, Leib, Jammal, Bergman, & Sprecher, 2005; Jelani, Salman Chishti, & Ahmad, 2009; Kamran-ul-Hassan Naqvi, Azeem, Ali, & Ahmad, 2010; Kjaer et al., 2005; Leib et al., 2006; Mason & Patel, 2015; Sprecher et al., 2001) (including missense, nonsense, and frameshifts) in 28 separate families of various ethnic origins have been reported to cause HJMD. We compared dermatologic characteristics of our extended family (e.g. hair morphology, nail, and skin findings) as well as ophthalmologic features (e.g. age of onset of visual disability and loss of visual acuity) with the previously reported cases (Table 1). No systematic correlation could be established between phenotypic characteristics and the type (missense vs. nonsense and/or frameshift) or location of the *CDH3* mutations among our current family and 19 previously reported mutations (Table 1). Phenotypic heterogeneity and absence of genotype-phenotype correlations were not only observed across various mutations and corresponding phenotypes but also intrafamilial phenotypic heterogeneity observed in our family. Most notably, we observed nail dystrophy and different severity of alopecia. In one family member (VIII-3) we

TABLE 1 Literature review of clinical characteristics and mutations identified in the *CDH3* gene in patients with HJMD

Reference	Origin of patients	Visual acuity (OD/OS)	Scalp hypotrichosis	Macular pigment degeneration	Additional clinical findings	<i>CDH3</i> mutations
Sprecher et al. (2001)	Israeli	N/A	+	+	N/A	c.981del (p.M327fs)
Indelman et al. (2002)	Israeli	N/A	+	+	N/A	c.1508G>A (p.R503H)
Indelman et al. (2003)	French	N/A	+	+	Atopic dermatitis	c.503T>A (p.L168X) c.2112del (p.G706fs)
Indelman et al. (2003)	Turkish	N/A	+	+	Keratosis pilaris	c.829del (p.G277fs)
Indelman et al. (2003)	Israeli	N/A	+	+	Centrofacial lentiginosis	c.1508G>A (p.R503H)
Indelman et al. (2003)	Israeli	N/A	+	+	N/A	c.462del (p.E155fs)
Indelman et al. (2005)	Arab	OD:20/28, OS: 20/33	+	+	N/A	c.1845T>G (p.Y615X)
Indelman et al. (2007)	English	OD: 6/36, OS: 6/5	+	+	Limb abnormalities	c. IVS2+1G>A c.1510G>A (p.E504K)
Indelman et al. (2007)	American	N/A	+	+	Discolored primary teeth, nail dystrophy	c.661C>T (p.R221X) c.1724A>G (p.H575R)
Bergman et al. (2004)	Arab-Israeli	N/A	+	N/A	Centrofacial lentiginosis	c.1508G>A (p.R503H)
Leibu et al. (2006)	Israeli	N/A	+	+	N/A	c.981del (p.M327fs)
Bergman et al. (2004)	Israeli	N/A	+	+	N/A	c.1508G>A (p.R503H)
Jelani et al. (2009)	Pakistani	N/A	+	+	N/A	c.IVS10–1G>T
Kamran-ul-Hassan Naqvi et al. (2010)	Pakistani	N/A	+	+	N/A	c.IVS10–1G>A
Shimomura, Wajid, Kurban, and Christiano (2010)	Pakistani	N/A	+	N/A	N/A	c.IVS12–2A>G
Shimomura et al., (2010)	Pakistani	N/A	+	N/A	N/A	c.IVS10–1G>T
Avitan-Hersh, Indelman, Khamaysi, Leibu, and Bergman (2012)	Arab	N/A	+	+	N/A	c.747C>A (p.Y249X)
Halford, Holt, Nemeth, and Downes (2012)	N/A	OD: 6/760, OS: 6/96	+	+	N/A	Deletion of 8,815 bp including exons 12–13
Khan and Bolz (2016)	Arab	OD: 20/60, OS: 20/60	+	+	Slow nail growth	c.307C>T (p.R103X)
Khan and Bolz (2016)	Arab	OD: 3/200, OS: 3/200	+	+	N/A	c.307C>T (p.R103X)
Karti et al. (2017)	Turkish	OD: 0.9, OS: 0.1	+	+	–	c.447_467del (p.149_156del)
Blanco-Kelly et al. (2017)	Spanish	OD: 0.08, OS: 0.1	+	+	N/A	c.613G>A (p.V205M) c.830del (p.G277AfsX20)
Blanco-Kelly et al. (2017)	Portuguese	OU:5/10	+	+	N/A	c.830delG (p.G277AfsX20)
Almeida, Carneiro-Freitas, Caldas, and Vieira (2018)	Iranian	OU:20/40	+	+	Mild eczema	c.640A>T (p.K214X)
Nasser et al. (2019)	Syrian	OD: 20/100, OS: 20/50	+	+	Hypoplastic nails	c.1508G>A (p.R503H)
Ghafouri-Fard, Fardael, Bagher Tabei, Dianatpour, and Miryounesi (2018)	Iranian	N/A	+	+	N/A	c.830delG (p.G277AfsX20)
This study	Iranian	20/20 to 20/400	+	+	Hypoplastic nails	c.del161–811_246 + 1,044

Abbreviations: OD, Oculus Dexter = Right eye; OS, Oculus Sinister = Left eye; OU, Oculus Uterque = Both eyes.

also observed skin rashes, severe alopecia, and nail dystrophy, whereas other patients, such as the brother of this patient (VIII-5) had alopecia and no other findings. Wide variations in age at onset and degree of visual disability were observed among the 10 patients in this family. Although the number of reported patients is small, no correlation could be established between the type of hair abnormality and the degree of macular damage and skin findings.

We performed single-nucleotide polymorphism genotyping on 10 members from the extended family to map the regions of homozygosity shared by all patients. There was only one homozygous region in Chr16:65808830–73077574, shared among all affected individuals and absent in carriers, which contains 298 genes including *CDH3*. WES failed to identify pathogenic variants in *CDH3*. Therefore, WGS on *CDH3* gene was performed, and a 1.8-Mb homozygous region was deleted in the *CDH3* gene and segregated in all affected individuals. Analysis of the sequences spanning the deletion breakpoints to detect possible repetitive elements was conducted by the Repeat Masker program. A number of repetitive elements, including Short Interspersed Nuclear Elements (SINE) and Long Interspersed Nuclear Elements (LINE), including *Alu* repeats were identified, suggesting that the deletion mechanism is *Alu*-mediated. Specifically, a recombination event between two highly homologous *Alu* repeats within introns 2 and 3 is likely responsible for the occurrence of the deletion, and the site of the crossover events is shown in Figure 2.

Distinguishing disease-causing mutations in individuals affected with the recessive disease can provide a molecular diagnosis that not only ends an often long diagnostic odyssey (Luzi, Rafi, & Wenger, 1995) but can also enable therapeutic options. CNVs encompassing recessive disease genes have been described as disease-causing mutations for several conditions, and are occasionally among the most common causative mutations for specific diseases (Lupski et al., 2010; Rafi, Luzi, Chen, & Wenger, 1995; Vahidnezhad, Youssefian, Saeidian, et al., 2018).

With the availability of state-of-the-art and relatively cheap and accurate technologies, such as HM, WES, and WGS, performing an accurate diagnosis is essential not only for prenatal diagnosis but also for available cell and gene therapy. Patients with HJMD could be a good candidates for gene therapy since there are several clinical trials going on for patients with retinal dystrophies. Therefore, phenotypic and genotypic characteristics are to be considered when selecting patients for future treatment.

4 | CONCLUSIONS

In summary, this extended Iranian family of Azeri ethnicity confirms a *CDH3* mutation as the cause of HJMD and demonstrates genetic homogeneity as well as phenotypic

heterogeneity in this disorder. Further studies including more patients are required to determine for possible genotype-phenotype correlations regarding the different clinical features related to *CDH3* mutations in HJMD. Also, for such a rare condition, it is difficult to predict the overall incidence of the disease and additional cases could be helpful toward such goal.

ACKNOWLEDGMENTS

We thank the patients and their families for participation. Carol Kelly assisted in manuscript preparation. Dr. John P. Sundberg, The Jackson Laboratory, generated the *Fhodi* knock-in mouse.


CONFLICT OF INTEREST

The authors state no conflict of interest.

DATA AVAILABILITY STATEMENT

The data that support the findings of this study are available from the corresponding author upon reasonable request.

ORCID

Amir Hossein Saeidian  <https://orcid.org/0000-0003-3512-0654>

Hassan Vahidnezhad  <https://orcid.org/0000-0003-4298-9147>

Leila Youssefian  <https://orcid.org/0000-0002-4253-6503>

Jouni Uitto  <https://orcid.org/0000-0003-4639-807X>

REFERENCES

- Almeida, F. T., Carneiro-Freitas, R., Caldas, R., & Vieira, A. P. (2018). Hypotrichosis with juvenile macular dystrophy. *International Journal of Trichology*, 10(5), 234–236. https://doi.org/10.4103/ijt.ijt_60_18
- Avitan-Hersh, E., Indelman, M., Khamaysi, Z., Leib, R., & Bergman, R. (2012). A novel nonsense *CDH3* mutation in hypotrichosis with juvenile macular dystrophy. *International Journal of Dermatology*, 51(3), 325–327. <https://doi.org/10.1111/j.1365-4632.2011.04973.x>
- Basel-Vanagaite, L., Pasmanik-Chor, M., Lurie, R., Yeheskel, A., & Kjaer, K. W. (2010). *CDH3*-related syndromes: Report on a new mutation and overview of the genotype-phenotype correlations. *Molecular Syndromology*, 1(5), 223–230. <https://doi.org/10.1159/000327156>
- Bergman, R., Sapir, M., & Sprecher, E. (2004). Histopathology of hypotrichosis with juvenile macular dystrophy. *American Journal of Dermatopathology*, 26(3), 205–209. <https://doi.org/10.1097/00000372-200406000-00006>

- Blanco-Kelly, F., Rodrigues-Jacy da Silva, L., Sanchez-Navarro, I., Riveiro-Alvarez, R., Lopez-Martinez, M. A., Corton, M., & Ayuso, C. (2017). New CDH3 mutation in the first Spanish case of hypotrichosis with juvenile macular dystrophy, a case report. *BMC Medical Genetics*, *18*(1), 1. <https://doi.org/10.1186/s12881-016-0364-5>
- Elfatoiki, F. Z., Cordoliani, F., Pascal Regane, P., & Afforitit-Demoge, A. (2016). Hypotrichosis with juvenile macular dystrophy: Portuguese case. *Dermatology Online Journal*, *22*(5):15.
- Ghafouri-Fard, S., Fardael, M., Bagher Tabei, S. M., Dianatpour, M., & Miryounesi, M. (2018). A CDH3 mutation is segregated in an Iranian family with congenital hypotrichosis and juvenile macular dystrophy. *International Journal of Pediatrics*, *6*(1), 6999–7002.
- Halford, S., Holt, R., Nemeth, A. H., & Downes, S. M. (2012). Homozygous deletion in CDH3 and hypotrichosis with juvenile macular dystrophy. *Archives of Ophthalmology*, *130*(11), 1490–1492. <https://doi.org/10.1001/archophthol.2012.708>
- Indelman, M., Bergman, R., Petronius, D., Ciubutaro, D., Sprecher, E., Lurie, R., ... Leib, R. (2002). A missense mutation in CDH3, encoding P-cadherin, causes hypotrichosis with juvenile macular dystrophy. *The Journal of Investigative Dermatology*, *119*(5), 1210–1213. <https://doi.org/10.1046/j.1523-1747.2002.19528.x>
- Indelman, M., Bergman, R., Ramon, M., Sprecher, E., Hamel, C. P., Nischal, K. K., ... Russell-Eggitt, I. (2003). Phenotypic diversity and mutation spectrum in hypotrichosis with juvenile macular dystrophy. *The Journal of Investigative Dermatology*, *121*(5), 1217–1220. https://doi.org/10.1046/j.1523-1747.2003.12550_1.x
- Indelman, M., Eason, J., Hummel, M., Loza, O., Suri, M., Leys, M. J., ... Sprecher, E. (2007). Novel CDH3 mutations in hypotrichosis with juvenile macular dystrophy. *Clinical and Experimental Dermatology*, *32*(2), 191–196. <https://doi.org/10.1111/j.1365-2230.2006.02335.x>
- Indelman, M., Leib, R., Jammal, A., Bergman, R., & Sprecher, E. (2005). Molecular basis of hypotrichosis with juvenile macular dystrophy in two siblings. *British Journal of Dermatology*, *153*(3), 635–638. <https://doi.org/10.1111/j.1365-2133.2005.06734.x>
- Jelani, M., Salman Chishti, M., & Ahmad, W. (2009). A novel splice-site mutation in the CDH3 gene in hypotrichosis with juvenile macular dystrophy. *Clinical and Experimental Dermatology*, *34*(1), 68–73. <https://doi.org/10.1111/j.1365-2230.2008.02933.x>
- Kamran-ul-Hassan Naqvi, S., Azeem, Z., Ali, G., & Ahmad, W. (2010). A novel splice-acceptor site mutation in CDH3 gene in a consanguineous family exhibiting hypotrichosis with juvenile macular dystrophy. *Archives of Dermatological Research*, *302*(9), 701–703. <https://doi.org/10.1007/s00403-010-1035-6>
- Karti, O., Abali, S., Ayhan, Z., Gokmeydan, E., Nalcaci, S., Yaman, A., & Saatci, A. O. (2017). CDH3 gene related hypotrichosis and juvenile macular dystrophy - A case with a novel mutation. *American Journal of Ophthalmology Case Reports*, *7*, 129–133. <https://doi.org/10.1016/j.ajoc.2017.06.007>
- Khan, A. O., & Bolz, H. J. (2016). Phenotypic observations in "hypotrichosis with juvenile macular dystrophy" (recessive CDH3 mutations). *Ophthalmic Genetics*, *37*(3), 301–306. <https://doi.org/10.3109/13816810.2015.1071411>
- Kjaer, K. W., Hansen, L., Schwabe, G. C., Marques-de-Faria, A. P., Eiberg, H., Mundlos, S., ... Rosenberg, T. (2005). Distinct CDH3 mutations cause ectodermal dysplasia, ectrodactyly, macular dystrophy (EEM syndrome). *Journal of Medical Genetics*, *42*(4), 292–298. <https://doi.org/10.1136/jmg.2004.027821>
- Leibu, R., Jermans, A., Hatim, G., Miller, B., Sprecher, E., & Perlman, I. (2006). Hypotrichosis with juvenile macular dystrophy: Clinical and electrophysiological assessment of visual function. *Ophthalmology*, *113*(5), 841–847. e843. <https://doi.org/10.1016/j.optha.2005.10.065>
- Lupski, J. R., Reid, J. G., Gonzaga-Jauregui, C., Rio Deiros, D., Chen, D. C. Y., Nazareth, L., ... Gibbs, R. A. (2010). Whole-genome sequencing in a patient with Charcot-Marie-Tooth neuropathy. *New England Journal of Medicine*, *362*(13), 1181–1191. <https://doi.org/10.1056/NEJMoa0908094>
- Luzi, P., Rafi, M. A., & Wenger, D. A. (1995). Characterization of the large deletion in the GALC gene found in patients with Krabbe disease. *Human Molecular Genetics*, *4*(12), 2335–2338. <https://doi.org/10.1093/hmg/4.12.2335>
- Mason, J. O. 3rd, & Patel, S. A. (2015). A case of hypotrichosis with juvenile macular dystrophy. *Retinal Cases & Brief Reports*, *9*(2), 164–167. <https://doi.org/10.1097/ICB.0000000000000127>
- Nasser, F., Mulahasanovic, L., Alkhateeb, M., Biskup, S., Stingl, K., & Zrenner, E. (2019). Hypotrichosis with cone-rod dystrophy in a patient with cadherin 3 (CDH3) mutation. *Documenta Ophthalmologica*, *138*(2), 153–160. <https://doi.org/10.1007/s10633-019-09675-w>
- Rafi, M. A., Luzi, P., Chen, Y. Q., & Wenger, D. A. (1995). A large deletion together with a point mutation in the GALC gene is a common mutant allele in patients with infantile Krabbe disease. *Human Molecular Genetics*, *4*(8), 1285–1289. <https://doi.org/10.1093/hmg/4.8.1285>
- Rentzsch, P., Witten, D., Cooper, G. M., Shendure, J., & Kircher, M. (2019). CADD: Predicting the deleteriousness of variants throughout the human genome. *Nucleic Acids Research*, *47*(D1), D886–D894. <https://doi.org/10.1093/nar/gky1016>
- Shimomura, Y., Wajid, M., Kurban, M., & Christiano, A. M. (2010). Splice site mutations in the P-cadherin gene underlie hypotrichosis with juvenile macular dystrophy. *Dermatology*, *220*(3), 208–212. <https://doi.org/10.1159/000275673>
- Sprecher, E., Bergman, R., Richard, G., Lurie, R., Shalev, S., Petronius, D., ... Szargel, R. (2001). Hypotrichosis with juvenile macular dystrophy is caused by a mutation in CDH3, encoding P-cadherin. *Nature Genetics*, *29*(2), 134–136. <https://doi.org/10.1038/ng716>
- Vahidnezhad, H., Youssefian, L., Jazayeri, A., & Uitto, J. (2018). Research techniques made simple: Genome-wide homozygosity/autozygosity mapping is a powerful tool for identifying candidate genes in autosomal recessive genetic diseases. *Journal of Investigative Dermatology*, *138*(9), 1893–1900. <https://doi.org/10.1016/j.jid.2018.06.170>
- Vahidnezhad, H., Youssefian, L., Saeidian, A. H., Zeinali, S., Touati, A., Abiri, M., ... Uitto, J. (2018). Genome-wide single nucleotide polymorphism-based autozygosity mapping facilitates identification of mutations in consanguineous families with epidermolysis bullosa. *Experimental Dermatology*, *138*, 121–131. <https://doi.org/10.1111/exd.13501>
- Wang, K., Li, M., & Hakonarson, H. (2010). ANNOVAR: Functional annotation of genetic variants from high-throughput sequencing data. *Nucleic Acids Research*, *38*(16), e164. <https://doi.org/10.1093/nar/gkq603>

Youssefian, L., Vahidnezhad, H., Saeidian, A. H., Pajouhanfar, S., Sotoudeh, S., Mansouri, P., ... Uitto, J. (2019). Inherited non-alcoholic fatty liver disease and dyslipidemia due to monoallelic ABHD5 mutations. *Journal of Hepatology*, *71*(2), 366–370. <https://doi.org/10.1016/j.jhep.2019.03.026>

SUPPORTING INFORMATION

Additional supporting information may be found online in the Supporting Information section at the end of the article.

How to cite this article: Saeidian AH, Vahidnezhad H, Youssefian L, et al. Hypotrichosis with juvenile macular dystrophy: Combination of whole-genome sequencing and genome-wide homozygosity mapping identifies a large deletion in *CDH3* initially undetected by whole-exome sequencing—A lesson from next-generation sequencing. *Mol Genet Genomic Med*. 2019;7:e975. <https://doi.org/10.1002/mgg3.975>