

# Ultrasonographic and CT diagnosis of a complete splenic duplication with right splenic torsion and presumed regional splenic vein hypertension in a dog

Pierantonio Battiato<sup>1,2,4</sup>  | Raquel Salgüero<sup>2</sup> | Swan Specchi<sup>3</sup>  | Maurizio Longo<sup>1,4</sup> 

<sup>1</sup> Diagnostic Imaging Department, Veterinary Teaching Hospital, University of Milan, Lodi (LO), Italy

<sup>2</sup> Diagnostic Imaging Department, Hospital Veterinario Puchol, Madrid, Spain

<sup>3</sup> Diagnostic Imaging Department, Ospedale Veterinario I Portoni Rossi, Bologna, Italy

<sup>4</sup> Department of Veterinary Medicine, Veterinary Teaching Hospital, University of Milan, Milan, Italy

## Correspondence

Pierantonio Battiato, Diagnostic Imaging Department, Veterinary Teaching Hospital, University of Milan, Lodi (LO), Italy.  
Email: [pierantonioBattiato@gmail.com](mailto:pierantonioBattiato@gmail.com)

## Abstract

An 8-year-old mixed breed dog, was referred for lethargy, abdominal discomfort, hematemesis, and melena. Abdominal ultrasound revealed mineralization of the “right splenic vein” with collateral spiraling and a suspected splenic duplication. Computed tomography confirmed the duplication along with torsion of the splenic pedicle. Exploratory laparotomy confirmed the splenic torsion associated with congestion of the gastrointestinal vessels, indicative of a chronic onset of secondary regional splenic vein hypertension.

## KEYWORDS

canine, spleen, ultrasound, vein, whirl sign

## 1 | SIGNALMENT, HISTORY, AND CLINICAL FINDINGS

An 8-year-old, female, spayed mixed breed dog, weighing 32.8 kg, was presented to the Internal Medicine Department of the Hospital Veterinario Puchol for a history of intermittent hematemesis, melena, and abdominal discomfort. On physical examination, a slightly painful abdomen was detected. Hematology identified a mild lymphopenia and a mild hyperchromia. Biochemistry showed a mild decrease of the alkaline-phosphatase and a mild hypotriglyceridemia.

## 2 | IMAGING FINDINGS, DIAGNOSIS, AND OUTCOME

Three radiographic projections of the abdomen were performed (right/left lateral and ventrodorsal views; X-Ray beam limiting device

BLR-1000A, Canon Medical System, Tokio, Japan). This technique showed a focal linear well-defined peritoneal mineral opacity caudal to the gastric body and two well-defined soft tissue opacities on the cranioventral abdomen (Figure 1A,B).

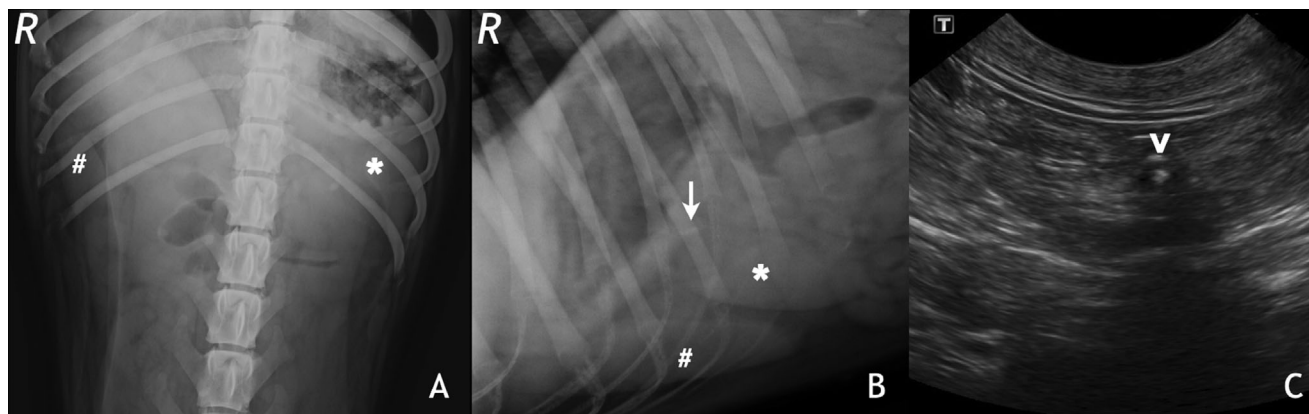
An abdominal ultrasound exam was performed with micro convex and linear array multifrequency probes ranging between 8 and 14 MHz (patient in dorsal recumbency; Aplio 300; Canon Medical System Europe). The examination revealed a normal splenic parenchyma in the anatomical localization on the left abdomen, along with an independent similar isoechoic parenchymal structure on the right cranial abdomen, caudal to the liver and the stomach, which presented a decreased color Doppler signal compared to the splenic vasculature. The latter structure presented multiple hila with arterial and venous vessels connecting to the parenchyma. A second finding included the presence of a hyperechoic and mildly casting well-defined linear interface (2 cm in length, 0.2 cm in thickness) located at the level of the “right splenic vein” (Figure 1C). This structure appeared to be intramural and was partially occluding the lumen of the “right splenic vein” with some peripheral luminal blood flow visible on Doppler color mode. The latter features led to suspect for a splenic parenchymal separation

**Abbreviations:** CT, computed tomography; GVs, gastroesophageal varices; RR, reference range; RSVH, regional splenic vein hypertension

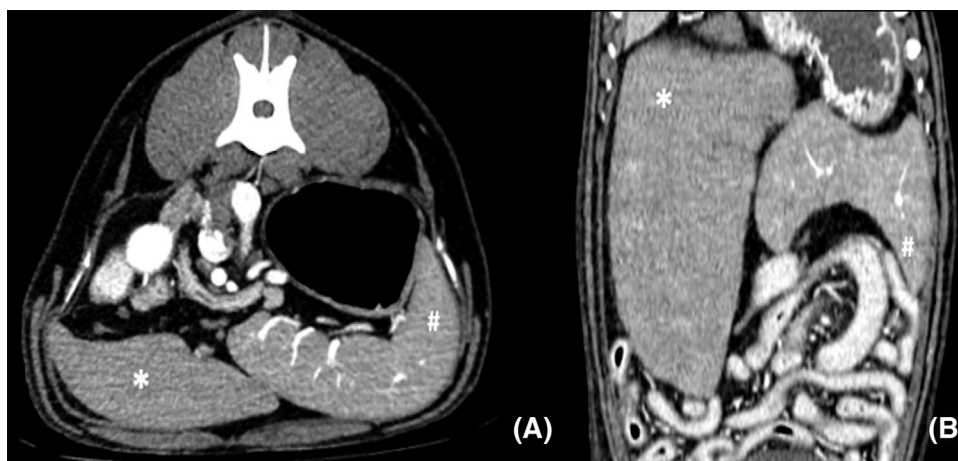
EQUATOR network guidelines disclosure: The authors followed the STROBE-VET reporting guidelines.

This is an open access article under the terms of the [Creative Commons Attribution-NonCommercial-NoDerivs](https://creativecommons.org/licenses/by-nc-nd/4.0/) License, which permits use and distribution in any medium, provided the original work is properly cited, the use is non-commercial and no modifications or adaptations are made.

© 2021 The Authors. *Veterinary Radiology & Ultrasound* published by Wiley Periodicals LLC on behalf of American College of Veterinary Radiology



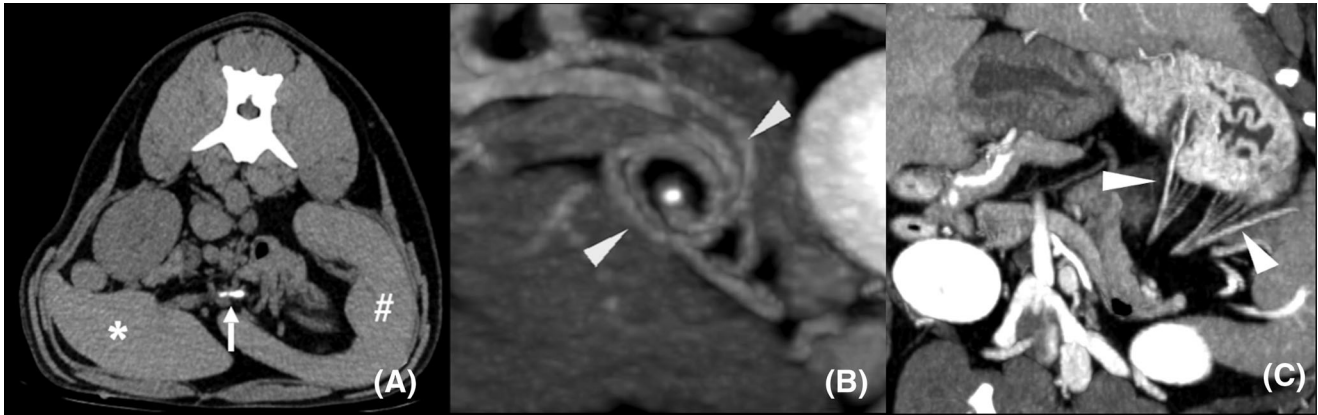
**FIGURE 1** Abdominal radiographic (ventrodorsal and right lateral views centered at cranial abdomen; kVp: 70, mAs: 10) and transverse ultrasonographic (patient in dorsal recumbency; microconvex probe, 4–10 MHz, 10 MHz used) images of the patient. A, A well-defined triangular-shaped soft tissue opacity is observed on the right cranial abdomen caudolateral to the right hepatic silhouette (hashtag). The dorsal extremity of the splenic silhouette is present in the left cranial abdomen (asterisk). B, On the lateral view two similar elongated soft tissue opacities are noted caudal to the hepatic silhouette (asterisk, hashtag). A linear mineral opacity is detected caudal to the gastric body (white arrow). C, Note the presence of a hyperechoic and mildly casting interface at the level of the “right splenic vein” (white arrowhead)



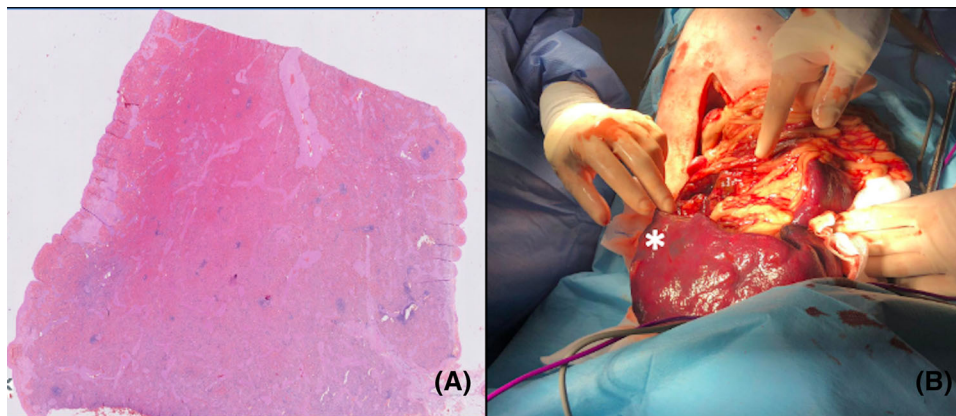
**FIGURE 2** Transverse and dorsal multiplanar reconstructions (MPR) postcontrast CT images (arterial phase) of the patient with a soft tissue algorithm (WL-40, WW-350). No connection is visible between the right (asterisk) and left (hashtag) splenic parenchyma. A decreased enhancement of the right spleen is visible (A)

with a focal dystrophic mineralization of the splenic vein, however these findings were considered equivocal to explain the clinical signs. In order to confirm the splenic duplication, further evaluate the splenic vein anatomy, exclude any possible parenchymal connection between the two “spleens” (which might be indicative of a parenchymal splenic torsion) and rule out additional causes for abdominal discomfort, an abdominal CT study was performed using a multidetector 16-slice CT scanner (Aquilion Lightning 16-Slice, Canon Medical Systems Europe), on helical scan mode, with the following parameters: pitch of 1.5, 120 kVp and 130 mAs, slice thickness of 2 mm. Postcontrast exam was performed using a manually injected bolus of 600 mg Iodine/kg of iodinated non-ionic contrast medium (Optiray®, Ioversol injection 68%, Liebel-Flarsheim Company LLC, Raleigh, NC 27616, USA) through a

cephalic venous angiocatheter. Images were acquired in soft tissue reconstruction algorithm 7 s after the start of injection of the contrast medium for the arterial phase, 25 s for the portal phase and 45 s for the late venous phase. The presence of a double spleen was confirmed along with multiple small gastric capillaries extending to the gastric wall (Figure 3C). The splenic parenchyma located in the right cranial abdomen was isoattenuating and hypoenhancing compared to the left one: precontrast HU mean 68 (left spleen HU mean 69) arterial HU mean 65 (left spleen HU mean 75), portal HU of 75 (left spleen HU mean 110), and delayed venous HU mean of 80 (left spleen HU mean 115; Figure 2). A focal mineralization was observed adhered to the wall of a “right splenic vein” anastomosing from the main splenic vein surrounded by multiple spiraling vessels (Figure 3A,B). Computed



**FIGURE 3** Transverse precontrast (A; WL-40, WW-350), sagittal and dorsal MPR postcontrast 3 mm slab-thickness MIP oblique (B-C; WL-160, WW-415) CT images of the patient with a low pass filter. A linear mineralized structure is visible at the level of the “right splenic vein” (white arrow, A). Two solid arrowheads indicate the “whirl-sign” of the splenic pedicle surrounding the vascular focal mineralization (B). Multiple congested capillaries extending to the gastric wall are indicated by the white arrowheads (C)



**FIGURE 4** Histological presentation of the normal splenic parenchyma with congestion of the *pulpa rubra* (A, scale bar = 2000 μm, Hematoxylin and Eosin). Intraoperative picture focused on the “right spleen” (B) with a macroscopic congestive appearance (asterisk) [Color figure can be viewed at [wileyonlinelibrary.com](http://wileyonlinelibrary.com)]

tomography diagnosis was consistent with a complete splenic duplication and mineralization of the “right splenic vein” and “whirl sign,” indicative of a chronic vascular splenic torsion.<sup>1,2</sup>

The exploratory laparotomy confirmed the presence of a complete splenic duplication with right and left splenic veins and an extensive peripheral collateral circulation. The splenic pedicle was 360° twisted at the level of the left gastroepiploic artery and venous outlets. Another finding included a prominent and congestive gastric and peritoneal capillary surface. A complete splenectomy and complete excision of the twisted vessels was performed.

On histopathology, the vessels appeared severely congestive; a connective-collagenous mineralized tissue band was detected on the mural vessel surface of the right splenic vein. Multiple lymphoplasmacytic aggregates, abundant necrotic adipocytes, and hemosiderin deposits were detected. Both samples from the spleens showed a normal splenic parenchyma though the specimen from the right spleen was characterized by a severe congestion compared to the left (Figure 4A,B).

These histopathological findings led to a final diagnosis of a complete splenic duplication with vascular wall mineralization, likely secondary to a focal hypoxic and necrotic area. The patient recovered uneventfully from surgery and was discharged after 24 h with palliative treatment.

At 2-weeks follow-up, a complete regression of the clinical signs was obtained, and the follow-up ultrasound exam showed no abnormalities.

### 3 | DISCUSSION

This case report highlights the important roles of CT and ultrasound as complementary modalities for the clinical management of a dog with a splenic duplication, torsion of the right-sided viscus and clinical signs presumably related to regional splenic vein hypertension. Recently, an original investigation about canine presumed regional splenic vein hypertension was published, although without focusing on the gastrointestinal disorders or evidence of splenic duplication.<sup>3</sup> Viscera

duplications have been widely described in veterinary medicine, affecting primarily the gastrointestinal and urogenital tract. The clinical signs often include abdominal discomfort or urinary incontinence.<sup>4,5</sup>

Based on our review of the literature, there are no reported cases of complete splenic duplication in veterinary medicine. Other colleagues described the sonographic assessment of accessory spleens, defined as “splenunculi.”<sup>6</sup> These congenital ectopic splenic tissues are small peritoneal iso-to-hypoechoic rounded nodules, commonly situated near the hilum of the spleen or adjacent to the tail of the pancreas and about one cm in diameter, different from what we found in the present case.<sup>6,13</sup>

“Splenosis” is another anomaly included among splenic ectopia, considered as a benign acquired condition of heterotopic autotransplantation in another anatomic compartment of the body, usually traumatic or iatrogenic. In this circumstance, splenic nodules can be found throughout the body and they derive their blood supply from neighboring tissues.<sup>14</sup> No history of trauma or splenectomy has been reported in this case and the blood supply for the “right spleen” was directly connected to the main splenic pedicle.

Ultrasonography was useful for the detection of an anomalous right-sided and cranially positioned part of the viscus.<sup>6</sup> Characteristics of splenic torsion were missing, such as the lack of connection between the two parenchymal spleens, the absence of lacy splenic echotexture or any hilar perivenous hyperechoic triangle.<sup>8</sup> Therefore, the authors hypothesized that the lack of most features typical for splenic torsion was due to changes in the position of the right spleen resulting in intermittent obstruction of the splenic vasculature. The close proximity with the liver and the gastrointestinal tract may have played a role in the movement of the right spleen. The mineralized structure detected on the right splenic vein, associated with a surrounding twirling of multiple collaterals, was consistent with a wall mineralization with spiraling of collaterals secondary to the vascular torsion.

The differentials for the hyperechoic/hyperattenuating structure found included an abnormal deposition of calcium in normal non-mineralized tissues or a chronic splenic vein thrombosis with mineralization secondary to the chronic splenic torsion.<sup>1,2</sup>

The “whirl sign”<sup>1,8</sup> is known as a strong indicator imaging sign of vascular torsion. In the present case, these findings were indicative of a vascular torsion considering the mineralization secondary to the focal hypoxemia as thereafter confirmed by the histopathology. Computed tomography was necessary to exclude any possible connection between the two splenic parenchyma.<sup>10</sup> Moreover, CT confirmed the vascular twirling previously detected in ultrasound and measured the attenuation of the mural mineralization of the “right splenic vein.” On CT angiography, the decreased enhancement of the “right spleen” compared to the “left spleen” revealed which part of the splenic parenchyma was affected by the vasculature torsion and occlusion.<sup>1,10</sup>

The authors presume intermittent onset of regional splenic vein hypertension and secondary microbleeds from the congested gastric capillary net, detected on laparotomy, as a probable cause of the gastrointestinal bleeding disorders that the patient was presented for.<sup>11</sup> Splenic vein occlusion results in back pressure, which is transmitted to

the left side of the portal system through the anastomoses between the splenic vein and the gastroepiploic vein. This reversal of flow may result in hypertension with secondary gastric/gastroesophageal varices (GVs), considered major sources for the gastrointestinal bleeding in regional splenic vein hypertension.<sup>3,11,12</sup> Furthermore, this syndrome is often associated with splenomegaly and normal liver function, with presence of GV only in 35–45% of the cases.<sup>11</sup> Splenectomy attenuates the arterial inflow into the left portal system and results in decompression of the concurrent gastric varices.<sup>11,12</sup>

According to the findings previously described and the absence of liver abnormalities, it was speculated that the double spleen, the spiraling vessels, the focal mineralization, and the prominent mesenteric vasculature may have been indicative of a chronic torsion of the right spleen<sup>1,10</sup>; resulting from the latter collateral pathway, a presumed regional splenic vein hypertension was considered as a trigger for the gastrointestinal bleeding disorders.

In conclusion, findings from the current study supported the use of CT as an ancillary diagnostic test for canine patients with abdominal discomfort, hematemesis/melena, and evidence of a duplicated spleen on ultrasound examination. Regional splenic vein hypertension should be included in the differential diagnosis list for dogs presenting a splenic duplication, vascular spiraling of the splenic tributaries, and prominence of the mesenteric/gastric vasculature on CT examination.

## LIST OF AUTHOR CONTRIBUTIONS

### Category 1

- (a) Conception and Design: Battiato, Longo
- (b) Acquisition of Data: Battiato, Longo
- (c) Analysis and Interpretation of data: Battiato, Salgüero, Specchi, Longo

### Category 2

- (a) Drafting the Article: Battiato, Salgüero, Specchi, Longo
- (b) Revising Article for Intellectual Content: Battiato, Salgüero, Specchi, Longo

### Category 3

- (a) Final Approval of the Completed Article: Battiato, Salgüero, Specchi, Longo

## CONFLICT OF INTEREST

The authors declare no conflict of interest.

## ORCID

Pierantonio Battiato  <https://orcid.org/0000-0003-0880-7944>

Swan Specchi  <https://orcid.org/0000-0001-5305-0245>

Maurizio Longo  <https://orcid.org/0000-0002-6838-8430>

## REFERENCES

1. Specchi S, d'Anjou MA. Diagnostic imaging for the assessment of acquired abdominal vascular diseases in small animals: a pictorial review. *Vet Radiol Ultrasound*. 2019;60(6):613-632.
2. Reinhart JM, et al. Chronic splenic torsion in two dogs. *J Am Anim Hosp Assoc*. 2015;51:185-190.
3. Specchi S, Bertolini G. CT angiography identifies collaterals in dogs with splenic vein obstruction and presumed regional splenic vein hypertension. *Vet Radiol Ultrasound*. 2020;1-5.
4. Mutascio L, et al. Multimodality characterization of a noncommunicating congenital duodenal duplication cyst causing pyloric outflow obstruction in a young dog. *Vet Radiol Ultrasound*. 2019;60(2):10-14.
5. Kopp KI, et al. Computed tomographic and sonographic findings in a dog with duplex kidney, ureter duplex and ectopic ureterocele. *Tierarztl Prax Ausg K Klientiere Heimtiere*. 2020;48(1):44-48.
6. Rossi F, et al. B-mode and contrast-enhanced sonographic assessment of accessory spleen in the dog. *Vet Radiol Ultrasound*. 2010;51(2):173-177.
7. Penninck D, D'Anjou MA. *Atlas of small animal ultrasonography*. New York: John Wiley and Sons; 2015:239-241.
8. Mai W. The hilar perivenous hyperechoic triangle as a sign of acute splenic torsion in dogs. *Vet Radiol Ultrasound*. 2006;47(5):487-491.
9. Valsky DV, et al. Whirlpool sign in the diagnosis of adnexal torsion with atypical clinical presentation. *Ultrasound Obstet Gynecol*. 2009;34(2).
10. Hughes J R, VS J, & Genain M A. (2020). CT characteristics of primary splenic torsion in eight dogs. *Vet Radiol Ultrasound*. 2019; 1-8.
11. Kul, M., Haliloğlu, N. Ü., Hürsoy, N., & Erden, A. Sinistral Portal Hypertension: computed tomography imaging findings and clinical appearance - A descriptive case series. *Can Assoc Radiol J* 2018;69(4):417-421.
12. Sarin, S. K., & Agarwal, S. R. Gastric varices and portal hypertensive gastropathy. *Clin Liver Dis* 2001;5:727-767
13. Gayer, G. et al. CT findings in congenital anomalies of the spleen. *Br J Radiol* 2001;74:767-772.
14. Lake, S. T. et al. CT of splenosis: patterns and pitfalls. *Am J Roentgenol* 2012;199(6):686-693.

**How to cite this article:** Battiato P, Salgüero R, Specchi S, Longo M Ultrasonographic and CT diagnosis of a complete splenic duplication with right splenic torsion and presumed regional splenic vein hypertension in a dog. *Vet Radiol Ultrasound*. 2022;E1-E5. <https://doi.org/10.1111/vru.13007>.