

# Repair of recto-urethral fistula with urethral augmentation by buccal mucosal graft and gracilis muscle flap interposition – our experience

Vikram Prabha<sup>1</sup>, Vishal Kadeli<sup>1,2</sup>

<sup>1</sup>KLE University's JN Medical College, KLES Dr. Prabhakar Kore Hospital & MRC, Department of Urology, Belgaum, India

<sup>2</sup>Department of Urology, KLES Kidney Foundation, KLE University's JN Medical College, KLES Dr. Prabhakar Kore Hospital & MRC, Belgaum, India

**Citation:** Prabha V, Kadeli V. Repair of recto-urethral fistula with urethral augmentation by buccal mucosal graft and gracilis muscle flap interposition – our experience. Cent European J Urol. 2018; 71: 121-128.

## Article history

Submitted: March 22, 2017

Accepted: Nov. 13, 2017

Published online: Dec. 8, 2017

## Corresponding author

Vishal Kadeli  
Kles Prabhakar Kore  
Hospital and Mrc  
NH Service Rd.  
590010 Belgaum, India  
phone: +97 420 84 012  
vishalkadeli@gmail.com

**Introduction** Recto-urethral fistula (RUF) is a relatively rare surgical condition, the treatment of which is quite challenging. There are many causes of RUF, but 60% of them are iatrogenic following open prostatectomies, radiotherapy, brachytherapy, urethral instrumentation etc. We present a series of six cases treated at our institution.

**Material and methods** A retrospective study of all six patients with recto-urethral fistula treated at our centre between 2011 and 2016 was performed. The study included charting of information like age, etiology, clinical presentation, diagnostic modalities, treatment protocols, complications and recurrence. All the patients had simple direct fistulas with no previous history of repair. One patient had history of pelvic fracture following road traffic accident, one patient had a penetrating perineal injury following road traffic accident; two patients had history of Freyer's prostatectomy for benign prostatic hypertrophy; two patients had history of open radical prostatectomy performed at other centres. All patients were treated with an initial double diversion (suprapubic cystostomy and colostomy) followed by definitive surgical repair three months later. The surgical technique used was fistula excision, urethral augmentation by buccal mucosal graft, primary rectal defect repair and gracilis muscle flap interposition between the rectum and urethra.

**Results** The patients were followed up ranging from after 6 to 48 months with a mean follow-up period of 27 months. There were minimal complications such as main wound site infections, seroma at the harvested site of gracilis muscle flap, urethral stricture. There was no report of recurrence.

**Conclusions** From our experience, we conclude that this method of repair is a very efficient one without any recurrence and with minimal complications. The results were on par with all the other successful methods of recto-urethral fistula repair described in the literature.

**Key Words:** radical prostatectomy ↔ rectourethral fistula ↔ Freyer's prostatectomy ↔ gracilis muscle flap

## INTRODUCTION

Recto-urethral fistula (RUF) is a relatively uncommon surgical condition (Figure 7) which requires complex and meticulous surgery. RUFs (recto-urethral fistulas) are classified according to etiology by Culp and Calhoon [1] as follows a) congenital due to malformation of anus and urinary tract, b) iatrogenic

following surgeries like open prostatectomy, radiotherapy, brachytherapy, urethral instrumentation, c) traumatic, d) neoplastic, e) inflammatory. Of these, 60% of RUFs are iatrogenic [2] and the majority are caused by radical prostatectomy [3, 4, 5].

RUFs are also reported after prostate cryosurgery, radiotherapy, chemotherapy, high intensity focused ultrasound therapy and transrectal hyperthermia

[6, 7, 8]. Common presentations of RUF are watery stools, fecaluria, pneumaturia [9, 10]. RUFs (can be diagnosed clinically with symptoms like fecaluria, pneumaturia, or urine leak from rectum. Digital rectal examination, proctoscopy and cystoscopy are some of the suggested modalities for diagnosis. MCU (micturating cysto-urethrogram) is suggested for all cases of suspected RUFs and passage of dye into rectum confirms the diagnosis [11–14]. Computed tomography (CT) cystogram is an additional and important diagnostic modality which is very useful during emergencies like traumatic cases. The aim of this study is to assess the outcome of this surgical technique on a long-term basis.

## MATERIAL AND METHODS

A retrospective study of all six patients with recto-urethral fistula treated at our centre between 2011 and 2016 was performed. The study included charting of information like age, etiology, clinical presentation, diagnostic modalities, treatment protocols, complications and recurrence. A total of six patients presented to our hospital with clinical features suggestive of RUF. Diagnosis was confirmed by symptoms, per rectal examination, MCU and cystoscopy. Two of the patients visited the emergency room with history of road traffic accident (RTA).

**Case 1.** This patient had a history of pelvic fracture with inability to pass a catheter through the urethra, for which supra pubic cystostomy was done. The patient presented with fecaluria and passing urine per rectum after 1 week. Digital rectal examination revealed a communication between the rectum and urethra. CT cystogram was done by pushing dye through the suprapubic cystostomy (SPC) into the bladder and there was passage of dye into the rectum. A diversion colostomy was done and the patient was reviewed after 3 months. The patient's pelvis was stabilized before the definitive surgery.

**Case 2.** The second patient had a history of RTA (road traffic accident) with a penetrating injury in the perineum resulting in injury to the urethra and rectum. Suprapubic cystostomy and colostomy were done. Prophylactic tetanus immunoglobulin was given. Thorough wound cleaning was done and it was made sure there was no infection before performing the definitive procedure. The patient was reviewed after 3 months.

**Cases 3 and 4.** Two patients had history of Freyer's prostatectomy performed for treatment of BPH at a different centre. The patients were referred to our hospital with complaints of watery diarrhea and fecaluria. Digital rectal examination and MCU (micturating cysto-urethrogram) confirmed the di-

agnosis. Suprapubic cystostomy and a diversion colostomy was done and reviewed after 3 months for definitive surgery.

**Cases 5 and 6.** Two patients had history of radical prostatectomy for prostate cancer at different centres. Both patients had undergone suprapubic cystostomy and a diversion colostomy. Spontaneous closure was not seen after 3 months and they were referred to our hospital.

In all six patients, excision of fistula, urethral augmentation by buccal mucosal graft, closure of rectal defect in multiple layers and transposition of gracilis muscle flap between urethra and rectum was done.

**Pre-operative instructions:** All patients were advised to maintain good colostomy and SPC hygiene.

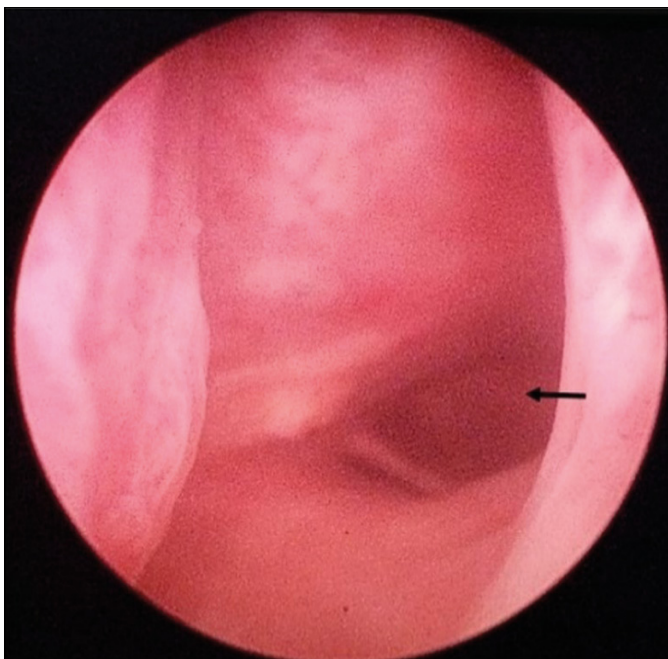
## Surgical technique

All surgeries were performed by the same urologist. The patients were placed in the lithotomy position. Cystoscopy was done and the fistulous connection was visualized (Figure 1). All the fistulas were direct and simple fistulas, measuring approximately 1 cm in size and allowed the insertion of the beak of a 22 Fr cystoscope. A 0.35 guide wire was passed into the bladder through the cystoscope (Figure 2). Foley's catheter was guided over the wire.

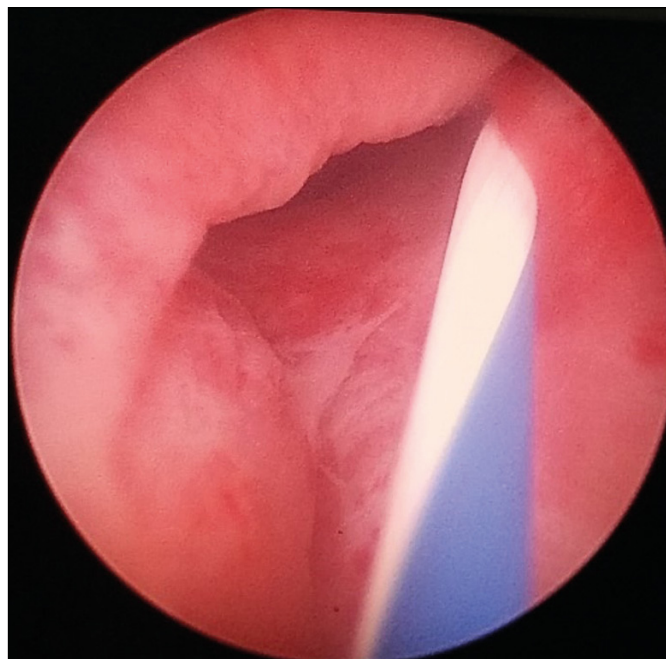
An inverted 'Y' shaped incision was made over the perineum. The incision was deepened and all the layers, including Colles' fascia, were incised. The perineal body was dissected and cut to create space between the rectum and urethra. The rectum was dissected while sparing the external sphincter. The urethra was mobilized anteriorly. An index finger was inserted into the rectum and the fistulous opening was felt. The fistulous opening was incised around the finger and the edges were freshened and sutured in two layers using 3-0 vicryl sutures. Simultaneously, the buccal mucosal graft was harvested from the inner cheek, sparing Stenson's duct. The buccal mucosal graft was placed over the urethral defect and sutured using 3-0 vicryl sutures (Figures 3A & B).

**Harvesting the gracilis muscle flap:** A line was drawn on the inner thigh starting from the pubic tubercle to the medial condyle of tibia. An incision was made 10 cm away and 3 cm below the pubic tubercle to conserve the main neurovascular bundle supplying the gracilis muscle. Three more incisions were made in between the first incision and the medial condyle, at equal distances from each other (Figure 4). The tendinous insertion was divided and the muscle was separated from its insertion. The gracilis muscle was carefully dissected by dividing the small vessels supplying the muscle and it was delivered out

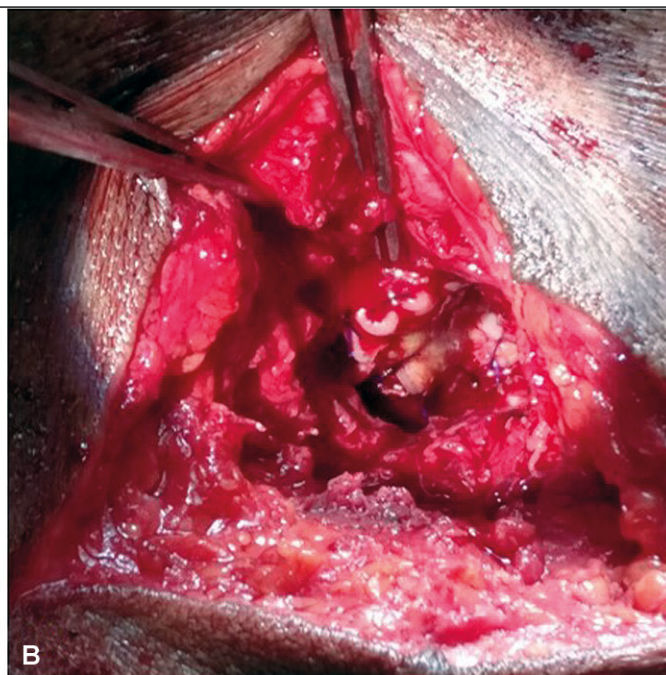
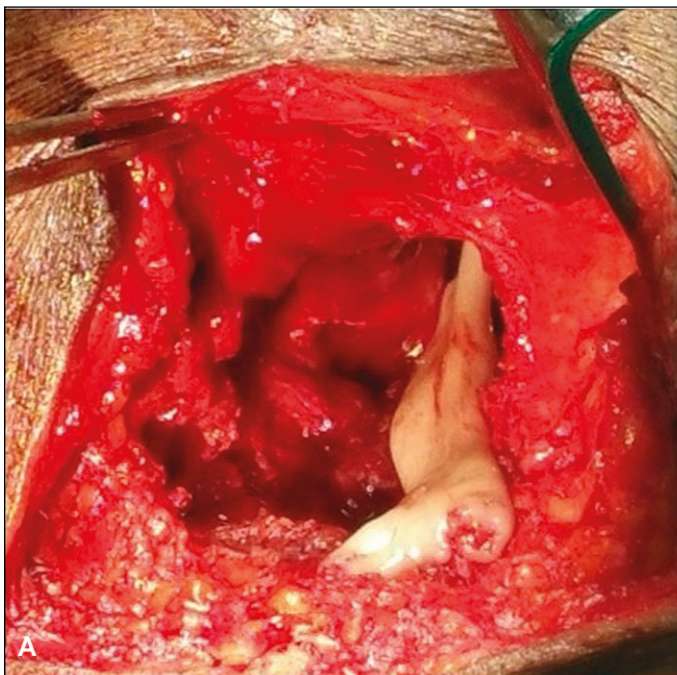




**Figure 1.** *Fistulous connection visualized through cystoscope.*



**Figure 2.** *Guidewire passed into patient's bladder.*

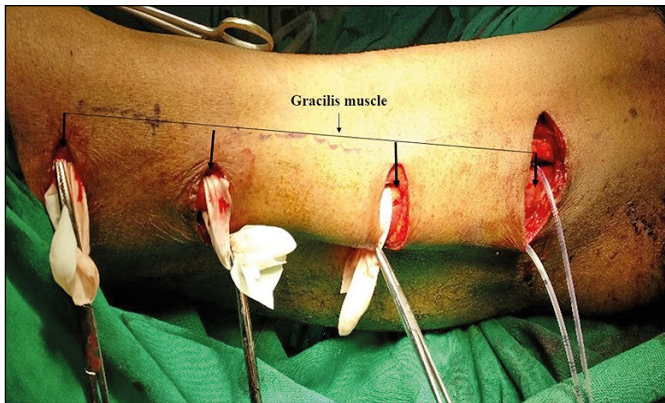


**Figure 3A.** *Buccal mucosal graft was placed on urethral defect. B.* *Shows the graft sutured to the urethral defect.*

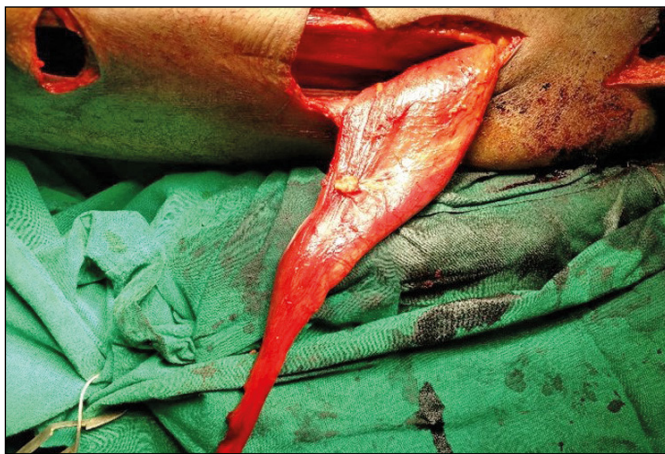from the proximal incision (Figure 5). The viability of muscle was tested by eliciting twitching after it was touched with a bipolar cautery. The muscle was rotated by 180 degrees and tunneled beneath the subcutaneous tissue and interposed between the rectum and urethra (Figure 8) and sutured to the pararectal tissues using 2-0 vicryl sutures (Figure 6).

A drain was kept at the harvested site and the incisions were sutured. The suprapubic catheter was removed after three days. The drain was removed after the wound was dry. Colostomy closure was done after 2 months. The urethral catheter was removed after 6 weeks. Post-operative instructions: All patients were advised to maintain perineal hygiene and report imme-

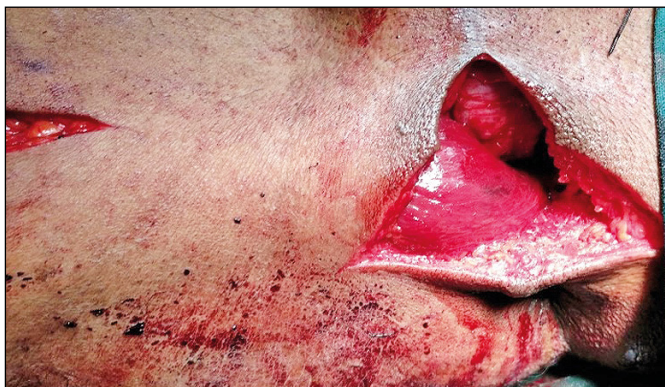



**Figure 4.** Gracilis muscle was dissected by dividing the small vessels supplying the muscle through multiple incisions while preserving the neurovascular bundle.

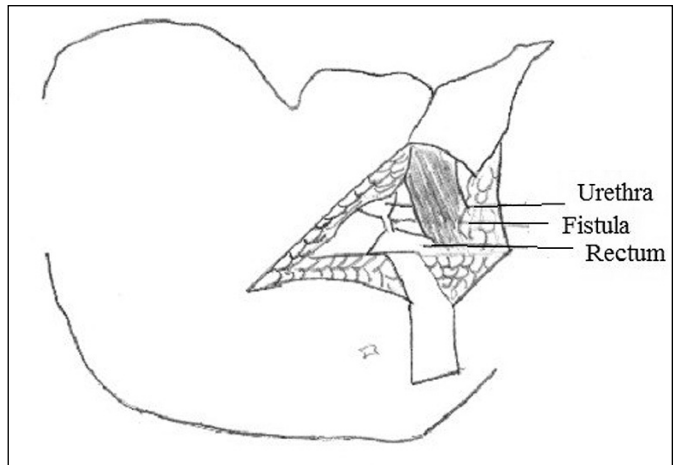


**Figure 5.** Gracilis muscle flap after division of tendon and delivered through proximal incision.

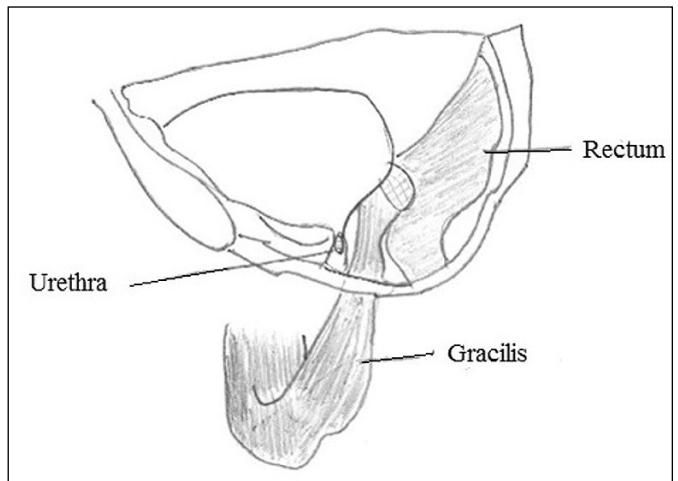


**Figure 6.** Gracilis muscle flap interposition between rectum and urethra by fixing it to para-rectal tissues.

diately if they experienced any symptoms like poor stream of urine, pneumaturia, or fecaluria. The average operating time was 227 minutes and the average hospital stay was 11.16 days (Table 1).



**Figure 7.** Shows the urethra and rectum and the fistulous connection.



**Figure 8.** Shows interposition of gracilis muscle flap between rectum and urethra.

## RESULTS

The patients were followed up ranging from 6 to 48 months with a mean follow-up period of 27 months. There were minor complications such as main wound infection or seroma at the harvested site of gracilis in 4 patients and these were managed conservatively. One patient presented with poor urine stream 4 months after the repair and was diagnosed with proximal urethral stricture. Four patients developed erectile dysfunction soon after the inciting factors causing the RUF (2 traumatic, 1 radical prostatectomy, 1 Freyer's prostatectomy). There was no improvement after the repair. It is important to note that erectile dysfunction was caused by the primary inciting factor and not the corrective surgery. There were no cases of anal stricture or urinary inconti-

nence. There was no recurrence of the fistula noted in any of our patients (Tables 2 & 3).

## DISCUSSION

Spontaneous closures of small RUFs have been reported following long-term urethral catheterization [15]. Spontaneous closures following double diversion have also been reported in war wounds [13] and post radical prostatectomies [15]. Currently, the widely accepted treatment protocol worldwide is double diversion followed by definitive surgical repair [9, 16]. More than 40 surgical techniques have been described in the literature [17, 18, 19] which include transperineal, transanal, posterior para-rectal, transabdominal and transvesical, transphincteric and combined methods [20]. In 1969, a posterior parasacrococcygeal transphincteric approach was described which involved division of the sphincter (The York Mason procedure) [22]. The patient is placed in the prone jackknife position. After incision and dividing the sphincter, the mucocutaneous junction and both internal and external anal sphincters are marked by color-coded sutures to provide proper alignment and reconstruction at closure. The fistula is excised exposing the catheter in the prostatic urethra and the rectal wall is separated from the urinary tract by sharp dissection to allow sufficient mobilization. After closing the urethra, the rectum is sutured while making sure that the suture lines do not overlap each other with a 'vest over pants' technique. Parks et al. [39] described a fistula's repair by means of a full thickness flap of the anterior rectal wall through a transanal approach, with the aim to avoid any division of the sphincter mechanism. The rectal mucosa is excised laterally and distally to the rectal opening of the track, and the circular muscular layer of the rectum is denuded. Then, a flap of about four centimeters in length is harvested. The defect in the urethra is closed using interrupted absorbable sutures over the urethral catheter to prevent stenosis. The rectal flap is advanced over the fistula and sutured to the rectal wall with interrupted absorbable sutures. Pera et al. [27] reported 100% cure rates in 5 patients after the York Mason procedure. Since this method involves the division of sphincters, rectal incontinence has been reported. Five to seven % of patients treated by this procedure also developed recto-cutaneous fistulas [28]. A posterior sagittal approach was also described by Kraske without the division of sphincters, however this technique is not very popular.

The perineal approach was first described by Young in 1917 where he dissected the rectum away from sphincters, divided the fistula, closed the urethra, and mobilized the rectum further cephalad in such a way as to pull the affected rectum caudad out of the

**Table 1.** The duration of surgery, hospital stay and amount of blood loss

Case	Duration of surgery	Blood loss	Duration of hospital stay
Case 1	248 min	<500 ml	14 days
Case 2	210 min	<500 ml	14 days
Case 3	189 min	<500 ml	8 days
Case 4	245 min	<500 ml	12 days
Case 5	196 min	<500 ml	9 days
Case 6	278 min	<500 ml	10 days
Mean	227 min	Mean	11.16 days

**Table 2.** Retrospective chart of patients' profiles

Sl. No.	Age	Etiology	Complications	Follow up	Recurrence
1.	29	Pelvic fracture	Main wound infection and stricture urethra and erectile dysfunction	48 months	Nil
2.	36	Penetrating injury	Wound infection and erectile dysfunction	36 months	Nil
3.	66	Freyer's prostatectomy	Seroma at gracilis muscle flap harvested site	36 months	Nil
4.	68	Freyer's prostatectomy	Wound infection and seroma at gracilis flap harvested site and erectile dysfunction	24 months	Nil
5.	62	Radical prostatectomy	Erectile dysfunction	12 months	Nil
6.	64	Radical prostatectomy	Wound infection	6 months	Nil

**Table 3.** The duration of surgery, hospital stay and amount of blood loss

Complications	Number	Management	Outcome
Main wound infection	2 (case 1 and 6)	Cleaning and dressing	Improved
Seroma at site of harvest of gracilis flap	1 (case 3)	Cleaning and dressing	Improved
Main wound infection and seroma at harvest site of gracilis	1 (case 4)	Cleaning and dressing	Improved
Stricture urethra	1 (case 1)	Cystoscopic dilatation done and advised clean intermittent catheterization once a day	Improved
Erectile dysfunction	4 (case 1, 2, 4, 5)	PDE5 inhibitors	Not improved

**Table 4.** Meta-analysis of various techniques described by surgeons and their success rates

Surgeon	Number of patients	Approach	Graft	Closure technique	Success rate
Pera et al. [27]	5	York mason	Nil	Layer to layer	100%
Crippa et al. [2]	5	York mason	Nil	Layer to layer	100%
Dafnis et al. [29]	1	York mason	Nil	Layer to layer	100%
Kasraeian et al. [30]	12	Modified York mason procedure	Nil	Layer to layer	100%
Spahn et al. [31]	4	Transperineal	Buccal mucosa	Mucosal patch	75%
Zmora et al. [32]	2	Transperineal	Gracilis muscle	Layer to layer	100%
Ghoniem et al. [33]	10	Transperineal	Gracilis muscle flap	Rectal flap	100%
Culkin and Ramsey [34]	3	Transperineal	De-epithelised scrotal flap	Y-V plasty	100%
Quazza et al. [35]	2	Transperineal	Omental flap mobilized laparoscopically	Layer to layer	100%
Youseffet al. [36]	2	Transperineal	Dartos-pedicled Flap	Layer to layer	100%
Wilbert et al. [37]	2	Transperineal	Fibrin glue	Layer to layer	100%
Abdalla [38]	1	Posterior sagittal pararectal with rectal mobilization	Gluteus muscle flap	Layer to layer	100%
Present study	6	Transperineal	Gracilis muscle flap	Layer to layer	100%

**Table 5.** Pros and cons of single vs. double diversion vs. gracilis interposition in small fistulas

Technique	Pros	Cons
Single diversion (ileal/colonic)	Less morbidity	High chances of failure if per urethral catheter is blocked in the post-operative period
Double diversion	Good option for surgically unfit patients, contaminated penetrating wounds	High morbidity
Gracilis interposition	High success rates	Challenging procedure

anus where it was then transected and discarded, suturing the proximal rectum to the anal skin. A large series of RUF repair by this method was reported by Goodwin in 1958 [21].

There have been reports of commercial fibrin sealant (Quixil) with anterior mucosal flap with no recurrence [24] and fibrin sealant injection with 70% cure rates [25, 26]. In 1979, Ryan et al. described the technique of gracilis muscle interposition [23]. Other alternatives that have been used are omentum, scrotal flap, levator ani muscles, gluteus muscle, fibrin glue etc. We preferred the gracilis muscle because of the ease of dissection with intact blood supply and relatively smaller muscle thickness; a gracilis muscle flap is ideal in this smaller operative field.

## CONCLUSIONS

RUF being a rare condition does not have a well-established protocol for diagnosis and treatment. However, there have been many reports by surgeons who have used different methods of repair with varying degrees of success (Table 4). In the present study, we propose this method of repair as a very efficient method with a defined protocol of double diversion followed by definitive repair. As urologists are well versed with the perineal anatomy, this method is easier to perform than other methods described in literature (Table 5). Though our study shows a 100% success rate with this method, use of this method on a larger number of RUF patients needs to be analyzed.

## Limitations of our study

Our study included six patients. This method of repair should be applied to a larger group of patients with recto-urethral fistulas.

The present study did not include patients with post radiation recto-urethral fistulas.

Further use of autologous cells cultivated by tissue engineering would be the ideal treatment in the future.

## CONFLICTS OF INTEREST

The authors declare no conflicts of interest.



## References

1. Culp OS, Calhoon HW. A variety of rectourethral fistulas: experiences with 20 cases. *J Urol.* 1964; 91: 560-571.
2. Crippa A, Dall'Oglio MF, Nesrallah LJ, Hasegawa E, Antunes AA, Srougi M. The York-Mason technique for recto-urethral fistulas. *Clinics.* 2007; 62: 699-704.
3. Tiptaft RC, Motson RW, Costello AJ, Paris AME, Blandy JP. Fistulae involving rectum and urethra: the place of Parks operations. *Br J Urol.* 1983; 55: 711-715.
4. Noldus J, Graefen M, Huland H. An 'old technique' for a new approach for repair of rectourinary fistulas. *J Urol.* 1997; 157 Suppl 4: 1547.
5. Eastham JA, Scardino PT. Radical Prostatectomy. In: Walsh PC, Retik AB, Vaughan ED, Wein AJ (Eds.). *Campbell's Urology.* Philadelphia, WB Saunders Co., 7th ed., 1997, pp. 2554.
6. Zippe CD. Cryosurgery of the prostate: technique and pitfalls. *Urol Clin North Am.* 1996; 23: 147-163.
7. Andrews EJ, Royce P, Farmer KC. Transanal endoscopic microsurgery repair of rectourethral fistula after high-intensity focused ultrasound ablation of prostate cancer. *Colorectal Dis.* 2011; 13: 342-343.
8. Montorsi F, Guazzoni G, Bergamaschi F, et al. Transrectal prostatic hyperthermia and advanced prostatic cancer. Clinical results of one year follow up. *Acta Urol Ital.* 1992; 6: 471-474.
9. Nyam DC, Pemberton JH. Management of iatrogenic rectourethral fistula. *Dis Colon Rectum.* 1999; 42: 994-997.
10. Kitamura H, Tsukamoto T. Rectourinary fistula after radical prostatectomy: review of the literature for incidence, etiology, and management. *Prostate Cancer.* 2011; 629105.
11. Blandy JP, Singh M. Fistulae involving the adult male urethra. *Br J Urol.* 1972; 44: 632-643.
12. Chiou RK, Anderson JC, Tran R, et al. Evaluation of urethral strictures and associated abnormalities using resolution and color Doppler ultrasound. *Urology.* 1996; 47: 102-107.
13. Al-Ali M, Kashmoula D, Saoud IJ. Experience with 30 posttraumatic rectourethral fistulas: presentation of posterior transsphincteric anterior rectal wall advancement. *J Urol.* 1997; 158: 421-424.
14. Noldus J, Graefen M, Huland H. An 'old technique' for a new approach for repair of recto urinary fistulas. *J Urol.* 1997; 157 (Suppl 4): 1547.
15. Chun L, Abbas MA. Rectourethral fistula following laparoscopic radical prostatectomy. *Tech Coloproctol.* 2011; 15: 297-300.
16. Hanus T. Rectourethral fistulas. *Int Braz J Urol.* 2002; 28: 338-345.
17. Thomas C, Jones J, Jäger W, Hampel C, Thüroff JW, Gillitzer R. Incidence, clinical symptoms and management of rectourethral fistulas after radical prostatectomy. *J Urol.* 2010; 183: 608-612.
18. Hanna JM, Turley R, Castleberry A, et al. Surgical management of complex rectourethral fistulas in irradiated and nonirradiated patients. *Dis Colon Rectum.* 2014; 57: 1105-1112.
19. Rouanne M, Vaessen C, Bitker MO, Chartier-Kastler E, Rouprêt M. Outcome of a modified York Mason technique in men with iatrogenic urethrorectal fistula after radical prostatectomy. *Dis Colon Rectum.* 2011; 54: 1008-1013.
20. Dal Moro F, Mancini M, Pinto F, Zanovello N, Bassi PF, Pagano F. Successful repair of iatrogenic rectourinary fistulas using the posterior sagittal transrectal approach (York-Mason): 15-year experience. *World J Surg.* 2006; 30: 107-113.
21. Goodwin WE, Turner RD, Winter CD. Rectourinary fistula: principles of management and a technique of surgical closure. *J Urol.* 1958; 80: 246-254.
22. Kilpatrick FR, Mason AY. Postoperative recto-prostatic fistula. *Brit J Urol.* 1969; 41: 649-654.
23. Ryan JA Jr, Beebe HG, Gibbons RP. Gracilis muscle flap for closure of rectourethral fistula. *J Urol.* 1979; 122: 124-125.
24. Verriello V, Altomare M, Masiello G, Curatolo C, Balacco G, Altomare DF. Treatment of post-prostatectomy rectourethral fistula with fibrin sealant (Quixil™) injection: a novel application. *Tech Coloproctol.* 2010; 14: 341-343.
25. Patrlj L, Kocman B, Martinac M, Jadrijević S, Šoša T, Šebečić B, Brkljačić B. Fibrin glue-antibiotic mixture in the treatment of anal fistulae: experience with 69 cases. *Dig Surg.* 2000; 17: 77-80.
26. Park JJ, Cintron JR, Orsay CP, Pearl RK, Nelson RL, Sone J, Song R, Abcarian H. Repair of chronic anorectal fistulae using commercial fibrin sealant. *Archi Surg.* 2000; 135: 166-169.
27. Pera M, Alonso S, Parés D, et al. Treatment of a rectourethral fistula after radical prostatectomy by York Mason posterior trans-sphincter exposure. *Cir Esp.* 2008; 84: 323-327.
28. Fengler SA, Abcarian H. The York Mason approach to repair of iatrogenic rectourinary fistulae. *Am J Surg.* 1997; 173: 213-217.
29. Dafnis G, WANG YH, Borck L. Transsphincteric repair of rectourethral fistulas following laparoscopic radical prostatectomy. *Int J Urol.* 2004; 11: 1047-1049.
30. Kasraeian A, Rozet F, Cathelineau X, Barret E, Galiano M, Vallancien G. Modified York-Mason technique for repair of iatrogenic rectourinary fistula: the montsouris experience. *J Urol.* 2009; 181: 1178-1183.
31. Spahn M, Vergho D, Riedmiller H. Iatrogenic recto urethral fistula: perineal repair and buccal mucosa interposition. *BJU Int.* 2009; 103: 242-246.
32. Zmora O, Tulchinsky H, Gur E, Goldman G, Klausner JM, Rabau M. Gracilis muscle transposition for fistulas between the rectum and urethra or vagina. *Dis Colon Rectum.* 2006; 49: 1316-1321.
33. Ghoniem G, Elmissiry M, Weiss E, Langford C, Abdelwahab H, Wexner S. Transperineal repair of complex rectourethral fistula using gracilis muscle flap interposition can urinary and bowel functions be preserved? *J Urol.* 2008; 179: 1882-1886.
34. Culkun DJ, Ramsey CE. Urethrorectal fistula: transanal, transsphincteric approach with locally based pedicle interposition flaps. *J Urol.* 2003; 169: 2181-2183.
35. Quazza JE, Firmin F, Cossa JP. Recto-urethral fistula following prostatectomy: surgical repair using a combined perineal and laparoscopic approach. Procedure and

- results of two cases. *Prog Urol.* 2009; 19: 434-437.
36. Youssef AH, Fath-Alla M, El-Kassaby AW. Perineal subcutaneous dartos pedicled flap as a new technique for repairing urethrorectal fistula. *J Urol.* 1999; 161: 1498-1500.
37. Wilbert DM, Buess G, Bichler KH. Combined endoscopic closure of rectourethral fistula. *J Urol.* 1966; 155: 256-258.
38. Abdalla MA. Posterior sagittal pararectal approach with rectal mobilization for repair of rectourethral fistula: an alternative approach. *Urology.* 2009; 73: 1110-1114.
39. Parks AG, Motson RW. Perianal repair of rectoprostatic fistula. *Brit J Surg.* 1983; 70: 725. ■