

Effect of video-assisted thoracoscopic surgery on pain stress indicators NO, IL-1 β and IL-6 in the treatment of mediastinal tumor in children

BO ZHAI, YONGHONG ZHANG, ZHENLIANG CHEN, FANG YANG, XIANGYANG DONG, ZHONGJIAN CHEN, YAZHOU CUI, PENGGAO WANG, LEI SHI and WENBO YU

Department of Cardiothoracic Surgery, Children's Hospital Affiliated to Zhengzhou University, Henan Children's Hospital, Zhengzhou Children's Hospital, Zhengzhou, Henan 450018, P.R. China

Received September 3, 2018; Accepted February 12, 2020

DOI: 10.3892/ol.2020.11515

Abstract. This study aimed to investigate the effect of video-assisted thoracoscopic surgery (VATS) on pain stress indicators nitric oxide (NO), interleukin-1 β (IL-1 β) and IL-6 in the treatment of mediastinal tumor in children, so as to explore the clinical application value of this surgery. A retrospective analysis was performed on 82 children with mediastinal tumor undergoing operation in Children's Hospital Affiliated to Zhengzhou University from January 2012 to January 2016. Among them, 48 children undergoing VATS were enrolled as an observation group, and 34 children undergoing conventional thoracotomy were enrolled as a control group. Enzyme-linked immunosorbent assay (ELISA) was used to detect the preoperative and postoperative expression levels of NO, IL-1 β and IL-6. The intraoperative clinical data, postoperative pain degree and infection rate were observed and recorded in real time, and then compared between the two groups. Before operation (T₀), there were no statistically significant differences between the two groups in serum NO, IL-1 β and IL-6 expression levels, which were lower in the observation group than those in the control group at 12 h (T₁) and 24 h (T₂) after operation (P<0.05). The visual analog scale (VAS) score in the observation group was lower than that in the control group at T₁ (P<0.05). Compared with the control group, the largest blade opening, intraoperative blood loss, drainage duration and postoperative pain degree were significantly improved in the observation group. The postoperative infection rate was 4.17% in the observation group, significantly lower than 17.64% in the control group. VATS is effective for postoperative pain stress indicators and infection control in children with mediastinal

tumor, which is therefore more suitable for children with the disease and has a higher clinical value.

Introduction

Mediastinal tumor is a common chest tumor. Mediastinum, an area defined by anatomy (1), contains all organs and tissues of the chest from the sternum to the spine and between the lungs. These organs and tissues are derived from different viviparous tissues, so there is no specific pathogenic factor and obvious disease zone of a high incidence in mediastinal tumor. So far, there are no clear data showing the number of patients with mediastinal tumor in the world, and it was only reported that there were 2,800 patients with the disease in the United States in 2017 (2). Mediastinal tumor grows in the mediastinal region that basically covers the whole thoracic cavity of human body, so mediastinal tumors are various. At present, mediastinal tumors are divided into neurogenic tumor (21%), thymoma (19%), mediastinal cyst (21%), teratoma (15%) and others (24%) (3). The main early clinical features of children with mediastinal tumor include cough, dyspnea and dysphagia (4), which are the result of the tumor obstructing the respiratory, nervous, digestive and circulatory systems in the body (5). The prevalence of mediastinal tumor in children is lower than that in adults, but the tumor growth rate and the carcinogenic rate in children are much higher than those in adults due to the small thoracic volume and the immaturity of tissues and organs in children (6). Therefore, there is no time to delay the treatment of mediastinal tumor in children.

At present, the main treatment of mediastinal tumor is surgical resection (7). Thoracotomy, a conventional resection operation (8), has an intuitive and clear visual field and is convenient to remove the tumor. However, during the operation, thoracotomy causes serious damage to human bone structure and exposes the tissues and organs for a long time, which leads to a high postoperative infection rate and incidence of complications and thereby prolongs the cure cycle. As the era of minimal invasiveness comes, video-assisted thoracoscopic surgery (VATS) makes up for the above shortcomings (9) and fundamentally reduces

Correspondence to: Dr Bo Zhai, Department of Cardiothoracic Surgery, Children's Hospital Affiliated to Zhengzhou University, Henan Children's Hospital, Zhengzhou Children's Hospital, 33 Longhu Outer Ring East Road, Zhengzhou, Henan 450018, P.R. China
E-mail: bbs3xx@163.com; zhai3000@163.com

Key words: thoracoscopy, mediastinal tumor, NO, IL-1 β , IL-6, pain stress

postoperative infection. In addition, VATS has small wound and does not damage the cutaneous branch of the intercostal nerve, so patients have milder pain, less bleeding and faster postoperative recovery. However, VATS is a traumatic operation, so there is still postoperative infection and pain stress, especially in children. The postoperative trauma leads to stress in the body, among which, the increase in nitric oxide (NO), interleukin-1 β (IL-1 β) and IL-6 levels activates the phagocytosis of phagocytes and granulocytes, thereby stimulating inflammation. Therefore, the observation and study of infection and pain stress indicators after the VATS surgery in children with mediastinal tumor, especially postoperative serum NO, IL-1 β and IL-6 levels, may improve the surgical effect and the well-being of patients (10,11). In this study, serum pain stress indicators were detected to evaluate the application value of VATS in the clinical treatment of mediastinal tumor in children.

Patients and methods

Clinical information. In this study, a retrospective analysis was performed on 82 children with mediastinal tumor undergoing operation in Children's Hospital Affiliated to Zhengzhou University (Zhengzhou, China) from January 2012 to January 2016, including 43 males and 39 females, aged 5-8 years. Of them, 48 children undergoing VATS were enrolled as the observation group and 34 children undergoing traditional thoracotomy were enrolled as the control group. Clinical records of the children in Children's Hospital Affiliated to Zhengzhou University, Henan Children's Hospital were recalled, and the basic clinical information was collected, including demographic data, lesion location and lesion diameter. This study was approved by the Ethics Committee of Children's Hospital Affiliated to Zhengzhou University, and the informed consent was signed by subjects' parents or their guardians.

Inclusion and exclusion criteria. Inclusion criteria (12): All the patients admitted were aged less than 14 years, and the mediastinal tumor was clinically diagnosed as positive by CT; the patients included and their family members were informed of the treatment and consented before operation. Exclusion criteria: Patients undergoing secondary mediastinal tumor resection; patients who refused to receive surgery; patients with a tumor that could not be completely resected with surgery or who were unable to receive resection surgery; patients who had undergone chemotherapy and radiotherapy before operation; patients who were unwilling to participate in this study or with understanding disorder; patients with severe cardiovascular disease, cardiac dysfunction, and abnormal lung function; patients with obvious intestinal obstruction in the gastrointestinal tract, and dilatation of the intestine; patients who were suffering from various types of hernia; patients with coagulopathy, massive ascites, internal bleeding, hepatitis, and obesity; patients who had other serious medical diseases, including hyperthyroidism, and diabetes; and patients who were unable to tolerate tube intubation were excluded.

Study methods. The mediastinal tumor resection was clinically carried out based on the clinical surgical guidelines (13)

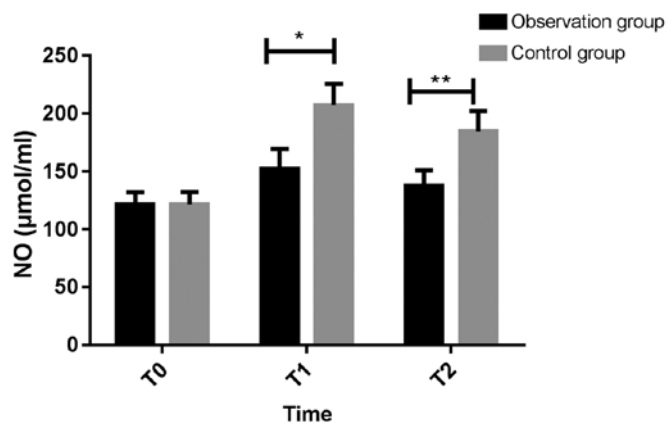


Figure 1. Changes in serum NO level before and after operation. Serum NO level in the control group was significantly higher than that in the observation group at T₁ and T₂, with statistically significant differences (*P<0.05 and **P<0.05). NO, nitric oxide; T₁, 12 h after operation; T₂, 24 h after operation.

in accordance with the specifications, with intraoperative operation time and blood loss and other clinical real-time data observed and recorded. The fasting venous blood from the children enrolled was collected before operation (T₀), at 12 h (T₁) and 24 h (T₂) after operation and sent for examination to detect serum with ELISA. The specific steps were as follows: the serum was separated at room temperature, stored at -70°C and then slowly defrosted at 37°C when used. An automatic biochemical analyzer and corresponding reagents (Mindray BS-220) were used to determine the expression levels of serum NO (KS10788; Shanghai Keshun Biological Technology Co., Ltd.), IL-1 β (HL10417; Shanghai Haling Biological Technology Co., Ltd.) and IL-6 (SBJ-H0465; Nanjing Senbeijia Biological Technology Co., Ltd.), with the above operations carried out in strict accordance with the instructions. The pain degree of the children at T₁ was observed, and then recorded using visual analogue scale (VAS) (14), and the length of stay and postoperative infection were recorded.

Statistical analysis. SPSS 20.0 statistical software package (Yonghong Technology Co., Ltd.) was used for processing the data. Measurement data were expressed as mean \pm standard deviation (mean \pm SD), and t-test was used for comparison between groups. Count data were expressed as percentage [n/(%)], and Chi-square test was used for comparison between groups. At P<0.05, the difference was considered statistically significant.

Results

Comparison of basic clinical information. In this study, 82 children with mediastinal tumor were enrolled as subjects and separated into the observation group (48 children) undergoing VATS and the control group (34 children) undergoing conventional thoracotomy according to operation methods. t-test and Chi-square test were used to analyze the clinical information. The results showed that the differences were not statistically significant in terms of age, sex or lesion between the two groups (P>0.05) (Table I). The two groups of patients were comparable.

Table I. Basic clinical information sheet of patients [mean \pm SD or n/(%)].

Items	Observation group (n=48)	Control group (n=34)	t/ χ^2 value	P-value
Sex			0.006	0.939
Male	25 (52.08)	18 (52.94)		
Female	23 (47.92)	16 (47.06)		
Age (years)	5.1 \pm 1.6	5.5 \pm 1.2	0.186	0.853
BMI (kg/m ²)	21.3 \pm 1.5	22.1 \pm 1.3	0.382	0.703
Lesion diameter (cm)	3.7 \pm 0.6	3.8 \pm 0.7	0.108	0.914
Tumor metastasis			0.009	0.909
Yes	12 (25.00)	8 (23.53)		
No	36 (75.00)	26 (76.47)		
Tumor type				
Neurogenic tumor	11 (22.92)	11 (32.35)	0.486	0.486
Teratoma	16 (33.33)	10 (29.41)	0.018	0.893
Thymoma	9 (18.75)	7 (20.89)	0.012	0.904
Others	12 (25.00)	6 (17.35)	0.272	0.602
Lesion location				
Anterior mediastinum	34 (70.83)	26 (76.48)	0.099	0.753
Middle mediastinum	9 (18.75)	4 (11.76)	0.299	0.585
Posterior mediastinum	5 (10.42)	4 (11.76)	0.088	0.918

Table II. Serum NO, IL-1 β and IL-6 levels before and after operation (mean \pm SD).

Indicators	Time	Observation group	Control group	t value	P-value
NO (normal range, 28.00-50.00 μ mol/ml)					
	T ⁰	121.63 \pm 10.65	121.56 \pm 10.78	0.0005	0.996
	T ¹	152.69 \pm 16.86	207.11 \pm 18.50	2.145	0.035
	T ²	137.35 \pm 13.66	184.60 \pm 17.28	2.168	0.033
IL-1 β (normal range, 0.01-0.25 pg/ml)					
	T ⁰	1.63 \pm 0.14	1.61 \pm 0.16	0.0934	0.926
	T ¹	2.45 \pm 0.21	3.25 \pm 0.27	2.371	0.020
	T ²	2.40 \pm 0.17	3.11 \pm 0.23	2.539	0.013
IL-6 (normal range, 1.00-3.00 pg/ml)					
	T ⁰	5.71 \pm 0.43	5.65 \pm 0.46	0.0936	0.926
	T ¹	8.39 \pm 1.23	12.87 \pm 1.53	2.300	0.024
	T ²	7.08 \pm 1.12	11.24 \pm 1.40	2.341	0.022

NO, nitric oxide; IL, interleukin; T₀, before operation; T₁, 12 h after operation; T₂, 24 h after operation.

Comparison of stress indicators after different operations. Pain stress indicators in the serum were detected at T₀ to T₂ after operation (Table II and Figs. 1-3). At T₀, there were no significant differences between the two groups with respect to NO, IL-1 β and IL-6 (P>0.05), which were lower in the observation group than those in the control group at T₁ and T₂, with statistically significant differences (P<0.05). The difference was the most significant at T₁ compared with that at T₀. It showed that VATS can effectively relieve postoperative pain thereby leading to less pain stress.

Intraoperative and postoperative clinical indicators of children in the two groups. The intraoperative and postoperative clinical data of children in the two groups were recorded, including operation time, intraoperative blood loss, and pain score at T₂ (Table III). Compared with the control group, the largest blade opening, intraoperative blood loss, drainage duration, length of stay and postoperative pain were significantly improved in the observation group (P<0.05), and the operation time was also shortened, indicating that VATS has a higher clinical application value for the clinical resection of mediastinal tumor in children within a certain range.

Table III. Clinically relevant indicators of children in the two groups (mean \pm SD).

Clinical information	Observation group (n=48)	Control group (n=34)	t value	P-value
Largest blade opening (cm)	5.13 \pm 0.48	15.32 \pm 3.46	3.442	0.0009
Operation time (min)	90.49 \pm 29.00	173.94 \pm 28.72	1.999	0.050
Intraoperative blood loss (ml)	81.99 \pm 30.28	172.37 \pm 32.64	1.996	0.049
Postoperative thoracic drainage duration (days)	2.56 \pm 0.47	4.03 \pm 0.57	1.997	0.049
Postoperative length of stay (days)	4.25 \pm 0.34	6.46 \pm 0.53	3.674	0.0004
VAS score at T ₂	2.93 \pm 0.66	5.37 \pm 0.63	2.530	0.013

VAS, visual analog scale; T₂, 24 h after operation.

Table IV. Comparison of infection.

Indicators	Infection (n=8)	No infection (n=74)	t value	P-value
NO (μ mol/ml)	107.62 \pm 15.74	86.93 \pm 8.24	6.079	<0.001
IL-1 β (pg/m)	6.32 \pm 1.58	3.06 \pm 0.79	9.868	<0.001
IL-6 (pg/m)	5.12 \pm 2.24	2.13 \pm 1.05	6.683	<0.001

NO, nitric oxide; IL, interleukin.

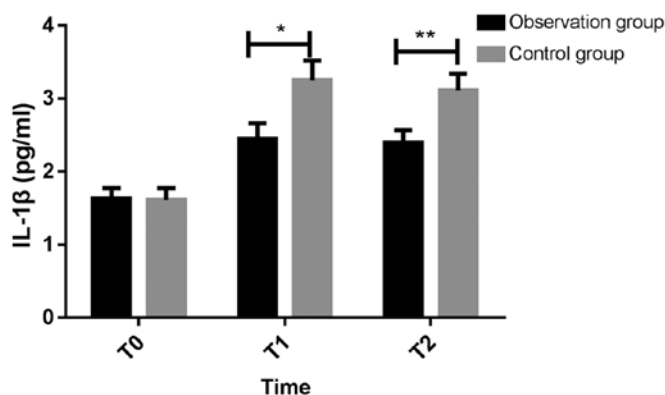


Figure 2. Changes in serum IL-1 β level before and after operation. Serum IL-1 β level in the control group was significantly higher than that in the observation group at T₁ and T₂, with statistically significant differences (*P<0.05 and **P<0.05). IL-1 β , interleukin-1 β ; T₁, 12 h after operation; T₂, 24 h after operation.

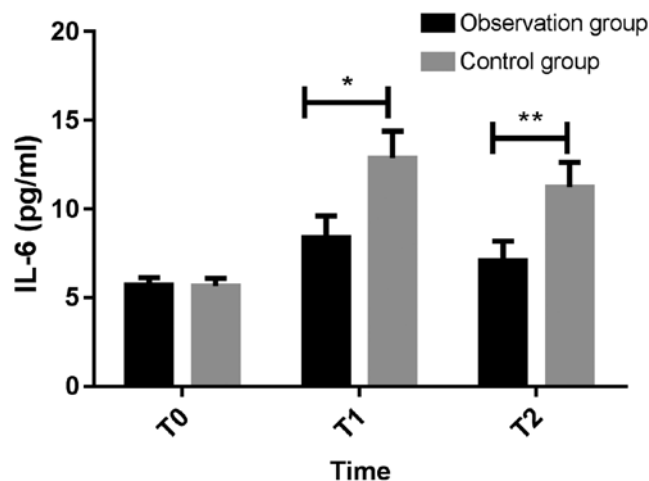


Figure 3. Changes in serum IL-6 level before and after operation. Serum IL-6 level in the control group was significantly higher than that in the observation group at T₁ and T₂, with statistically significant differences (*P<0.05 and **P<0.05). IL-6, interleukin-6; T₁, 12 h after operation; T₂, 24 h after operation.

Postoperative infection rate. The infection in children was recorded within 1 month after operation. The results showed that there were 8 cases of postoperative infection in the two groups. Two cases were in the observation group, and both cases were pulmonary infection. Six cases were in the control group, including 3 cases of wound infection, 1 case of pulmonary infection, and 2 cases of other infection. IL-1 β , NO and IL-6 were significantly higher in children with infection than those without infection (P<0.001) (Table IV).

Discussion

Due to the promotion of medical knowledge in recent years, people's awareness of minimally invasive surgery has gradually developed. For operation methods, most parents of children

with mediastinal tumor are more likely to choose VATS (15) that has a small wound area and non-direct contact operation, with low trauma and infection (16). However, VATS has some known and unknown adverse effects on the quality of operation. Therefore, paying close attention to the postoperative relevant indicators remains a hot issue in medical studies. It has been shown that (17) NO, IL-1 β and IL-6 are clinically common indicators for inflammatory pain stress, mainly because they can better reflect the contraction and relaxation of the smooth muscle during the inflammatory response. When the content exceeds a certain amount, they stimulate the muscle to contract and reflex, and reflect the pain in real time.

Because pediatric mediastinal tumor is not common in clinical practice, existing studies mainly focus on the comparison of the clinical efficacy of different treatment for mediastinal tumors. For example, Fuchs *et al* (18) proposed that the laparoscopic minimally invasive surgery has a good clinical effect in the treatment of mediastinal tumors, and Christison-Lagay *et al* (19) compared the effects of different openings on pediatric mediastinal tumors. The significance of the clinical indicators of postoperative pediatric mediastinal tumors is relatively rare. In this study, subjects were enrolled through rigorous inclusion of exclusion criteria. The differences between VATS and conventional thoracotomy in the treatment of children with mediastinal tumor were compared, and the significance of inflammatory factors NO, IL-1 β and IL-6 for perioperative period was analyzed, which provides reference for future clinical treatment of pediatric mediastinal tumors. Monitoring of common inflammatory factors may improve the quality of surgical treatment. In this study, serum NO, IL-1 β and IL-6 levels were used to investigate the adaptability of VATS or traditional thoracotomy to mediastinal tumors.

The results of the study showed that postoperative NO, IL-1 β and IL-6 levels in the observation group (VATS) were lower than those in the control group (conventional thoracotomy) ($P < 0.05$). Patients undergoing conventional thoracotomy have a stronger postoperative stress response than those undergoing VATS, suggesting that VATS can effectively reduce the postoperative pain in children. Under normal circumstances, the human body responds to external trauma, and operative trauma stimulates the patient to secrete NO, IL-1 β , IL-6 and other stress factors that stimulate the nerve ending and thereby shows pain once exceeding normal content (20,21). Rondón *et al* (22) have found that in the central nervous system, NO, glutamic acid and polyamines are commonly mediated by *N*-methyl-D-aspartate (NMDA) receptor, and the increase in NO enhances the sensitivity to pain in the body. Gopalsamy *et al* (11) reported that the inhibition of IL-1 β and IL-6 expression effectively inhibits the pain stress response. In the study of different operation methods for mediastinal tumor resection, Uchida *et al* (23) and Kamata *et al* (24) found that VATS is the first choice for tumor resection. In the present study, a judgement of pain stress indicators was added in the confirmation of results, which enhanced the real-time control of operation. The VAS score at T₂ also reflected that VATS was more suitable for children, and the pain value was lower in the observation group at T₂ ($P < 0.05$). This is because the operative trauma of VATS is weak and the recovery of children is better in a short time. The levels of NO, IL-1 β and IL-6 in patients with postoperative infection were significantly higher than those in patients without postoperative infection, suggesting that the future clinical monitoring of NO, IL-1 β and IL-6 concentrations in children can be used to judge the occurrence of perioperative infections, so the recovery of patients could be improved.

There is a study showing that painkillers reduce cytokine levels (25). In this study, children with a VAS score greater than 3 points were treated with 0.15-0.20% ropivacaine (initial dose, 6-10 ml; maintenance dose, 4-6 ml/h; aggressive dose: is 2-4 ml; the lockout time, 20-30 min; and the maximum dose, 12 ml/h). In this study, the analgesic dose was selected in reference to the study of Kim *et al* (26) who applied this dose in the investigation of children with lower extremity orthopaedic

surgery, which significantly reduced the pain of children and has extremely high application value. The VAS score at T₂ was 2.93 ± 0.66 in the observation group and 5.37 ± 0.63 in the control group. It can be seen that children in the control group generally take more analgesic drugs than those in the observation group, so NO, IL-1 β and IL-6 levels measured in the control group should be lower than their actual levels. However, postoperative NO, IL-1 β and IL-6 levels in the observation group were significantly lower than those in the control group, indicating that their levels in the observation group are significantly lower than the actual levels in the control group.

The study of VATS in children with mediastinal tumor is of great importance and value, and further in-depth research is expected. Of course, not all children with mediastinal tumor are suitable for VATS (27). For example, children with a large tumor area, tumor metastasis and proliferation and children who are too young (the body volume is too small) can only choose thoracotomy or chemotherapy. Therefore, the promotion of VATS in the clinic still needs to take the condition of the patient into consideration. Since the pathogenesis of pediatric mediastinal tumor is not completely clear, the exact mechanism of NO, IL-1 β , IL-6 in mediastinal tumor requires to be further explored. Because pediatric mediastinal tumor is not common, we are unable to expand the sample size, and the results could be slightly different with more subjects included.

In conclusion, compared with thoracotomy, VATS is more suitable for children with the disease, the recovery and infection of children could be monitored by detecting the inflammatory factors NO, IL-1 β , IL-6, which has a higher promotion value in clinical practice.

Acknowledgements

Not applicable.

Funding

No funding was received.

Availability of data and materials

The datasets used and/or analyzed during the present study are available from the corresponding author on reasonable request.

Authors' contributions

BZ drafted this manuscript. BZ, YZ and ZhenliangC were mainly devoted on collecting and interpreting the data. FY, XD and ZhongjianC performed ELISA. YC and PW helped with the pain degree of patients analysis. LS and WY were responsible for statistical analysis. All authors read and approved the final manuscript.

Ethics approval and consent to participate

The study was approved by the Ethics Committee of Children's Hospital Affiliated to Zhengzhou University (Zhengzhou, China). Signed informed consents were obtained from their parents or legal guardians.

Patient consent for publication

Not applicable.

Competing interests

The authors declare that they have no competing interests.

References

- Bohnenberger H, Dinter H, König A and Ströbel P: Neuroendocrine tumors of the thymus and mediastinum. *J Thorac Dis* 9 (Suppl 15): S1448–S1457, 2017.
- Siegel RL, Miller KD and Jemal A: Cancer statistics, 2018. *CA Cancer J Clin* 68: 7-30, 2018.
- Siddiqi MS, Al Badai Y, Al Kemyani NA and Al Kindi AH: Combined transcervical and thoracoscopic mediastinal parathyroid adenoma resection. *Asian Cardiovasc Thorac Ann* 24: 593-596, 2016.
- Chen L, Wang M, Fan H, Hu F and Liu T: Comparison of pediatric and adult lymphomas involving the mediastinum characterized by distinctive clinicopathological and radiological features. *Sci Rep* 7: 2577, 2017.
- Madariaga ML, Borges LF, Rabinov JD, Chang DC, Lanuti M, Mathisen DJ and Gaissert HA: Angiography before posterior mediastinal tumor resection: Selection criteria and patient outcomes. *Ann Thorac Surg* 105: 1000-1007, 2018.
- Jaramillo D: Soft tissue tumors in children. In: *Musculoskeletal Diseases 2017-2020*. Hodler J, Kubik-Huch R and von Schulthess G (eds). Springer, Cham, pp167-172, 2017.
- Zhang L, Liu X, Li X, Tang Z, Shi C and Wang G: Diagnosis and surgical treatment of mediastinal solitary fibrous tumor. *Asia Pac J Clin Oncol* 13: e473-e480, 2017.
- Clark A, Ozdirik J and Cao C: Thoracotomy, video-assisted thoracoscopic surgery and robotic video-assisted thoracoscopic surgery: Does literature provide an argument for any approach? *Video-assist Thorac Surg* 2: 21, 2017.
- Brodsky JB and Cohen E: Video-assisted thoracoscopic surgery. *Curr Opin Anaesthesiol* 13: 41-45, 2000.
- Waltz P, Escobar D, Botero AM and Zuckerbraun BS: Nitrate/nitrite as critical mediators to limit oxidative injury and inflammation. *Antioxid Redox Signal* 23: 328-339, 2015.
- Gopalsamy B, Farouk AA, Tengku Mohamad TA, Sulaiman MR and Perimal EK: Antiallodynic and antihyperalgesic activities of zerumbone via the suppression of IL-1 β , IL-6, and TNF- α in a mouse model of neuropathic pain. *J Pain Res* 10: 2605-2619, 2017.
- Baxter KJ, Gale BF, Travers CD, Heiss KF and Raval MV: Ramifications of the children's surgery verification program for patients and hospitals. *J Am Coll Surg* 226: 917-924.e1, 2018.
- Mayo JR, Clifton JC, Powell TI, English JC, Evans KG, Yee J, McWilliams AM, Lam SC and Finley RJ: Lung nodules: CT-guided placement of microcoils to direct video-assisted thoracoscopic surgical resection. *Radiology* 250: 576-585, 2009.
- Price DD, McGrath PA, Rafii A and Buckingham B: The validation of visual analogue scales as ratio scale measures for chronic and experimental pain. *Pain* 17: 45-56, 1983.
- Hanna AM and VanderWel B: Thoracoscopic approach to pediatric mediastinal masses. In: *The SAGES Manual of Pediatric Minimally Invasive Surgery*. Walsh D, Ponsky T and Bruns N (eds). Springer, Cham, pp239-259, 2017.
- Wang L, Liu D, Lu J, Zhang S and Yang X: The feasibility and advantage of uniportal video-assisted thoracoscopic surgery (VATS) in pulmonary lobectomy. *BMC Cancer* 17: 75, 2017.
- Thobakgale C, Naidoo K, McKinnon LR, Werner L, Samsunder N, Karim SA, Ndung'u T, Altfeld M and Naidoo K: Interleukin 1-beta (IL-1 β) production by innate cells following TLR stimulation correlates with TB recurrence in ART-treated HIV-infected patients. *J Acquir Immune Defic Syndr* 74: 213-220, 2017.
- Fuchs J, Schafbuch L, Ebinger M, Schäfer JF, Seitz G and Warmann SW: Minimally invasive surgery for pediatric tumors - current state of the art. *Front Pediatr* 2: 48, 2014.
- Christison-Lagay ER, Darcy DG, Stanelle EJ, Dasilva S, Avila E and La Quaglia MP: 'Trap-door' and 'clamshell' surgical approaches for the management of pediatric tumors of the cervicothoracic junction and mediastinum. *J Pediatr Surg* 49: 172-176, discussion 176-177, 2014.
- Mann E and Carr E: Pain management. In: *Foundation Studies for Caring: Using Student-Centred Learning*. Palgrave Macmillan, New York, NY, p259, 2018.
- Salman AH, Iqbal MN and Bakir WA: The *in situ* expression of IL-6 and IL-1 β in breast cancer patients. *Iraqi J Pharm Sci* 17: 55-62, 2017.
- Rondón LJ, Farges MC, Davin N, Sion B, Privat AM, Vasson MP, Eschalier A and Courteix C: L-Arginine supplementation prevents allodynia and hyperalgesia in painful diabetic neuropathic rats by normalizing plasma nitric oxide concentration and increasing plasma agmatine concentration. *Eur J Nutr* 57: 2353-2363, 2018.
- Uchida T, Matsubara H, Nagasaka S, Kina S, Ichihara T, Matsuoaka H and Nakajima H: Video-assisted thoracoscopic surgery can help enable the complete resection of a mediastinal tumor caused by immunoglobulin G4-related disease and avoid the need for postoperative medication: A case report. *Asian J Endosc Surg* 11: 248-251, 2018.
- Kamata T, Shiba M, Fujiwara T, Nagato K, Yoshida S, Inoue T and Iida T: Chylopericardium following thoracoscopic resection of a mediastinal cyst: A case report. *Int J Surg Case Rep* 39: 126-130, 2017.
- Wang LZ, Hu XX, Liu X, Qian P, Ge JM and Tang BL: Influence of epidural dexamethasone on maternal temperature and serum cytokine concentration after labor epidural analgesia. *Int J Gynaecol Obstet* 113: 40-43, 2011.
- Kim DH, Kim N, Lee JH, Jo M and Choi YS: Efficacy of preemptive analgesia on acute postoperative pain in children undergoing major orthopedic surgery of the lower extremities. *J Pain Res* 11: 2061-2070, 2018.
- Doğusoy I, Yıldırım M, Ustaalioglu R and Demirbağ H: A comparison of axillary thoracotomy versus video-assisted thoracoscopic surgery in the surgical treatment of primary spontaneous pneumothorax. *Turk Gogus Kalp Dama* 26: 132-137, 2018.



This work is licensed under a Creative Commons Attribution-NonCommercial-NoDerivatives 4.0 International (CC BY-NC-ND 4.0) License.