

## Case report

## Rare encounter: hydrocoele of canal of Nuck in a Scottish rural hospital during the COVID-19 pandemic

Michael Scott, Ahmed Hazem Helmy 

General Surgery, NHS Highland, Fort William, UK

Correspondence to Professor Ahmed Hazem Helmy; ahazem@aucegypt.edu

Accepted 31 July 2020

**SUMMARY**

We report the case of a 32-year-old woman who presented with reducible indirect inguinal hernia and a challenging constellation of symptoms, signs and radiographic findings. Surgical approach superseded conservative management when the patient's abdomen became acute, with a rising lactate and haemodynamic instability. Specifically, the presence of a fluid collection was concerning for sinister acute pathology. Our patient was rediagnosed intraoperatively with hydrocoele of canal of Nuck. This so-called 'female hydrocoele' is an eponymous anatomical rarity in general surgery, presenting as an inguinolabial swelling with variable clinical profile. Hydrocoele of canal of Nuck takes origin from failure of transitory reproductive anlagen to regress and is thus analogous to patent processus vaginalis. Its true incidence is speculative, with just several hundred cases globally. We aim to provide insights into surgical patient management for a rare entity during the COVID-19 outbreak, from the unique perspective of a small rural hospital in Scotland.

**BACKGROUND**

Hydrocoele of Nuck usually presents clinically as a painless to moderately tender, irreducible lump in the inguinolabial region. The presentation varies according to morphology, as well as unpropitious sequelae, and there is no single set of signs lending to a consistent clinical profile.<sup>1</sup> When encysted, or associated with infection or endometriosis, the swelling is severely painful and incarcerated inguinal hernia will be the primary differential diagnosis.<sup>2</sup>

Communicating hydrocoele and indirect inguinal hernia are caused by incomplete regression of the processus vaginalis, allowing either a patent channel to communicate with the peritoneum or formation of a potential space that is morphologically encysted.<sup>3-5</sup> Thus, the extent to which the hydrocoele traverses the canal depends on how much of the canal remains patent. Theoretically, the hydrocoele may be contiguous from deep inguinal ring to labium majus, or manifest as a cyst with rostral and caudal boundaries anywhere along this tract. The cysts seldom exceed 3 cm in length or a diameter of 0.5 cm.<sup>6,7</sup>

The incidence in female adults is estimated to be in the region of 400 globally.<sup>5,7</sup> That said, true incidence remains elusive and grossly underestimated as a result of misdiagnosis and under-reporting.<sup>8-11</sup>

**CASE PRESENTATION**

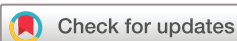This 32-year-old female sports instructor presented via her general practitioner for left iliac fossa bulge associated with lower abdominal pain without radiation. She was triaged for COVID-19 by our emergency department, having nil symptoms but stratifying as COVID-19 vulnerable because of complex asthma. The abdominal pain elapsed 4 days, but was progressively worsening in frequency and sharpness and associated with nausea but not vomitus. The bulge did not increase in size during this time; bowels were opening ordinarily and there were nil urinary symptoms.

There was a history of intractable asthma and recurrent ovarian cysts which had previously required gynaecological surgical intervention. Nine years prior, right oophorectomy was performed as part of an exploratory laparotomy and proceed for torsion of large dermoid cyst of ovary. Four years ago, she underwent laparoscopic adhesiolysis for ongoing dyspareunia and infertility. Cystectomy was also carried out on the remaining ovary in the interim under private healthcare. The final gynaecological encounter to date was in 2019, in which haemorrhagic left ovarian cyst was managed conservatively and spontaneously resorbed.

On examination, the inguinal bulge was superomedial to the pubic tubercle and behaved like a reducible indirect inguinal hernia. The hernia remained in place following manual reduction and there was no peristaltic activity, nor any associated vascularity. Observations and blood tests were entirely unremarkable. Simple analgesia brought effective pain relief and the patient was given a worsening statement before discharge.

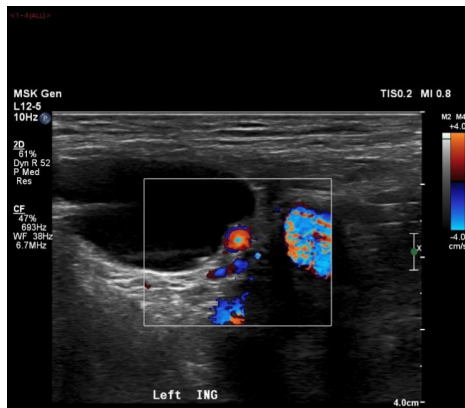This conservative approach was justified by virtue of elective surgery precautions during the COVID-19 pandemic. National guidelines have mandated minimising high-risk aerosol generating procedures including general anaesthesia and surgery. As such, elective surgery is deferred and only emergency surgery is being performed. At this stage, the patient was stratified for home management by a UK Government COVID-19 discharge to assess model.<sup>12</sup>

The patient returned by ambulance 24 hours later, this time hypotensive and feverish and now exquisitely painful in the lower abdomen. As she still had no symptoms suspicious for COVID-19, she was cohorted according to local adaptations of national policy in our rural hospital's 'green' (COVID-19 free) zone. Given the background of intractable asthma, cohorting also had the



© BMJ Publishing Group Limited 2020. No commercial re-use. See rights and permissions. Published by BMJ.

**To cite:** Scott M, Helmy AH. *BMJ Case Rep* 2020;**13**:e237169. doi:10.1136/bcr-2020-237169



**Figure 1** Transverse Doppler ultrasound scan demonstrating an anechoic, defined tubular cystic structure with a thin septation in the left inguinal region.

embedded benefit of conferring her protection as a COVID-19-vulnerable patient.

There was now distension in the inguinal region, which precluded appreciation of any discrete lump.

Pain was also more severe than the day prior, being controlled initially with Entonox and then requiring 5 mg intravenous morphine. Respiratory alkalosis and a rising lactate were notable findings on arterial blood gas. She was still afebrile with nil symptoms of COVID-19 and she was not peritonitic. The ensuing workup was templated against differential diagnoses including incarcerated hernia and adnexal abnormality in view of her medical history.

### INVESTIGATIONS

On day 1, ultrasound scan of the left inguinal region was convincing for inguinal hernia and negative for femoral hernia. (figure 1) Appearance was of a thin-walled cystic mass which did not change with Valsalva manoeuvre. Presence of bowel in the swelling was excluded, while the fluid component was tentatively interpreted as inflammation amidst scan limitations and clinical unfamiliarity.

When the patient represented to us 24 hours later, a negative beta-human chorionic gonadotropin (HCG) was ensured before investigation with abdominal X-ray. There were clear signs of heavy faecal loading without small bowel obstruction.

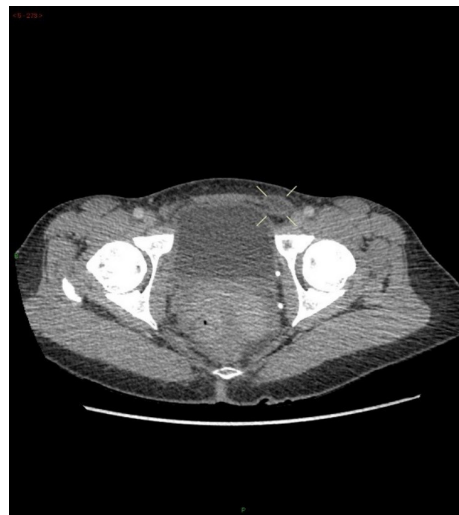CT abdomen and pelvis ruled out adnexal anomaly but further demonstrated the unexpected finding of free fluid in the left inguinal canal. While there was nil herniation of bowel contents, the fluid collection in the sac was now concerning for possible bowel perforation and an evolving peritonitis (figures 2 and 3).

100 mL oral gastrograffin was then administered to achieve duality of therapeutic effect and diagnosis, namely bowel clearance and to interrogate the bowel for any pathology or other cause of the fluid collection. No ostensible pathology was evident.

### TREATMENT

Due to clinical deterioration, informed consent was obtained for inguinal region exploration and mesh repair of the reducible left inguinal hernia.

Full personal protective equipment was donned and minimal personnel were present in theatre in accordance with joint National and Health Protection Society guidelines.<sup>12 13</sup>

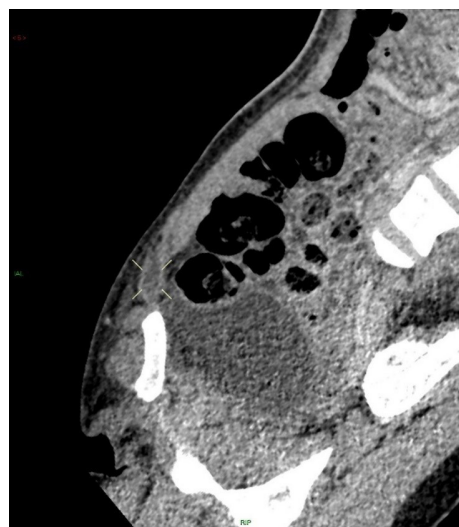


**Figure 2** Contrast enhanced axial CT scan demonstrating a non-enhancing fluid collection, located medially to the femoral vessels in the left inguinal canal.

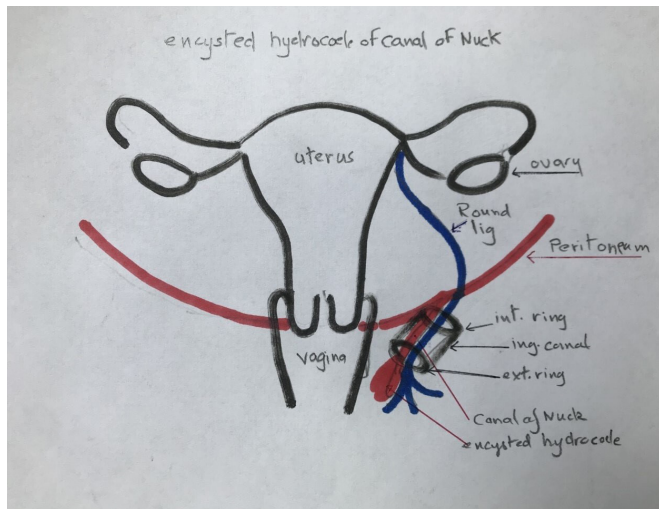
Spinal and regional anaesthesia was opted for instead of general anaesthesia to mitigate against unnecessary aerosol generating procedures and in view of the patient having complex asthma.

Surgical exploration of the left inguinal region revealed the presence of a small hernial sac. Surprisingly, a cystic lesion with dark fluid and size 2×2 cm was discovered, explaining the radiological findings. Thus, an intraoperative diagnosis of hydrocoele of canal of Nuck was made.

Surgical excision of the cystic hydrocoele was performed. The hydrocoele was easily ligated from proximal tissue planes and after total separation, high release of the canal of Nuck was performed, thereby facilitating excision of the cyst. Following herniotomy and excision of the sac, herniorrhaphy with tightening of the deep inguinal ring and hernioplasty was performed using large pore monofilament propylene mesh 10×5 cm for reinforcement of the posterior wall. Good haemostasis was achieved for the rest of the procedure.



**Figure 3** Contrast enhanced sagittal CT reconstructed image demonstrating a non-enhancing fluid collection located in the left inguinal canal, demonstrating no soft-tissue internal component.



**Figure 4** Hydrocoele of canal of Nuck diagram, demonstrating patent processus vaginalis with concomitant hydrocoele. The position of the hydrocoele varies anywhere from the superficial ring distally. Incomplete proximal and distal obliteration of the processus vaginalis will cause the hydrocoele to assume an encysted morphology. Illustrated independently by AH, corresponding author.

Postoperatively, we observed an uneventful recovery. The patient was discharged home the following morning with basic pain relief and instructions for wound care.

#### OUTCOME AND FOLLOW-UP

Our patient presented 10 days postoperatively with subcutaneous haematoma at the surgical wound site. This was drained in clinic and the wound was redressed. Prophylactic antibiotics were dispensed for 1 week. She recovered completely with no further attendances.

#### DISCUSSION

##### Embryological basis for hydrocoele of canal of Nuck

Hydrocoele and indirect inguinal hernia share a kindred aetiology in both sexes. This is demonstrated by tracing anatomy back to common fetal ontogeny, in which the processus vaginalis extends as a tubular outpouching of the peritoneal cavity and abdominal wall layers. The gonadal guide—an anlage called gaubernaculum—aids descent of the developing gonads to their final destinations in the pelvis or scrotum. The course is relatively shorter in women than men, with gaubernaculum regressing distally to leave the round ligament of uterus as a fetal remnant.<sup>14 15</sup> In men, the spermatic cord dominates the inguinal canal and this relatively greater spatial occupancy is responsible for an inguinal region that is more prone to hydrocoele and hernia. When there is incomplete obliteration of processus vaginalis, a communicating or non-communicating potential space is formed. In the former, an indirect inguinal hernia may develop.<sup>1</sup> In both, hydrocoele may develop, with mixed, communicating or cystic morphology (figure 4).<sup>3 6 7</sup>

##### The clinical profile of hydrocoele of canal of Nuck

Benali *et al*<sup>11</sup> have provided a narrative synthesis of hydrocoele of canal of Nuck using the literature base. There is no ostensible pattern regarding reducibility of the hernia, or whether or not it is painful.<sup>1 5 15 16</sup> The most frequent sign of Nuck hydrocoele is inguinolabial lump or swelling, rendering it clinically

indistinguishable from inguinal hernia.<sup>11 14</sup> Indeed, Matsumoto *et al*<sup>9</sup> coined the term ‘inguinal hernia mimic’ for hydrocoele of Nuck because of its changeable mass.<sup>9</sup>

Ultrasonography is the gold standard imaging for hydrocoele of canal of Nuck, with benefit derived from the live nature of the imaging. The presence of bowel can also be adequately confirmed or excluded in the hernial sac. Cardinal ultrasonographic signs include a homogenous, cystic, superficial mass which does not change with Valsalva manoeuvre.<sup>15 17 18</sup>

The intraoperative experience is also subject to variation. One demonstration is that cystic hydrocoele fluid content seems to differ, with Bhattacharjee and Ghosh<sup>19</sup> and Topal *et al*<sup>7</sup> having described a light or serous fluid, while Mandhan *et al*<sup>2</sup> and Matsumoto *et al*<sup>9</sup> had encountered dark fluid on rupture of the cyst, similar to our own case.<sup>2 7 9 19</sup> We found clinical and radiographic findings intriguing and unfamiliar, producing a diagnostic dilemma which was only resolved intraoperatively.<sup>20</sup>

#### Surgical management with COVID-19 considerations

We report successful implementation of COVID-19 guidelines in a rural surgical setting. Our scenario was complex, by virtue of our rurality, the COVID-19 pandemic and lastly the patient’s rapid decline with an indeterminate surgical diagnosis.

While our patient had nil COVID-19 symptoms, we favoured peripheral and neuraxial nerve blocks in order to minimise the overall burden of aerosol generating procedures. By opting for regional and spinal anaesthesia as opposed to general anaesthesia, our anaesthesia protocol spared bag and mask ventilation, endotracheal intubation and suctioning, all of which involve aerosolization and confer greater risk of respiratory secretion exposure and viral transmission.<sup>21 22</sup>

A commissioner report by the UK government in March 2020 acknowledged COVID-19 as an ‘unprecedented challenge’ for health and social care services.<sup>23</sup> We implemented pre-emptive measures to safeguard the well-being of acute patients, including the safe, streamlined discharge of non-emergency patients and strict conservation of high-risk procedures including surgery.<sup>12</sup> According to the WHO’s COVID-19 readiness checklist, such an approach is strategic for relieving pressure and creating additional hospital capacity for surge demand.<sup>22</sup> This is even more germane in a remote and rural hospital in the North of Scotland which has already experienced clusters of patients who are COVID-19 positive.

In accessory to the above, the ‘Hospital Discharge Service Requirements’ guidance was charted in tandem with Strategic Coordination Groups across the National Health Service. When our 32-year-old woman was clinically stable, our surgeon in charge entered her into ‘Pathway 1’ of the COVID-19 ‘Discharge to Assess Model’, which is a viable portal for an estimated 45% of patient influx in the UK. Here, the patient is fit for discharge with a short-term supported recovery at home. A responsible point of contact is agreed on, and the patient has a worsening statement to help facilitate further contact if needed.<sup>12 22</sup>

When our patient presented back to us with worsening condition, we promptly admitted and made the decision to operate after obtaining informed consent. The interface between conservative and emergency management is evident on day 1 versus day 2 and was justified by the guidelines. Crucially, COVID-19 guideline adherence was abided without simultaneously jeopardising patient safety.

## CONCLUSION

By raising awareness of this condition, general surgeons may append hydrocoele of canal of Nuck to their roster of differential diagnoses and spare their patients from overinvestigation.

Ultrasound remains the gold standard for imaging female hydrocoeles. The clinical profile is mutable and challenging to interpret; therefore, surgery is usually opted with the intention to repair a hernia.

Surgery simultaneously forms the definitive management of hydrocoele of canal of Nuck as well as providing an intraoperative, revised diagnosis. We have provided insight into surgery during pandemics from the unique perspective of a small yet busy Scottish rural hospital. With this exceptionally rare case, we demonstrate the feasibility of implementing COVID-19 strategies for surgical management of a patient belonging to a high-risk COVID-19 vulnerable subgroup.

## Learning points

- ▶ Inconsistent clinical profile and clinical unfamiliarity often preclude the preoperative diagnosis of hydrocoele of canal of Nuck.
- ▶ Radiology and ultrasonography findings distinguish hydrocoele of canal of Nuck from inguinal hernias.
- ▶ Surgery in pandemics: successful management of a rare surgical patient is possible with appropriate risk stratification and implementation of COVID-19 strategies.

**Acknowledgements** Special thanks to Radiographer Niall Lloyd for provision of images and reconstructions.

**Contributors** Both authors involved in preparation and review of the manuscript.

**Funding** The authors have not declared a specific grant for this research from any funding agency in the public, commercial or not-for-profit sectors.

**Competing interests** None declared.

**Patient consent for publication** Obtained.

**Provenance and peer review** Not commissioned; externally peer reviewed.

This article is made freely available for use in accordance with BMJ's website terms and conditions for the duration of the covid-19 pandemic or until otherwise determined by BMJ. You may use, download and print the article for any lawful, non-commercial purpose (including text and data mining) provided that all copyright notices and trade marks are retained.

## ORCID iD

Ahmed Hazem Helmy <http://orcid.org/0000-0002-3478-2990>

## REFERENCES

- 1 Sarkar S, Panja S, Kumar S. Hydrocoele of the canal of Nuck (female hydrocoele): a rare differential for Inguino-Labial swelling. *J Clin Diagn Res* 2016;10:PD21–2.
- 2 Mandhan P, Raouf Z, Bhatti K. Infected hydrocoele of the canal of nuck. *Case Rep Urol* 2013;2013:1–3.
- 3 Counseller VS, Black BM. Hydrocoele of the canal of NUCK. *Ann Surg* 1941;113:625–30.
- 4 Park P, Lee SR. Laparoscopic Intracorporeal Hydrocelectomy and posterior wall suture repair of the hydrocoele for the canal of Nuck. *J Clin Case Rep* 2017;7.
- 5 Ferreira AF, Marques JP, Falcão F. Hydrocoele of the canal of Nuck presenting as a sausage-shaped mass. *BMJ Case Rep* 2017;2017. doi:10.1136/bcr-2017-221024. [Epub ahead of print: 04 Oct 2017].
- 6 Rafailidis V, Varelas S, Apostolopoulou F, et al. Nonobliteration of the processus vaginalis. *Journal of Ultrasound in Medicine* 2016;35:805–18.
- 7 Topal U, Sarıtaş AG, Ülkü A, et al. Cyst of the canal of Nuck mimicking inguinal hernia. *Int J Surg Case Rep* 2018;52:117–9.
- 8 Huang C-S, Luo C-C, Chao H-C, et al. The presentation of asymptomatic palpable movable mass in female inguinal hernia. *Eur J Pediatr* 2003;162:493–5.
- 9 Matsumoto T, Hara T, Hirashita T, et al. Laparoscopic diagnosis and treatment of a hydrocoele of the canal of Nuck extending in the retroperitoneal space: a case report. *Int J Surg Case Rep* 2014;5:861–4.
- 10 Poghosyan T, Panzegrau B, Ackerman S. Hydrocoele of canal of Nuck. *Applied Radiology* 2014;37–8.
- 11 Benali F, Gooszen A, Wetzels C, et al. Cyst of Nuck: the importance of histopathological evaluation. *Obstet Gynecol Int J* 2020;5.
- 12 Reducing the risk of transmission of COVID-19 in the hospital setting, 2020. Available: <https://www.gov.uk/government/publications/wuhan-novel-coronavirus-infection-prevention-and-control/reducing-the-risk-of-transmission-of-covid-19-in-the-hospital-setting#standard-precautions> [Accessed 8 May 2020].
- 13 COVID-19 personal protective equipment (PPE), 2020. Available: <https://www.gov.uk/government/publications/wuhan-novel-coronavirus-infection-prevention-and-control/covid-19-personal-protective-equipment-ppe> [Accessed 21 Apr 2020].
- 14 Kono R, Terasaki H, Murakami N, et al. Hydrocoele of the canal of Nuck: a case report with magnetic resonance hydrography findings. *Surg Case Rep* 2015;1:86.
- 15 Patnam V, Narayanan R, Kudva A. A cautionary approach to adult female groin swelling: hydrocoele of the canal of Nuck with a review of the literature. *BMJ Case Rep* 2016;2016:bcr2015212547.
- 16 De Meulder F, Wojciechowski M, Hubens G, et al. Female hydrocoele of the canal of Nuck: a case report. *Eur J Pediatr* 2006;165:193–4.
- 17 Shadbolt CL, Heinze SB, Dietrich RB. Imaging of groin masses: inguinal anatomy and pathologic conditions revisited. *Radiographics* 2001;21 Spec No:S261–71.
- 18 Qureshi NJ, Lakshman K. Laparoscopic excision of cyst of canal of Nuck. *J Minim Access Surg* 2014;10:87.
- 19 Bhattacharjee PK, Ghosh G. Hydrocoele of the canal of Nuck. *J Indian Med Assoc* 2006;104:150–1.
- 20 Anderson CC, Broadie TA, Mackey JE, et al. Hydrocoele of the canal of Nuck: ultrasound appearance. *Am Surg* 1995;61:59–61.
- 21 Lie SA, Wong SW, Wong LT, et al. Practical considerations for performing regional anesthesia: lessons learned from the COVID-19 pandemic. *Can J Anaesth* 2020;67:885–92.
- 22 World Health Organisation Hospital Readiness Checklist For COVID-19, 2020. Available: [http://www.euro.who.int/\\_\\_data/assets/pdf\\_file/0010/430210/Hospital-Readiness-Checklist.pdf?ua=1](http://www.euro.who.int/__data/assets/pdf_file/0010/430210/Hospital-Readiness-Checklist.pdf?ua=1) [Accessed 19 Apr 2020].
- 23 HM UK Government. COVID-19 hospital discharge service requirements; 2020: 1–2 [Accessed 3 Apr 2020].

Copyright 2020 BMJ Publishing Group. All rights reserved. For permission to reuse any of this content visit <https://www.bmj.com/company/products-services/rights-and-licensing/permissions/> BMJ Case Report Fellows may re-use this article for personal use and teaching without any further permission.

Become a Fellow of BMJ Case Reports today and you can:

- ▶ Submit as many cases as you like
- ▶ Enjoy fast sympathetic peer review and rapid publication of accepted articles
- ▶ Access all the published articles
- ▶ Re-use any of the published material for personal use and teaching without further permission

## Customer Service

If you have any further queries about your subscription, please contact our customer services team on +44 (0) 207111 1105 or via email at [support@bmj.com](mailto:support@bmj.com).

Visit [casereports.bmj.com](http://casereports.bmj.com) for more articles like this and to become a Fellow