

Intravascular ultrasound imaging as a novel tool for the diagnosis of endofibrosis

Danielle Campbell, MD,^a Elizabeth Andraska, BS,^a John Rectenwald, MD,^b and Katherine Gallagher, MD,^a *Ann Arbor, Mich; and Dallas, Tex*

Given the rise of high-intensity sport athletes and the paucity of literature on endofibrosis, we describe a novel adjunctive imaging technique to aid in diagnosis. A 41-year-old female triathlete presented with exercise-limiting claudication. Results of lower extremity magnetic resonance angiography, provocative Doppler, angiogram, and digital subtraction angiography with papaverine were nondiagnostic. Intravascular ultrasound imaging was able to delineate an abnormal segment of the proximal external iliac artery with intimal hypertrophy. We report intravascular ultrasound imaging as a superior imaging modality to definitively diagnose endofibrosis and assist proper planning and operative treatment of patients with endofibrosis. (*J Vasc Surg Cases* 2016;2:59-61.)

Endofibrosis is a rare cause of lower extremity claudication in a healthy young adult.¹ Given the increase in the number of high-intensity athletes during the past decade, the prevalence of endofibrosis is steadily increasing, making this disease relevant to the practice of the modern vascular surgeon. The pathology involves hypertrophy of the intimal layer of the iliac vessels, seen usually in runners or cyclists, and results in intimal thickening that leads to stenosis and decreased blood flow during heavy exercise.² Symptoms occur only at maximal exertion.

Diagnosis has previously been described by provocative duplex examinations and angiography, sometimes with pressure gradients obtained across the proposed lesion with vasodilators to mimic the exercise state.³ Angiographic findings are generally subtle, and often, pharmacologically stimulating the high level of exercise needed to induce symptoms in these patients may not be possible. The patient consented to the publication of this report in which we found the use of intravascular ultrasound (IVUS) imaging as a diagnostic tool to aid in the diagnosis of endofibrosis. We believe that IVUS imaging is superior to the other traditional modalities used for the diagnosis of this disease. In this report, we introduce the use of IVUS to definitively diagnose intimal thickening and

endofibrosis, which leads to appropriate operative planning and surgical treatment.

CASE REPORT

A 43-year-old woman with exercise-limiting left lower extremity claudication presented for evaluation. She was a competitive long-distance runner who began to experience symptoms while running uphill or >1 mile during the past year. The patient's medical and surgical histories were unremarkable. She had no family history of vascular disease, musculoskeletal injuries, or congenital defects. She was a nonsmoker with no classic risk factors for vascular disease. Physical examination revealed equally palpable femoral and distal lower extremity pulses, no psoas muscle hypertrophy, and results of the laboratory evaluation were unremarkable.

We obtained bilateral pulse volume recordings, segmental pressures, and ankle-brachial indices (ABIs), which were within normal reference ranges at rest. Exercise on a treadmill at an 8-mph pace on 10% incline induced symptoms and provided evidence of demand ischemia, with the left ABI dropping from 1.06 to 0.66.

Provocative noninvasive imaging by Doppler with triphasic waveforms remaining in dorsiflexion, plantar flexion, and knee hyperextension and magnetic resonance angiography (MRA) were done to rule out popliteal entrapment and cystic adventitial disease. Neither showed evidence of extrinsic compression or iliac stenosis. Given the patient's persistent symptoms and left lower extremity demand ischemia evidenced on exercise ABIs, a diagnostic angiogram was performed. This demonstrated a focal yet subtle stenosis of the proximal external iliac artery just distal to the iliac bifurcation. Intraluminal pressures were obtained across the lesion, with and without the administration of intra-arterial papaverine, which demonstrated no transitional gradient (Fig 1).

Because we had a continued suspicion for endofibrosis with limited angiographic evidence, we used IVUS to evaluate for thickening of the arterial intima in the proposed diseased segment compared with normal vessel proximally and distally. As evidenced in Fig 2, there was significant arterial thickening in the area of question: the luminal diameter narrowed from 10 mm to 4.5 mm at the segment of greatest intimal hypertrophy.

From the Section of Vascular Surgery, Department of Surgery, University of Michigan, Ann Arbor^a; and the Section of Vascular Surgery, Department of Surgery, University of Texas Southwestern Medical Center, Dallas.^b

Author conflict of interest: none.

Presented at the 2014 Winter Annual Meeting of the Peripheral Vascular Surgery Society, Steamboat Springs, Colo, January 30-February 2, 2014.

Correspondence: Katherine Gallagher, MD, 5463 Cardiovascular Center, 1500 E. Medical Center Dr, Ann Arbor, MI 48109-5867 (e-mail: kgallag@med.umich.edu).

The editors and reviewers of this article have no relevant financial relationships to disclose per the Journal policy that requires reviewers to decline review of any manuscript for which they may have a conflict of interest.

2352-667X

© 2016 The Authors. Published by Elsevier Inc. on behalf of Society for Vascular Surgery. This is an open access article under the CC BY-NC-ND license (<http://creativecommons.org/licenses/by-nc-nd/4.0/>).

<http://dx.doi.org/10.1016/j.jvsc.2016.03.007>

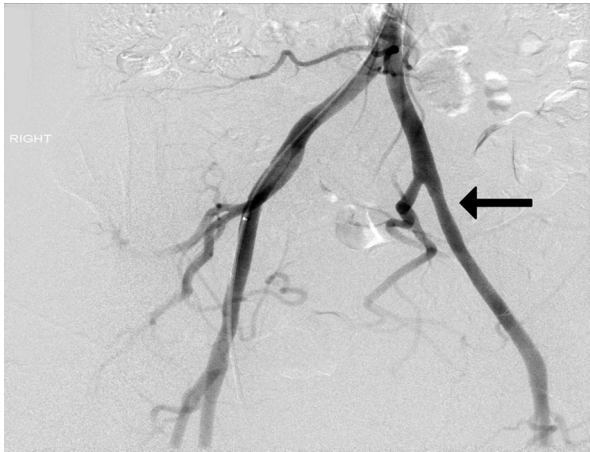


Fig 1. Angiogram of affected vessel after administration of papaverine demonstrates no obvious stenosis or lesion defect (*arrow*).

After discussion of risks and benefits, the patient elected to undergo left external iliac replacement with a reversed saphenous interposition graft via a retroperitoneal approach. No complications occurred. The specimen demonstrated significant intimal thickening on gross pathology (*Fig 3*). Postoperative duplex demonstrated a patent bypass with no elevated velocities. At the 6-month follow-up, the patient had resolving symptoms and improved exercise ABI. The patient has now been monitored for 3 years and has run several marathons without difficulty.

DISCUSSION

Endofibrosis is a rare problem seen in young, healthy, endurance athletes. The differential diagnosis to consider in a young patient with lower extremity claudication pain

includes atherosclerosis, chronic compartment syndrome, cystic adventitial disease, persistent sciatic artery, popliteal entrapment syndrome, and endofibrosis. Owing to the rarity of endofibrosis, incidence of the disease is not well known or characterized.^{1,2,4} It is most extensively reported in competitive cyclists but can also affect other high-endurance athletes.¹

The condition is characterized by progressive thickening of the intimal layer in the vessel wall with loose connective tissue with variable amounts of collagen, elastin, and smooth muscle cells.⁵ Chronically, this causes stenosis, vessel kinking, and impaired flow.² Endofibrosis affects the external iliac artery in 90% of cases.² It is described as a primarily unilateral claudication but can be bilateral in up to 15% of cases.⁴

Current literature suggests the etiology is most likely due to local mechanical factors such as the position of the athlete. Repetitive hyperflexion of the hip stimulates fibrotic changes within the vessel.³ The repeated flexion may affect the adjacent fascia and prevent the iliac vessel from moving freely, rendering it susceptible to traumatic injury during exercise.² Athletes may also develop hypertrophy of the psoas muscle over time, which stretches the iliac artery and creates mechanical stress that predisposes to fibrotic injury.³ Although mechanical stress seems most likely, investigators have also suggested systemic factors for the cause of endofibrosis because most affected individuals display metabolic variations such as methionine metabolism abnormalities.⁶

A variety of imaging modalities are suggested for the diagnosis of endofibrosis, but none provide consistent, definitive diagnosis. ABIs provide helpful data when evaluating an athlete with claudication, and discrepancies in ABIs between one leg and the other after exercise provide

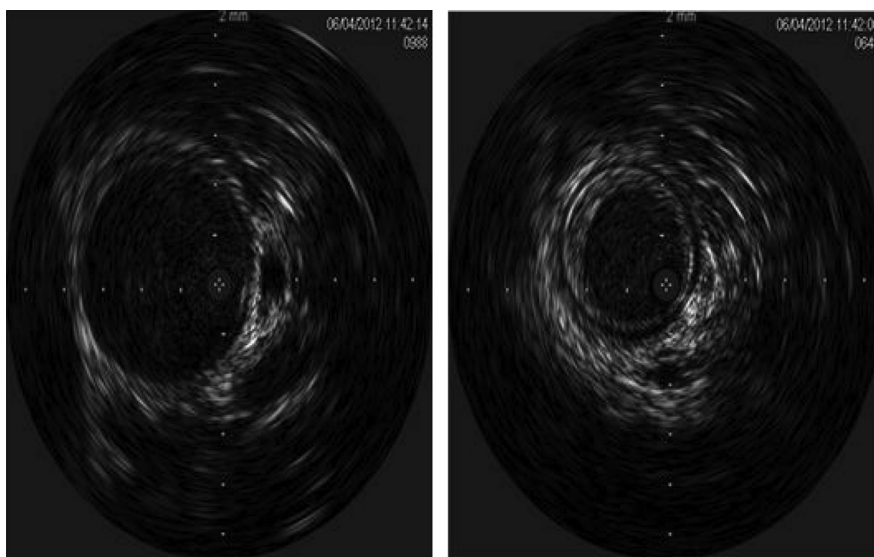


Fig 2. Intravascular ultrasound (IVUS) imaging differentiated (*left*) a normal segment of proximal iliac artery from (*right*) a section of proximal iliac artery that demonstrated intimal hypertrophy.

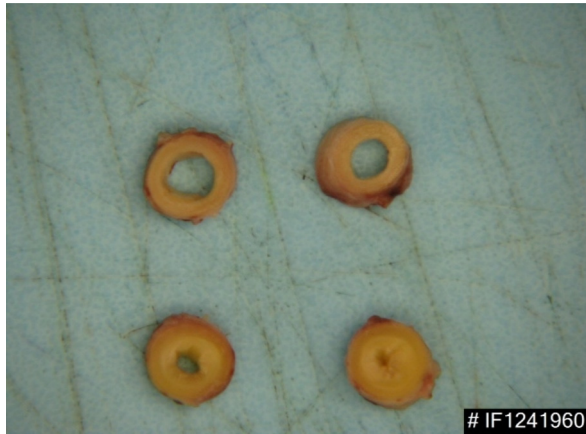

Fig 3. Gross pathology demonstrated obvious intimal thickening in a portion of the (**bottom**) proximal iliac artery compared with (**top**) a normal segment of the proximal iliac artery.

a sensitivity of 73% to 100%.² Duplex US imaging is a useful tool in assessing anatomic abnormalities and changes in flow due to affected vessels. Sensitivity with duplex imaging is reported to be as high as 86%; however, this was only achieved in patients with advanced disease.^{7,8} Furthermore, duplex imaging is operator dependent and requires precise positioning to reproduce the claudication.

MRA is useful in the detection of flow abnormalities.⁴ However, kinked vessels in endofibrosis have been suggested to cause significant movement during MRA, rendering it less useful due to movement artifact.²

Digital subtraction angiography is also used to visualize flow-limiting lesions. The calculated pressure gradient is most useful for diagnosis when vasodilators are administered, mimicking exercise physiology, because most affected patients show normal flow physiology at rest. Pharmacologic vasodilation with digital subtraction angiography identifies stenosis in the external iliac artery with 54% sensitivity.⁹ Often in these extreme athletes, reproducing their high degree of physiologic stress can be difficult. With such significant potential for false-negative results, an alternative imaging modality is needed. Furthermore, an imaging technique that specifically captures intimal thickening is required to differentiate endofibrosis from other forms of lower extremity claudication.

In this report, we suggest IVUS as an alternative and potentially more definitive diagnostic imaging modality in the diagnosis of endofibrosis. IVUS provides in vivo

histologic information regarding the vessel wall and associated lesions. Unlike other imaging techniques, IVUS distinguishes the three layers of muscular arteries based on different echogenicity.¹⁰ Therefore, unlike the aforementioned imaging, IVUS has the ability to differentiate lesions causing endofibrotic claudication by identifying intimal thickening, making it a useful adjunct to definitively diagnose endofibrosis in highly conditioned athletes where provocative angiography may not be able to detect this pathogenesis.

CONCLUSIONS

Endofibrosis is an uncommon disease seen in high-endurance athletes. IVUS is a novel imaging modality that provides a definitive diagnosis that allows for proper planning and operative treatment of these patients.

REFERENCES

1. Ford S, Rehman A, Bradbury A. External iliac endofibrosis in endurance athletes: a novel case in an endurance runner and a review of the literature. *Eur J Vasc Endovasc* 2003;26:629-34.
2. Peach G, Schep G, Palfreeman R, Beard J, Thompson M, Hinchliffe R. Endofibrosis and kinking of the iliac arteries in athletes: a systematic review. *Eur J Vasc Endovasc* 2012;43:208-17.
3. Lindner D, Agar G, Domb B, Beer Y, Shub I, Mann G. An unusual case of leg pain in a competitive cyclist: a case report and review of the literature. *Sports Health* 2014;6:492-6.
4. Lim C, Gohel M, Shepherd A, Davies A. Iliac artery compression in cyclists: mechanisms, diagnosis and treatment. *Eur J Vasc Endovasc* 2009;38:180-6.
5. Giannoukas A, Berczi V, Anoop U, Cleveland T, Beard J, Gaines P. Endofibrosis of iliac arteries in high-performance athletes: diagnostic approach and minimally invasive endovascular treatment. *Cardiovasc Intervent Radiol* 2006;29:866-9.
6. Feugier P, Chevalier J. Endofibrosis of the iliac arteries: an underestimated problem. *Acta Chir Belg* 2004;104:635-40.
7. Abraham P, Leftheriotis G, Bourre Y, Chevalier J, Saumet J. Echography of external iliac artery endofibrosis in cyclists. *Am J Sports Med* 1993;21:861-3.
8. Schep G, Schmikli S, Bender M, Mosterd W, Hammacher E, Wijn P. Recognising vascular causes of leg complaints in endurance athletes. Part I: validation of a decision algorithm. *Int J Sports Med* 2002;23:313-21.
9. Alimi Y, Accrocca F, Bathclemey P, Hartung O, Dubuc M, Boufi M. Comparison between duplex scanning and angiographic findings in the evaluation of functional iliac obstruction in top endurance athletes. *Eur J Vasc Endovasc* 2004;28:513-9.
10. Gussenhoven E, Essed C, Frietman P, Van Egmond F, Lancee C, Van Kappellen W, et al. Intravascular ultrasonic imaging: histologic and echographic correlation. *Eur J Vasc Surg* 1989;3:571-6.

Submitted Feb 7, 2016; accepted Mar 23, 2016.