

Tubercular Osteomyelitis Mimic Ewing's Sarcoma

Sudarshan Pavan¹, Arvind¹, Aayush Arora¹, Guruchetan Singh¹

Learning Point of the Article:

Tubercular osteomyelitis may sometime mimic Ewing's sarcoma radiologically.

Abstract

Introduction: Ewing's sarcoma in children is an extremely rare malignant tumor that is frequently challenging to identify. In addition to its rarity in young children, Ewing's sarcoma can resemble an infectious disease, contributing to diagnostic delay. Both conditions have similar presenting symptoms, such as general weakness, pain, and fever.

Case Report: We present a case of a 13-year-old girl with pain over the right distal humerus for 2 months. X-ray findings showed lesions over the distal humerus which led to a differential diagnosis of osteomyelitis and Ewing's sarcoma. The patient underwent bone biopsy and was diagnosed with tuberculous osteomyelitis and was managed conservatively in the form of antituberculosis treatment.

Conclusion: For distinguishing Ewing's sarcoma from osteomyelitis, imaging modalities can be unreliable, and these patients require a higher diagnostic yield in the form of a bone biopsy for greater accuracy.

Keywords: Osteomyelitis, Ewing's sarcoma, young children.

Introduction

Ewing's sarcoma and infections both have similar routine investigation because leukocyte counts and erythrocyte sedimentation rates (ESR) show irregular elevations in both. Blood and tissue cultures may be sterile [1]. Atypical cases necessitate additional testing to rule out major differentials such as bone infection and skeletal tumors.

The modality of choice for investigation is magnetic resonance imaging (MRI), and the assessment is determined through a combination of clinical and radiological follow-up to illustrate relapsing and remitting incidents [2]. However, distinguishing osteomyelitis from bone tumors remains difficult, particularly in long bones. Often, only after carefully examining the histologic

characteristics of the lesions can a diagnosis be made. Unless tubercular osteomyelitis is promptly recognized and treated, it can be devastating with a high percentage of sequelae, particularly in resource-poor countries where patients present with advanced disease and survivors frequently have serious and long-term complications. Acute bone infection in children is most commonly caused by an hematogenous source [3].

We present a case of a 13-year-old female who presented with symptoms and investigations suggestive of osteomyelitis. This case also revealed histology suggestive of chronic osteomyelitis and was negative for malignancy. Despite negative microbiologic cultures, treatment was commenced on a presumptive diagnosis of osteomyelitis. The patient's condition responded to antibiotic

Author's Photo Gallery



Dr. Sudarshan Pavan



Dr. Arvind



Dr. Aayush Arora



Dr. Guruchetan Singh

Access this article online

Website:
www.jocr.co.in

DOI:
<https://doi.org/10.13107/jocr.2023.v13.i12.4060>

¹Department of Orthopaedic Surgery, Tata motors hospital, Jamshedpur, Jharkhand, India.

Address of Correspondence:

Dr. Aayush Arora,
Department of Orthopaedic Surgery, Tata Motors Hospital, Jamshedpur, Jharkhand, India.
E-mail: ayush.arora52@gmail.com

Submitted: 15/09/2023; Review: 01/10/2023; Accepted: November 2023; Published: December 2023

DOI: <https://doi.org/10.13107/jocr.2023.v13.i12.4060>

This is an open access journal, and articles are distributed under the terms of the Creative Commons Attribution-NonCommercial-ShareAlike 4.0 License <https://creativecommons.org/licenses/by-nc-sa/4.0/>, which allows others to remix, tweak, and build upon the work non-commercially, as long as appropriate credit is given and the new creations are licensed under the identical terms



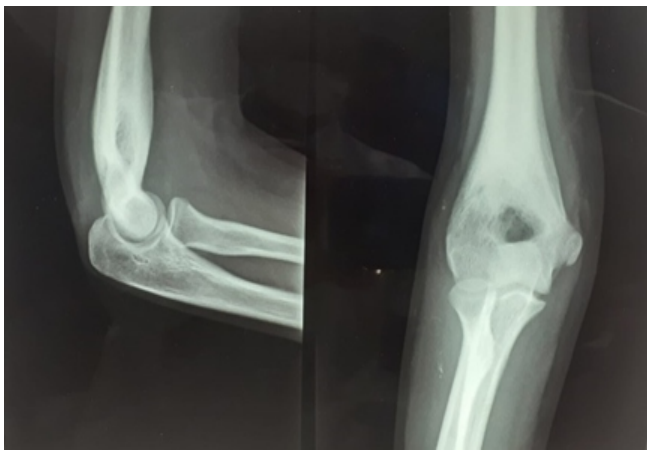


Figure 1: X-ray of right elbow joint AP and lateral view.

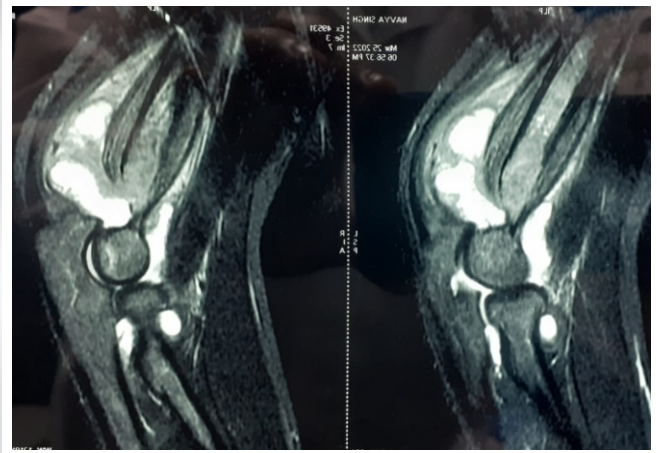


Figure 2: Magnetic resource imaging of right elbow joint.

therapy and improved.

Case Report

A 13-year-old patient presented to the outpatient department with a chief complaint of pain and swelling in the right elbow for 2 months. The patient was examined clinically and had tenderness over the lower aspect of the right arm. Radiograph of the right elbow was done in anteroposterior and lateral view which showed cortical thickening and periosteal reaction over the distal humerus (Fig. 1).

MRI of the right elbow showed synovial thickening, marked joint effusion, and periosteal reaction measuring up to 7.3 mm extending into medial and lateral epicondyle. Moderate periarticular muscle edema was seen due to inflammation (Fig. 2).

The patient was planned for a bone biopsy from the right distal humerus over the site of lesion. Bone biopsy revealed caseous necrosis, Langhans giant cells, mononuclear infiltrate suggestive of tuberculous osteomyelitis (Fig. 3).

Discussion

Children and young adults are the most commonly affected by chronic osteomyelitis. It is distinguished by sclerotic osseous lesions in the absence of a noticeable causative organism or tumor. Long bone metaphyses are those that are most frequently affected. The clavicle and spine are also seen as being involved. The disease has a slow onset and a protracted course. Patients tend to experience repeated pain episodes. The test results are sometimes non-specific but they do point to an inflammatory process. Elevated ESR, alkaline phosphatase, and C-reactive proteins (CRPs) are all illustrations of abnormal laboratory tests. The patient will almost never have an irregular

white blood cell count [4].

Early differentiation between chronic osteomyelitis and a tumor of the bone is critical for rapid and suitable management [5]. Children with osteomyelitis usually have clinical signs 3–4 days before disease presentation. According to Abdi et al, infection is much more prevalent in the lower limbs than the upper limbs, with the femur (27%), tibia (22%), and humerus (12%) being the most frequently affected sites. The involvement of a single bone is more frequent than multifocal involvement. More than half of all cases involve children below the age of five. Patients with pain, swelling, fever, and pathological fractures with fever are related to the dissemination of disease.

X-rays show lytic destruction and the formation of subperiosteal new bone. These non-specific findings can occur in a variety of conditions, including metastatic carcinoma, malignant lymphoma, and osteomyelitis, requiring a biopsy to verify the diagnosis. Several cases of Ewing's sarcoma being misdiagnosed as osteomyelitis have been reported. Misdiagnoses have been attributed to a lack of suspicion, occurrence at an unusual site, and inadequate histologic specimens [6]. On radiological evaluation, we (the World Health Organization) discovered that involvement of the metaphyseal region is more frequent in patients with Ewing's sarcoma compared to those with bony osteomyelitis. In children with a lesion on the diaphysis and clinical manifestations of osteomyelitis, a biopsy of the lesion is required to make an unambiguous diagnosis [7]. In comparison to bone tumors, osteomyelitis did not have a high level of alkaline phosphatase above an age-appropriate level [8]. Until culture outcomes are accessible, real-time polymerase chain reaction could help guide antibiotic treatment [9]. A few recent researchers advocate the use of procalcitonin and another

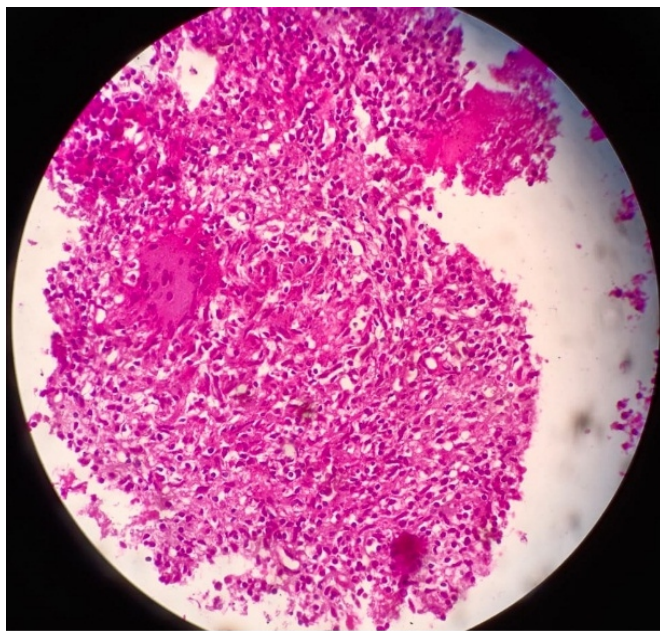


Figure 3: Microscopic illustration of lesion over right elbow.

inflammatory marker, but we doubt it adds anything to CRP, which is less expensive and easier and faster to measure [10].

Conclusion

For an accurate and timely diagnosis of *Mycobacterium tuberculosis* osteomyelitis, a high level of clinical suspicion is required. The role of imaging modalities in distinguishing a benign lesion from an infective lesion is limited. As a result, biopsies play an important role in the early diagnosis and management of these patients.

Clinical Message

Chronic tubercular osteomyelitis should always be considered as a differential diagnosis in cases appearing to be Ewing's sarcoma clinically and radiologically.

Declaration of patient consent: The authors certify that they have obtained all appropriate patient consent forms. In the form, the patient has given the consent for his/ her images and other clinical information to be reported in the journal. The patient understands that his/ her names and initials will not be published and due efforts will be made to conceal their identity, but anonymity cannot be guaranteed.

Conflict of interest: Nil **Source of support:** None

References

1. Durbin M, Randall RL, James M, Sudilovsky D, Zoger S. Ewing's sarcoma masquerading as osteomyelitis. *Clin Orthop Relat Res* 1998;357:176-85.
2. Nepal P, Alam SI, Sajid S, Sapire J, Ojili V. Rare presentation of chronic recurrent multifocal osteomyelitis of the Iliac wing mimicking Ewing's sarcoma. *SAJ Radiol* 2021;25:2030.
3. Peltola H, Pääkkönen M. Acute osteomyelitis in children. *N Engl J Med* 2014;370:352-60.
4. Bracamonte JD, Roberts CC. Chronic recurrent multifocal osteomyelitis mimicking osteosarcoma. *Radiol Case Rep* 2006;1:42-6.
5. Shimose S, Sugita T, Kubo T, Matsuo T, Nobuto H, Ochi M. Differential diagnosis between osteomyelitis and bone tumors. *Acta Radiol* 2008;49:928-33.
6. Abdi R, Taheri MM. A case report of Ewing's sarcoma of tibial epiphysis with retrobulbar mass. *J Surg Trauma* 2015;3:23-5.
7. Tountas AA, Kwok JM. Acute hematogenous diaphyseal osteomyelitis in childhood. *Can Med Assoc J* 1985;132:1287-8.
8. Shimose S, Sugita T, Kubo T, Matsuo T, Nobuto H, & Ochi M. Differential diagnosis between osteomyelitis and bone tumors. *Acta Radiologica*, 2008;49(8):928-33. Doi:10.1080/02841850802241809.
9. Arkader A, Brusalis C, Warner WC Jr, Conway JH, Noonan K. Update in pediatric musculoskeletal infections: When it is, when it isn't, and what to do. *J Am Acad Orthop Surg* 2016;24:e112-21.
10. Pääkkönen M, Peltola H. Simplifying the treatment of acute bacterial bone and joint infections in children. *Expert Rev Anti Infect Ther* 2011;9:1125-31.

Conflict of Interest: Nil
Source of Support: Nil

Consent: The authors confirm that informed consent was obtained from the patient for publication of this case report

How to Cite this Article

Pavan S, Arvind, Arora A, Singh G. Tubercular Osteomyelitis Mimic Ewing's Sarcoma. *Journal of Orthopaedic Case Reports* 2023 December;13(12): 18-20.