

Subependymal Giant Cell Astrocytoma: Associated Hyperproteinorrhachia Causing Shunt Failures and Nonobstructive Hydrocephalus - Report of Successful Treatment with Long-term Follow-up

Abstract

Subependymal giant cell astrocytomas (SEGAs) are histologically benign tumors most frequently associated with tuberous sclerosis complex (TSC). Despite their benign histopathological appearance, they may cause unfavorable outcomes due to their intraventricular location. Rarely, SEGA may be associated with hyperproteinorrhachia (high levels of proteins in the cerebrospinal fluid [CSF]), which causes malresorptive, communicating hydrocephalus; certainly, this scenario makes shunt obstruction likely in this patient population. In this report, we illustrate the case of hyperproteinorrhachia in an SEGA patient with known TSC, who presented repeatedly with shunt failure from proteinaceous shunt obstruction. Subsequent surgical resection of the main intraventricular lesion resulted in a dramatic drop in the CSF protein levels and has since prevented further shunt failures. Different treatment concepts and possible pathophysiology are discussed and the pertinent literature is reviewed.

Keywords: Communicating hydrocephalus, hyperproteinorrhachia, subependymal giant cell tumor, tuberous sclerosis

Introduction

Tuberous sclerosis complex (TSC) was first described as a multisystem disorder by Bourneville in the late 1800s.^[1,2] Mutation causes TSC in one of two tumor suppressor genes TSC1 (9q34; Hamartin) and TSC2 (16p13; Tuberin).^[3-5] Radiographically, TSC patients present with three distinct intracranial lesions: subcortical tubers, subependymal nodules, and subependymal giant cell astrocytomas (SEGAs). Although SEGA has been reported to grow in the absence of TSC,^[6,7] it is most frequently found in TSC and occur in 5%–20% of TSC patients.^[4,8-10] In spite of histopathological benign characteristics, SEGAs can cause a variety of severe clinical symptoms that may substantially increase the mortality and morbidity of TSC patients. This is due to their preferential proximity to the foramen of Monro, which can be blocked during tumor growths, causing obstructive hydrocephalus. Although the related symptoms can be relieved by shunt insertion, especially in the acute setting, the current standard management

of symptomatic SEGA is surgical resection.^[11]

One of the arguments against shunt placement as the initial treatment is that abnormally high levels of cerebrospinal fluid (CSF) protein (hyperproteinorrhachia) in nonresected SEGAs may lead to obstruction of CSF diversion devices in shunted patients. However, only a few reports actually describe this phenomenon.^[12-14]

Here, we illustrate the beneficial and long-term effects of resecting the tumor in a symptomatic TSC patient afflicted by such hyperproteinorrhachia – associated SEGA presenting with multiple recurrent shunt failures from valve obstruction due to high CSF protein levels before open resection.

Case Report

An 18-year-old female patient was diagnosed with tuberous sclerosis at an early age. Seizures were her initial neurological symptoms, associated with some developmental delay and progressively emerging mental retardation.

**Ekkehard Kasper,
Yosef Laviv,
Mohammed-Adeeb
E. Sebai,
Ning Lin¹,
William Butler¹**

*Department of Surgery,
Beth Israel Deaconess
Medical Center, Division
of Neurosurgery, Harvard
Medical School, ¹Department
of Neurosurgery, Massachusetts
General Hospital,
Harvard Medical School,
Boston, MA, USA*

Address for correspondence:

*Dr. Yosef Laviv,
Department of Surgery,
Beth Israel Deaconess
Medical Center, Division of
Neurosurgery, Harvard Medical
School, Boston, MA, USA.
E-mail: ylaviv@
bidmc.harvard.edu*

Access this article online

Website: www.asianjns.org

DOI: 10.4103/ajns.AJNS_231_16

Quick Response Code:



How to cite this article: Kasper E, Laviv Y, Sebai MAE, Lin N, Butler W. Subependymal giant cell astrocytoma: Associated hyperproteinorrhachia causing shunt failures and nonobstructive hydrocephalus - Report of successful treatment with long-term follow-up. *Asian J Neurosurg* 2017;12:746-50.

This is an open access article distributed under the terms of the Creative Commons Attribution-NonCommercial-ShareAlike 3.0 License, which allows others to remix, tweak, and build upon the work non-commercially, as long as the author is credited and the new creations are licensed under the identical terms.

For reprints contact: reprints@medknow.com

A 2.5 cm × 1.8 cm intraventricular tumor was first diagnosed on brain imaging at the age of 14, and for this, she was followed with annual magnetic resonance imagings (MRIs). In 2/2003, at the age of 18, she represented with newly decreased appetite, fatigue, and somnolence. She developed projectile vomiting. A head computed tomography (CT) revealed enlarged lateral, third, and fourth ventricles, consistent with communicating hydrocephalus [Figure 1a]. No appreciable tumor growth of the ventricular lesion was noted. The first ventriculoperitoneal shunt (VPS) was placed and the septum pellucidum was fenestrated endoscopically. Postoperative CT showed resolution of the hydrocephalus [Figure 1b].

Postoperatively, the patient recovered satisfactorily and remained neurologically stable until 8/2003 when she represented with shunt failure manifesting as decreased energy level and vomiting. A head CT scan [Figure 1c] showed enlargement of the lateral and third ventricles. An urgent shunt revision was undertaken. During this revision, her CSF was found to be xanthochromic in appearance. Total CSF protein (total protein [TP]) level at this time was found to be 737 mg/dl (normal ventricular CSF protein: 5–15 mg/dl) with no signs of infection. A new valve was placed. Two further episodes of symptomatic shunt malfunction occurred in early 10/2003, during which her CSF – TP level had increased even further (TP peak level measured 946 mg/dl). It was hypothesized that excessive amounts of CSF proteins released from the tumor and its related vessels was the likely cause for her recurrent valve occlusions. The decision was thus made to remove the intraventricular tumor. The right frontal craniotomy was

performed and a transcortical-transventricular approach through the middle frontal gyrus was chosen. The patient tolerated the procedure well. Histopathological examination was consistent with SEGA.

Postoperatively, the patient remained neurologically stable. TP level of her CSF declined rapidly to levels around 45 mg/dl. A postoperative MRI [Figure 1d] of the brain showed minimal residual tumor. Postoperative intracranial pressure (ICP) values remained slightly elevated and a decision was made to insert new VPS.

Since then, there were no more obstructive shunt failures. Long-term follow-up showed persistent small ventricles [Figure 1e and f] and she has been doing well since from a neurosurgical perspective.

Discussion

The operative approach to SEGA has shifted from simple shunt placement to a more aggressive approach, with early attempts at gross total resection. In the 2012 International TSC Consensus Conference, it was recommended that symptomatic SEGA or SEGA associated with increasing ventricular enlargement or with unexplained changes in neurological status will require intervention or more frequent clinical monitoring and reimaging. For acutely symptomatic individuals, surgical resection is the recommended intervention, but CSF diversion may also be necessary. It has been suggested that early surgical intervention will offer a better long-term clinical course for young SEGA patients as these tumors will be less vascular and smaller in comparison to older patients.^[8] This will bring patients to cure while avoiding lifelong shunt dependency. There were also reports on sudden death associated with SEGA,^[15] leading surgeons to decide on earlier resection of these tumors. On the other hand, hydrocephalus is the main factor contributing to an increased ICP in symptomatic SEGA patients rather than the tumor volume itself. As a result, the initial operative approach to SEGA may still include simple shunt placement, especially in the acute setting of life-threatening hydrocephalus. In 2004–2014, five pediatric series reported on a total of 84 TSC patients who underwent surgical resection of SEGA. Among those, only 22 shunt insertions were reported (26%).^[16] Moreover, 86% of these shunts (19/22) were inserted after the tumor was resected.^[13] This may reflect the current trend, favoring initial surgical resection over shunt placement.

Interestingly, the association of these tumors with a highly proteinaceous CSF has been mentioned as a reason to avoid shunt placement as the first-line treatment in symptomatic SEGA patients.^[11] However, we have found only a few published reports describing this unique scenario.^[12–14]

Our patient had CSF protein levels measured at multiple times during her management. This revealed a significant and progressive increase in values, strikingly reaching levels that are >50-fold greater than the upper normal

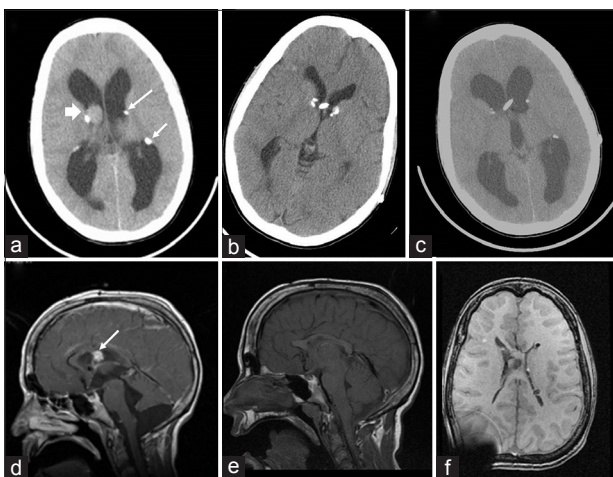


Figure 1: (a) Head computed tomography after patient's first deterioration. Hydrocephalus, right subependymal giant cell astrocytoma (arrowhead), and few subependymal nodules (arrows) are noted. The cerebrospinal fluid protein level was 435 mg/dl. (b) Head computed tomography showing resolution of the hydrocephalus following shunt insertion. (c) Head computed tomography at time of second deterioration. Communicating hydrocephalus is noted. The cerebrospinal fluid protein level was 737 mg/dl. (d) T1-weighted magnetic resonance image with gadolinium posttumor – resection. A small enhancing residual tumor is noticed (arrow). Four years later, the patient was diagnosed with shunt overdrainage. T1-weighted magnetic resonance images (e – sagittal view; f – axial view)

limit. We attribute this mainly to secretions from the lesion and its surroundings and not to any significant extent to postsurgical changes from the VPS placements, as the surgical impact from the placement of a ventricular catheter is considered rather minimal. When it reached a peak value of more than 900 mg/dl, surgical removal of the growing SEGA was carried out. After tumor resection, the patient's CSF showed a significant and impressively rapid decrease of the level of CSF protein [Figure 2].

We would like to emphasize that the patient presented in this manuscript was treated before the everolimus era. Everolimus, a mechanistic target of rapamycin inhibitor, is a pharmaceutical tool, recently added to the armamentarium against SEGA in TSC patients. Based on an open-label phase 2 trial^[17] and a phase 3, double-blind, placebo-controlled trial (EXIST-1),^[18] everolimus has been approved for treating SEGA. In the EXIST-1 trial, 117 patients were randomly assigned to everolimus ($n = 78$) or placebo ($n = 39$). A total of 27 (35%) patients in the everolimus group had at least 50% reduction in the volume of SEGA versus none in the placebo group.^[18] Reported data from an extension of the open-label phase 2 trial have recently confirmed the long-term tolerability and efficacy of everolimus in treating SEGA.^[19]

We found three reported cases on hyperproteinorrhachia – associated SEGA with shunt complications that were successfully treated with everolimus.

Perek-Polnik *et al.*^[14] reported on a 10-year-old female TSC patient with SEGA and symptomatic hydrocephalus who could not undergo surgery because of the high anesthesia risks. He had an external CSF drainage for 6 months because of sustained increased CSF protein levels of 1200 mg/dl. The patient was then given everolimus and within 3 months, the reported CSF protein level decreased to 489 mg/dl, allowing peritoneal shunt implantation. Of

note, after 4 months of treatment, more than 50% volume reduction of the tumor was documented on the brain MRI and CSF protein levels were further reduced to a level as low as 189 mg/dl.

Recently, Laviv *et al.*^[13] described two further cases of persistent communicating hydrocephalus and hyperproteinorrhachia in TSC patients with SEGA, both treated successfully with everolimus. Marked decrease in CSF-TP levels and resolution of the hydrocephalus was demonstrated in both cases.

This patient is now 12 years out from her last surgery for tumor removal and thus far, did not develop any complications or shunt obstruction and did not undergo further surgeries. Of note, this has been achieved despite suspected residual tumor postsurgically, showing that near-total resection may be enough to reverse the hyperproteinorrhachic state.

The association between high protein content in the CSF and the development of communicating hydrocephalus is not new. In 1954, Gardner *et al.* described two cases of small, solid tumors (vestibular schwannoma [VS] and cauda equine ependymoma) that were associated with papilledema and communicating hydrocephalus.^[20] They also described ten cases of Guillain–Barre syndrome (GBS) associated with high CSF – protein levels and communicating hydrocephalus. They concluded that “a small tumor located anywhere along the cerebrospinal axis may cause increased ICP, papilledema, and communicating hydrocephalus.” They explained these phenomena by the escape of proteins through the imperfect walls of the tumor's blood vessels. The proteins then pile up against the blood–brain barrier (BBB) and obstruct its absorption points. This is also true for nonneoplastic conditions such as GBS and transverse myelitis. This explanation suits very well with the common belief that hydrocephalus is a reflection of either a blockage of CSF circulation within the ventricles and/or impaired CSF absorption through the arachnoid projections into the cranial venous. Although this may be the explanation for the clinical scenario observed in our case, there are other possibilities. One of them concerns the CSF osmolality. Increasing evidences suggest that brain pathologies that compromise BBB integrity or which otherwise promote the pathological release of cellular constituents into interstitial fluid and/or CSF may be sufficient to induce hydrocephalus by increasing CSF osmolality.^[21]

It could also be that the type of the elevated proteins is more important than the amount of them or the level of osmolality that they cause. The most common intracranial, solid tumor associated with high levels of protein in the CSF is VS.^[22,23] However, despite being a hallmark of this tumor,^[24] most patients with VS do not develop symptomatic communicating hydrocephalus.^[25] Therefore, perhaps other factors are involved in the pathophysiology,

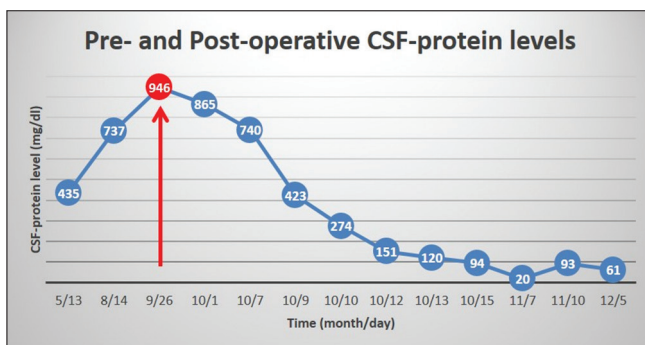


Figure 2: Diagram showing the patient's cerebrospinal fluid protein levels since first clinical deterioration until the final resolution of symptoms. The patient underwent tumor resection at age 18 years, 4.5 months following her first presentation with symptomatic communicating hydrocephalus. The cerebrospinal fluid protein level peaked at that time to 946 mg/dl (arrow). Following surgery, the protein level decreased gradually, reaching nadir (20 mg/dl) at 6 weeks. No further obstructive shunt malfunctions were noted

including the type of the elevated protein. It was reported that the CSF was extremely viscous and basically clotted in a previously published SEGA case,^[13] causing recurrent shunt obstructions. Our patient also had multiple shunt malfunctions from obstructed device. Taken into account the fact that high protein content has only minor effect on CSF viscosity,^[26] it could be that the basis for the malabsorptive hydrocephalus in the SEGA cases are high levels of clotting proteins, such as fibrinogen. CSF – fibrinogen has been related many times to hydrocephalus.^[27,28] Nevertheless, we did not check fibrinogen levels in the CSF in our patient; further studies are needed.

There are, yet, other possible mechanisms, such as recurrent hemorrhages into the tumor with spillage of the blood products into the CSF which, in turn, clog its absorptions points; shedding of tumor cells into the CSF or even meningeal spreading of the solid tumor (usually associated with high – grade malignancies). These explanations are less likely in our case, since there was no evidence of hemorrhage and the CSF cellularity was normal (“albuminocytologic dissociation”).

We have stated that the high protein content may have resulted from increased proteinaceous secretions by the tumor. We are neither aware of the existence of such hypersecretory mechanism in these tumors, nor could we found evidence for a related mechanism in VS. In fact, we do not know if the proteins found in the CSF came directly from the tumor, from the surrounding tissue or the vessels surround it (in the form of exudate). Review of the literature on VS cases associated with hyperproteinorrhachia has also failed to come with the exact origin of the proteins. Interestingly, Hass has demonstrated that the major protein components of CSF in 27 patients with solid brain tumors are derived from, or, at least, antigenically identical to, the plasma proteins.^[29] Whether or not this is true for these special SEGA cases will require further research.

Conclusion

Controversies still exist about the optimal timing and type of surgery for SEGA tumors. The decision making is further complicated when encountering cases of communicating hydrocephalus associated with hyperproteinorrhachia. Albeit rare, this clinical scenario can be extremely hard to treat as was presented in this paper. We have shown that surgical resection of a SEGA tumor can not only relieve local mass effect and reverse blockage of the foramen of Monro; it also allows reversing grossly elevated CSF protein levels. This particular aspect of CSF dynamics in the setting of TSC is striking and should be further explored. It has also been shown that resolution of this condition can be achieved by a combination of surgery + everolimus therapy or even by everolimus alone. These options bring optimism, knowing that the therapeutic modalities are not limited. Finally, whether the pathophysiology of these unique cases is related to CSF malabsorption, increased

osmotic gradient or activation of coagulation cascade will require further studies.

Financial support and sponsorship

Nil.

Conflicts of interest

There are no conflicts of interest.

References

1. Curatolo P, Bombardieri R, Jozwiak S. Tuberous sclerosis. *Lancet* 2008;372:657-68.
2. Rodrigues DA, Gomes CM, Costa IM. Tuberous sclerosis complex. *An Bras Dermatol* 2012;87:184-96.
3. Crino PB, Nathanson KL, Henske EP. The tuberous sclerosis complex. *N Engl J Med* 2006;355:1345-56.
4. Kim SK, Wang KC, Cho BK, Jung HW, Lee YJ, Chung YS, *et al.* Biological behavior and tumorigenesis of subependymal giant cell astrocytomas. *J Neurooncol* 2001;52:217-25.
5. Sparagana SP, Roach ES. Tuberous sclerosis complex. *Curr Opin Neurol* 2000;13:115-9.
6. Bonnin JM, Rubinstein LJ, Papasozomenos SC, Marangos PJ. Subependymal giant cell astrocytoma. Significance and possible cytogenetic implications of an immunohistochemical study. *Acta Neuropathol* 1984;62:185-93.
7. Halmagyi GM, Bignold LP, Allsop JL. Recurrent subependymal giant-cell astrocytoma in the absence of tuberous sclerosis. Case report. *J Neurosurg* 1979;50:106-9.
8. Goh S, Butler W, Thiele EA. Subependymal giant cell tumors in tuberous sclerosis complex. *Neurology* 2004;63:1457-61.
9. Osborne JP, Fryer A, Webb D. Epidemiology of tuberous sclerosis. *Ann NY Acad Sci* 1991;615:125-7.
10. Skalicky AM, Rentz AM, Liu Z, Wheless JW, Pelletier CL, Dunn DW, *et al.* The burden of subependymal giant cell astrocytomas associated with tuberous sclerosis complex: Results of a patient and caregiver survey. *J Child Neurol* 2015;30:563-9.
11. Wheless JW, Klimo P Jr. Subependymal giant cell astrocytomas in patients with tuberous sclerosis complex: Considerations for surgical or pharmacotherapeutic intervention. *J Child Neurol* 2014;29:1562-71.
12. Di Rocco C, Iannelli A, Marchese E. On the treatment of subependymal giant cell astrocytomas and associated hydrocephalus in tuberous sclerosis. *Pediatr Neurosurg* 1995;23:115-21.
13. Laviv Y, Jackson S, Rappaport ZH. Persistent communicating hydrocephalus in adult tuberous sclerosis patients: A possible therapeutic role for everolimus. *Acta Neurochir (Wien)* 2015;157:241-5.
14. Perek-Polnik M, Józwiak S, Jurkiewicz E, Perek D, Kotulska K. Effective everolimus treatment of inoperable, life-threatening subependymal giant cell astrocytoma and intractable epilepsy in a patient with tuberous sclerosis complex. *Eur J Paediatr Neurol* 2012;16:83-5.
15. Prahlow JA, Teot LA, Lantz PE, Stanton CA. Sudden death in epilepsy due to an isolated subependymal giant cell astrocytoma of the septum pellucidum. *Am J Forensic Med Pathol* 1995;16:30-7.
16. Harter DH, Bassani L, Rodgers SD, Roth J, Devinsky O, Carlson C, *et al.* A management strategy for intraventricular subependymal giant cell astrocytomas in tuberous sclerosis complex. *J Neurosurg Pediatr* 2014;13:21-8.
17. Krueger DA, Care MM, Holland K, Agricola K, Tudor C,

- Mangeshkar P, *et al.* Everolimus for subependymal giant-cell astrocytomas in tuberous sclerosis. *N Engl J Med* 2010;363:1801-11.
18. Franz DN, Belousova E, Sparagana S, Bebin EM, Frost M, Kuperman R, *et al.* Efficacy and safety of everolimus for subependymal giant cell astrocytomas associated with tuberous sclerosis complex (EXIST-1): A multicentre, randomised, placebo-controlled phase 3 trial. *Lancet* 2013;381:125-32.
 19. Krueger DA, Care MM, Agricola K, Tudor C, Mays M, Franz DN. Everolimus long-term safety and efficacy in subependymal giant cell astrocytoma. *Neurology* 2013;80:574-80.
 20. Gardner WJ, Spittle DK, Whitten C. Increased intracranial pressure caused by increased protein content in the cerebrospinal fluid; an explanation of papilledema in certain cases of small intracranial and intraspinal tumors, and in the Guillain-Barre syndrome. *N Engl J Med* 1954;250:932-6.
 21. Krishnamurthy S, Li J. New concepts in the pathogenesis of hydrocephalus. *Transl Pediatr* 2014;3:185-94.
 22. Bloch J, Vernet O, Aubé M, Villemure JG. Non-obstructive hydrocephalus associated with intracranial schwannomas: Hyperproteinorrhachia as an etiopathological factor? *Acta Neurochir (Wien)* 2003;145:73-8.
 23. Tanaka Y, Kobayashi S, Hongo K, Tada T, Sato A, Takasuna H. Clinical and neuroimaging characteristics of hydrocephalus associated with vestibular schwannoma. *J Neurosurg* 2003;98:1188-93.
 24. Edwards CH, Paterson JH. A review of the symptoms and signs of acoustic neurofibromata. *Brain* 1951;74:144-90.
 25. Al Hinai Q, Zeitouni A, Sirhan D, Sinclair D, Melancon D, Richardson J, *et al.* Communicating hydrocephalus and vestibular schwannomas: Etiology, treatment, and long-term follow-up. *J Neurol Surg B Skull Base* 2013;74:68-74.
 26. Brydon HL, Hayward R, Harkness W, Bayston R. Physical properties of cerebrospinal fluid of relevance to shunt function 1: The effect of protein upon CSF viscosity. *Br J Neurosurg* 1995;9:639-44.
 27. Brinker T, Seifert V, Dietz H. Subacute hydrocephalus after experimental subarachnoid hemorrhage: Its prevention by intrathecal fibrinolysis with recombinant tissue plasminogen activator. *Neurosurgery* 1992;31:306-11.
 28. Whitelaw A, Pople I, Cherian S, Evans D, Thoresen M. Phase I trial of prevention of hydrocephalus after intraventricular hemorrhage in newborn infants by drainage, irrigation, and fibrinolytic therapy. *Pediatrics* 2003;111 (4 Pt 1):759-65.
 29. Hass WK. Soluble tissue antigens in human brain tumor and cerebrospinal fluid. *Arch Neurol* 1966;14:443-7.