

The anteroposterior diameter of nodules in the risk assessment of papillary thyroid microcarcinoma

Kun Huang, PhD^a, Ningning Gao, PhD^b, Qixi Zhai, MD^a, Donglin Bian, PhD^a, Difei Wang, PhD^{c,*}, Xuemei Wang, PhD^{a,*}

Abstract

This study investigates the application of ultrasound, especially the anteroposterior diameter of nodules in the malignancy and metastasis risk assessment of papillary thyroid microcarcinoma through a retrospective analysis of 500 cases of thyroid nodule ultrasonography.

We selected 500 patients with thyroid nodules (maximum nodule diameter ≤ 2.0 cm) that had been diagnosed clinically and graded TI-RADS 4c by ultrasonography and surgically treated. Among these, there were 258 cases of pathologically diagnosed papillary thyroid microcarcinoma, 72 cases of nodular goiter or adenoma, 137 cases of papillary thyroid carcinoma, 28 cases of acinar cell carcinoma, and 5 cases of undifferentiated carcinoma. In all cases, color Doppler ultrasonography had been performed preoperatively to determine the size and number of nodules, surrounding lymph node metastasis, and TI-RADS grading. Cases of papillary thyroid microcarcinoma diagnosed by pathology were selected as the study group, and cases of nodular goiter or adenoma as the control group. Each group was further subdivided based on the anteroposterior, vertical, and transverse nodule diameters. Intergroup statistical analysis was also performed. Receiver operating characteristic (ROC) curve analysis was conducted on the study and control groups based on the anteroposterior nodule diameters, and the optimal critical value for malignancy risk was determined. Thyroid nodules in the study group were divided into groups based on the presence or absence of lymph node metastasis. Based on the anteroposterior nodule diameter, ROC curve analysis was performed, and the optimal critical value for metastasis risk was determined.

There were 500 cases of malignant nodules diagnosed by ultrasound. Among these, there were 428 cases of malignant nodules diagnosed by pathology. The coincidence rate of the ultrasound diagnosis with pathological diagnosis was 85.60%. While, interestingly, there was a significant statistical difference between the study and control groups based on the anteroposterior nodule diameter. When the anteroposterior nodule diameter was 0.7 cm, sensitivity of malignant diagnosis was 76.70% and specificity of that was 66.70%, and the Youden index was the highest. The lymph node metastasis rate for papillary thyroid microcarcinoma was 13.95%. Within this group, the lymph node metastasis rate for nodules ≥ 0.9 cm (anteroposterior diameter) was 38.46%. When the anteroposterior nodule diameter was equal to 0.9 cm, sensitivity of diagnosis was 83.30%, and specificity of that was 77.80%, and the Youden index was the highest.

The anteroposterior diameter of thyroid nodules is more suitable for assessing their malignancy with 0.7 cm, which can be used as the critical value. Nodules ≥ 0.7 cm require surgical treatment, and those < 0.7 cm can be observed. An anteroposterior diameter of 0.9 cm can be used as the critical value for assessing the metastasis risk of malignant thyroid nodules. During surgery, the dissection of central cervical lymph nodes is required for nodules ≥ 0.9 cm.

Abbreviations: AJCC = American Joint Committee on Cancer, PMC = papillary thyroid microcarcinoma, ROC = receiver operating characteristic, SEER = Surveillance, Epidemiology and End Results Program, TI-RADS = Thyroid Imaging-Reporting And Data System, WHO = World Health Organization.

Keywords: color Doppler ultrasound, malignancy risk, metastasis risk, papillary thyroid microcarcinoma

Editor: Eleonore Fröhlich.

The authors report no conflicts of interest.

^a Department of Ultrasonic Diagnosis, The First Affiliated Hospital of China Medical University, ^b Department of Ultrasonic Diagnosis, Liaoning Province Cancer Hospital and Institute, ^c Department of Geriatrics, The First Affiliated Hospital of China Medical University, Shenyang, Liaoning Province, China.

* Correspondence: Difei Wang, Department of Geriatrics, The First Affiliated Hospital of China Medical University, Shenyang, Liaoning Province, China (e-mail: wdf8lm@163.com); Xuemei Wang, Department of Ultrasonic Diagnosis, The First Affiliated Hospital of China Medical University, Shenyang, Liaoning Province, China (e-mail: wxmlmt@163.com).

Copyright © 2018 the Author(s). Published by Wolters Kluwer Health, Inc. This is an open access article distributed under the Creative Commons Attribution-NoDerivatives License 4.0, which allows for redistribution, commercial and noncommercial, as long as it is passed along unchanged and in whole, with credit to the author.

Medicine (2018) 97:10(e9712)

Received: 22 November 2016 / Received in final form: 3 January 2018 /

Accepted: 8 January 2018

<http://dx.doi.org/10.1097/MD.00000000000009712>

1. Introduction

Thyroid cancer is the most common malignancy of the endocrine system. In recent years, its incidence has gradually increased, attracting more attention from clinical physicians and researchers. The data from the United States National Cancer Institute's Surveillance, Epidemiology and End Results Program (SEER) show that, from 1975 to date, the incidence of thyroid cancer has been on the rise, and of all malignancies, it has the fastest rate of increase.^[1] Pathologically, this rise is mainly due to an increase in papillary carcinoma, and the greatest increase, based on pathologic staging, is in papillary microcarcinoma.^[2] According to the latest statistics from SEER, nearly 90% of cases of thyroid cancer are papillary carcinoma.^[3] Therefore, studies on papillary thyroid microcarcinoma are particularly important. In addition, microcarcinoma accounts for 30% to 70% of cervical lymph node metastasis.^[4–6] Some patients with microcarcinoma develop early local recurrence after surgery, or even show distant

metastasis to the lung or bone at presentation.^[7,8] Therefore, this study mainly focuses on papillary thyroid microcarcinoma, exploring the value of ultrasound in its risk assessment to provide a theoretical basis for clinical diagnosis and treatment.

Papillary thyroid microcarcinoma (PMC) is defined by the World Health Organization (WHO) as papillary thyroid carcinoma that is <1 cm in the maximum diameter of the lesion.^[9,10] However, in the 2004 edition of *Pathology and Genetics of Tumours of Endocrine Organs* by the WHO, microcarcinoma is regarded as a subtype of thyroid cancer, and thyroid microcarcinoma is referred to specifically as papillary thyroid microcarcinoma. Therefore, thyroid microcarcinoma in this study is papillary thyroid microcarcinoma.

2. Materials and methods

2.1. Study subjects

We selected 463 patients from our hospital who had undergone thyroid nodule surgery between January 2012 and October 2015 and who had nodules ≤ 2.0 cm in maximum diameter with a preoperative ultrasound diagnostic classification of TI-RADS4C. The patients ranged between 14 and 78 years of age, with a mean age of (35.6 ± 2.8) years, including 369 females and 94 males. Among the 500 cases of thyroid nodules, there were 258 cases of pathologically diagnosed papillary microcarcinoma, 72 cases of nodular goiter or adenoma, 137 cases of papillary carcinoma, 28 cases of acinar cell carcinoma, and 5 cases of undifferentiated carcinoma. Of the papillary microcarcinoma cases, there were 190 cases of solitary nodules, 25 cases of 2 nodules, 6 cases of 3 nodules, and no cases with more than 4 nodules. In cases with multiple nodules, 27 were bilateral, and 4 were unilateral; 12 cases had level IV and 24 cases had level VI cervical lymph node metastasis. There were 12 cases with a maximum nodule diameter <0.5 cm, 132 cases with a maximum diameter 0.5 to 1.0 cm, 90 cases with a maximum diameter 1.0 to 1.5 cm, and 24 cases with a maximum diameter 1.5 to 2.0 cm. No patients had any surgical contraindications. The study protocol was approved by the Ethics Committee of China Medical University. Written informed consent was obtained from all the participants involved in the study.

2.2. Equipment and methods

The SuperSonic Imagine Aixplorer model color Doppler ultrasound scanner (SuperSonic Imagine, Aix-en-Provence, France), with a transducer frequency of 4 to 15 MHz, was used. Patients were scanned in the supine position for thyroid nodules to determine the definitive size, number, border, shape, internal echogenicity, blood flow, presence or absence of calcification and a halo, aspect ratio of >1 or not, presence or absence of attenuation, and surrounding lymph node metastasis. Additionally, TI-RADS grading was performed. All of the cases were graded TI-RADS4C. After surgery, thyroid nodules were sent for pathological diagnosis.

For malignancy risk assessment, papillary thyroid microcarcinoma was selected as the study group, and nodular goiter or adenoma as the control group. Each group was further subdivided respectively, based on the anteroposterior, transverse, and vertical nodule diameters. Intergroup statistical analysis was performed to verify which diameter would be more representative of the malignancy risk of nodules.

The range of anteroposterior nodule diameters for the study group was 0.34 to 1.17 cm, and the range for the control group was 0.31 to 0.89 cm. Based on the anteroposterior nodule

diameter grouping, receiver operating characteristic (ROC) curve analysis was performed, revealing the optimal critical value for malignancy risk.

For metastasis risk assessment, papillary microcarcinoma with lymph node metastasis was selected as the study group. The control group was papillary microcarcinoma without lymph node metastasis. Based on the anteroposterior nodule diameter grouping, ROC curve analysis was performed, revealing the optimal critical value for metastasis risk. Each patient was tested using the same method. Two associate (or higher-level) clinical professors completed all the tests together. In cases with dispute, an agreement would be reached after discussion.

2.3. Statistical analysis

SPSS 17.0 statistical analysis software was used and measurement data were indicated as (mean \pm standard deviation). Comparisons between thyroid nodule diameter groups were performed using the *t*-test. The optimal critical value of malignancy risk was determined by plotting the ROC curve, calculating the area (*Az*) under the ROC curve, selecting the highest and most posterior point on the curve, then calculating the Youden index and selecting its maximum point of tangency as the critical value, based on the sensitivity and specificity of each possible point of tangency in the statistical result. The optimal critical value of the metastasis risk was determined in the same manner as above.

3. Results

We diagnosed 500 cases of malignant thyroid nodules by color Doppler ultrasound. Among these, 428 cases were malignant thyroid nodules and 72 cases were benign by pathology. The accuracy rate of malignant thyroid nodule diagnosis by ultrasound was 85.60%. Among the malignant thyroid nodules with pathological diagnosis, there were 258 cases of papillary microcarcinoma, 137 cases of papillary carcinoma, 28 cases of acinar cell carcinoma, and 5 cases of undifferentiated carcinoma. Papillary microcarcinoma accounted for 60.28% of malignant nodules.

3.1. Malignancy risk assessment

Excluding cases of papillary thyroid carcinoma, acinar cell carcinoma, and undifferentiated carcinoma, grouping statistical analysis was conducted for the remaining 330 cases, based on the vertical (Table 1), anteroposterior (Table 2), and transverse

Table 1
Based on the vertical diameter of thyroid nodules.

Group	Malignant (n)	Benign (n)
<5	12	6
5–6	12	0
6–7	30	6
7–8	16	12
8–9	54	24
9–10	18	12
10–11	24	6
11–12	42	6
12–13	6	0
13–14	12	0
14–15	6	0
15–16	6	0
16–17	18	0
≥ 17	0	0

Table 2

Based on the anteroposterior diameter of thyroid nodules.

Group	Malignant (n)	Benign (n)
<5	6	12
5-6	6	0
6-7	48	36
7-8	72	6
8-9	48	18
9-10	30	0
10-11	30	0
11-12	18	0
12-13	0	0
13-14	0	0
14-15	0	0
15-16	0	0
16-17	0	0
≥17	0	0

Table 3

Based on the transverse diameter of thyroid nodules.

Group	Malignant (n)	Benign (n)
<5	12	12
5-6	48	36
6-7	72	6
7-8	48	18
8-9	30	0
9-10	30	0
10-11	18	0
11-12	0	0
12-13	0	0
13-14	0	0
14-15	0	0
15-16	0	0
16-17	0	0
≥17	0	0

(Table 3) nodule diameters, respectively. There was a statistically significant difference ($P < .001$) between groupings by anteroposterior nodule diameter. Therefore, we believe the anteroposterior diameter of thyroid nodules was a more suitable assessment indicator for thyroid nodule malignancy (Figs. 1-6).

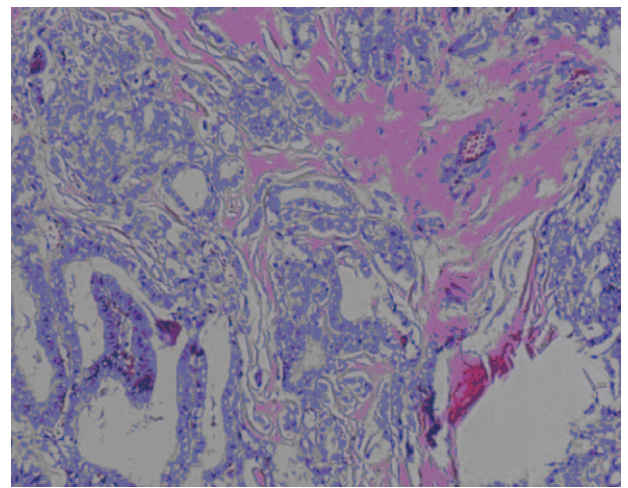


Figure 2. Papillary thyroid microcarcinoma shown in pathology. The maximum diameter of cancer nest was about 0.5 cm.

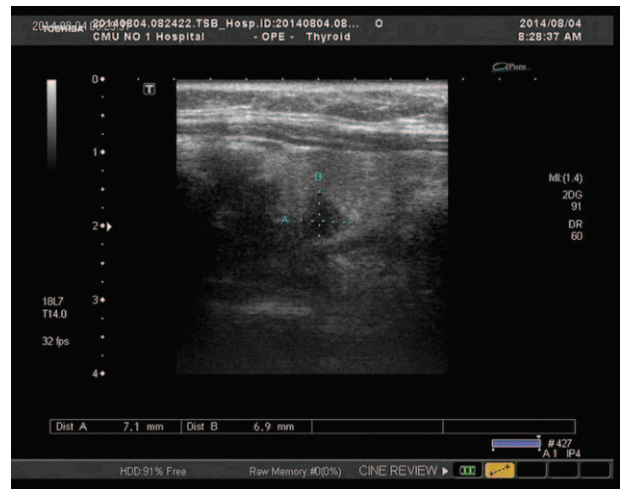


Figure 3. Ultrasound showing nodule size 0.71 × 0.69 cm.

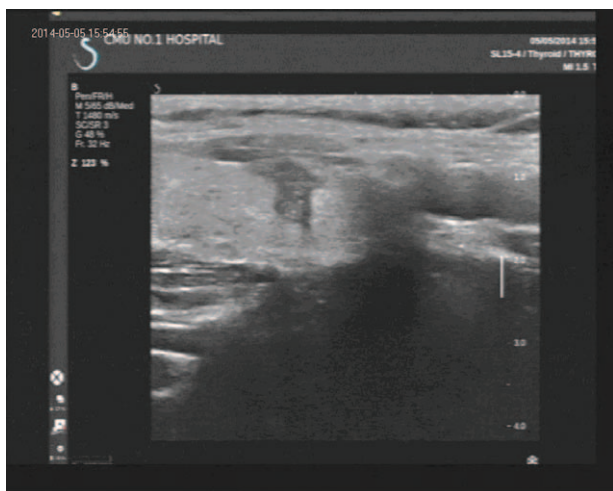

Figure 1. Ultrasound showing nodule size 0.62 × 0.78 cm.

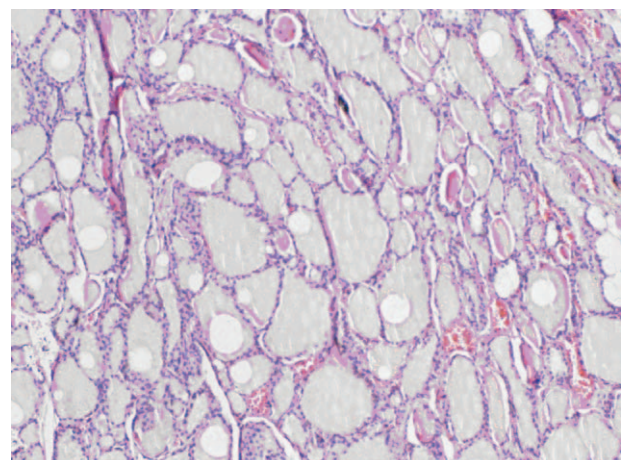


Figure 4. Nodular goiter shown in pathology.

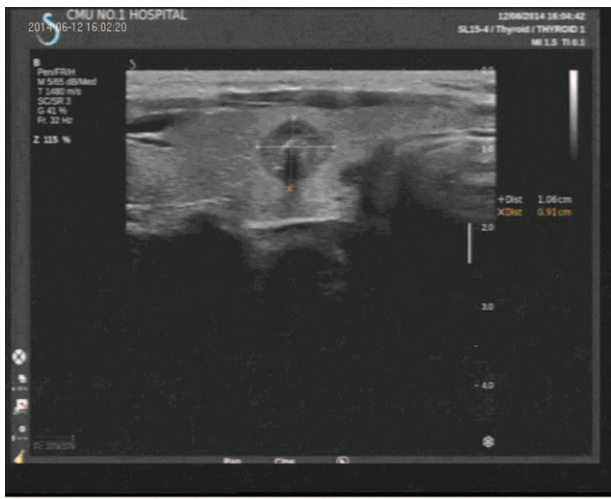


Figure 5. Ultrasound showing nodule size 1.06 × 0.91 cm.

3.2. Determination of the optimal critical value for malignancy risk

Based on the ROC curve, when the anteroposterior nodule diameter was equal to 0.7 cm, sensitivity of malignant diagnosis was 76.70%, specificity of that was 66.70%, and the Youden index was 43.4 as the highest. Therefore, a diameter of 0.7cm could be used as the optimal critical value for malignancy risk assessment for thyroid nodules. Nodules ≥0.7cm have a high degree of malignancy. Nodules < 0.7cm have a low degree of malignancy (Fig. 7).

3.3. Metastasis risk assessment

Among the 258 cases of papillary thyroid microcarcinoma, there were 36 with lymph node metastasis. The lymph node metastasis rate for papillary thyroid microcarcinoma was 13.95%. The metastasis rate for nodules ≥0.9cm was 38.46%.

3.4. Determination of the optimal critical value for metastasis risk

Based on the ROC curve, when the anteroposterior nodule diameter was equal to 0.9cm, sensitivity of metastasis diagnosis was

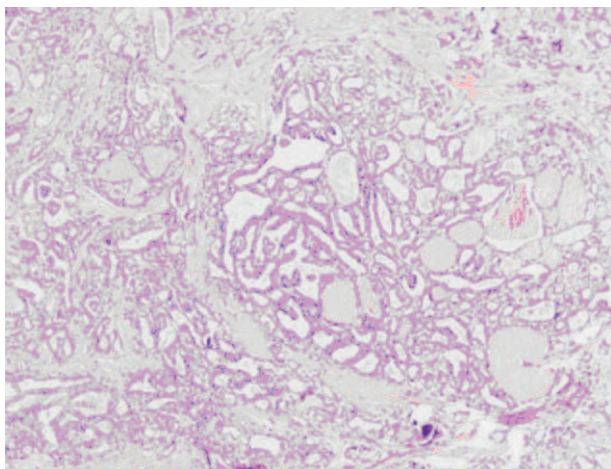


Figure 6. Papillary thyroid microcarcinoma with lymph node metastasis, shown in pathology. The max diameter of cancer nest was about 0.9cm.

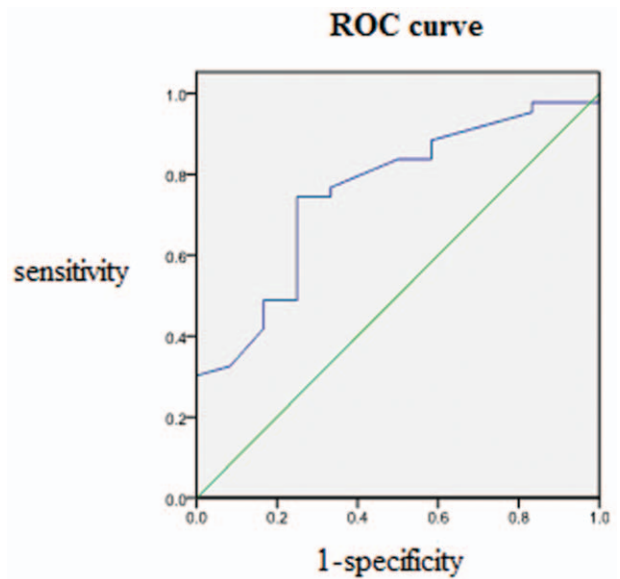


Figure 7. Determination of the optimal critical value for malignancy risk. When the anteroposterior nodule diameter was equal to 0.7cm, sensitivity of malignant diagnosis was 76.70%, specificity of that was 66.70%.

was 83.30%, specificity of that was 77.80%, and the Youden index was 61.1 as the highest. Therefore, an anteroposterior nodule diameter of 0.9 cm could be used as the optimal critical value for metastasis risk of thyroid nodules. Nodules ≥0.9cm have a higher degree of metastasis. Nodules <0.9 cm do not have a high degree of metastasis (Fig. 8).

4. Discussion

Papillary thyroid microcarcinoma progresses rapidly, but internationally, there exists considerable controversy regarding whether to perform prophylactic central lymph node dissection for this cancer.^[11] Proponents believe that papillary thyroid

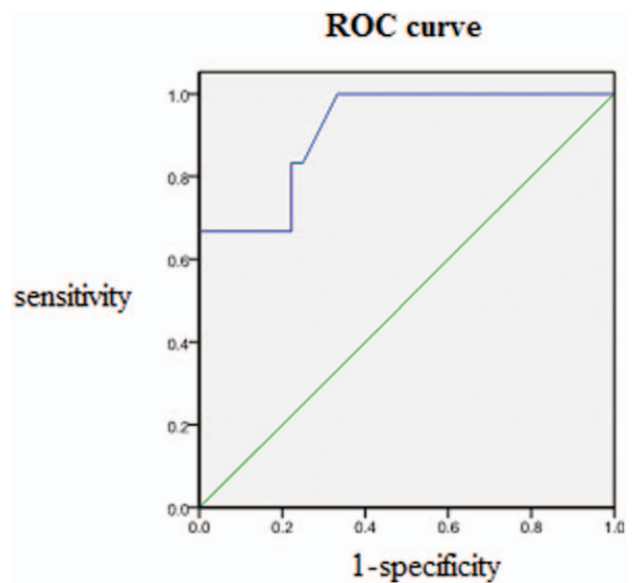


Figure 8. Determination of optimal critical value for metastasis risk. When the anteroposterior nodule diameter was equal to 0.9cm, sensitivity of metastasis diagnosis was 83.30%, specificity of that was 77.80%.

microcarcinomas with tumor diameters >0.5 cm have significantly higher rates of central lymph node metastasis,^[12] and are often multifocal (35%). Studies have shown that most multifocal cancers have a higher rate of metastasis to central lymph nodes,^[13] which can be as high as 38.1% to 42%. A number of other studies have shown that prophylactic central lymphadenectomy can reduce the recurrence rate of thyroid cancer.^[14] However, other scholars believe that prophylactic central lymphadenectomy may lead to temporary or permanent recurrent laryngeal nerve injury, and increase the risk of hypoparathyroidism.^[15,16] The diagnosis of tumors >0.5 mm in diameter requires pathological evaluation. If an accurate diagnosis can be made before surgery, providers will then be able to select a reasonable surgical approach, avoiding the debate of whether to perform prophylactic central lymph node dissection. Therefore, preoperative determination of the characteristics and the metastasis risk of thyroid nodules is imperative.

This study firstly selected 500 cases of thyroid nodules, and their inclusion criterion was a maximum diameter of ≤ 2 cm by ultrasound. The reason for this is that our study mainly examined the risk assessment of malignancy and metastasis of lesser tubercle of thyroid, though there is no clear conception for the definition of small nodules. However, thyroid microcarcinoma is defined as cancer nests with a maximum diameter of <1 cm,^[17] and hence some of the nodules would be >1 cm in maximum diameter. This is because tissue hyperplasia and inflammation take place around cancer nests, resulting in indistinct borders. Ultrasound cannot definitively distinguish the cancer nest from the surrounding tissue hyperplasia and inflammation, leading to imaging findings of nodules >1 cm in maximum diameter. Therefore, it was not possible to solely select nodules with a maximum diameter of <1 cm, as many cases could be missed in this manner. The upper limit was determined mainly by reference to the TNM Classification for Thyroid Cancer, 7th Edition (2010), by the American Joint Committee on Cancer (AJCC). In the TNM classification, class T1 is the mildest tumor, limited to the thyroid, with a maximum diameter ≤ 2 cm. Based on these considerations, our study enrolled patients with a maximum nodule diameter ≤ 2 cm as the standard.

The nodules included in this study were grouped by maximum diameter. However, the direction of the maximum diameter was unclear, since there were vertical, anteroposterior, and transverse diameters, among which most were vertical. This multidirectional nature without a uniform standard caused some confusion. To further examine the malignancy risk of the nodules, a unified standard was necessary. To this aim, we divided the nodules into groups based on the above diameters, and then made intergroup comparisons. As a statistical difference of the anteroposterior diameter of the nodules was found between groups, we selected it as the standard for the malignancy risk assessment of nodules. The reason for the statistical difference in the anteroposterior nodule diameter is mainly due to its growth pattern, where the growth of tumor cells is arranged longitudinally. The tumor cells in the anteroposterior direction are in mitotic division during the early phase of thyroid cancer, but the cells in other directions are in the resting stage during the same phase. This leads to the relatively larger anteroposterior tumor diameter compared to transverse and vertical ones, which is a completely different growth pattern from benign nodules.^[18]

This study concludes that an anteroposterior nodule diameter of 0.7 cm can be used as the optimal critical value for assessing the degree of malignancy of thyroid nodules. The main reason is that malignant nodules have to grow to a certain extent for malignant

signs perceptible on imaging to be detectable by ultrasound. A diameter of 0.7 cm is an appropriate critical value. Guidelines in other countries state that only nodules > 1.0 cm in diameter may be resected. However, in China, we find that malignant nodules >0.5 cm in diameter may be resected.^[14] It appears obvious that the criteria for resection are more liberal and loose in China, with the result that many benign nodules have unintentionally been resected, subsequently leading to unnecessary hypothyroidism in patients. The criteria for resection are more stringent in other countries, resulting in metastasis in some patients before surgery, and missing of the optimal time for operation. Therefore, there is an urgent need for an appropriate surgical standard to assess malignant thyroid nodules, and a diameter of 0.7 cm is a reasonable critical value.

The main route of spread of papillary thyroid microcarcinoma is cervical lymph node metastasis. In the early stages of disease detection, the presence of associated cervical lymph node metastasis is the most important indicator in assessing the prognosis of patients. Numerous clinical trials have shown that the risk of postoperative local recurrence and distal metastasis in thyroid cancer patients with associated cervical lymph node metastasis is 3 to 17 times that of patients without lymph node metastasis.^[6,19-23] Based on the characteristics of cervical lymph node lymphatic flow and clinical observation, papillary carcinoma locally metastasizes to the central lymph nodes initially, then to the lateral ones.^[24] However, ultrasound is not sensitive in the detection of central lymph node metastasis, detecting $<10\%$. This is mainly due to the location of the nodes as well as interference from the trachea and pulsating vessels. Additionally, at present, it has not been confirmed that central lymph nodes are the sentinel lymph nodes for thyroid cancer metastasis. Upper-pole PMC in the thyroid can more easily metastasize to levels IIa, IIb, and III, than to the central region. Within the thyroid surgery community, there continues to be great controversy regarding whether to perform prophylactic central lymph node dissection during unilateral thyroidectomy + isthmusectomy. Therefore, there are many reasons for the urgent assessment of the metastasis risk for thyroid cancers, the anteroposterior nodule diameter of 0.9 cm precisely provides a possible solution. This is because malignant nodules of a diameter < 0.9 cm have a nearly 0% rate of metastasis, and those that are > 0.9 cm have a nearly 40% rate of metastasis. This further indicates that 0.9 cm is a reasonable critical value.

4.1. Limitations of this study

Due to fewer multinodular cases in this study, we did not superimpose the diameters of multinodules. This caused the anteroposterior diameter to be <0.6 cm in some of the focal nodules that also had metastasized. This deviates from the conclusion of our study. In reports in domestic literature, researchers found that the superimposed diameter of nodules that are multifocal is an independent risk factor. Therefore, the follow-up research to this study will include the superimposed diameter of multifocal nodules in a grouping for investigation. In addition, this paper mainly studied the diameter of thyroid nodule while the other characteristics such as echo, boundary, morphology, blood flow and the calcification were not included. The reason is that the diameter of the nodule of papillary thyroid microcarcinoma is so small that the characteristics of echo, boundary, morphology and the blood flow were not typical for research.

Overall, the establishment of the anteroposterior nodule diameter provides a uniform standard for assessing the malignancy of thyroid nodules. Nodule diameter is no longer a confusing issue.

The critical value of 0.7 cm indicates that if the anteroposterior diameter of a nodule is ≥ 0.7 cm represents an increased degree of malignancy and requires surgical resection. Thyroidectomy with isthmusectomy is an option. Prophylactic central lymph node dissection is unnecessary.

The critical value of 0.9 cm indicates that if the anteroposterior diameter of the nodule is >0.9 cm, not only its degree of malignancy is greatly increased, but its risk of metastasis is significantly increased as well, and it requires surgical resection. If ultrasound finds no lymph node metastasis, then thyroidectomy, isthmusectomy, and central lymph node dissection will be required. If ultrasound does detect lymph node metastasis, then thyroidectomy, isthmusectomy, and standard central and/or unilateral and/or bilateral cervical lymph node dissection will be required.

References

- [1] Xu D, Lv X, Wang S, et al. Risk factors for predicting central lymph node metastasis in papillary thyroid microcarcinoma. *Int J Clin Exp Pathol* 2014;7:6199–205.
- [2] Chen AY, Jemal A, Ward EM. Increasing incidence of differentiated thyroid cancer in the United States, 1988–2005. *Cancer* 2009;115:3801–7.
- [3] Davies L, Welch HG. Increasing incidence of thyroid cancer in the United States, 1973–2002. *JAMA* 2006;295:2164–7.
- [4] Lim YC, Choi EC, Yoon YH, et al. Central lymph node metastases in unilateral papillary thyroid microcarcinoma. *Br J Surg* 2009;96:253–7.
- [5] Mercante G, Frasoldati A, Pedroni C, et al. Prognostic factors affecting neck lymph node recurrence and distant metastasis in papillary microcarcinoma of the thyroid: Results of a study in 445 patients. *Thyroid* 2009;19:707–16.
- [6] Lombardi CP, Bellantone R, De Crea C, et al. Papillary thyroid microcarcinoma: Extrathyroidal extension, lymph node metastases, and risk factors for recurrence in a high prevalence of goiter area. *World J Surg* 2010;34:1214–21.
- [7] Xu YH, Song HJ, Qiu ZL, et al. Brain metastases with exceptional features from papillary thyroid carcinoma: Report of three cases. *Hell J Nucl Med* 2011;14:56–9.
- [8] Varsavsky M, Cortés BM, Alonso G, et al. Metastatic adenopathy from a thyroid microcarcinoma: Final diagnosis of a presumed paraganglioma. *Endocrinol Nutr* 2011;58:143–4.
- [9] Sobin LH. Histological typing of thyroid tumours. *Histopathology* 1990;16:513.
- [10] Hedinger C, Williams ED, Sobin LH. The WHO histological classification of thyroid tumors: a commentary on the second edition. *Cancer* 1989;63:908–11.
- [11] Cooper DS, Doherty GM, Haugen BR, et al. Revised American Thyroid Association management guidelines for patients with thyroid nodules and differentiated thyroid cancer. *Thyroid* 2009;19:1167–214.
- [12] Tuttle RM, Haddad RI, Ball DW, et al. Thyroid carcinoma, version 2.2014. *J Natl Compr Canc Netw* 2014;12:1671–80. 1680.
- [13] Mazeh H, Samet Y, Hochstein D, et al. Multifocality in well-differentiated thyroid carcinomas calls for total thyroidectomy. *Am J Surg* 2011;201:770–5.
- [14] Sun W, Lan X, Zhang H, et al. Risk factors for central lymph node metastasis in CN0 papillary thyroid carcinoma: a systematic review and meta-analysis. *PLoS One* 2015;10:e139021.
- [15] Roh JL, Kim JM, Park CI. Central lymph node metastasis of unilateral papillary thyroid carcinoma: patterns and factors predictive of nodal metastasis, morbidity, and recurrence. *Ann Surg Oncol* 2011;18:2245–50.
- [16] Kim MK, Mandel SH, Baloch Z, et al. Morbidity following central compartment reoperation for recurrent or persistent thyroid cancer. *Arch Otolaryngol Head Neck Surg* 2004;130:1214–6.
- [17] Kim BY, Jung CH, Kim JW, et al. Impact of clinicopathologic factors on subclinical central lymph node metastasis in papillary thyroid microcarcinoma. *Yonsei Med J* 2012;53:924–30.
- [18] Samir AE, Vij A, Seale MK, et al. Ultrasound-guided percutaneous thyroid nodule core biopsy: clinical utility in patients with prior nondiagnostic fine-needle aspirate. *Thyroid* 2012;22:461–7.
- [19] Moreno MA, Agarwal G, de Luna R, et al. Preoperative lateral neck ultrasonography as a long-term outcome predictor in papillary thyroid cancer. *Arch Otolaryngol Head Neck Surg* 2011;137:157–62.
- [20] Hay ID, Hutchinson ME, Gonzalez-Losada T, et al. Papillary thyroid microcarcinoma: A study of 900 cases observed in a 60-year period. *Surgery* 2008;144:980–7. 987–988.
- [21] Pisanu A, Reccia I, Nardello O, et al. Risk factors for nodal metastasis and recurrence among patients with papillary thyroid microcarcinoma: differences in clinical relevance between nonincidental and incidental tumors. *World J Surg* 2009;33:460–8.
- [22] Vaisman F, Shaha A, Fish S, et al. Initial therapy with either thyroid lobectomy or total thyroidectomy without radioactive iodine remnant ablation is associated with very low rates of structural disease recurrence in properly selected patients with differentiated thyroid cancer. *Clin Endocrinol (Oxf)* 2011;75:112–9.
- [23] Lundgren CI, Hall P, Dickman PW, et al. Clinically significant prognostic factors for differentiated thyroid carcinoma: a population-based, nested case-control study. *Cancer* 2006;106:524–31.
- [24] Leboulloux S, Girard E, Rose M, et al. Ultrasound criteria of malignancy for cervical lymph nodes in patients followed up for differentiated thyroid cancer. *J Clin Endocrinol Metab* 2007;92:3590–4.