

# Extracalvarial Composite Infantile Myofibromatosis: Case Report and Literature Review

Alexander Ivanov<sup>1</sup> Tibor Valyi-Nagy<sup>2</sup> Dimitrios Nikas<sup>1</sup>

<sup>1</sup>Department of Neurosurgery, University of Illinois at Chicago, Chicago, Illinois, United States

<sup>2</sup>Department of Pathology, University of Illinois at Chicago, Chicago, Illinois, United States

**Address for correspondence** Dimitrios Nikas, MD, Department of Neurosurgery, University of Illinois at Chicago, 912 S Wood Street, Chicago, Illinois 60612, United States (e-mail: dnikas@uic.edu).

Eur J Pediatr Surg Rep 2016;4:22–25.

## Abstract

### Keywords

- ▶ infantile myofibromatosis
- ▶ composite infantile myofibromatosis
- ▶ infantile fibrosarcoma

Infantile soft tissue tumors of the head are very rare and the majority of them are myofibromas. The authors present the case of a 1-day-old boy with a scalp tumor with several distinct histopathological features including myofibroma, hemangiopericytoma, and fibrosarcoma consistent with the diagnosis of composite infantile myofibromatosis. Genetic testing was negative for trisomy 17, translocation (12; 15), FUS, and ETV6 translocations. Despite the ominous histopathological features, the clinical course was benign. The authors review here available literature concerning current concepts of making the diagnosis of composite infantile myofibromatosis and discuss treatment options.

## New Insights and Importance for the Pediatric Surgeon

Extracalvarial composite infantile myofibromatosis is very rare entity. Mixed histopathological features including benign and malignant features may be misleading in patient management. Surgeon and pathologist should be aware of such clinical and pathological presentation and manage a patient in accordance with current clinical outcome data.

## Introduction

Soft tissue tumors of the head are relatively uncommon neoplasms and occur in less than 5 to 10% of all soft tissue mesenchymal neoplasms.<sup>1</sup> Of these, infantile myofibromatosis (IM) has a unique predilection for early childhood. Other pediatric mesenchymal neoplasms such as fibrosarcoma and hemangiopericytoma have a distinct clinical course in infantile patients in comparison to their adult counterparts.<sup>2–4</sup> We present a case of a male infant with an extracalvarial mesenchymal neoplasm, which had histopathologic features of IM, fibrosarcoma, and hemangiopericytoma as a spectrum within one individual tumor. Very few similar cases have been reported previously in the literature and therefore little is known about their long-

term prognosis and treatment options. The authors present a literature review and discuss treatment paradigms.

## Case Report

### History and Physical Examination

The patient was a 1-day-old boy. He was born full term by vaginal delivery following uncomplicated pregnancy. A head mass was noticed during extraction, and neurosurgery service was consulted. His neurological exam was intact, and he did not show signs of distress. The patient was diagnosed with a right temporoparietal area soft tissue mass, which prompted further evaluation.

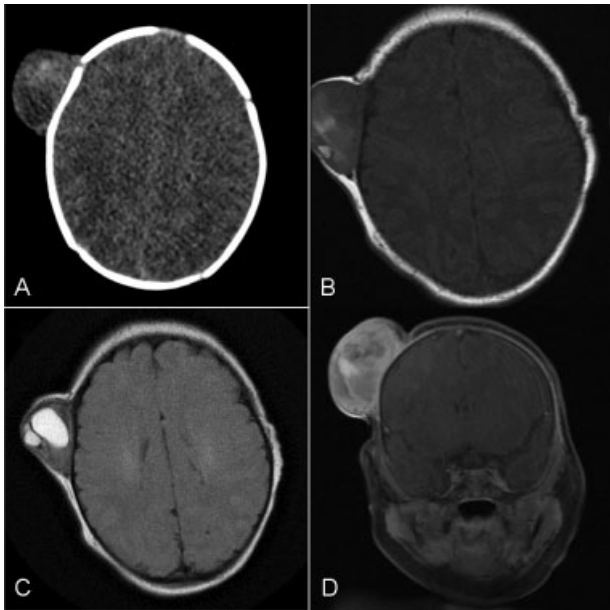
received  
November 15, 2015  
accepted after revision  
February 14, 2016  
published online  
June 12, 2016

DOI <http://dx.doi.org/10.1055/s-0036-1580704>.  
ISSN 2194-7619.

© 2016 Georg Thieme Verlag KG  
Stuttgart · New York

License terms





**Fig. 1** Imaging studies demonstrating right temporoparietal mass. (A) CT of the head—axial image demonstrates large-size extracalvarial mass. (B) Axial noncontrast T1-weighted MRI image. (C) Axial noncontrast MRI T2-FLAIR image. (D) Axial postcontrast MRI T1-weighted image.

**Imaging**

Magnetic resonance imaging (MRI) showed a right temporoparietal mass (3 × 4.5 cm), which was heterogeneous on T1- and T2-weighted images, with mild heterogeneous enhancement on T1-weighted images. Computer tomography of the head showed an extracalvarial mass without bone involvement (→Fig. 1).

**Operative Procedure and Postoperative Imaging**

After discussing management options with family, surgery was elected. Patient was brought to the operating room on the fourth day of life and careful resection with grossly negative

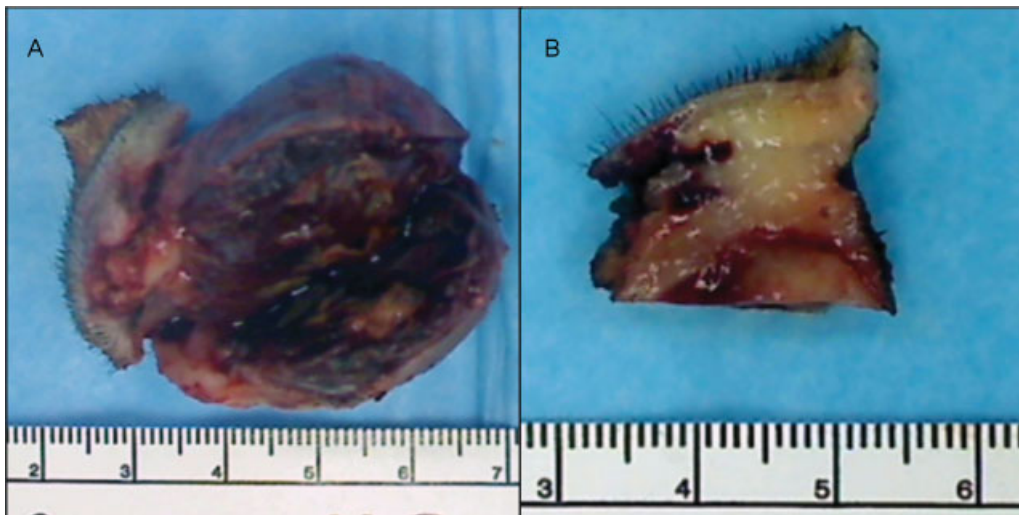
margins of the lesion was performed under general anesthesia. The mass was not well circumscribed from the surrounding scalp and therefore a wide local excision was performed (→Fig. 2). There was a normal dissection plane at the level of the periosteum between the soft tissue below the mass and calvarium. On gross inspection, the mass had a nodular appearance with rubber consistency. Deeper tissues showed hemorrhagic areas. The postoperative course was uncomplicated. MRI of the head performed the next day showed no signs of the residual lesion. Patient was followed with clinical observations and follow-up appointments on yearly basis. No signs of the local recurrence have been observed.

**Pathological Analysis**

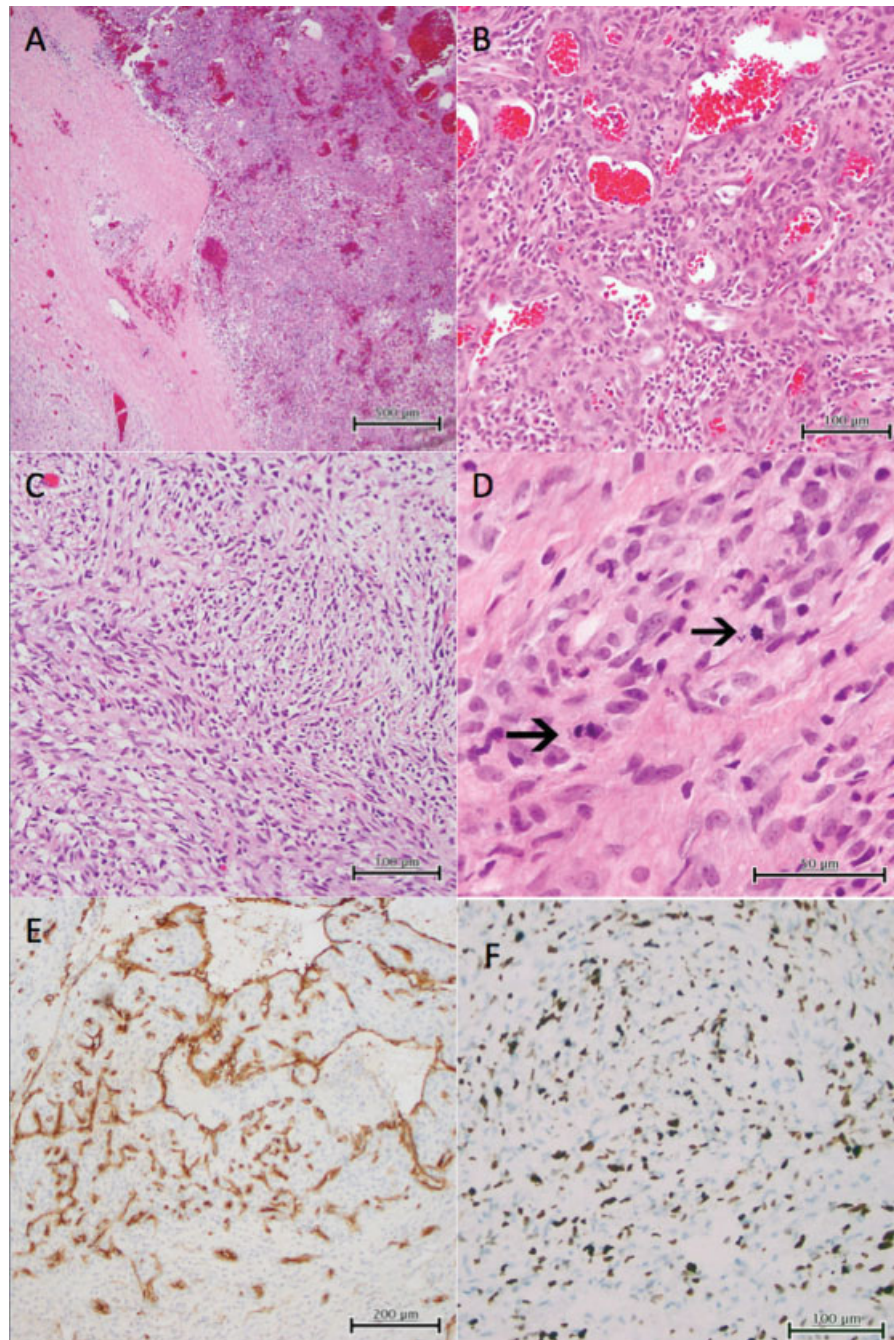
Histopathologic examination revealed a complex lesion with a core of vascular/pericytic proliferation surrounded by a zone of myofibroblastic spindle cell proliferation. The spindle cell areas had an infiltrative fascicular growth pattern and the cells in this area showed nuclear atypia, hyperchromasia, and increased mitotic activity (→Fig. 3). Immunohistochemical studies revealed the endothelial cell component to be positive for CD31, CD34, and smooth muscle actin. The spindle component was negative for S-100, cytokeratin, myogenin, smooth muscle actin, CD99, HMB-45, MART-1, MITF, GFAP, and β-catenin. Ki-67 showed a proliferation index of 10 to 20% in the vascular portions of the tumor, but 40 to 50% in the spindle cell component. Cytogenetic testing of the tumor revealed rare cells (under 10%) with trisomy 8 and trisomy 11. Genetic testing was negative for trisomy 17, translocation (12; 15), FUS, and ETV6 translocations. Therefore, this tumor featured several histological entities, including infantile myofibroma, congenital fibrosarcoma, and hemangiopericytoma. The histologic examination indicated clear resection margins.

**Follow-Up**

At the last follow-up appointment, 2.5 years after resection surgery, no local recurrence was present on examination.



**Fig. 2** (A and B) Specimen picture shows irregular shape rubber mass with attached hair-bearing skin.



**Fig. 3** Histopathological studies. (A) Low-power photomicrograph showing the abrupt transition between the central, vascular portion of the tumor and the outer rim of myofibroblastic atypical spindle cell proliferation. (B) High-power photomicrograph showing vascular portion of the tumor. (C) High-power photomicrograph showing spindle cell portion of the tumor. (D) High-power photomicrograph showing prominent mitotic activity in the spindle cell portion of the tumor. (E) Low-power photomicrograph showing CD34-positive vascular channels within the spindle cell portion of the tumor. (F) Photomicrograph revealing Ki-67 proliferation index of 40 to 50% in the atypical spindle cell tumor portion.

## Discussion

IM is a proliferative disorder of mesenchymal origin, which is characterized by nodular neoplasm formation in soft tissues, including cutaneous, subcutaneous, muscle, bone, and visceral structures. It typically occurs in infancy, predominantly in the head and neck.<sup>5</sup> Tumors are characterized by positive staining for smooth muscle actin and muscle-specific actin with more

prominent regressive features in solitary tumors.<sup>6,7</sup> The clinical course of the solitary lesion is usually benign with surgical excision appearing to sufficiently control further recurrence.<sup>7</sup> Since tumor identification as a unique entity by Stout in 1954,<sup>8</sup> there were multiple studies on the clinical course of the solitary myofibroma and treatment outcomes.<sup>6,9-11</sup> To this date, all reported cases of patients who underwent surgical resection have had uncomplicated postoperative course.

The differential diagnosis also included fibrosarcoma. Infantile fibrosarcoma is a rare mesenchymal tumor with 5 to 10% occurrences from all sarcomas in children younger than 1 year.<sup>2,3,12,13</sup> Although the clinical course is less aggressive than in adult cases, chemotherapy is used in noncomplete resection, nonresectable tumors, and recurrences.<sup>3</sup> Infantile myofibroma may have histologic overlap with infantile fibrosarcoma appearance and cytogenetic analysis may be helpful in differential diagnosis. It was shown that infantile fibrosarcoma has specific translocation between chromosome 12 and 15, with ETV6-NTRK3 gene fusion; therefore, cytogenetic studies are crucial in clinicopathological diagnosis. In our case, although the cytogenetic analysis was negative for above-mentioned translocation, the highly cellular spindle cell component with atypical features warranted the consideration of an infantile fibrosarcoma component to the lesion.

The observed prominent vascular pattern in our case prompted the consideration of infantile hemangiopericytoma as a third entity in the lesion. Clinical and histological similarities between infantile hemangiopericytoma and IM have been recognized in 1994 by Mentzel et al.<sup>4</sup> Other studies showed similar histologic characteristics between hemangiopericytoma and infantile myofibroma<sup>14,15</sup> strongly suggesting that infantile hemangiopericytoma represents a different stage of maturation of the myofibroblastic/pericytic component of the immature IM. Thus, hemangiopericytoma-like pattern is currently considered as a variant of IM.

Overlapping histopathologic features within the infantile myofibroma-like tumor group were recognized previously in several studies.<sup>4,14,15</sup> A broader histological category was proposed to describe individual tumors where all three histological patterns (IM, hemangiopericytoma, and fibrosarcoma) coexist.<sup>16</sup> Sarangarajan and Dehner showed 21 cases of IM with a mixture of each pattern, myofibromatosis, hemangiopericytoma, and fibrosarcoma, and proposed to use the term *composite myofibromatosis* as a unifying concept. Further identification of the characteristic translocation t(12;15) in infantile fibrosarcoma cases helped to differentiate challenging cases and to choose management accordingly. Currently, cytogenetic analysis is considered as a key method of differential diagnosis, and composite myofibromatosis is suggested in the absence of a chromosomal aberration such as translocation between chromosome 12 and 15, and ETV6-NTRK3 gene fusion.<sup>17</sup> In cases with confirmed cytogenetic features of infantile fibrosarcoma, chemotherapy plus surgery is considered if there was only incomplete resection.<sup>17,18</sup>

Histopathological examination in our case showed features of myofibromatosis, infantile hemangiopericytoma, and infantile fibrosarcoma that were in line with previously published studies supporting histogenetic relationships among these three entities. Therefore, our case likely represents infantile composite solitary myofibromatosis. Observation for local recurrence and metastasis was chosen to manage our patient after surgical

resection, as this has been reportedly to be effective in the literature.<sup>15,17</sup> Postoperative surveillance should avoid radiation exposure; thus, MRI is recommended as a more favorable imaging modality.

## References

- 1 Fletcher CD. Distinctive soft tissue tumors of the head and neck. *Mod Pathol* 2002;15(3):324–330
- 2 Cecchetto G, Carli M, Alaggio R, et al; Italian Cooperative Group. Fibrosarcoma in pediatric patients: results of the Italian Cooperative Group studies (1979–1995). *J Surg Oncol* 2001;78(4):225–231
- 3 Orbach D, Rey A, Cecchetto G, et al. Infantile fibrosarcoma: management based on the European experience. *J Clin Oncol* 2010;28(2):318–323
- 4 Mentzel T, Calonje E, Nascimento AG, Fletcher CD. Infantile hemangiopericytoma versus infantile myofibromatosis. Study of a series suggesting a continuous spectrum of infantile myofibroblastic lesions. *Am J Surg Pathol* 1994;18(9):922–930
- 5 Oudijk L, den Bakker MA, Hop WC, et al. Solitary, multifocal and generalized myofibromas: clinicopathological and immunohistochemical features of 114 cases. *Histopathology* 2012;60(6B):E1–E11
- 6 Wiswell TE, Davis J, Cunningham BE, Solenberger R, Thomas PJ. Infantile myofibromatosis: the most common fibrous tumor of infancy. *J Pediatr Surg* 1988;23(4):315–318
- 7 Chung EB, Enzinger FM. Infantile myofibromatosis. *Cancer* 1981;48(8):1807–1818
- 8 Stout AP. Juvenile fibromatoses. *Cancer* 1954;7(5):953–978
- 9 Larralde M, Hoffner MV, Boggio P, Abad ME, Luna PC, Correa N. Infantile myofibromatosis: report of nine patients. *Pediatr Dermatol* 2010;27(1):29–33
- 10 Kuo FY, Huang SC, Eng HL, Chuang JH, Chen WJ. Solitary infantile myofibromatosis: report of two cases. *Chang Gung Med J* 2002;25(6):393–398
- 11 Schmidt D. Fibrous tumors and tumor-like lesions of childhood: diagnosis, differential diagnosis, and prognosis. *Curr Top Pathol* 1995;89:175–191
- 12 Coffin CM, Dehner LP. Soft tissue tumors in first year of life: a report of 190 cases. *Pediatr Pathol* 1990;10(4):509–526
- 13 Hayani A, Mahoney DH Jr, Hawkins HK, Steuber CP, Hurwitz R, Fernbach DJ. Soft-tissue sarcomas other than rhabdomyosarcoma in children. *Med Pediatr Oncol* 1992;20(2):114–118
- 14 Coffin CM, Dehner LP. Fibroblastic-myofibroblastic tumors in children and adolescents: a clinicopathologic study of 108 examples in 103 patients. *Pediatr Pathol* 1991;11(4):569–588
- 15 Variend S, Bax NM, van Gorp J. Are infantile myofibromatosis, congenital fibrosarcoma and congenital haemangiopericytoma-histogenetically related? *Histopathology* 1995;26(1):57–62
- 16 Sarangarajan RWF, Dehner LP. Composite myofibromatosis (CM). A unifying concept for infantile myofibromatosis, infantile hemangiopericytoma and infantile fibrosarcoma. *Mod Pathol* 1998;11:5P
- 17 Alaggio R, Barisani D, Ninfo V, Rosolen A, Coffin CM. Morphologic overlap between infantile myofibromatosis and infantile fibrosarcoma: a pitfall in diagnosis. *Pediatr Dev Pathol* 2008;11(5):355–362
- 18 McCahon E, Sorensen PH, Davis JH, Rogers PC, Schultz KR. Non-resectable congenital tumors with the ETV6-NTRK3 gene fusion are highly responsive to chemotherapy. *Med Pediatr Oncol* 2003;40(5):288–292