

Received: 2018.09.14
Accepted: 2018.11.02
Published: 2019.01.26

Olmesartan Associated Enteropathy: A Rare Underdiagnosed Cause of Diarrhea and Weight Loss

Authors' Contribution:
Study Design A
Data Collection B
Statistical Analysis C
Data Interpretation D
Manuscript Preparation E
Literature Search F
Funds Collection G

AEF 1 **Sripriya Gonakoti**
A 2 **Sanjiv Khullar**
EF 1 **Aarathi Rajkumar**

1 Department of Internal Medicine, North East Ohio Medical University, Canton Medical Education Foundation, Canton, OH, U.S.A.
2 Department of Internal Medicine, North East Ohio Medical University, Rootstown, OH, U.S.A.

Corresponding Author: Aarathi Rajkumar, e-mail: aarthirajkumar96@gmail.com, aarathi.rajkumar@aultman.com
Conflict of interest: None declared

Patient: Male, 59
Final Diagnosis: Olmesartan associated enteropathy
Symptoms: Diarrhea and weight loss
Medication: —
Clinical Procedure: —
Specialty: Gastroenterology and Hepatology

Objective: Unusual or unexpected effect of treatment





Background: Olmesartan, an angiotensin receptor blockade class of antihypertensive medication has recently been associated with a seronegative sprue like enteropathy. Patients typically present with diarrhea and weight loss often prompting exhaustive diagnostic workup. Discontinuation of the drug leads to dramatic recovery and hence, physicians need to be aware of olmesartan associated enteropathy (OAE) in order to avoid unnecessary testing.

Case Report: A 59-year-old Caucasian male was admitted to the hospital with complaints of intractable diarrhea, vomiting and considerable weight loss. Medical history was notable for hypertension being treated with olmesartan. Workup for all potential infectious causes and celiac disease was negative. Eventually, a colonoscopy was performed due to his persistent symptoms and biopsy revealed lymphocytic colitis. An upper endoscopy was also performed, and histopathology of the duodenum revealed total villous blunting. In light of negative serology for celiac disease and after a detailed review of the patient's medications, the possibility of olmesartan induced enteropathy was considered. Olmesartan was stopped and his symptoms resolved. A follow-up endoscopy done a few months later showed normal small bowel mucosa.

Conclusions: This case demonstrates the need for a thorough medication review by healthcare providers especially after a full workup for the patient's symptoms has already been performed. It also reiterates that having an awareness of rare side effects of common medications mitigates the need for extensive diagnostic testing.

MeSH Keywords: Antihypertensive Agents • Celiac Disease • Diarrhea • Weight Loss

Full-text PDF: <https://www.amjcaserep.com/abstract/index/idArt/913207>

 2286   6  21



Background

Olmesartan medoxomil was approved for the treatment of hypertension in 2002. It is 1 of 8 types of angiotensin receptor blockade (ARB) agents used for the treatment of high blood pressure and can be used alone or in combination with other classes of anti-hypertensives drugs. It is available worldwide under the trade names of Benicar, Benicar HCTZ, Azor, and Tribenzor. The most common reported adverse effects of this medication include headache, flu-like symptoms, and dizziness [1]. In 2012, a Mayo Clinic study described a sprue-like enteropathy in patients on olmesartan, which resolved with discontinuation of the medication [2]. This led to a safety warning issued by the Food and Drug Administration (FDA) in 2013 [3]. Ever since, there have been a few case reports in the published literature about this adverse effect [4–7]. However, despite the safety warning and reported side effects, this medication continues to be popular due to its limited interaction with other medications and its effectiveness in reducing blood pressure. Symptoms of enteropathy can be disabling for patients, and physicians may resort to extensive testing to diagnose the etiology of diarrhea and weight loss. In individuals who take olmesartan, the mere discontinuation of the medication leads to prompt resolution of the symptoms [8]. Our case report with a brief review of pertinent literature, aims to increase the awareness among physicians of olmesartan-induced enteropathy (OAE)

Case Report

A 59-year-old Caucasian male presented to our Emergency Department (ED) with complaints of vomiting, diarrhea, and a 25-pound weight loss. His symptoms started 3 weeks prior and had progressively worsened over time to the extent that he vomited anything that he ate or drank, and he was experiencing more than 10 loose bowel movements every day. He also complained of abdominal cramping which was unrelieved by over-the-counter medications, fasting, or bowel movements. His medical history was significant for hypertension, hypothyroidism, and reflux disease; and his home medications included metoprolol succinate, amlodipine, lansoprazole, olmesartan, and levothyroxine.

In the ED, his abdominal examination was noted to be normal with no guarding or rigidity. Laboratory findings were significant for mild hypokalemia of 3.4 meq/dL and a creatinine of 1.85 mg/dL. Computerized tomography scan of abdomen and pelvis in the ED showed nonspecific scattered air fluid levels with non-dilated small and large bowel loops suggestive of enterocolitis. He was admitted to the hospital for clinical dehydration and was started on intravenous fluids and antiemetics. Stool studies for ova, parasites, *Clostridium difficile*, and other infections were negative. His IgA was 257 mg/dL and

his tissue transglutaminase antibodies were less than 20 units, ruling out celiac disease. He continued to have loose stools in the hospital and a Gastroenterology consult was obtained. A colonoscopy was performed. There were no inflammatory or neoplastic changes noted anywhere in the colon (Figures 1, 2). Random biopsies were taken of the ascending and distal descending colon. The pathology report revealed lymphocytic colitis within the ascending and descending colon (Figure 3). The patient was discharged a day after his colonoscopy with the diagnosis of microcytic/lymphocytic colitis and a follow-up outpatient visit to the Gastroenterology clinic was arranged.

The patient continued to have abdominal pain, nausea, vomiting, and diarrhea despite treatment with antidiarrheal agents. At a follow-up office appointment, he had an upper gastrointestinal endoscopy (UGIE) which was unremarkable; however, a biopsy of stomach tissue showed lymphocytic gastritis (Figure 4). Random biopsies of the duodenum revealed marked chronic duodenitis with near-total villous blunting (Figure 5).

A detailed review of the patient's medication was undertaken, and it was thought that his symptoms and pathology findings could be related to olmesartan use. Olmesartan was stopped and his symptoms began to abate. A few months later, he underwent a repeat UGIE, and a biopsy of the duodenum showed normalization of small intestinal mucosa (Figure 6).

Discussion

Olmesartan medoxomil is an angiotensin receptor antagonist that has been used for the management of hypertension since 2002. It acts by blocking the angiotensin-II receptor and is usually well tolerated except for minor side effects including headache, influenza-like symptoms, and dizziness [1]. A decade after its introduction into the market, a sprue-like enteropathy was described in association with its use. In a study by Rubio-Tapia et al, many patients on olmesartan developed diarrhea and weight loss. All of them had negative serology for celiac disease but were noted to have intestinal villous atrophy, mucosal inflammation, and subepithelial collagen deposition which reverted to complete normalcy once the drug was discontinued [2]. This led to FDA to issue a safety alert about sprue-like enteropathy in patients using olmesartan [3]. In response to this much publicized study, another large study looked at an association of enteropathy with olmesartan use from the Randomized Olmesartan and Diabetes Micro Albuminuria Prevention (ROADMAP) trial database which reported no association between olmesartan and enteropathy resembling celiac disease [9,10]. Despite these contradictory reports, many single-centered case studies and large nationwide surveys done in Europe continued to report findings similar to Rubio-Tapia et al. [8,11–13].

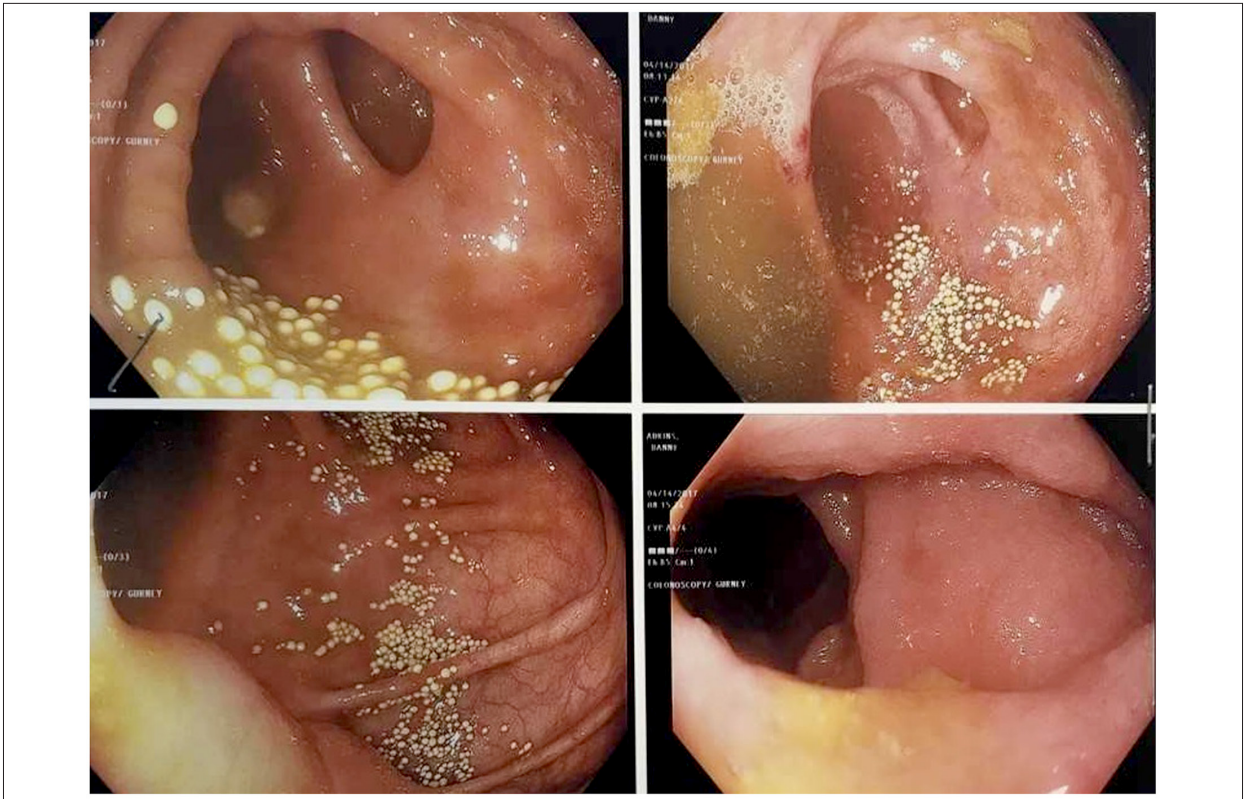


Figure 1. Colonoscopy showing normal ileocecal valve and ascending colon.

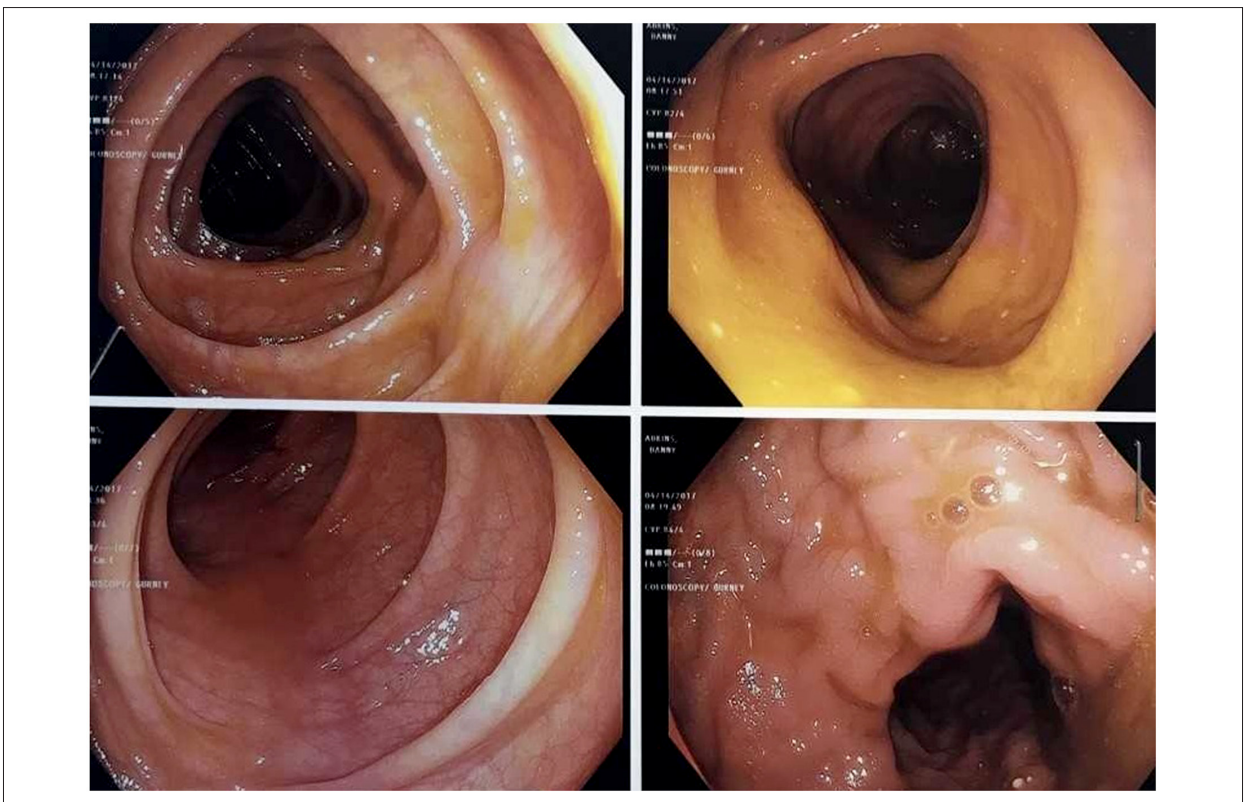


Figure 2. Sigmoid and transverse colon with no obvious pathology.

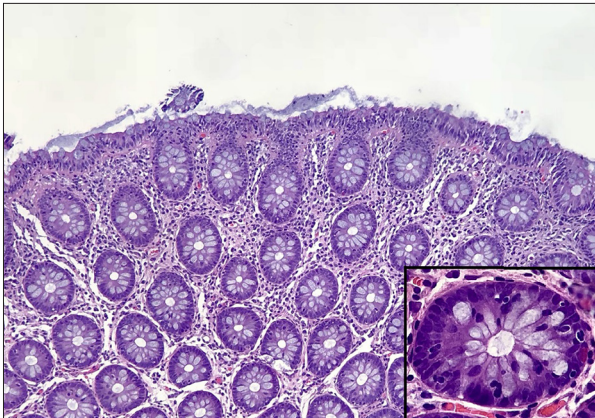


Figure 3. Colonic biopsy showing mucosal gland with many small lymphocytes infiltrating the glandular epithelium, mimicking lymphocytic colitis. Hematoxylin and eosin 100x. Inset showing higher magnification of colonic mucosal glands 400x.

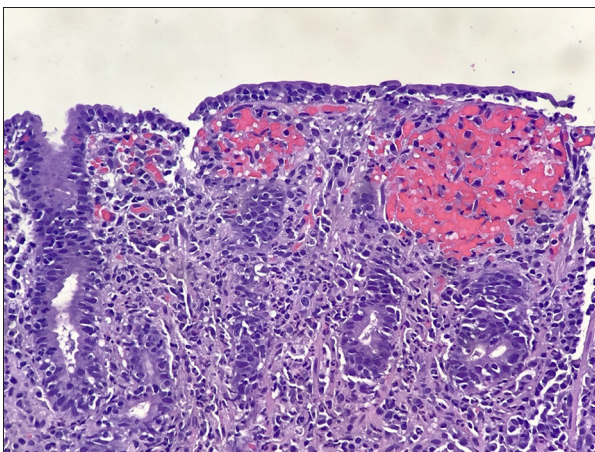


Figure 4. Biopsy from stomach showing chronic gastritis with lymphocytic infiltration of gastric pit and overlying epithelium. Hematoxylin and eosin 100x.

OAE typically presents with non-bloody diarrhea, characterized by numerous liquid stools daily, crampy abdominal pain, vomiting, and weight loss [14]. These symptoms may be complicated by severe dehydration, acute renal failure, electrolyte abnormalities, and can sometimes lead to hospitalization [4]. An occasional case report of colonic perforation has been reported [15]. Most patients are usually in the sixth to eighth decade of life and there is no particular gender predisposition [11]. The time between olmesartan exposure and onset of symptoms is very variable and ranges from less than a few months to 5 years, the mean duration of exposure was about 3 years [6,14]. Hence, it is possible that patients may have been on olmesartan for a long period of time without any noticeable side effect.

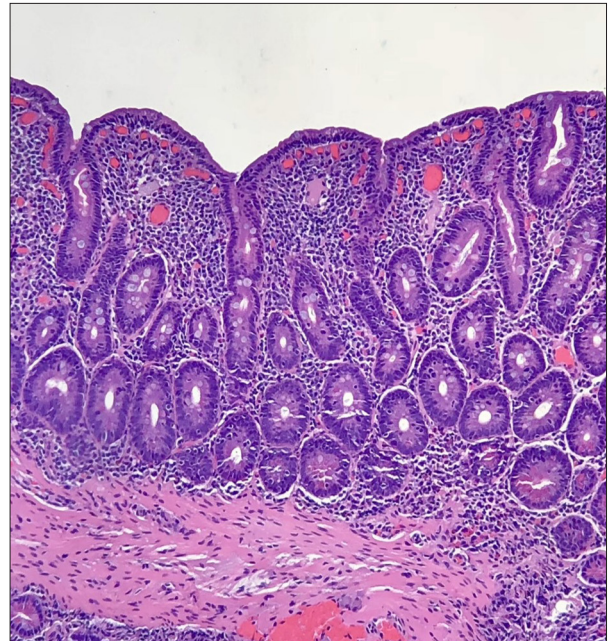


Figure 5. Biopsy from duodenum with villous flattening and crypt hyperplasia mimicking celiac disease. Hematoxylin and eosin 100x.

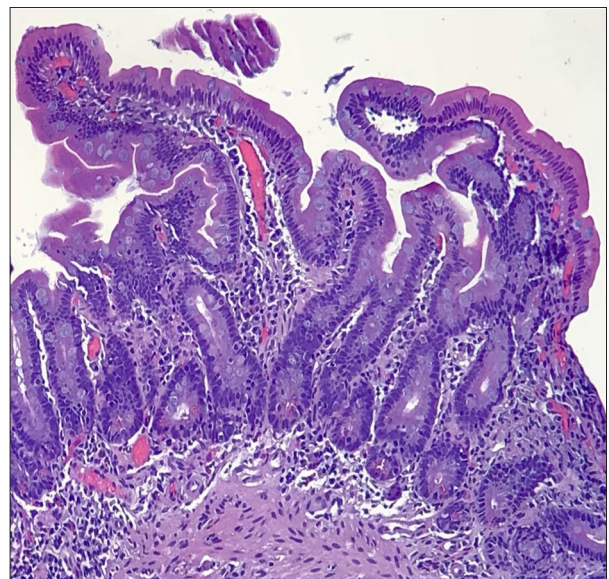


Figure 6. Repeat duodenal biopsy after 6 months showing restoration of normal villous architecture. Hematoxylin and eosin 100x.

The most common laboratory abnormalities seen in patients with OAE include, normocytic normochromic anemia, hypoalbuminemia, elevated transaminases, and electrolyte imbalances including hypokalemia and hypocalcemia [11–13]. Celiac serology including anti-transglutaminase, anti-gliadin, or anti-endomysial antibodies are always negative [13]. Some patients have demonstrated anti-enterocyte/antinuclear antibodies [13].

An association between HLA-DQ2 or HLA-DQ8 was also noted in a few cases [8,11,14]. In patients who undergo endoscopy, nonspecific findings such as nodular appearance of duodenum with partial to complete flattening of villi and occasional ulceration have been noted [11,12,14]. Pathological examination has shown varying grades of villous atrophy in the duodenum along with intra epithelial lymphocytosis (IEL) and subepithelial collagen deposition [2,4,7,11,12,14,16]. While increased IEL is a consistent feature noted in over 61% of pathology specimens, subepithelial collagen deposition was noted only in 22% [11]. Biopsies from other parts of the gastrointestinal tract also demonstrated variable changes. The stomach showed collagenous and or lymphocytic gastritis and colonoscopic biopsies showed feature of microscopic/lymphocytic colitis characterized by increased IEL, variable subepithelial collagen deposition, chronic inflammation of lamina propria, and colonic crypt apoptosis [11,16]. However, none of these biopsy features were statistically significant to be a pathological marker of OAE.

The differential diagnosis for this kind of clinical and pathological features include celiac disease, tropical sprue, autoimmune enteropathy, inflammatory bowel disease, and drug induced enteropathy [14,16]. Other clinical conditions which need to be excluded in patients with chronic diarrhea include infections disorders such as *C. difficile* colitis, small intestinal bacterial overgrowth (SIBO), intestinal lymphomas, and combined variable immunodeficiency disease [14,16,17]. Clinical distinction between these conditions can be made based on supporting laboratory features and tissue biopsy. SIBO has been reported to coexist in cases of OAE, however, in such cases symptoms resolve after olmesartan is stopped, where as in SIBO, a prolonged course of antibiotics is usually curative [14]. At times, biopsies have shown predominantly villous atrophy and IEL, which may be seen in other diseases entities. Serological markers such as anti-transglutaminase and anti-gliadin antibodies help confirm the diagnosis of celiac disease in patients who have villous atrophy. In cases wherein serological markers are negative, the diagnosis remains broad. Tropical sprue, autoimmune enteropathy, and many drug-induced enteropathies have similar presentation but can be distinguishing from OAE based on histopathological features [16]. Tropical sprue usually has a preserved architecture of villi and the IEL is predominantly in the terminal ileum than duodenum. Autoimmune enteropathy has many overlapping features with OAE and clinical history becomes extremely important to distinguish one from another [14,16].

A careful medication history is important as certain medications are known to cause enteropathies. Drug-induced enteropathy usually shows increased crypt apoptosis, but some cases may also show IEL and/or villous atrophy. It is commonly seen with mycophenolate mofetil, methotrexate, azathioprine, colchicine, and non-steroidal anti-inflammatory drugs. Olmesartan

is a recent inclusion to this class of medications causing drug-induced enteropathy. Before the first description of OAE in 2012, many seronegative enteropathies with villous atrophy were classified as unclassified sprue. In a large study done by DeGaetani et al, several cases of unclassified sprue were later re-classified as OAE [18]. In patients with OAE, small intestinal biopsies showed increased IEL, flattening of villi, and variable subepithelial collagen deposition [11,16].

The exact mechanism of action of OAE is unclear. However, given the long period between exposure and symptoms onset, a cell mediated immunity rather than a type 1 hypersensitivity is thought to be the reason for this drug reaction [2]. It is thought that the ARB class of drugs have an inhibitory action of transforming growth factor beta (TGF- β) which is important for the gut homeostasis and hence a predilection for the intestine. Villous atrophy is believed to be the result of a pro-apoptotic effect of angiotensin-II on intestinal epithelial cells. In the gut, angiotensin-II binds to angiotensin II receptor type 1 (AT1) which are present throughout the gut activating growth promoting factors and mediating the major effects of angiotensin in sodium and water homeostasis. When angiotensin binds to angiotensin II receptor type 2 (AT 2) located specifically in the duodenum and jejunum, it exerts an opposing effect inducing apoptosis. Olmesartan, which is an angiotensin receptor blocking agent has a high affinity for AT 1 and due to the drug induced AT 1 blockade, circulating angiotensin is left to bind to the AT 2 in the upper small intestine leading to increased apoptosis and loss of villi [7]. There is also a suggestion of upregulation of pro-apoptotic proteins like Bax and GATA-6 and downregulation of BCL-2 all of which lead to apoptotic loss of intestinal epithelial cells resulting in atrophy of the villi [11]. It is also believed that olmesartan is converted to its active metabolite in the intestine, therefore more changes are seen here than elsewhere [12]. All cases of OAE show complete resolution of symptoms and normalization of intestinal mucosa within a few weeks after cessation of the medication. Olmesartan re-challenge was not documented in published literature except one case report which described recurrence of symptoms once medication was restarted [5,14,18]. It is unknown whether this can be considered an all class effect of ARB agents. Many have reported this side effect only among olmesartan users [19], although there have been case reports about telmisartan also causing a sprue-like enteropathy [20].

Treatment of OAE involves stopping the drug. In severe cases, oral or intravenous steroids have alleviated the symptoms. Other than a single case report of colonic perforation, no other major morbidities were reported and there has not been a single report of death associated with this condition. Hujuel and Rubio-Tapia [21] in a more recently published article describe a practical algorithm for workup and treatment of patients with seronegative enteropathy, wherein they state that

the first step after testing for celiac disease is a detailed review of the patient's medication. In the same report [21], there was also a mention that patients who continue to have symptoms despite withdrawal of olmesartan may benefit from a short course of either oral budesonide or parenteral steroids. Thus far, reviews of literature have shown that the spectrum of gastrointestinal injury associated with olmesartan is extensive and variable with histological changes seen at different levels including the stomach, small intestine and colon [6,19]. More studies need to be done in a prospective fashion to elucidate the exact pathogenic mechanism by which these changes are induced and also to see if such changes can be seen with other newer classes of ARBs such as azilsartan [16,19].

Our patient had clinical features suggesting celiac disease, however, initial workup revealed negative serology and colon biopsy was consistent with lymphocytic colitis which could also cause diarrhea. An UGIE done subsequently showed marked villous atrophy and lymphocytic gastritis prompting a review of the patient's medication list. Olmesartan was stopped and his symptoms resolved. A re challenge with olmesartan was not done as his symptoms were very distressing and had even led to hospitalization. The fact that a through workup for chronic diarrhea was negative for all known conditions and that his symptoms improved after stopping olmesartan led us to believe that this was indeed a case of OAE.

References:

- Norwood D, Branch E, Smith B, Honeywell M: Olmesartan medoxomil for hypertension: A clinical review. *Drug Forecast*, 2002; 27: 611–18
- Rubio-Tapia A, Herman ML, Ludvigsson JF et al: Severe sprue-like enteropathy associated with olmesartan. *Mayo Clin Proc*, 2012; 8: 732–38
- FDA Drug Safety Communication: FDA approves label changes to include intestinal problems (sprue-like enteropathy) linked to blood pressure medicine olmesartan medoxomil. (2013, July3). Retrieved from <https://www.fda.gov/downloads/Drugs/DrugSafety/UCM359496.pdf>
- Theophile H, David XR, Miremont-Salame G, Haramburu F: Five cases of sprue-like enteropathy in patients treated by olmesartan. *Dig Liver Dis*, 2014; 46: 465–69
- Kulai T, Arnason T, MacIntosh D, Igoe J: Duodenal villous atrophy in a TTG-negative patient taking olmesartan: A case report and review of the literature. *Canadian J Gastroenterol Hepatol*, 2016; 2016: 6091571
- Adike A, Corral J, Rybnicek D et al: Olmesartan-induced enteropathy. *Methodist DeBakey Cardiovasc J*, 2016; 12: 230–32
- Galanopoulos M, Varytimiadis L, Tsigaridas A et al: Small bowel enteropathy associated with olmesartan medoxomil treatment. *Ann Gastroenterol*, 2016; 29: 1–3
- Nielsen JA, Steephen A, Lewin M: Angiotensin-II inhibitor (olmesartan)-induced collagenous sprue with resolution following discontinuation of drug. *World J Gastroenterol*, 2013; 19: 6928–30
- Menne J, Haller H: Olmesartan and intestinal adverse effects in the ROADMAP Study. *Mayo Clin Proc*, 2012; 87: 1230–31
- Greywoode R, Braunstein ED, Arguelles-Grande C et al: Olmesartan, other anti-hypertensives, and chronic diarrhea among patients undergoing endoscopic procedures: A case-control study. *Mayo Clin Proc*, 2014; 89: 1239–43
- Ianiro G, Bibbò S, Montalto M et al: Systematic review: Sprue like enteropathy associated with olmesartan. *Aliment Pharmacol Ther*, 2014; 40: 16–23
- Eusébio M, Caldeira P, Antunes AG et al: Olmesartan-induced enteropathy: An unusual cause of villous atrophy. *GE Port J Gastroenterol* 2016;23: 91–95
- Marthey L, Cadiot G, Seksik P et al: Olmesartan associated enteropathy: Results of a national survey. *Aliment Pharmacol Ther*, 2014; 40: 1103–9
- Choi E-YK, McKenna BJ: Olmesartan-associated enteropathy: A review of clinical and histologic findings. *Arch Pathol Lab Med*, 2015; 139: 1242–47
- Abdelghany M, Gonzalez L 3rd, Slater J, Begley C: Olmesartan associated sprue-like enteropathy and colon perforation. *Case Rep Gastrointest Med*, 2014; 2014: 494098
- Burbure N, Leibold B, Arguelles-Grande C et al: Olmesartan-associated sprue-like enteropathy: A systematic review with emphasis on histopathology. *Hum Pathol*, 2016; 50: 127–34
- Kamboj AK, Oxentenko AS: Clinical and histologic mimickers of celiac disease. *Clin Transl Gastroenterol*, 2017; 8(8): e114
- DeGaetani M, Tennyson CA, Leibold B et al: Villous atrophy and negative celiac serology: A diagnostic and therapeutic dilemma. *Am J Gastroenterol*, 2013; 108: 647–53
- Lagana SM, Braunstein ED, Arguelles-Grande C et al: Sprue-like histology in patients with abdominal pain taking olmesartan compared with other angiotensin receptor blockers. *J Clin Pathol*, 2015; 68: 29–32
- Negro A, De Marco L, Cesario V et al: A case of moderate sprue-like enteropathy associated with telmisartan. *J Clin Med Res*, 2017; 9: 1022–25
- Hujoel IA, Rubio-Tapia A: Sprue-like enteropathy associated with olmesartan: A new kid on the enteropathy block. *GE Port J Gastroenterol*, 2016; 23: 61–65

Conclusions

A clear association between olmesartan and seronegative sprue-like enteropathy is emerging, and physicians need to be aware of the possibility of this rare drug-induced side effect and understand that this is potentially reversible after discontinuation of the medication. Extensive investigation for chronic diarrhea in patients on olmesartan should be avoided and these patients should be given an olmesartan drug free interval to see if symptoms resolve prior to pursuing further workup. As olmesartan is used worldwide, clinicians need to be cognizant of this remote side effect in order to reduce unnecessary diagnostic testing.

Acknowledgements

The authors would like to acknowledge Daniel Wasdahl, MD, Associate Professor of Pathology, North East Ohio Medical University (NEOMED) for reviewing and obtaining the histopathology images for this manuscript. The authors would also like to thank Joscelyn Greaves, CNP, Gastroenterology Specialists for her help in getting the patient's clinical history.

Conflict of interest

None.