

Available online at [www.sciencedirect.com](http://www.sciencedirect.com)

ScienceDirect

journal homepage: [www.elsevier.com/locate/radcr](http://www.elsevier.com/locate/radcr)

## Case Report

# Uterine artery pseudoaneurysm following cesarean section; a case report

Shahab Shayesteh, MD, Daniel Fadaei Fouladi, MD, Linda C. Chu, MD\*,  
Elliot K. Fishman, MD

The Russell H. Morgan Department of Radiology and Radiological Science, Johns Hopkins University School of Medicine, Baltimore, MD, USA

## ARTICLE INFO

## Article history:

Received 30 January 2020

Revised 26 February 2020

Accepted 26 February 2020

## Keywords:

Doppler ultrasound

Intrauterine device

Computed tomography

Uterine artery pseudoaneurysm

Cesarean section

Case report

## ABSTRACT

Uterine artery pseudoaneurysm is an uncommon cause of vaginal bleeding that can occur after cesarean, hysterectomy, myomectomy, uncomplicated vaginal delivery, as well as gynecologic surgery. A 29-year-old woman (G4P1122) who underwent stat cesarean section and intrauterine device placement was found to have a 1.6-cm left uterine artery pseudoaneurysm on follow-up ultrasound. The patient presented to interventional radiology for angiography and uterine artery embolization to minimize the risk of spontaneous hemorrhage. This is the rare reported case, to our knowledge, of a uterine artery pseudoaneurysm associated with a recent cesarean section. Computed tomography angiogram, with multiplanar and maximal intensity projection images, can optimally display the pseudoaneurysm and the feeding vessel, which can provide valuable information for image-guided catheter embolization.

© 2020 The Authors. Published by Elsevier Inc. on behalf of University of Washington.

This is an open access article under the CC BY-NC-ND license.

(<http://creativecommons.org/licenses/by-nc-nd/4.0/>)

## Introduction

A pseudoaneurysm is a blood-filled cavity with turbulent flow communicating with the parent vessel leading to a deficiency of the arterial wall. Pseudoaneurysm of the uterine artery—a rare, life-threatening complication causing vaginal bleeding—has been associated with cesarean or vaginal delivery and gynecologic surgery [1].

Typically, patients are diagnosed due to rupture of the pseudoaneurysm, leading to hemorrhage [2]. Doppler sonography and arteriography are usually used as a diagnostic test [3]. More importantly, transcatheter uterine artery emboliza-

tion (UAE) has emerged as an effective method to control obstetric and gynecologic hemorrhage [4], especially in the treatment of pseudoaneurysm after iatrogenic injury. We report a case of pseudoaneurysm of the left uterine artery presenting after the cesarean section.

## Case presentation

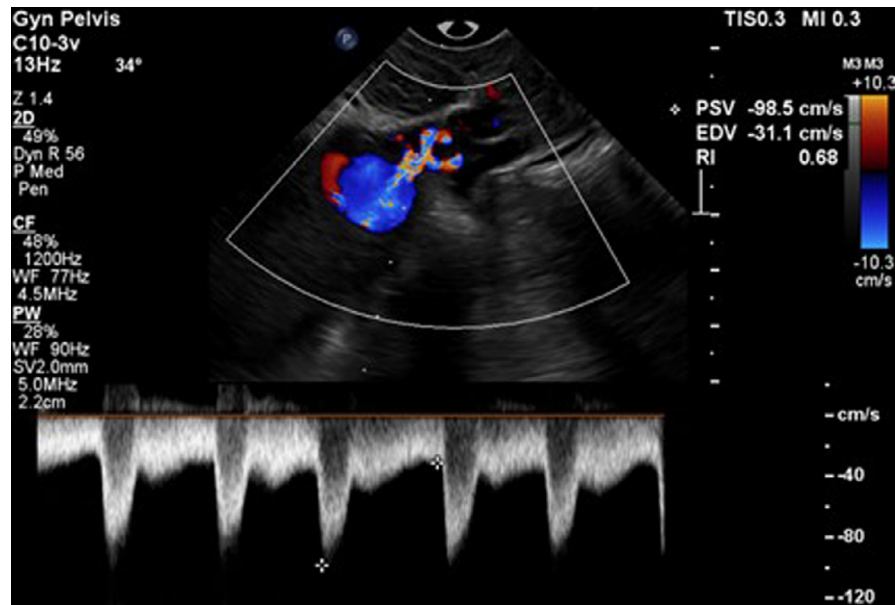
A 29-year-old woman (G4P1112) with a history of an unprovoked pulmonary embolism on anticoagulation, stat cesarean section 3 months prior to a presentation followed by postpar-

\* Corresponding author.

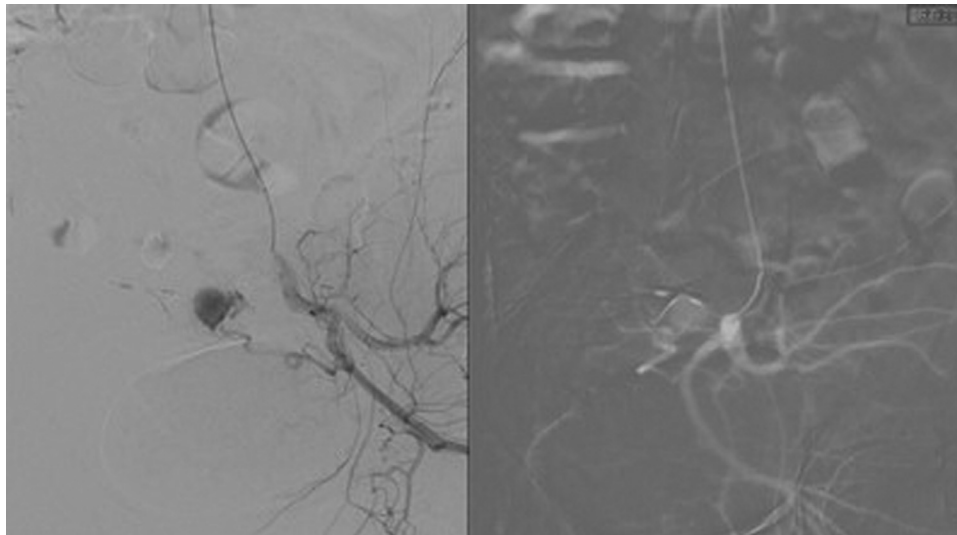
E-mail addresses: [sshyest1@jhmi.edu](mailto:sshyest1@jhmi.edu) (S. Shayesteh), [dfoulad1@jhmi.edu](mailto:dfoulad1@jhmi.edu) (D.F. Fouladi), [lchu1@jhmi.edu](mailto:lchu1@jhmi.edu) (L.C. Chu), [efishman@jhmi.edu](mailto:efishman@jhmi.edu) (E.K. Fishman).

<https://doi.org/10.1016/j.radcr.2020.02.032>

1930-0433/© 2020 The Authors. Published by Elsevier Inc. on behalf of University of Washington. This is an open access article under the CC BY-NC-ND license. (<http://creativecommons.org/licenses/by-nc-nd/4.0/>)



**Fig. 1 – Color Doppler ultrasound image shows a vascular structure in the uterus with typical “yin yang” appearance and narrow connection with the adjacent vessel, compatible with a left uterine artery pseudoaneurysm.**

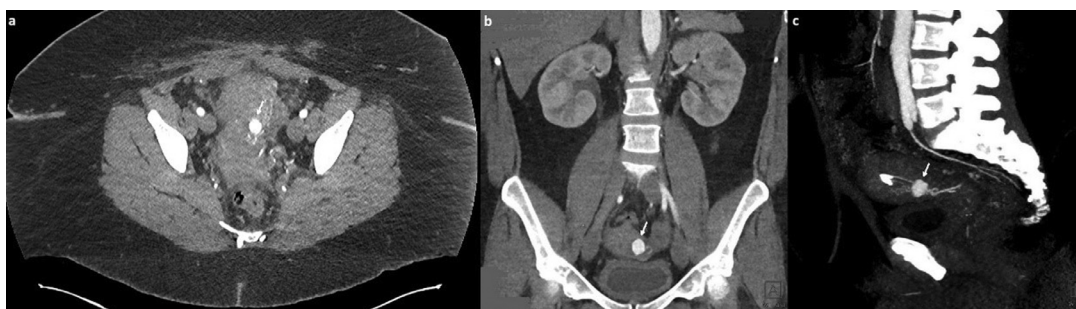


**Fig. 2 – Angiogram shows a pseudoaneurysm arising from the left uterine artery.**

tum ParaGard intrauterine device (IUD) placement, was transported from an outside hospital due to concern for a vascular abnormality within her cervix on a sonogram.

She had been on therapeutic anticoagulation for 2 years when she was diagnosed with an unprovoked pulmonary embolism. She initially was on rivaroxaban, but during her pregnancy transitioned to enoxaparin, which has continued since delivery. The patient denied any clinical symptoms of vaginal pain or bleeding. She did not have abdominal pain, dizziness, or dysuria. She had a regular period with normal bleeding, which is a moderate flow. Her recent small amount of bleeding was associated with no vaginal discharge or pelvic pain. On presentation, her vital signs included a temperature of

36.6 C, heart rate 92, respiratory rate 18 breath/min, and blood pressure 163/89 mm Hg. Physical examination revealed good appearance with no acute distress, regular heart rate, and clear lung field. Her abdominal wall was soft and nontender. Pelvic examination revealed normal external genitalia, vulva, vagina, cervix, uterus, and adnexa. Her hemoglobin level was 9.6 g/dL. Pelvic ultrasound demonstrated a 1.6-cm aneurysm in the left lower uterine segment corresponding to the abnormality (Fig. 1). Intravenous (IV) contrast-enhanced computed tomography (CT) angiogram of the chest, abdomen, and pelvis was performed. Images show a 1.6-cm contrast collection with the same attenuation as a blood pool within the left aspect of the uterus, compatible with a left uterine artery pseudoa-



**Fig. 3 – Axial contrast-enhanced CT demonstrates a contrast collection in the left aspect of the uterine, compatible with a left uterine artery pseudoaneurysm (arrow) (A). Coronal reconstruction shows the findings of the uterine artery pseudoaneurysm (B). Sagittal maximum intensity projection image better illustrates the connection between this pseudoaneurysm (arrow) and the left uterine artery (C).**

neurysm (Fig. 2). The origin from the left uterine artery is better visualized on multiplanar and maximal intensity projection images (Fig. 3A–C).

The etiology of the pseudoaneurysm is suspected to be associated with injury to a vessel during the cesarean section. Since the pseudoaneurysm poses an increased risk of spontaneous hemorrhage, the patient underwent angiography and UAE. Left UAE was applied successfully using seven ccs of Gelfoam.

## Discussion and conclusion

We report a 29-year-old woman who underwent a cesarean section and IUD placement, which was found to have a pseudoaneurysm of the left uterine artery on follow-up ultrasound. This vascular abnormality resulted from the disruption of the arterial wall. Blood flows around the damaged artery and dissects the adjacent tissue, then forming a sac that communicates with the arterial lumen. A true aneurysm consists of a three-layered wall, which differentiates it from a pseudoaneurysm [1].

If a pseudoaneurysm is not recognized, its enlargement and rupture can occur through the extraluminal turbulent flow, possibly leading to bleeding. Since the traumatic injury of the uterine artery wall leads to uterine artery pseudoaneurysms, it is crucial to consider it as a differential diagnosis when there is vaginal bleeding, especially in the postoperative setting or postpartum. Pseudoaneurysm of the uterine artery can occur due to dilatation and curettage, myomectomy, after an uncomplicated vaginal delivery, hysterectomy, and cesarean section [2]. Several diagnostic approaches use noninvasive radiological imaging techniques, including CT, magnetic resonance imaging, and ultrasound to identify pseudoaneurysm of the uterine artery [5].

Previously, surgical management, including internal iliac artery ligation and laparotomy, has been performed as a treatment [6]. Recently, image-guided catheter embolization has emerged as a reliable and cutting-edge method to treat uterine artery pseudoaneurysm [1]. Covered stent ultrasound-guided thrombin injection is another possible treatment requiring local expertise and the experience of an operator [7].

There are few case reports of a pseudoaneurysm of the uterine artery after gynecological procedures. Henrich et al reported one of the first cases in this regard in 2002 [8]. The patient was a 35-year-old (G2P2) woman admitted to the hospital due to increased vaginal bleeding and lower abdominal pain two weeks after cesarean section. A pseudoaneurysm was diagnosed on the basis of signs of the perfusion in Doppler transvaginal sonography. Arterial embolization was considered but, finally, on the patient's request, hysterectomy was performed. Her recovery was uneventful, and the patient was discharged two weeks after hysterectomy.

Another case report was presented by Yeniel et al in 2013 [9]. The patient was a 28-year-old female who developed postpartum hemorrhage after cesarean section. The aneurysmatic vessel was resected, and the right uterine artery was ligated to preserve fertility.

In another case report, Zimon et al described a 31-year-old patient who had moderate suprapubic pain 8 days postpartum [10]. A uterine artery pseudoaneurysm was diagnosed with ultrasound and confirmed by arteriography. The embolization of the left uterine artery was carried out without complication.

In 2011, Dasari et al reported on a 30-year-old patient with abdominal pain and profuse vaginal bleeding 3 weeks after cesarean section, who was found to have a left uterine artery pseudoaneurysm [11]. Imaging modalities were used to confirm the diagnosis. Bilateral internal iliac arteries were ligated since embolization facilities were not available. Follow-up sonography confirmed that the ligation was successful.

Compared to the available case reports in the literature, our patient was unique in terms of being asymptomatic, and the aneurysm was found incidentally following sonography performed after insertion of an IUD. Angiography and UAE were conducted for the patient to decrease the risk of spontaneous bleeding, and she was discharged from the hospital without any complication.

## Acknowledgment

The authors thank senior science editor Edmund Weisberg, MS, MBE, who helped us to review and edit the article.

## REFERENCES

- 
- [1] Kwon JH, Kim GS. Obstetric iatrogenic arterial injuries of the uterus: diagnosis with US and treatment with transcatheter arterial embolization. *Radiographics* 2002;22(1):35–46.
- [2] Langer JE, Cope C. Ultrasonographic diagnosis of uterine artery pseudoaneurysm after hysterectomy. *J Ultrasound Med* 1999;18(10):711–14.
- [3] Hidar S, Bibi M, Atallah R, Essakly K, Bouzakoura C, Hidar M. [Pseudoaneurysm of the uterine artery: apropos of 1 case]. *J Gynecol Obstet Biol Reprod (Paris)* 2000;29(6):621–4.
- [4] Nanjundan P, Rohilla M, Raveendran A, Jain V, Khandelwal N. Pseudoaneurysm of uterine artery: a rare cause of secondary postpartum hemorrhage, managed with uterine artery embolisation. *J Clin Imaging Sci* 2011;1(1):14.
- [5] Belli S, Parlakgumus A, Colakoglu T, Ezer A, Yildirim S, Moray G, et al. Surgical treatment modalities for complicated aneurysms and pseudoaneurysms of arteriovenous fistulas. *J Vasc Access* 2012;13(4):438–45.
- [6] Descargues G, Douvrin F, Gravier A, Lemoine JP, Marpeau L, Clavier E. False aneurysm of the uterine pedicle: an uncommon cause of postpartum haemorrhage after caesarean section treated with selective arterial embolization. *Eur J Obstet Gynecol Reprod Biol* 2001;97(1):26–9.
- [7] Jesinger RA, Thoreson AA, Lamba R. Abdominal and pelvic aneurysms and pseudoaneurysms: imaging review with clinical, radiologic, and treatment correlation. *Radiographics* 2013;33(3):E71–96.
- [8] Henrich W, Fuchs I, Luttkus A, Hauptmann S, Dudenhausen JW. Pseudoaneurysm of the uterine artery after cesarean delivery: sonographic diagnosis and treatment. *J Ultrasound Med* 2002;21(12):1431–4.
- [9] Yeniel AO, Ergenoglu AM, Akdemir A, Eminov E, Akercan F, Karadadas N. Massive secondary postpartum hemorrhage with uterine artery pseudoaneurysm after cesarean section. *Case Rep Obstet Gynecol* 2013;2013:285846.
- [10] Zimon AE, Hwang JK, Principe DL, Bahado-Singh RO. Pseudoaneurysm of the uterine artery. *Obstet Gynecol* 1999;94(5 Pt 2):827–30.
- [11] Dasari P, Maurya DK, Mascarenhas M. Uterine artery pseudoaneurysm: a rare cause of secondary postpartum haemorrhage following caesarean section. *BMJ Case Rep* 2011;2011:bcr0120113709.