




## CASE REPORT

# SARS-CoV-2–related ARDS in a maintenance hemodialysis patient: case report on tailored approach by daily hemodialysis, noninvasive ventilation, tocilizumab, anxiolytics, and point-of-care ultrasound

Andrea Galassi<sup>1</sup>  | Francesca Casanova<sup>2</sup> | Lidia Gazzola<sup>3</sup> | Rocco Rinaldo<sup>4</sup> | Marco Ceresa<sup>5</sup> | Elena Restelli<sup>2</sup> | Alessia Giorgini<sup>6</sup> | Simone Birocchi<sup>2</sup> | Marco Giovenzana<sup>7</sup> | Ulisse Zoni<sup>2</sup> | Federica Valli<sup>8</sup> | Laura Massironi<sup>8</sup> | Sebastiano Belletti<sup>8</sup> | Lorenza Magagnoli<sup>1</sup> | Andrea Stucchi<sup>1</sup> | Michela Ippolito<sup>1</sup> | Stefano Carugo<sup>8</sup>  | Elena Parazzini<sup>4</sup> | Mario Cozzolino<sup>1,9</sup> 

<sup>1</sup>Renal & Dialysis Unit, S. Paolo Hospital, ASST Santi Paolo e Carlo, Milan, Italy

<sup>2</sup>Internal Medicine Unit, S. Paolo Hospital, ASST Santi Paolo e Carlo, Milan, Italy

<sup>3</sup>Department of Health Sciences, Clinic of Infectious Disease, “San Paolo” Hospital-University of Milan, Milan, Italy

<sup>4</sup>Respiratory Unit, Department of Health Sciences, University of Milan, ASST Santi Paolo e Carlo, Milan, Italy

<sup>5</sup>Palliative Care Unit, S. Paolo Hospital, ASST Santi Paolo e Carlo, Milan, Italy

<sup>6</sup>Gastroenterology and Hepatology Unit, S. Paolo Hospital, ASST Santi Paolo e Carlo, Milan, Italy

<sup>7</sup>Unit of Hepatobiliary, Pancreatic, and Digestive Surgery, Department of Surgery, S. Paolo Hospital, University of Milan, Milan, Italy

<sup>8</sup>Division of Cardiology, S. Paolo Hospital, University of Milan, Milan, Italy

<sup>9</sup>Department of Health Sciences, University of Milan, Milan, Italy

## Correspondence

Andrea Galassi, Renal & Dialysis Unit, S. Paolo Hospital, ASST Santi Paolo e Carlo, Milan, Italy.

Email: andrea.galassi@asst-santipaolocarlo.it

## Abstract

Without rescue drugs approved, holistic approach by daily hemodialysis, noninvasive ventilation, anti-inflammatory medications, fluid assessment by bedside ultrasound, and anxiolytics improved outcomes of a maintenance hemodialysis patient affected by severe COVID-19.

## KEY WORDS

COVID-19, expanded hemodialysis, hemodialysis, point-of-care ultrasound, suprahepatic veins venogram, tocilizumab

# 1 | INTRODUCTION

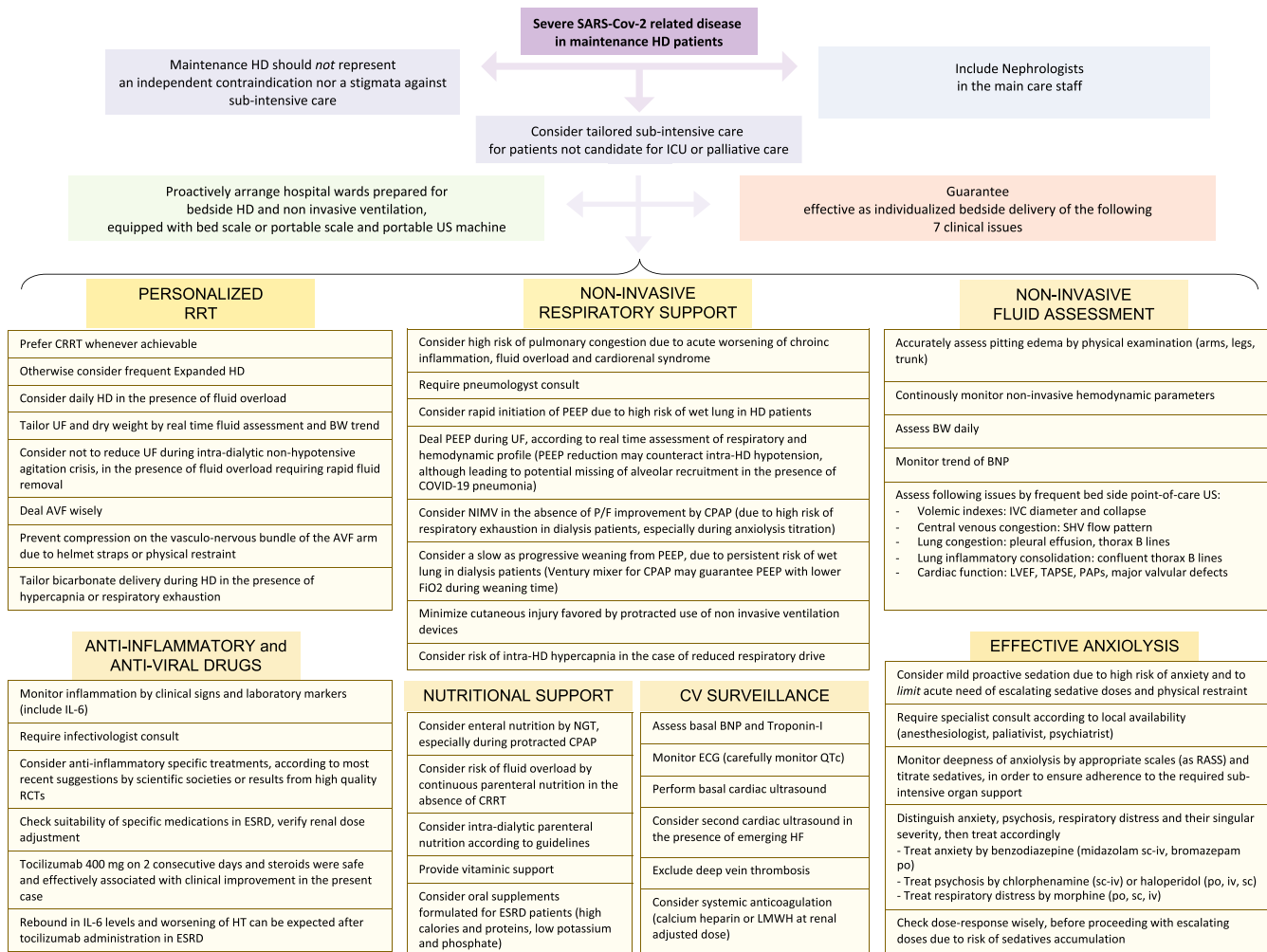
A 50-year-old man, on maintenance hemodialysis, was affected by SARS-CoV-2-related acute respiratory distress syndrome. Multipronged intervention included daily expanded hemodialysis, noninvasive ventilation, anti-inflammatory medications, fluid assessment by point-of-care ultrasound, and anxiolytics. Individualized subintensive care improved outcomes of a maintenance hemodialysis (MHD) patient affected by severe SARS-CoV-2-associated disease.

SARS-CoV-2-related disease (COVID-19) affected MHD patients,<sup>1-3</sup> leading to high rate of hospitalization (61%),<sup>2</sup> acute respiratory distress syndrome (ARDS) (79%),<sup>2</sup> and mortality (11%-29%) in Europe.<sup>2,3</sup> Cardiovascular disease resulted a strong independent predictor of worse outcomes.<sup>1,2</sup>

Suggestions were published on how to prevent interhuman transmission of SARS-CoV-2 within facilities<sup>4</sup> and treating COVID-19 in HD patients.<sup>5,6</sup> Although a gold standard of care remains uncertain, without a single intervention capable of healing the disease has yet been identified, several clinical issues could be relevant for caring MHD patients affected by severe COVID-19.

Tailored management of fluids represents a mainstay for treating COVID-19 critical cases.<sup>6,7</sup> Point-of-care ultrasound (US) was suggested for improving therapy of patients,<sup>7-9</sup> at high risk of developing SARS-CoV-2-related ARDS and acute cardiovascular syndrome, precipitating in heart failure, fluid overload, and death.<sup>10-12</sup>

Neurological involvement was described in SARS-CoV-2 infection, including high incidence of anxiety and delirium.<sup>13-16</sup> Although monitoring and treatment of



**FIGURE 1** Clinical issues suggested by the case, for treating COVID-19 in critically ill MHD patients. AVF, arteriovenous fistula; BNP, brain natriuretic peptide; CPAP, continuous positive airway pressure; CRRT, continuous renal replacement therapy; ECG, electrocardiography; HD, hemodialysis; ICU, intensive care unit; IL-6, interleukin-6; Iv, intravenously; LVEF, ejection fraction; NGT, nasogastric tube; NIMV, noninvasive mechanical ventilation; PAPs, pulmonary arterial pressures; PEEP, positive end respiratory pressure; Po, per os; RASS, Richmond Agitation Sedation Scale; Sc, subcutaneously; TAPSE, tricuspid annular plane systolic excursion

anxiety in COVID-19 were discussed in intensive care unit (ICU),<sup>14</sup> strategies tailored on MHD patients are unexplored.

Case reports on COVID-19 MHD patients were reported.<sup>17-21</sup> We herein describe the case of a 50-year-old hemodialysis (HD) man, affected by COVID-19-related ARDS, successfully treated in subintensive setting, who developed severe fluid overload, acute myocardial insufficiency, and anxiety, requiring daily dialysis, noninvasive ventilation, anxiolytics, tocilizumab, steroids, and fluid assessment by point-of-care US.

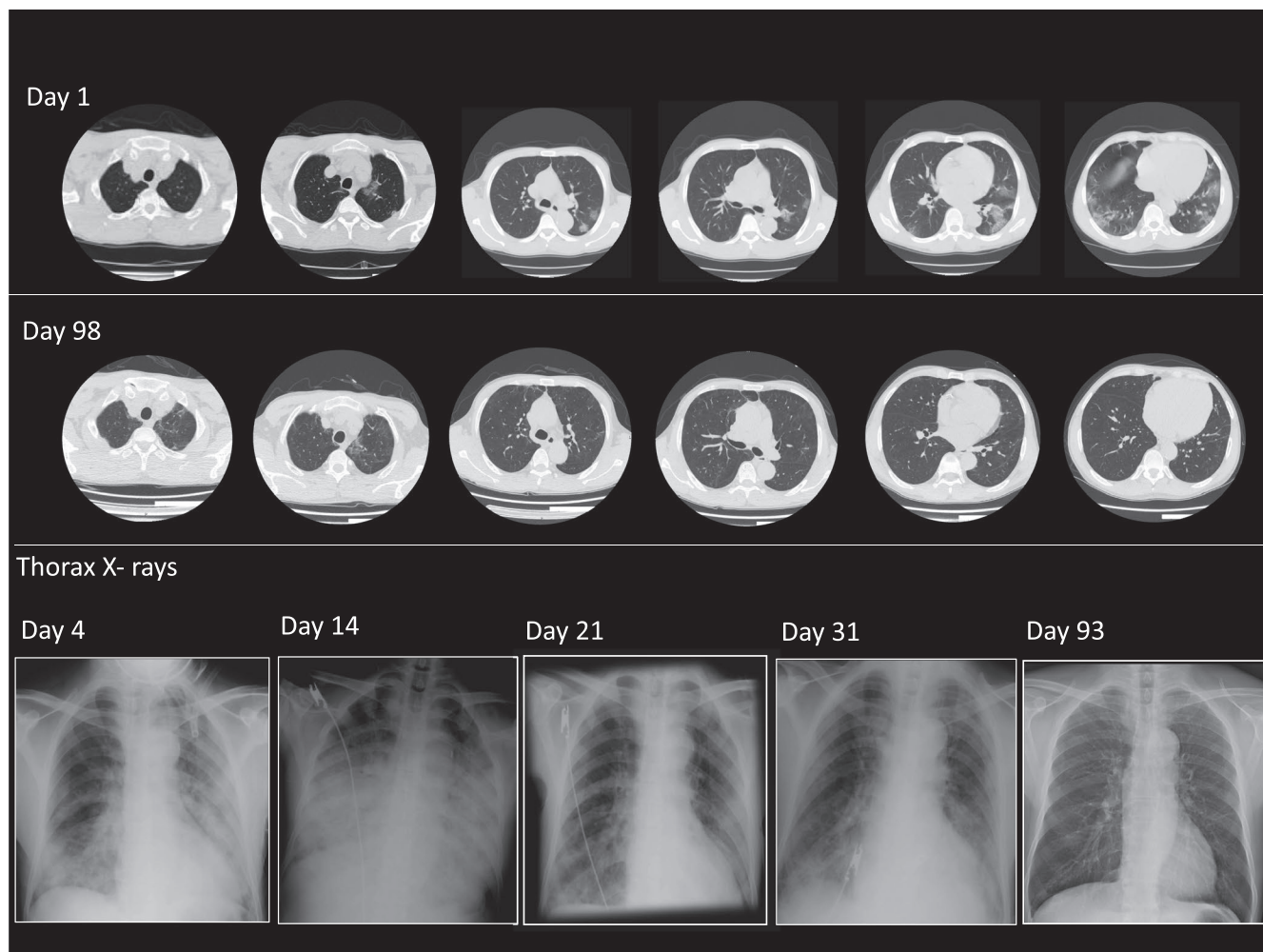
Clinical messages are summarized (Figures 1-4, Figures S1-S7, Table S1). Assessment of dynamic trend in suprahepatic veins (SHV) venogram is categorized and discussed as potential tool, for improving real-time diagnosis of venous return and tailoring fluid management in critically ill dialysis patients (Figure 4).

## 2 | CASE PRESENTATION

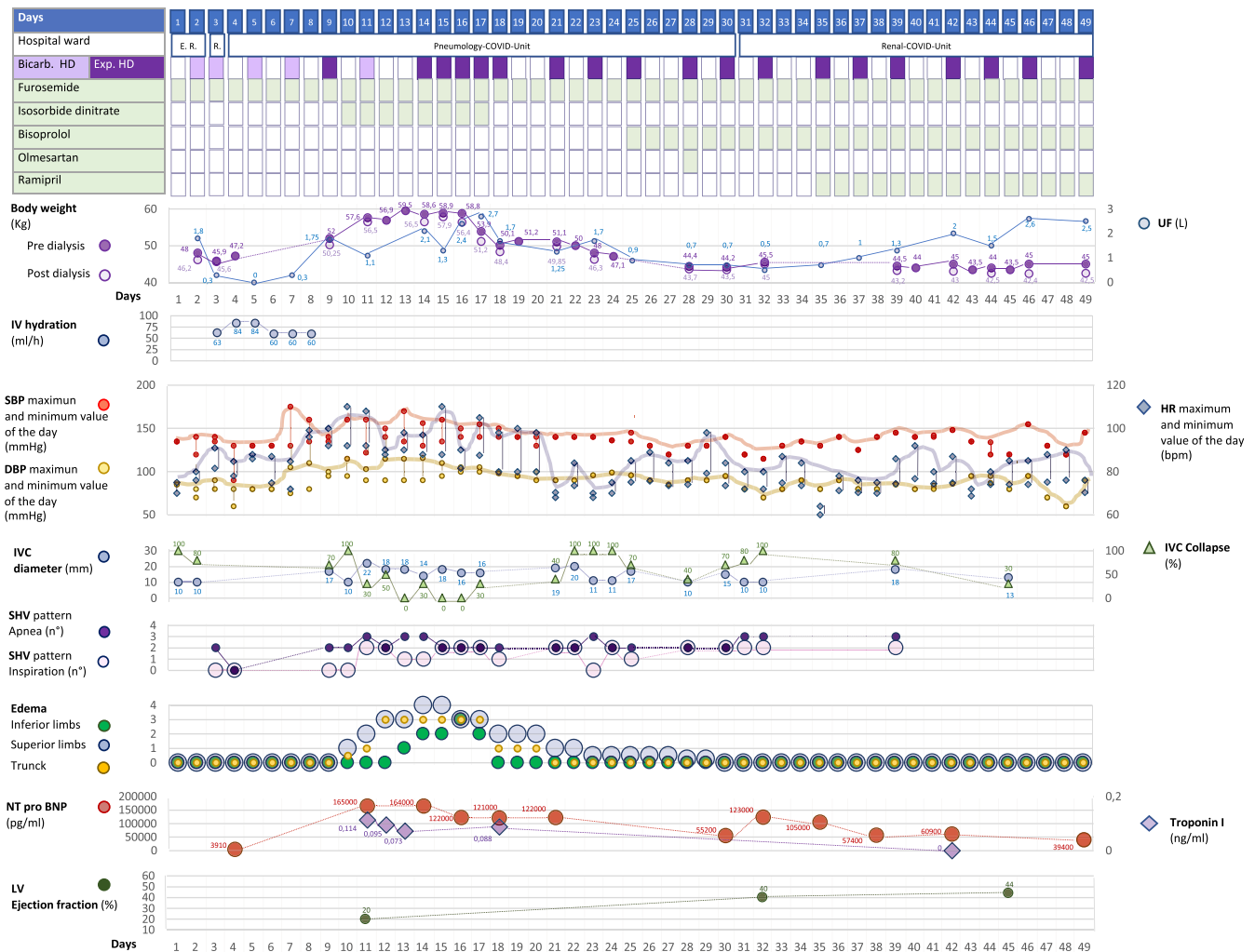
### 2.1 | Admission to emergency room and preliminary care

On 17 March 2020, a 50-year-old Asian man was admitted to emergency room (ER) due to cough and fever (Figure S3). He was receiving thrice weekly HD by native arteriovenous fistula (AVF). Clinical history was suggestive for hypertensive cardiomyopathy and renal failure due to IgA nephropathy, previously treated by deceased donor kidney transplantation, followed by chronic allograft rejection, requiring HD resumption. Chronic medications included prednisolone 2.5 mg on alternate days. No renin-angiotensin-aldosterone inhibitors or other immunosuppressants were prescribed.

Vital signs at admission were not remarkable (Figure 3, Figures S2 and S3). SARS-CoV-2 infection was ascertained



**FIGURE 2** Imaging follow-up by CT scan and thorax X-rays. Bilateral ground-glass areas were present on CT scans at day 1, followed by rapid worsening of multifocal pneumonia and vascular congestion from day 4 to day 14. Partial improvement of both inflammatory infiltrates and fluid congestion was observed on days 21 and 31. Extended follow-up to days 93 and 98 revealed almost complete resolution, excepting apical fibrotic lesions on left lung



**FIGURE 3** Daily representation of HD, cardiologic medications, and noninvasive assessment of hemodynamic and fluid distribution.

Bicarb HD, bicarbonate hemodialysis; DBP, diastolic blood pressure; ER, emergency room; Exp HD, expanded hemodialysis; HR, heart rate; Iv, intravenously; IVC, inferior vena cava; LV, left ventricular; R., Renal-COVID-Unit; SBP, systolic blood pressure; SHV, suprahepatic veins; UF, ultrafiltration

by positive nasopharyngeal swab. Thorax CT scan revealed multiple ground-glass parenchymal thickening, without pleural effusion or wet lungs (Figure 2).

The day after he became febrile, low flow oxygen supplementation was initiated and bicarbonate HD (FX<sup>®</sup> 80 dialyzer [Fresenius]) was delivered by portable osmosis in a dedicated room at ER. On day 3, HD session was performed without ultrafiltration (UF) due to fever and spontaneous BW reduction in the absence of fluid overload at physical examination (Figure 3, Table S1).

## 2.2 | Transfer to Renal-COVID-Unit and respiratory worsening

Patient was transferred to Renal-COVID-Unit. Intravenous (iv) hydration was started based on refractory fever, mild-to moderate cardiac filling pressure at point-of-care US

(inferior vena cava [IVC] diameter 10 mm, inspiratory collapse 100%, SHV class A2-I0) and absence of extravascular overload (Figures 3 and 4; Figure S4). Within next 48 hours, systemic inflammation increased (Figure S3) and respiratory parameters worsened (Figure S2) in association with B lines appearance without significant pleural effusion (Figure S4). Serologic tests for Chlamydia, Mycoplasma, Legionella, and Pneumococcus were negative. Paracetamol and lysine acetylsalicylate were required for resistant fever, keeping steroid doses unchanged. Thorax X-ray showed worsened multifocal pneumonia (Figure 2). Hydroxychloroquine, meropenem, and linezolid were started at renal adjusted dose (Figures S1 and S3), and patient was transferred to pneumology-COVID-Unit, initiating helmet continuous positive airway pressure (CPAP; Figures S1 and S2). Multidisciplinary team (internists, infectious disease specialists, nephrologists, pneumologists, palliative care experts) was involved.



### 2.3 | Transfer to Pneumology-COVID-Unit: early fluid overload, point-of-care ultrasound, CPAP, and tocilizumab initiation

Up to day 8, iv hydration was continued due to recurrent fever (Figure 3; Figure S2). Bicarbonate HD was performed on days 5 and 7 with mild UF in the suspicion of persistent normotensive hypovolemia (Figure 3, Table S1). Bedside US was not performed, and patient was not weighted before HD sessions. Between days 7 and 8 agitation crisis occurred, with tachypnea and oxygen desaturation. Low dose morphine was started subcutaneously (sc; Figure S5). Tocilizumab 400 mg was administered after infectious disease consult. On day 9, patient was relayed on bed scale and point-of-care US examination was performed: 4 Kg BW increase compared with admission time and bilateral pleural effusion were detected, despite the absence of intravascular fluid overload with normal-high venous return (IVC diameter 17 mm, IVC inspiratory collapse 70%, SHV pattern A2-I0; Figures 3 and 4; Figure S4). Expanded HD session (TheraNova® 500 dialyzer [Baxter]) was performed with moderate UF in the suspect of unpredictable hemodynamic instability due cytokine storm (Table S1). Iv hydration was interrupted. D-dimer increased up to 12.366 pg/mL (Figure S6): Ecocolor-doppler excluded deep vein thrombosis and calcium heparin (5.000 IU bid) was initiated due to bedridden patient and emerging rationale for systemic anticoagulation in COVID-19 at that time (Figure S3).

### 2.4 | Anxiety, hypertensive crisis, heart failure, and steroid initiation

Refractory fever and anxious crisis appeared from day 10 (Figure 3; Figures S2 and S5). Anxiolytics were upgraded, by midazolam and inappropriate use of morphine Figure S5). Physical restraint was applied. Remarkable increase in body weight (9.4 Kg) was detected in association with diffuse peripheral edema, pleural effusions, hypervolemia (IVC 22 mm, collapse 30%, SHV A3-I2), and heart failure with low ejection fraction (EF) in the absence of myocardial necrosis (Figures 3 and 4; Figure S4). On day 11, HD was initiated by EvoDial® 2.2 dialyzer (Baxter), due to hypothetic absorption of SARS-CoV-2 virus on heparan sulfate particles. HD was interrupted after 60 minutes due to suspected dialyzer reaction. Symptoms improved after hydrocortisone bolus and HD suspension. HD was restarted by Expanded HD still with mild UF (Table S1). Reduction of positive end expiratory pressure (PEEP) during UF was ineffective in improving respiratory as hemodynamic parameters, rather hampering alveolar recruitment.

On day 11, refractory agitation was treated by escalating morphine and midazolam boluses, followed by continuous infusion of both (Figure S5). Prednisone was upgraded to

methylprednisolone 20 mg iv/daily. Calcium heparin dose was increased to 5.000 IU thrice daily (Figure S3).

### 2.5 | Respiratory depression and severe fluid overload: anxiolytic remodulation, NIMV, and daily hemodialysis

Up to day 14 clinical condition worsened, despite resolution of fever and improved inflammatory markers with exception of IL-6 rebound (Figure S3). Anxiety was treated by morphine and midazolam boluses (12 and 9.5 mg/d, respectively) on top of escalating infusion rates of both (Figure S5). Impaired respiratory drive ensued and generalized fluid overload worsened (IVC 14 mm, collapse 30%, SHV A3-I1) (Figures 3 and 4; Figures S2 and S4). Thorax X-ray revealed worsened multifocal pneumonia, overlapped on wet lungs (Figure 2). Negative fluid balance was planned by daily UF (Figure 3; Table S1), methylprednisolone was increased up to 40 mg iv daily, CPAP helmet was alternated with noninvasive mechanical ventilation (NIMV; Figure S2), and anxiolytics were adjusted (Figure S5). Morphine drip was downgraded and finally suspended. Morphine boluses were avoided in the absence of respiratory distress. Chlorpheniramine and midazolam drip plus low dose haloperidol sc at night were preferred as maintaining anxiolytics. Low dose midazolam boluses were taken as first choice against anxious crisis. Physical restraint was abandoned and not further required.

Daily dialysis was performed on days 14-18. On days 15-16, venous return improved (SHV A2-I2), despite persisting indexes of intravascular overload (IVC diameter 16-18 mm, collapse 0%) and unchanged predialysis BW (Figure 3; Table S1). Almost 9 Kg of BW reduction was achieved on day 18. Systemic improvement of fluid overload was characterized by reduction of both edema and venous congestion (IVC diameter 16 mm, collapse 30%, SHV A2-I1), as by resolution of pleural effusions, despite persisting thorax B lines and elevated NT-proBNP (Figures 3 and 4; Figure S4). Anxiety control and breathing stability were achieved from day 17 (Figures S2 and S5).

### 2.6 | Improvement of pulmonary infiltrates and fluid overload: steroid tapering and hypereosinophilia

On day 21 patient was afebrile, pitting edema and B lines decreased, interdialytic weight gain was almost null, respiratory drive, and P/F normalized (Figures 3 and 4; Figures S2-S5). NIMV was suspended on day 22, proceeding with CPAP helmet for alveolar recruitment. CPAP was thereafter delivered by Venturi mixer, allowing PEEP administration with low FiO<sub>2</sub>, minimizing arterial pO<sub>2</sub> excess. CPAP was alternated to O<sub>2</sub> mask and thereafter to ambient air from day 28.

Thorax X-ray confirmed improvement of multifocal pneumonia (Figure 2). Methylprednisolone was tapered to prednisolone 10 mg q.d. (still ongoing at discharge). UF by Expanded HD was continued thrice weekly, achieving further 5.4 Kg predialytic BW reduction on day 28 (Figure S3). Pitting edema and circulating volume reduced, despite residual B lines (Figure S4) and unstable indexes of venous congestion (IVC diameter 11-17 mm, collapse 100%-70%, SHV class ranging from A3-I0 to A2-I1; Figure 3; Figure S4).

Eosinophil count increased from day 23, following initial eosinopenia and reaching hypereosinophilic plateau on day 30, associated with normal circulating levels of IgE and positive fecal antigen for *Helicobacter Pylori*. Eosinophil count thereafter normalized and diarrhea resolved (Figure S3) with negative results for common causes of diarrhea (Epstein-Barr, Cytomegalovirus, Salmonella, Shigella, Campylobacter, Clostridium Difficile, Mycobacteria, and parasites).

## 2.7 | Step down to Renal-COVID-Unit: weaning CPAP and dry weight reassessment

Patient was transferred to Renal-COVID-Unit on day 31. On day 32, trends of venous return (SHV A3-I2), cardiac filling pressure, and lung congestion inverted, despite stable

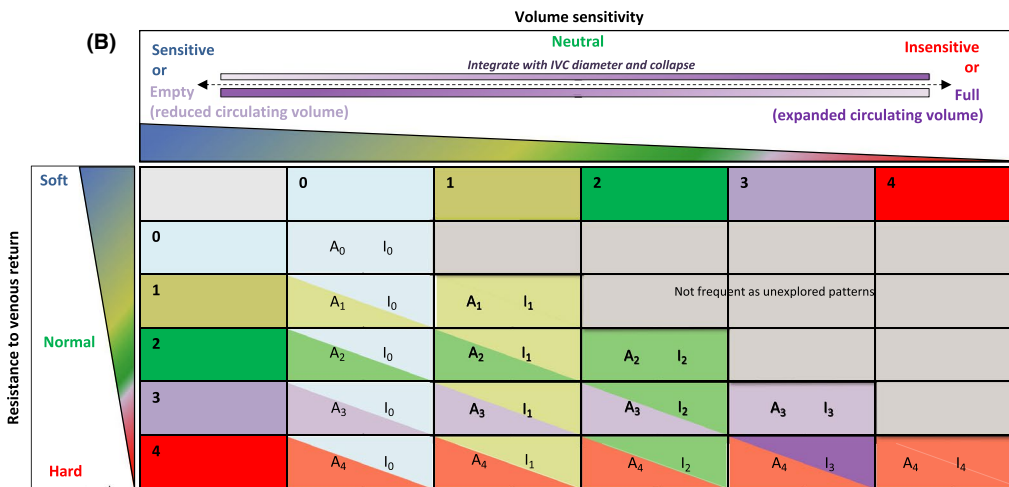
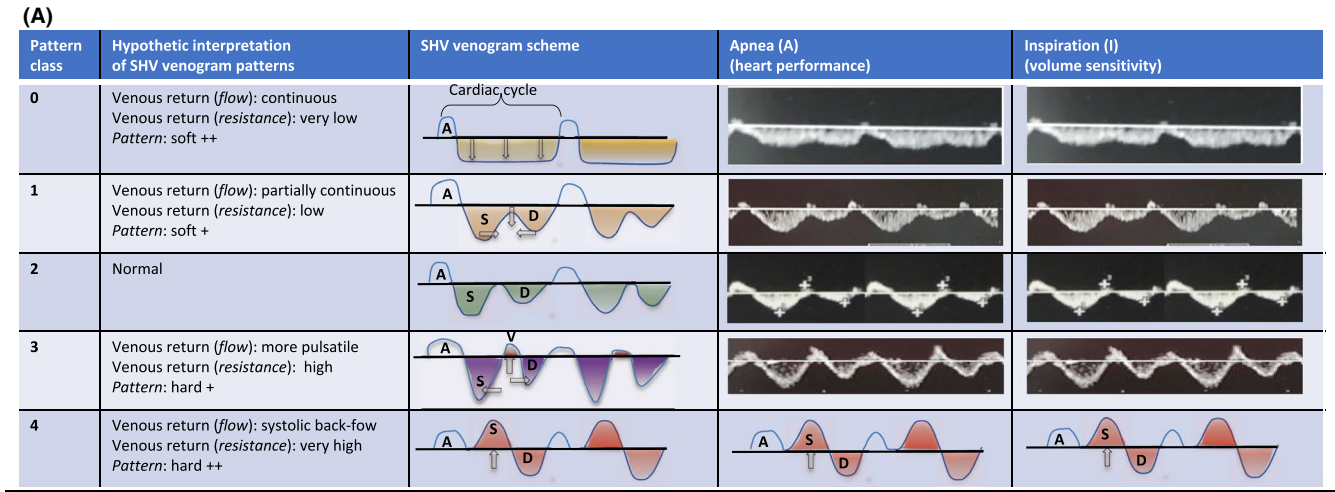
improvement of circulating volumes (IVC 10 mm, collapse 80%-100%) in the absence of heart failure, edema, or pleural effusion (Figure 3; Figure S4). Thorax X-ray performed on day 31 was unchanged (Figure 2).

Bilateral centimetric ulcers were detected at the traction site of the shoulder belts for CPAP helmet, which rapidly healed by local dressing. Cycling CPAP was withdrawn on day 35 due to stable normalization of gas exchange in ambient air. Thorax US was normal on day 38 (Figure S4). Sedation was tapered toward low dose bromazepam as monotherapy, without anxiety recrudescence (Figure S5). Starting from day 37 UF was increased to reduce DW, due to indirect signs of lean mass wasting and slow recovery from acute myocardial pathology, deserving lower circulating volume (SHV A3-I2, IVC 18 mm, collapse 80%; Figure 3). Post-HD 2.5 Kg reduction in BW and moderate improvement of NT-proBNP were achieved at discharge without intra-HD hypotension (Figure 3; Table S1). Cardiac US on day 45 showed improvement of left ventricle EF up to 44% (Figure 3).

## 2.8 | Discharge and follow-up

Patient was discharged at home on day 49 after double negative nasopharyngeal swabs for SARS-CoV-2 on days 47 and 48.

**FIGURE 4** Hypothetical dynamic classification of suprahepatic veins venogram. A, Normal SHV pattern during a complete cardiac cycle is characterized by positive A wave (right atrial systole), negative S wave (right ventricular systole), and negative D wave (right ventricular diastole).<sup>9</sup> Small positive wave between S and D (positive V wave) may occasionally be observed. Based on the authors' unpublished data, hypothetically normal SHV pattern is herein classified as a middle range class (class 2) out of 4 classes (0-4) (fig a). Classes 0-1 are attributed to increased venous return. Classes 3-4 are attributed to reduced venous return. Descriptively: class 0 is characterized by fusion of S and D waves, class 1 by initial fusion of S and D waves and initial increase in deceleration time of both. On the opposite: class 3 is characterized by reduced deceleration time of S and D waves, appearing with diamond shape, occasionally associated with Z wave appearance, class 4 is characterized by S wave inversion as previously associated to pulmonary hypertension.<sup>9</sup> Flow patterns of venous return are herein taken as makers of resistance to venous return, hypothetically proportional to real-time cardiac filling pressures, influenced by both primary cardiac performance as by circulating volume. Thus, classes 0-1 are taken as markers of progressively increased venous return, reduced resistance to venous return and reduced cardiac filling pressure (*soft* patterns). On the opposite, classes 3-4 are taken as markers of progressively reduced venous return, increased resistance to venous return, and increased cardiac filling pressure (*hard* patterns). Based on the authors' unpublished data, SHV patterns are sensible to inspiration as described for the inferior vena cava (IVC) ultrasonographic interpretation. B, SHV patterns are subcategorized into morphologic patterns assessed during apnea (category A, classes 0-4) and inspiration (category I, classes 0-4) leading to 15 combined classes. Hypothetically, patterns during apnea are herein purposed as mainly representative of resistance to venous return, primarily influenced by cardiac performance per se, while patterns assessed during inspiration as more influenced by reduction of venous pressure, secondary to inspiratory weakened mediastinic pressure (volume sensitivity). Thus, class A2-I2 will correspond to the normal comprehensive class, class A0-I0 to lowest venous return, lowest resistance, lowest filling pressure, highest volume sensitivity or hypovolemia (*soft, volume sensitive or hypovolemic pattern*), class A4-I4 as corresponding to lowest venous return, highest resistance, highest filling pressure, lowest volume sensitivity or hypervolemia (*hard, volume insensitive, or hypervolemic pattern*). Patterns of IVC will be additive for interpreting SHV pattern. For instance, class A3-I3 in the presence of enlarged and noncollapsing IVC may correspond to high resistance to venous return and high cardiac filling pressure, associated with volume expansion and thus subjective to possible improvement after reduction of circulating volume, to be tested by UF or diuretic challenge (*hard, full, potentially volume-sensitive pattern*). The same class, in the presence of normal or highly collapsing IVC, may represent high resistance to venous return and high cardiac filling pressure despite normal-low circulating volumes, thus less improvable by circulating volume reduction and marker of impaired cardiac performance (*hard, empty, volume insensitive pattern*). Transition between classes may be taken as a continuum, responsive to real-time variations of circulating volume and cardiorenal performance. Of note, hepatic stiffness (as in cirrhosis) can induce pattern A0-I0 independently from circulating volume and cardiac performance.<sup>39</sup> Original iconographic reports of US were herein not available due to contact isolation precautions observed during COVID-19 emergency. The aforementioned classification and interpretation of SHV venogram must be taken as hypothesis generating and still prone to verification by extended trials



At 93- and 98-day follow-ups, despite normal gas exchange at rest and normalized thorax X-ray, patient remained persisting dyspnea at moderate physical activity, associated with positive 6 minutes walking test, residual apical ground glass at CT scan (Figure 2) and unchanged EF.

### 3 | DISCUSSION AND CONCLUSIONS

Although mortality risk in COVID-19 MHD patients is higher than in general population, MHD should not represent an independent contraindication for admission to subintensive wards. The high rate of ARDS and heart failure, described in COVID-19, requires hospital wards predisposed for noninvasive ventilation also for MHD patients. Eventual preconditioned impaired access to subintensive care for MHD patients during early as unpredictable phase of pandemic emergency should represent a matter of allocating healthcare resources, poorly sustained by clinical and ethical principles up to date. Due to peculiarities of end-stage renal disease (ESRD) concerning prognostic evaluation and fluids

management, nephrologist may be included in the acute care team of critically ill COVID-19 dialysis patients admitted to subintensive units.

Intensive dialysis may be required in ESRD as well as in acute kidney injury patients affected by severe COVID-19, due to cytokine storm and rapid precipitation of fluid overload observed in SARS-CoV-2 infection. Although CRRT represents the mainstay in such conditions,<sup>6</sup> it was unavailable outside of ICU at our Institution. Thus, dedicated rooms, for delivering intermittent HD (IHD) by portable osmosis, were predisposed at San Paolo Hospital (Milan, Italy) shortly after initiation of SARS-CoV-2 outbreak in Lombardy. Expanded HD could be considered as the modality of choice for IHD in COVID-19-infected patients due to its ascertained anti-inflammatory properties.<sup>5,22</sup> Daily IHD herein was life-saving during acute phase of SARS-CoV-2 infection.

Abrupt precipitation of respiratory and cardiac function in COVID-19 alters fluid redistribution just as quickly. Fluid overload in anuric patients represents a common drawback of resuscitating therapies in the absence of UF. Bed scale resulted indispensable for daily assessment of mass balance in subintensive setting, being more accurate than mathematical

computation of fluid balance. Real-time assessment of fluid status by point-of-care US was adjuvant for guiding fluid and ventilatory management. Notably, ultrasound data guided negative fluid balance during last 20 days, in the absence of otherwise objective fluid excess. Dynamic variation in SHV venogram was reported and interpreted based on literature<sup>23-25</sup> and authors' unpublished data. Classification of SHV venogram patterns in 15 combined classes (apnea [A: 0-4] combined with inspiration [I: 0-4]) is herein purposed (Figure S4). SHV pattern may appear influenced by both circulating volume, indirectly estimable by IVC diameter and collapse, and cardiac performance.

In April 2020, when the patient's clinical trend was improving, the venous excess ultrasound score (VEXUS) was purposed for assessing venous congestion in cardiorenal syndrome, including US examination of IVC diameter and waveforms of hepatic, portal and renal veins, in patients admitted to ICU after cardiac surgery, excluding patients with critical illness, eGFR < 15 mL/min, or renal transplantation.<sup>26</sup> VEXUS score was associated with the risk of acute kidney injury, and subsequently adopted by Bhardwaj et al,<sup>27</sup> for tailoring fluid removal by diuretics and ultrafiltration in patients with cardiorenal syndrome associated with acute kidney injury stage 1 to 3. On May 2020 Tri-POCUS approach, including bedside assessment of lungs, heart, and venous system, was suggested for critically ill patients with COVID-19.<sup>28</sup>

Although assessment of hepatic, portal, and renal veins waveforms can be more complete, the present case is hypothesis generating on how easier approach, limited to hepatic veins and IVC, could be suitable outside from ICU. Furthermore, the case first describes assessment of venous congestion in a COVID-19 MHD patient, where renal veins waveform could be less informative for cardiorenal trend. A new pattern of hepatic vein venogram (fusion of S and D waves, scored as stage 0) is herein suggested, which may associate with extreme reduction of venous congestion, potentially informative against excessive fluid removal. Finally, variation of hepatic vein venogram in apnea and inspiration is herein purposed for the first time; this may be adjuvant in interpreting sensibility of venous congestion to circulating volumes independently from IVC parameters. However, the herein reported interpretation of SHV venogram remains hypothetical, deserving further studies to be verified.

Positive end expiratory pressure was reported as crucial for treating COVID-19 ARDS. The present case confirms efficacy of PEEP delivered by CPAP helmet. Transitory reduction of PEEP during UF in the acute phase was associated with oxygenation worsening without benefits on anxiety or hemodynamic parameters. Slow weaning from PEEP, also beyond normalization of P/F, was considered reasonable, due to high risk of wet lung recrudescence in HD patient with residual myocardial impairment and pulmonary inflammation. Venturi mixer for helmet CPAP (Harol®) resulted adjuvant

for delivering PEEP during recovery phase, with low FiO<sub>2</sub> (down to 35%), in order to avoid patient's hyperoxygenation. Prolonged use of noninvasive ventilation requires precaution against cutaneous lesions induced by helmet, belts, or mask. Counterweight system may be considered, for limiting traction on axillary areas induced by helmet straps.<sup>29</sup>

Acute cardiovascular syndrome was described in COVID-19 and attributed to acute coronary syndrome, demand ischemia, microvascular ischemic injury, myocarditis, or cytokine storm.<sup>10</sup> Severe transitory myocardial insufficiency without myocardial necrosis was herein taken as consequent to cytokine storm and fluid overload, superimposed on chronic hypertensive-ESRD cardiomyopathy. Assessment of EF, NT-proBNP, and troponin-I at admission could be reasonable to monitor COVID-19 HD patients, commonly affected by chronic cardiovascular disease and elevated basal levels of both markers.

COVID-19 has been associated with hypercoagulability and itself worsens the prognosis.<sup>30</sup> Although prophylactic anticoagulation is now advised,<sup>30</sup> heparin was started on day 9 due to uncertain knowledge about anticoagulation in COVID-19 at admission.

Anti-inflammatory drugs were reported for treating COVID-19 dialysis patients.<sup>5,31</sup> Tocilizumab, in association with moderate steroids doses, was herein well tolerated and followed by resolution of fever and improvement of inflammatory markers within 4 days, with exception of IL-6 rebound as previously observed.<sup>26</sup> Although hypertensive crises were attributed to adrenergic activation triggered by COVID-19, hypertension induced by tocilizumab has been reported.<sup>11</sup> Hydroxychloroquine was herein adopted prior to international warning against its use in COVID-19. Notably hydroxychloroquine is now contraindicated in COVID-19-infected patients due to uncertain efficacy and increased arrhythmic risk.<sup>32</sup> Antivirals were herein not prescribed. Although Remdesivir is now approved for treating COVID-19,<sup>33</sup> it remains contraindicated in dialysis patients.

Agitation represented a relevant matter. Notably, morphine is not indicated in dialysis patients due to risk of life threatening accumulation. Furthermore, it is indicated for treating pain, respiratory distress, or palliative sedation, but not for treating anxiety. Distinguishing respiratory distress from anxiety and terminal phase is crucial in COVID-19-infected patients, where anxiety and delirium could be better treated by benzodiazepine and antihistamines or neuroleptics, respectively, rather than with morphine (Figure 1; Figures S5 and S7). Agitation sedation should be monitored by Richmond Agitation Sedation Scale (RASS).<sup>34</sup> Other opioids, as buprenorphine or fentanyl, could be cautiously preferred when indicated.

Persistent eosinopenia was observed until day 24, being thereafter followed by eosinophilia associated with diarrhea and rash, uncertainly attributed to allergic reaction to



Olmесartan. Eosinopenia was described in acute phase of COVID-19.<sup>35,36</sup> Further eosinophils increase was suggested as marker of disease improvement,<sup>36</sup> based on unknown mechanisms.<sup>37,38</sup> Significance of eosinophil trend in COVID-19 requires further investigation.

Renal associations have mostly provided recommendations for preventing COVID-19 outbreak within dialysis facilities, but data are still poor for recommending specific drugs for the care of severe COVID-19 in MHD patients at the moment. Although clinical messages derived by this case remain opinion-based and hypothesis generating, in the current scenario meticulous application of available anti-inflammatory drugs, ventilation and dialysis techniques, close to accurate daily evaluation of fluid balance and neurological status, may be crucial for treating severe COVID-19 in MHD patients.

In conclusion, the case supports efficacy of individualized subintensive care, delivered by multidisciplinary team, and the need to allocate health resources for achieving similar goals in the treatment of critically ill COVID-19 MHD patients during second pandemic wave.

## ACKNOWLEDGMENTS

None. Consent statement: Published with written consent of the patient.

## CONFLICT OF INTEREST

None declared.

## AUTHOR CONTRIBUTION

AG: had major role in data collection, writing, and editing the manuscript. All authors: involved in the patient care. All authors: read and approved the final manuscript.

## ETHICAL APPROVAL AND CONSENT TO PARTICIPATE

No ethical issue in reporting of this case.

## DATA AVAILABILITY STATEMENT

Data sharing is not applicable to this article as no datasets were generated or analyzed during the current study. Para clinic data which are referred to in the case presentation are available on request from the corresponding author.

## ORCID

Andrea Galassi  <https://orcid.org/0000-0001-7533-2876>

Stefano Carugo  <https://orcid.org/0000-0002-5166-0899>

Mario Cozzolino  <https://orcid.org/0000-0002-8494-6252>

## REFERENCES

- Xiong F, Tang H, Liu L, et al. Clinical characteristics of and medical interventions for COVID-19 in hemodialysis patients in Wuhan, China. *J Am Soc Nephrol*. 2020;32(7):1387-1397.
- Alberici F, Delbarba E, Manenti C, et al. A report from the Brescia renal COVID task force on the clinical characteristics and short-term outcome of hemodialysis patients with SARS-CoV-2 infection. *Kidney Int*. 2020;98(1):20-26.
- Goicoechea M, Camara LAS, Macias N, et al. COVID-19: clinical course and outcomes of 36 hemodialysis patients in Spain. *Kidney Int*. 2020;98(1):27-34.
- Basile C, Combe C, Pizzarelli F, et al. Recommendation for the prevention, mitigation, and containment of the emerging SARS-CoV-2 (COVID-19) pandemic in hemodialysis centers. *Nephrol Dial Transplant*. 2020;35(5):737-741.
- Alberici F, Delbarba E, Manenti C, et al. Management of patients on dialysis and with kidney transplantation during the SARS-CoV-2 (COVID-19) pandemic in Brescia, Italy. *Kidney Int Rep*. 2020;5(5):580-585.
- Ronco C, Reis T, Husain-Syed F. Management of acute kidney injury in patients with COVID-19. *Lancet Respir Med*. 2020;8(7):738-742.
- Kazory A, Ronco C, McCullough PA. SARS-CoV-2 (COVID-19) and intravascular volume management strategies in the critically ill. *Proc (Bayl Univ Med Cent)*. 2020;33(3):370-375. <https://doi.org/10.1080/08998280.2020.1754700>
- Sofia S, Bocatonda A, Montanari M, et al. Thoracic ultrasound and SARS-COVID-19: a pictorial essay. *J Ultrasound*. 2020;2:217-221.
- Vieira ALS, Pazeli Junior JM, Bastos MG. Role of point-of-care ultrasound during the COVID-19 pandemic: our recommendations in the management of dialytic patients. *Ultrasound J*. 2020;12(1):30. <https://doi.org/10.1186/s13089-020-00177-4>
- Hendren N, Drazner MH, Bozkur B, et al. Description and proposal management of the acute COVID-19 cardiovascular syndrome. *Circulation*. 2020;141(23):1903-1914.
- Long B, Brady W, Koefman A, et al. Cardiovascular complication in COVID-19. *Am J Emerg Med*. 2020;38(7):1504-1507.
- Guzik T, Mohiddin AA, Dimarco A, et al. COVID-19 and the cardiovascular system: implications for risk assessment, diagnosis and treatment options. *Cardiovasc Res*. 2020;116(10):1666-1687. <https://doi.org/10.1093/cvr/cvaa106>
- Helms J, Kremer S, Merdji H, et al. Neurologic features in severe SARS-CoV-2 infection. *N Engl J Med*. 2020;382:2268-2270.
- Kotfis K, Roberson SW, Wilson JE, et al. COVID-19: ICU delirium management during SARS-CoV-2 pandemic. *Crit Care*. 2020;24(1):176. <https://doi.org/10.1186/s13054-020-02882-x>
- Mao L, Wang JH, Chen S, et al. Neurologic manifestations of hospitalized patients with coronavirus disease 2019 in Wuhan, China. *JAMA Neurol*. 2020;77(6):1-9.
- Singhania N, Bansal S, Singhania G. An atypical presentation of novel coronavirus disease 2019 (COVID-19). *Am J Med*. 2020;133(7):e365-e366.
- Ke C, Wang Y, Zeng X, et al. 2019 novel coronavirus disease (COVID-19) in hemodialysis patients: a report of two cases. *Clin Biochem*. 2020;81:9-12.
- Wang R, Liao C, He H, et al. COVID-19 in hemodialysis patients: a report of 5 cases. *Am J Kidney Dis*. 2020;77(1):141-143.
- Fu D, Yang B, Xu J, et al. COVID-19 infection in a patient with end-stage kidney disease. *Nephron*. 2020;44:245-247.
- Ferrey A, Choi G, Hanna RH, et al. A case of novel coronavirus disease 19 in a chronic hemodialysis patient presenting with gastroenteritis and developing severe pulmonary disease. *Am J Nephrol*. 2020;52:337-342.

21. Delafosse M, Saint-Jaques C, Petit-Hoang C, et al. Steroids: a therapeutic option for COVID-19 pneumonia patients with end stage renal disease? *Kidney Int Rep.* 2020;5(8):1375. <https://doi.org/10.1016/j.ekir.2020.05.031>
22. Cozzolino M, Magagnoli L, Ciceri P, et al. Effects of medium cut-off (Theranova) dialyser on hemodialysis patients: a prospective cross-over study. *Clin Kidney J.* 2019. <https://doi.org/10.1093/ckj/sfz155>
23. Meola M, Nalesso F, Petrucci I, et al. Clinical scenarios in acute kidney injury: hepatorenal syndrome. *Contrib Nephrol.* 2016;188:33-38.
24. Beigel R, Cercek B, Luo H, et al. Non invasive evaluation of atrial pressure. *J Am Soc Echocardiogr.* 2013;26:1033-1042.
25. Iida N, Seo Y, Sai S, et al. Clinical implication of intrarenal hemodynamic evaluation by doppler ultrasonography in heart failure. *JACC Heart Fail.* 2016;4:674-678.
26. Beaubien-Souligny W, Rola P, Haycock K, et al. Quantifying systemic congestion with point-of-care ultrasound: development of the venous excess ultrasound grading system. *Ultrasound J.* 2020;12(1):16. <https://doi.org/10.1186/s13089-020-00163-w>
27. Bhardwaj V, Vikneswaran G, Rola P, et al. Combination of inferior vena cava diameter, hepatic venous flow, and portal vein pulsatility index: venous excess ultrasound score (VEXUS score) in predicting acute kidney injury in patients with cardiorenal syndrome: a prospective cohort study. *Indian J Crit Care Med.* 2020;24(9):783-789.
28. Koratala A, Ronco C, Kazory A. Need for objective assessment of volume status in critically ill patients with COVID-19: the Tri-POCUS approach. *Cardiorenal Med.* 2020;10(4):209-216.
29. Lucchini A, Giani M, Isgrò D, et al. The “helmet bundle” in COVID-19 patients undergoing non invasive ventilation. *Intensive Crit Care Nurse.* 2020;58:102859. <https://doi.org/10.1016/j.iccn.2020.102859>
30. Singhanian N, Bansal S, Nimmatoori DP, et al. Current overview on hypercoagulability in COVID-19. *Am J Cardiovasc Drugs.* 2020;20(5):393-403.
31. Bose S, Adapa S, Aeddula NR, et al. Medical management of COVID-19: evidence and experience. *J Clin Med Res.* 2020;12(6):329-343.
32. U.S. Food and Drug Administration. July 2020. <https://www.fda.gov/drugs/drug-safety-and-availability/fda-cautions-against-use-hydroxychloroquine-or-chloroquine-covid-19-outside-hospital-setting-or>. Accessed 14 November 2020.
33. U.S. Food and Drug Administration. October 2020. <https://www.fda.gov/news-events/press-announcements/fda-approves-first-treatment-covid-19>. Accessed 14 November 2020
34. Toniati P, Piva S, Cattalini M, et al. Tocilizumab for the treatment of severe COVID-19 pneumonia with hyperinflammatory syndrome and acute respiratory failure: a single center study of 100 patients in Brescia, Italy. *Autoimmun Rev.* 2020;19(7):102568. <https://doi.org/10.1016/j.autrev.2020.102568>
35. Zhang JJ, Dong X, Cao YY, et al. Clinical characteristics of 140 patients infected with SARS-CoV-2 in Wuhan, China. *Allergy.* 2020;75(7):1730-1741.
36. Liu F, Xu A, Zhang Y, et al. Patients of COVID-19 may benefit from sustained Lopinavir-combined regimen and the increase eosinophil may predict the outcome of COVID-19 progression. *Int J Infect Dis.* 2020;95:183-191.
37. Jesenak M, Banovcin P, Diamant Z. COVID-19, chronic inflammation respiratory disease and eosinophils – observations from reported clinical series. *Allergy.* 2020;75(7):1819-1822.
38. Lindsley A, Schwartz JT, Rothenberg MC. Eosinophil response during COVID-19 infections and coronavirus vaccination. *J Allergy Clin Immunol.* 2020;146:1-7.
39. Meola M. Analisi della curva spettrale delle vene sovraepatiche. *Ecografia clinica in Nefrologia.* Eureka Editore. 2015:470-477.

## SUPPORTING INFORMATION

Additional supporting information may be found online in the Supporting Information section.

**How to cite this article:** Galassi A, Casanova F, Gazzola L, et al. SARS-CoV-2–related ARDS in a maintenance hemodialysis patient: case report on tailored approach by daily hemodialysis, noninvasive ventilation, tocilizumab, anxiolytics, and point-of-care ultrasound. *Clin Case Rep.* 2021;9:694–703. <https://doi.org/10.1002/ccr3.3623>