

Case Report

# A Rare Case of Mixed Infectious Keratitis Caused by *Pseudomonas koreensis* and *Aspergillus fumigatus*

Lin Wei Khoo<sup>a, b</sup> Sathish S. Srinivasan<sup>a, b</sup> Fiona L. Henriquez<sup>b</sup>  
Abhijit M. Bal<sup>c</sup>

<sup>a</sup>Department of Ophthalmology, University Hospital Ayr, Ayr, UK; <sup>b</sup>School of Health and Life Sciences, University of West of Scotland, Paisley, UK; <sup>c</sup>Department of Medical Microbiology, University Hospital Crosshouse, Crosshouse, UK

## Keywords

Mixed infectious keratitis · Infectious keratitis · Gram-negative bacteria · Bacteria · Fungus

## Abstract

We report the clinical and microbiological features of contact lens-related mixed infectious keratitis caused by a spore-forming filamentous fungus and a rare gram-negative bacterial infection. A 66-year-old Caucasian female presented with right eye (OD) pain after sleeping in her 2-weekly contact lenses for 3 days. On presentation, corrected distance visual acuity was 0.46 LogMAR OD and 0.20 in the left eye. Slit lamp biomicroscopy revealed a 1.9 mm by 1.9 mm area of dense stromal infiltrate with epithelial defect. Corneal scrapes grew *Aspergillus fumigatus* and *Pseudomonas koreensis*, and culture-directed microbial therapy with oral and topical voriconazole and topical fortified gentamicin along with regular debridement resulted in slow resolution of the infection, leaving a dense stromal scar in the visual axis requiring penetrating keratoplasty. Mixed infectious keratitis caused by filamentous fungi and gram-negative bacteria is rare. *Pseudomonas koreensis* infection has not been previously reported as a cause of infectious keratitis in humans. In our experience, these mixed infections require prolonged systemic and topical therapy and the secondary scarring may require surgical intervention for vision rehabilitation.

© 2020 The Author(s)  
Published by S. Karger AG, Basel

## Introduction

Infectious keratitis is an ophthalmic emergency that often results in ocular morbidity and visual disability [1–3]. The most common aetiology is bacterial; virus, fungi, and *Acanthamoeba* are less common pathogens [1–4]. Infectious keratitis attributed to multiple microorganisms is relatively uncommon. This could occur as a coinfection or as a secondary infection superimposed on a pre-existent infectious pathology [5]. We report a case of an infectious keratitis caused by *Pseudomonas koreensis*, a gram-negative rod, and *Aspergillus fumigatus*, a sporulating filamentous fungus.

## Case Report

A 66-year-old Caucasian female and a known contact lens wearer presented with a 3-day history of right eye (OD) redness and pain. She had no past ocular or medical history. Corrected distance visual acuities (CDVA) were 0.46 LogMAR in the OD and 0.20 LogMAR in the left eye. Examination revealed a 1.9 × 1.9 mm epithelial defect with a stromal infiltrate in the inferior cornea in the OD (shown in Fig. 1a, b). Posterior segment examination of both eyes was unremarkable.

Corneal scrape was obtained, and she was commenced on topical fortified 5% cefuroxime and 1.5% gentamicin. Corneal scrape on this occasion showed no growth. Mild clinical improvement was noted and the CDVA improved to 0.34 LogMAR OD. Dexamethasone 0.1% drops were commenced b.i.d. to treat the secondary ocular surface inflammation. Two days later she presented with severe pain in OD. Biomicroscopy revealed a 2 mm by 2 mm raised central plaque (shown in Fig. 1c). Following discontinuation of topical antibiotics for 48 h, the plaque was debrided and sent to the microbiology. Dexamethasone drops were discontinued. At week 3, CDVA of OD deteriorated to hand movements and cultures grew *Pseudomonas koreensis* and *Aspergillus fumigatus* on blood and Sabouraud's agar, respectively. *P. koreensis* was susceptible to ceftazidime, ciprofloxacin, and gentamicin. Biomicroscopy revealed a generally hazy cornea with central stromal infiltrate and hypopyon (shown in Fig. 1d). With the identification of causative microorganisms, the treatment was changed to oral voriconazole 200 mg b.i.d. along with hourly 1.5% topical gentamicin and 5% cefuroxime and topical voriconazole 1.0% hourly.

At week 7, improvement was noted in the form of reduced hypopyon (shown in Fig. 2a). Over the next 2 months, debridement of the plaque was performed during her weekly reviews and topical voriconazole was tapered. At week 18, oral voriconazole was discontinued and at week 22, all topical medications were discontinued. Twelve months after her initial presentation, her CDVA was 0.80 LogMAR due to a dense central corneal scar (shown in Fig. 2c). She eventually underwent a penetrating keratoplasty (shown in Fig. 2d) and her CDVA improved to 0.40 LogMAR.

## Discussion

Mixed infectious keratitis caused by bacteria and fungi are rare and are usually associated with poor prognosis [5]. *Pseudomonas koreensis* is a non-spore forming gram-negative rod, first isolated from the rice rhizosphere in Heilongjiang province in Korea [6]. A literature review revealed no previous cases of *P. koreensis* infectious keratitis in humans. However, it may

have a predilection for ocular tissues as it has been reported in association with eye lesions in fish [7]. This species has been reported to produce the biosurfactant, which has biocontrol ability against *Phytophthora infestans* and *Pythium ultimum* [8, 9]. It is unclear whether this biocontrol ability had any role in the late diagnosis of the co-existing fungal keratitis in our patient. Recently genome sequencing of *Pseudomonas koreensis* CRS05-R55 was performed [10], which demonstrated one gene cluster encoding fimbrial associated proteins only existing in CRS05-R5 (A8L59\_09240–A8L59\_09310). These genes have been reported to be critical for the initial stage of biofilm development [11]. This biofilm development may have contributed to the prolonged infection.

Our patient had no history of travel to the Korean peninsula but reports frequent contact with soil as she lives and works in a farm that raises cattle and grows vegetables, which may have increased her risk of acquiring this mixed gram-negative bacterial and filamentous fungal infection, which has also has predilection for vegetable matter [12]. South Korea is not a major exporter of farm products, so we are unable to establish any direct link to intercontinental spread of infection. We believe that the environmental niches of this species have not been fully characterized. It has been isolated from soil in Northern France [13] and related species such as *P. baetica* have been isolated from other parts of Europe, notably Spain [14]. There was a 3-week delay in identification of the causative organism in our case and it required multiple corneal scrapes for microbiological investigation. It is unclear whether the biofilm and bio surfactant formation ability of *P. koreensis* may have led to the delay in culturing this microbe [8, 9, 11]. In addition, the indolent slow nature of the fungal keratitis may also have contributed to the delay in diagnosis.

Both topical and oral voriconazole has been shown to be effective in treating *Aspergillus fumigatus* keratitis [15]. Natamycin has also been widely used in the treatment of fungal keratitis. A comparison of natamycin with voriconazole demonstrated a trend favouring the latter [16]. To conclude, mixed infectious keratitis may be difficult to diagnose and treat due to the potential bio-interactions between the infective organisms. Once diagnosed, prolonged topical and systemic therapy may be required.

## Statement of Ethics

We can confirm that the subject (patient discussed in this case report) has given her written informed consent to publish her case (including publication of images).

## Conflict of Interest Statement

The authors have no conflicts of interest to declare.

## Funding Sources

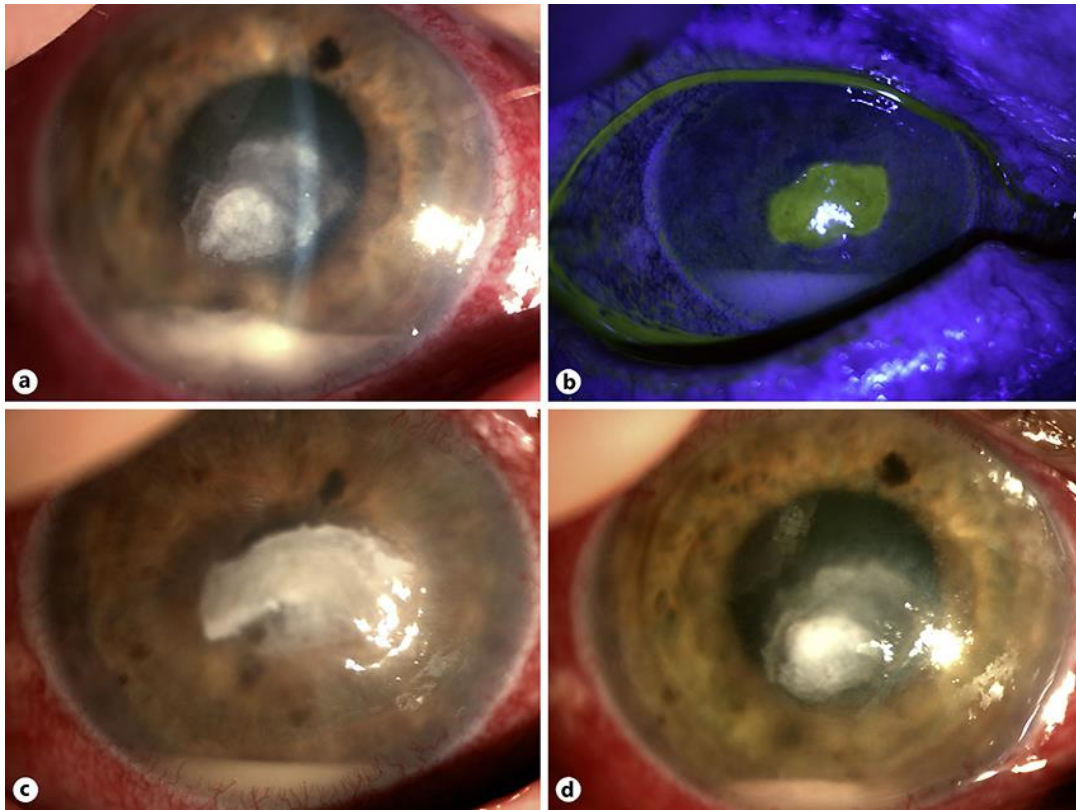
No funding was obtained with regards to this case report. The authors have no funding sources to declare.

## Author Contributions

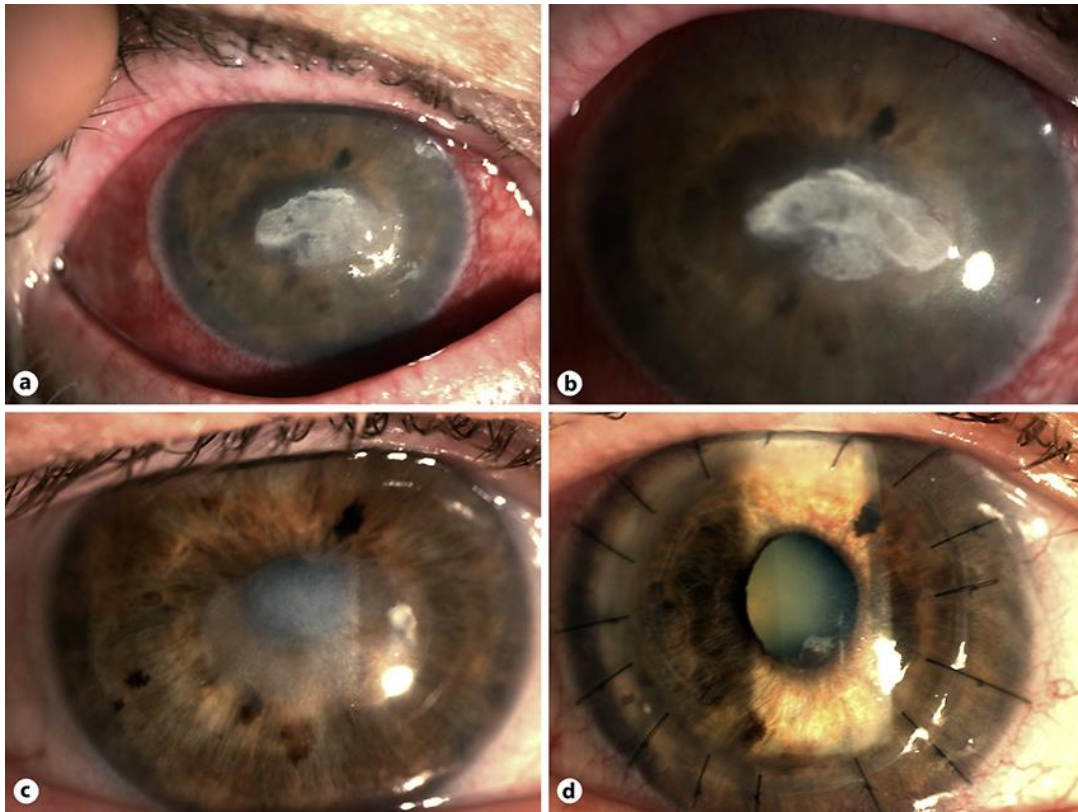
Drs. Khoo and Srinivasan were involved in the clinical management of this patient, design of the case report, writing of the manuscript, and in obtaining clinical pictures. Drs. Henriquez and Bal provided the microbiology expertise in managing this case and also provided input in writing and reviewing the manuscript. All authors confirm that they approve the final version of the manuscript.

## References

- Hernandez-Camarena JC, Graue-Hernandez EO, Ortiz-Casas M, Ramirez-Miranda A, Navas A, Pedro-Aguilar L, et al. Trends in Microbiological and Antibiotic Sensitivity Patterns in Infectious Keratitis: 10-Year Experience in Mexico City. *Cornea*. 2015 Jul;34(7):778–85.
- Lin TY, Yeh LK, Ma DH, Chen PY, Lin HC, Sun CC, et al. Risk Factors and Microbiological Features of Patients Hospitalized for Microbial Keratitis: A 10-Year Study in a Referral Center in Taiwan. *Medicine (Baltimore)*. 2015 Oct;94(43):e1905.
- Austin A, Lietman T, Rose-Nussbaumer J. Update on the Management of Infectious Keratitis. *Ophthalmology*. 2017 Nov;124(11):1678–89.
- Lichtinger A, Yeung SN, Kim P, Amiran MD, Iovieno A, Elbaz U, et al. Shifting trends in bacterial keratitis in Toronto: an 11-year review. *Ophthalmology*. 2012 Sep;119(9):1785–90.
- Ahn M, Yoon KC, Ryu SK, Cho NC, You IC. Clinical aspects and prognosis of mixed microbial (bacterial and fungal) keratitis. *Cornea*. 2011 Apr;30(4):409–13.
- Kwon SW, Kim JS, Park IC, Yoon SH, Park DH, Lim CK, et al. *Pseudomonas koreensis* sp. nov., *Pseudomonas umsongensis* sp. nov. and *Pseudomonas jinjuensis* sp. nov., novel species from farm soils in Korea. *Int J Syst Evol Microbiol*. 2003 Jan;53(Pt 1):21–7.
- Shahi N, Mallik SK. Recovery of *Pseudomonas koreensis* from eye lesions in golden mahseer, *Tor putitora* (Hamilton, 1822) in Uttarakhand, India. *J Fish Dis*. 2014 May;37(5):497–500.
- Hultberg M, Bengtsson T, Liljeroth E. Late blight on potato is suppressed by the biosurfactant-producing strain *Pseudomonas koreensis* 2.74 and its biosurfactant. *BioControl*. 2010;55(4):543–50.
- de Boer W, Wagenaar AM, Klein Gunnewiek PJ, van Veen JA. In vitro suppression of fungi caused by combinations of apparently non-antagonistic soil bacteria. *FEMS Microbiol Ecol*. 2007 Jan;59(1):177–85.
- Lin H, Hu S, Liu R, Chen P, Ge C, Zhu B, et al. Genome sequence of *Pseudomonas koreensis* CRS05-R5, an antagonistic bacterium isolated from rice paddy field. *Front Microbiol*. 2016 Nov;7:1756.
- Wei Q, Ma LZ. Biofilm matrix and its regulation in *Pseudomonas aeruginosa*. *Int J Mol Sci*. 2013 Oct;14(10):20983–1005.
- Garg P, Gopinathan U, Choudhary K, Rao GN. Keratomycosis: clinical and microbiologic experience with dematiaceous fungi. *Ophthalmology*. 2000 Mar;107(3):574–80.
- Camiade M, Bodilis J, Chaftar N, Riah-Anglet W, Gardères J, Buquet S, et al. Antibiotic resistance patterns of *Pseudomonas* spp. isolated from faecal wastes in the environment and contaminated surface water. *FEMS Microbiol Ecol*. 2020 Feb 1;96(2):fiae008.
- Beaton A, Lood C, Cunningham-Oakes E, MacFadyen A, Mullins AJ, Bestawy WE, et al. Community-led comparative genomic and phenotypic analysis of the aquaculture pathogen *Pseudomonas baetica* a390T sequenced by Ion semiconductor and Nanopore technologies. *FEMS Microbiol Lett*. 2018 May;365(9):fny069.
- Mehta H, Mehta HB, Garg P, Kodial H. Voriconazole for the treatment of refractory *Aspergillus fumigatus* keratitis. *Indian J Ophthalmol*. 2008 May-Jun;56(3):243–5.
- Prajna NV, Mascarenhas J, Krishnan T, Reddy PR, Prajna L, Srinivasan M, et al. Comparison of natamycin and voriconazole for the treatment of fungal keratitis. *Arch Ophthalmol*. 2010 Jun;128(6):672–8.



**Fig. 1.** **a** Slit lamp photograph showing a central stromal infiltrate in the right eye. **b** Overlying epithelial defect. **c** Slit lamp photograph showing a raised central stromal plaque. **d** Slit lamp photograph showing a reduction of the stromal infiltrate and hypopyon.



**Fig. 2.** a, b Slit lamp photograph at week 7 shows complete resolution of the hypopyon with decreased stromal plaque. c At week 22, central dense stromal scar. d Slit lamp photograph showing a full-thickness corneal transplant.