

MEETING ABSTRACT

Open Access

Color-Doppler-Ultrasound guided compression to repair common femoral artery pseudoaneurysm

B Bonfiglio*, G Dipaola, G Rivoli, G Navarra

From de Senectute: Age and Health Forum
Catanzaro, Italy. 5-7 December 2009

Background

The insurgence of post-catheterization pseudoaneurysms has dramatically increased among the elderly if compared to the past, due to the spreading of endovascular treatments, both of diagnostic and surgical nature. The case presented here shows the usefulness of eco Color Doppler in this kind of pathology.

Materials and methods

Female, 76 y.o., with coronary disease, had undergone coronarography at another hospital. She came to our attention a month later, for suspected deep venous thrombosis of the right leg; we performed an Eco-color-Doppler on her, that showed a pseudoaneurysm of the common femoral artery, sized 4,5 mm x 3,4 mm (see Figure 1). The pseudoaneurysm was treated with ultrasound-guided compression through 7,5 MHz linear probe for about 55', until the pseudoaneurysm was totally excluded from the femoral artery due to the formation of a thrombus inside it (see Figure 2).

A week later, the eco-color-Doppler showed the stabilisation of the thrombus. One month later, the pseudoaneurysm was reduced, no flow was detected into it and no communication to the femoral artery remained.

Results and conclusions

The occurrence of post-catheterization pseudoaneurysms is increasing especially among the elderly; eco-guided compression is a non invasive treatment of these lesions and provides a viable option, as it allows the risks of traditional surgery to be avoided [1,2].

Published: 19 May 2010

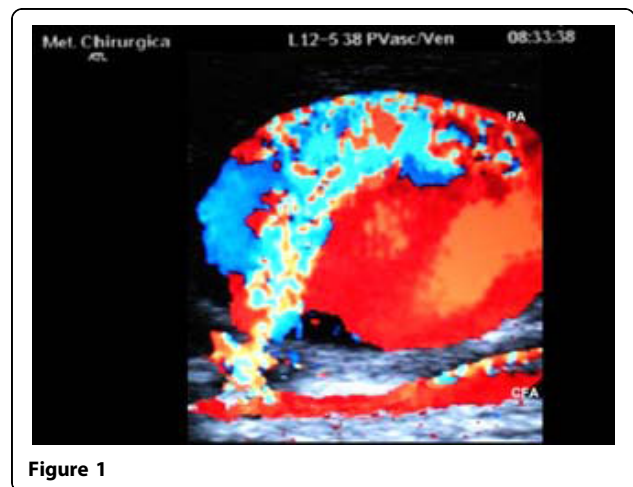


Figure 1

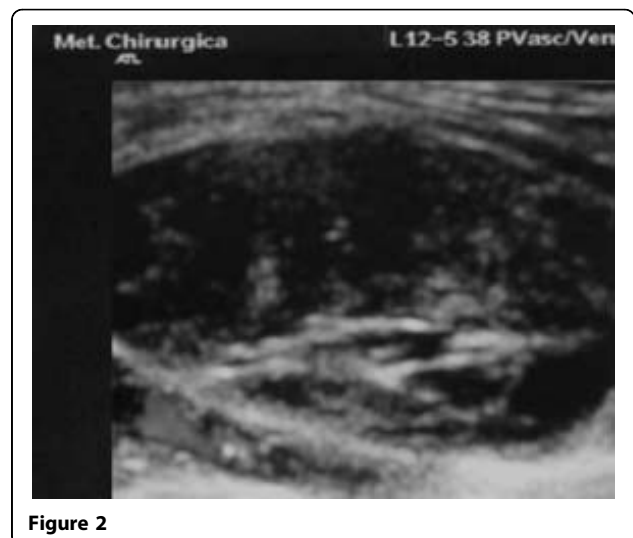

Figure 2

Phlebology and Wound Care, Surgical Department University Hospital,
Messina, Italy

References

1. Fellmeth BD, Roberts AC, Bookstein JJ, *et al*: Postangiographic femoral artery injuries: nonsurgical repair with US-guided compression. *Radiology* 1991, **178**:671-5.
2. Eisenberg L, Paulson EK, Kliewer MA, Hudson MP, DeLong DM, Carroll BA: Sonographically guided compression repair of pseudoaneurysms: further experience from a single institution. *AJR Am J Roentgenol.* 1999, **173**(6):1567-73.

doi:10.1186/1471-2318-10-S1-A45

Cite this article as: Bonfiglio *et al.*: Color-Doppler-Ultrasound guided compression to repair common femoral artery pseudoaneurysm. *BMC Geriatrics* 2010 **10**(Suppl 1):A45.

**Submit your next manuscript to BioMed Central
and take full advantage of:**

- Convenient online submission
- Thorough peer review
- No space constraints or color figure charges
- Immediate publication on acceptance
- Inclusion in PubMed, CAS, Scopus and Google Scholar
- Research which is freely available for redistribution

Submit your manuscript at
www.biomedcentral.com/submit

