



# Case report--mechanical bowel obstruction with appendicitis without strangulation and leukocytosis

Anil Khetarpal<sup>\*</sup>, Ayush Khetarpal

Department- General Surgery, Institution – Khetarpal Hospital, India

## ARTICLE INFO

### Keywords:

Acute appendicitis  
Mechanical intestinal obstruction  
Appendectomy  
Elderly

## ABSTRACT

Intestinal obstruction is a common surgical emergency caused by varied conditions. Acute appendicitis is considered as one of the unusual cause of intestinal obstruction especially functional and very few cases of mechanical obstruction. Here we report a Case of 62-years-old male who presented here with a clinical picture of small bowel obstruction. On laparotomy, there was a dilated gut with long appendix having inflamed tip buried into adjoining mesentery and then appendectomy was done and obstruction was relieved. Also, bowel was found to be viable hence simple appendectomy was found to be sufficient treatment. Histopathological findings was suggestive of chronic fibrosing appendicitis. Hence, in cases of bowel obstruction in an elderly patients with clinical examination which was not typical for appendicitis can be managed with laparotomy and simple appendectomy when early intervention is made to avoid the risk of ischemia and gangrenous changes in intestinal mesentery which may require resection in later stages.

## 1. Introduction

Acute appendicitis is the most common surgical condition with which patients present in emergency departments worldwide. The relationship between acute appendicitis and mechanical intestinal obstruction was first described by Hotchkiss et al. in 1901 and Hawkes in 1909 [1,2]. The clinical features of small bowel obstruction can obscure the clinical picture of appendicitis [3]. We here report an unusual Case of acute appendicitis that clinically presented in emergency department of private practice setting as mechanical small bowel obstruction without strangulation and leukocytosis.

## 2. Case report

A 62-years-old male patient who is a known Case of HTN, walked in private practice setting (emergency department) with a complaint of absolute constipation for 6 days associated with progressive abdominal distension and pain. He could not even tolerate any fluids or solid food and began to vomit, with no associated fever, weight loss or previous attacks of bleeding per-rectum. There was no history of tuberculosis or previous surgery.

On examination, he was alert, afebrile and hemodynamically stable, with no signs of dehydration and on per-abdominal examination, found

to have abdominal distension with sluggish bowel activity and lower abdominal tenderness. After initial resuscitation, X-ray abdomen (Erect & Supine) was done which showed multiple air/fluid levels on bilateral domes of diaphragm and multiple gas filled loops of small bowel throughout the abdomen and sonography showed few small polyps in the GB walls and fluid filled intestinal loops-S/O SAIO. Routine blood investigatory parameters revealed mild anaemia with coagulopathy and mildly deranged renal function with normal pancreatic enzymes and also found to have dyselectrolytemia for which treatment was imparted. CECT abdomen showed features of high grade small bowel obstruction with transition at the terminal ileum.

Supportive therapy given as i/v fluids, antibiotics (broad spectrum carbapenem group of antibiotic, nitroimidazole group of antibiotic) thrice daily, proton pump inhibitors twice daily, with insertion of nasogastric tube and urinary catheter. In view of coagulopathy, patient was transfused by FFP.

As clinical picture along with the CT findings, were suggestive of bowel obstruction but in view of physical examination (i.e. lower abdominal guarding and tenderness with sluggish bowel activity), an emergency decision was taken up for exploratory laparotomy with a doubtful diagnosis of bowel obstruction of unknown aetiology (as blood picture was not suggestive of infective/inflammatory aetiology) and a differential of bowel perforation (in view of lower abdominal tenderness

<sup>\*</sup> Corresponding author. F-95, Bali Nagar, New Delhi, 110015, India.

E-mail address: [khetarpalhospital@gmail.com](mailto:khetarpalhospital@gmail.com) (A. Khetarpal).

<https://doi.org/10.1016/j.amsu.2021.01.100>

Received 5 January 2021; Received in revised form 28 January 2021; Accepted 28 January 2021

Available online 4 February 2021

2049-0801/© 2021 The Authors. Published by Elsevier Ltd on behalf of IJS Publishing Group Ltd. This is an open access article under the CC BY-NC-ND license

(<http://creativecommons.org/licenses/by-nc-nd/4.0/>).

along with guarding and distension) was also considered prior to surgery.

After getting consent, patient underwent exploratory laparotomy and intra-operatively found to have dilated gut and long appendix (measuring approx. 6–8 inches) with large and firm base lying over ileal loops and tip buried into the adjoining mesentery and found to be inflamed (Fig. 1). Appendectomy performed and obstruction relieved (Fig. 2). After thorough wash of abdomen, two drains were kept and closed in layers.

Post-operatively, the patient was managed with bowel rest, appropriate fluid, optimum analgesia and antibiotics with transfusion of FFP and PRBC. Patient improved symptomatically without any surgical site infection with 2–3 episodes of low grade fever on post-operative day 1, for which all relevant investigations were sent which showed leukocytosis and then I/V antibiotics were modified accordingly. Patient condition improved gradually and was discharged with advice on 9th post-operative day.

The patient was then followed up after 7 days with no fresh complaints and biopsy specimen (Fig. 3) showed appendix (measuring 7 × 1x0.5cm) with necrotic material in its lumen-S/O Chronic Fibrosing Appendicitis (Fig. 4).

On 3-month follow up, he is doing well with normal bowel and bladder habits.

We ensured that the work has been reported in our manuscript is in line with the SCARE 2020 criteria [4].

### 3. Discussion

Appendix is a mobile organ with many variations in its normal position. During the initial event of appendicular inflammation, it would get adhered to surrounding structures and producing various pathologies and increased length of appendix seems to predispose such events (intestinal obstruction, bowel ischemia or gangrene of terminal ileum).

As per the literature reviewed, we found that intestinal obstruction resulting from acute appendicitis is classified pathologically into two subtypes: functional or paralytic subtype and mechanical obstruction subtype.

Mechanical bowel obstruction may be classified into either: (a) open loop, which is due to external compression on terminal ileum by inflammatory process in the appendix, either as an abscess or appendicular mass [5]; or (b) closed loop–appendiceal tourniquet (AT). AT is a very rare condition in which the appendix is wrapped around the bowel loop; this results from adherence of the appendicular tip to the ileocolic mesentery by a band or when an inflamed appendix adheres to cecum/retro-peritoneum and part of the bowel herniates through this defect [6].

We observed that the picture of intestinal obstruction dominates in our Case scenario. Clinical examination was not typical for appendicitis, as only physical findings of intestinal obstruction along with right iliac tenderness was evident. A leukocytes count was found to be within the

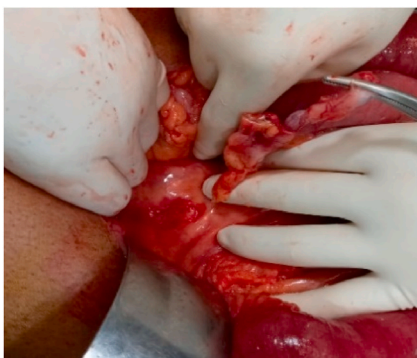


Fig. 1. Appendix tip buried in adjoining mesentery.

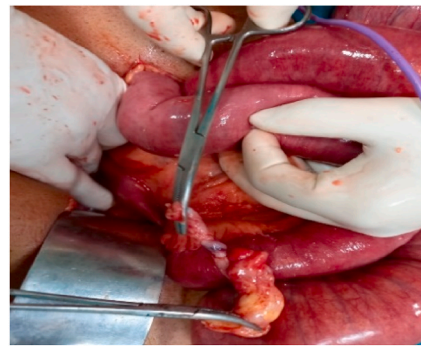


Fig. 2. Resected appendix from mesentery but still connected with cecum.

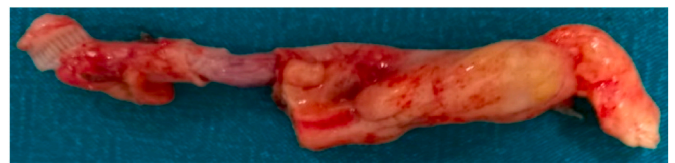


Fig. 3. Resected appendix.

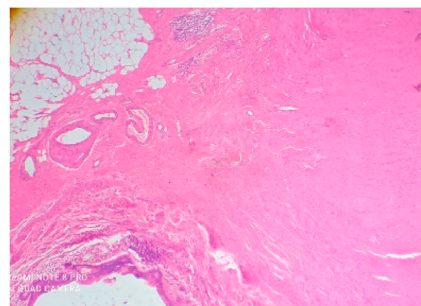


Fig. 4. Histopathological findings.

normal range in our study, although it has been reported to be elevated in some series [6]. Hence, leukocytosis is not a reliable indicator of acute appendicitis associated with mechanical small bowel obstruction. In this study, CT scan was able to show signs of mechanical obstruction but failed to demonstrate the definite cause of obstruction.

Small bowel obstruction might get associated with gangrenous ileal loop in a majority of cases due to delayed presentations, necessitating appendectomy and small bowel resection as a definitive treatment. In this Case, the bowel was found to be viable intra operatively, and this may be due to early presentation of the case seeking treatment and/or early intervention. Hence simple appendectomy was found to be sufficient treatment, as has been reported in a few series [7].

### 4. Conclusion

In cases of bowel obstruction in an elderly patients with clinical examination which was not typical for appendicitis can be managed with laparotomy and simple appendectomy when early intervention is made to avoid the risk of ischemia and gangrenous changes in intestinal mesentery which may require resection in later stages.

### Sources of funding

No funding sources.

### Ethical approval

Not required.

### Consent

A written informed consent was obtained from the patient for publication of this Case report and accompanying images.

### Author contribution

Drafting of manuscript, proofreading. All authors read and approved the final manuscript.

### Provenance and peer review

Not-commissioned, externally peer-reviewed.

### Guarantor

Dr. Anil Khetarpal & Dr. Ayush Khetarpal.

### Declaration of competing interest

All authors declared no conflict of interest.

### Appendix A. Supplementary data

Supplementary data related to this article can be found at <https://doi.org/10.1016/j.amsu.2021.01.100>.

### References

- [1] L.W.V. Hotchkiss, Acute intestinal obstruction following appendicitis. A report of three cases successfully operated upon, *Ann. Surg.* 34 (1901) 660–677 [PMID: 17861052].
- [2] F. Hawkes III., The prevention of intestinal obstruction following operation for appendicitis, *Ann. Surg.* 49 (1909) 192–207 [PMID: 17862302].
- [3] L. Awale, B.R. Joshi, S. Rajbanshi, S. Adhikary, Appendiceal tie syndrome: a very rare complication of a common disease, *World J. Gastrointest. Surg.* 7 (4) (2015) 67–70.
- [4] R.A. Agha, T. Franchi, C. Sohrabi, G. Mathew, A. Kerwan, For the SCAREGroup, “the SCARE 2020 guideline: updating consensus surgical Case report (SCARE) guidelines”, *Int. J. Surg.* (2020) <https://doi.org/10.1016/j.ijvs.2020.10.034>.
- [5] S. Harris, L.E. Rudolf, Mechanical small bowel obstruction due to acute appendicitis: review of 10 cases, *Ann. Surg.* 164 (1) (1966) 157.
- [6] L. Awale, B.R. Joshi, S. Rajbanshi, S. Adhikary, Appendiceal tie syndrome: a very rare complication of a common disease, *World J. Gastrointest. Surg.* 7 (4) (2015) 67.
- [7] S.N. Deshmukh, A.N. Maske, S.M. Bote, H.S. Parashi, Small bowel obstruction caused by appendiceal tourniquet, *Am. J. Surg.* 201 (2) (2011) e21–e22.