

Direct visualization of an atrial transeptal left ventricular endocardial lead implantation within an isolated heart



Zhongping Yang, PhD,^{*} Michael D. Eggen, PhD,^{*} Kyle R. Marquard, BS,^{*} Andrea J. Asleson, BS,^{*} Rick D. McVenes, BS,^{*} Paul A. Iaizzo, PhD[†]

From the ^{*}Medtronic, Inc, Minneapolis, Minnesota, and [†]Departments of Surgery, Biomedical Engineering, and Integrative Biology & Physiology, and the Institute for Engineering in Medicine, University of Minnesota, Minneapolis, Minnesota.

Introduction

Left ventricular (LV) endocardial pacing is a relatively new therapy that may offer several advantages over coronary venous lead placement for biventricular resynchronization therapy, including access to more regions of the LV, faster impulse propagation, avoidance of phrenic nerve stimulation, and more physiologic LV activation.¹ We report a case of transeptal implantation of a pacing lead in the LV chamber from a superior approach, which was observed using direct visualization, for better understanding of the implantation procedure and device-tissue interactions during the procedural steps.

Case report

Endoscopic cameras (IplexFX, Olympus Corporation, Tokyo, Japan) were placed within the right atrium, left atrium (LA), and LV of a human donor heart (LifeSource, St. Paul, MN) that was deemed not viable for transplantation. The heart was reanimated and perfused with a clear Krebs–Henseleit buffer according to previously described methodologies.^{2,3} The intrinsic sinus rhythm of the beating heart was 70 bpm. An external view of the experimental setup is shown in [Figure 1](#) and [Online Supplementary Video 1](#).

Initially, the right atrial septum was located using a deflectable catheter, and the fossa ovalis was tented using a dilator and a subselection catheter as viewed from the right atrium ([Figure 2A](#)) and LA ([Figure 2B](#)) (the delivery system, leads, and implant technique are not approved for investigational or commercial use in the United States). The fossa ovalis then

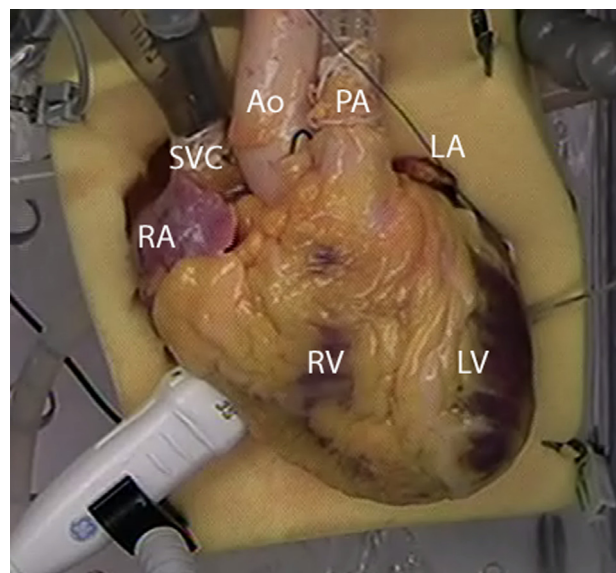


Figure 1 External view of the experimental setup showing the right atrium (RA), left atrium (LA), superior vena cava (SVC), aorta (Ao), pulmonary artery (PA), left ventricle (LV), and right ventricle (RV). Access to the heart was gained via an introducer placed in the SVC cannula.

was punctured using a radiofrequency (RF) wire ([Figure 2C](#)) and a generator (25 W at 2 seconds), and the RF wire (Baylis Medical Inc, Montreal, Quebec, Canada) was advanced into the LA ([Figure 2D](#)). The dilator was subsequently placed across the fossa ovalis within the LA using the RF wire as a guide ([Figure 2E](#)). Next, a subselection catheter was placed over the dilator, across the septum and into the LA ([Figure 2F](#)). After the dilator was withdrawn, the subselection catheter was directed toward the mitral valve, and the RF wire was advanced across the mitral valve without impinging on the chordae tendineae or leaflets ([Figure 2G](#)). Thereafter, the subselection catheter was guided over the RF wire and across the mitral valve ([Figure 2H](#)). The RF wire was removed, which allowed the subselection catheter to move freely within the LV. Note that in a clinical setting, a pressurized, continuous heparinized saline flush would then be attached to subselection catheter after removal of the RF wire. The subselection catheter was positioned on the lateral free wall of the LV, and an active fixation lead (3830 SelectSecure,

KEYWORDS Transeptal puncture; Cardiac resynchronization therapy; Isolated heart; Left ventricular pacing; Endocardial pacing

ABBREVIATIONS CRT = cardiac resynchronization therapy; LA = left atrium; LV = left ventricle; RF = radiofrequency (Heart Rhythm Case Reports 2015;1:107–109)

This work was funded in part by the Institute for Engineering in Medicine at the University of Minnesota and by Medtronic, Inc. Dr. Yang, Dr. Eggen, Kyle Marquard, Andrea Asleson, and Rick McVenes are employed by and have ownership interest in Medtronic, Inc. Dr. Iaizzo has consulted for Medtronic, Inc. **Address reprint requests and correspondence:** Dr. Paul A. Iaizzo, University of Minnesota, Department of Surgery, B172 Mayo, MMC 195, 420 Delaware St SE, Minneapolis, MN 55455. E-mail address: iaizz001@umn.edu.

KEY TEACHING POINTS

- Implantation of an LV endocardial lead is feasible using a superior atrial transeptal approach.
- A catheter-based delivery system with RF wire can be used to locate and puncture the atrial septum, and subsequently guide/implant an active fixation lead in the LV with minimal steps.
- An LV endocardial lead can be placed without impingement of the mitral valve.

Medtronic Inc, Mounds View, MN) was inserted into the catheter and fixated (**Figure 2I**). After fixation, the subselection catheter was withdrawn to ensure that the lead was fully fixated in the myocardium. The procedure can be viewed in [Online Supplementary Video 1](#).

Discussion

LV endocardial lead placement enables physiologic pacing and freedom to select an optimal LV pacing site in order to

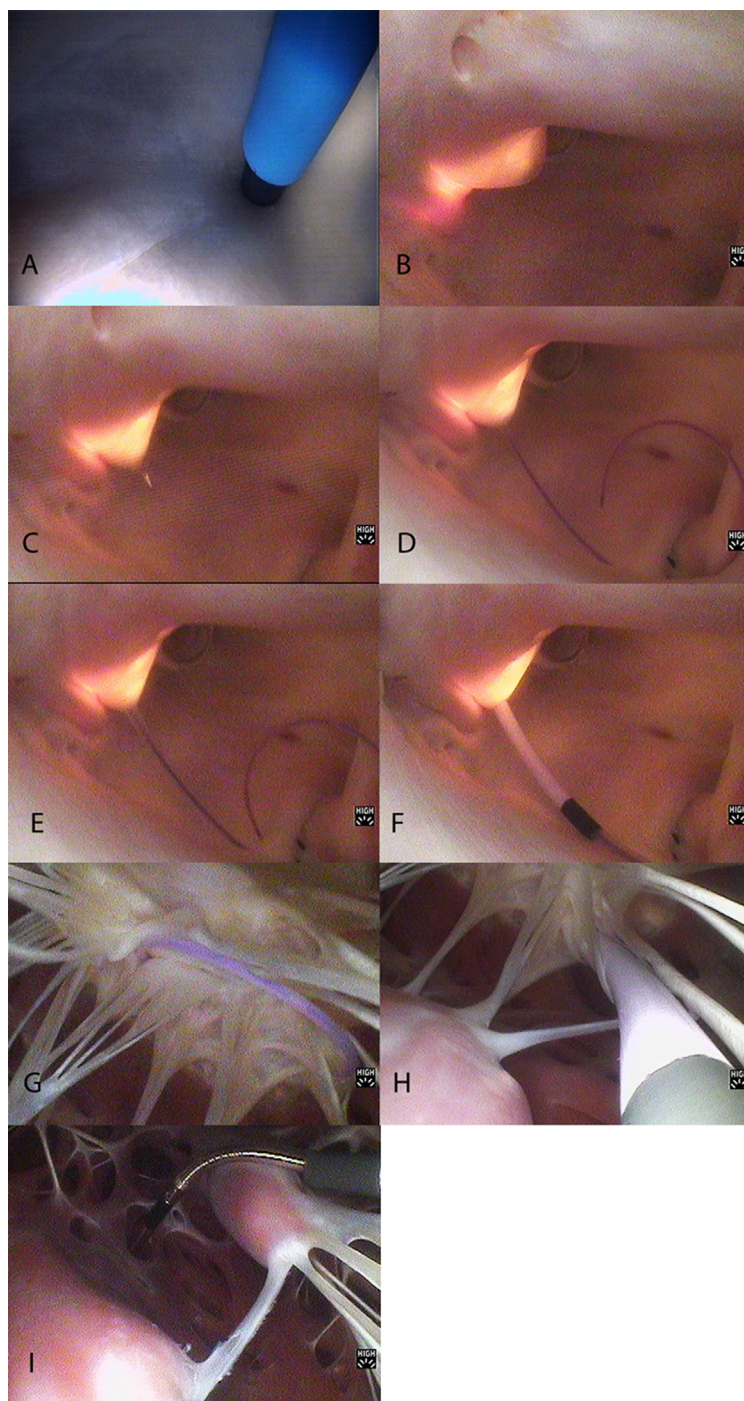


Figure 2 Transseptal left ventricular endocardial lead implantation sequence.

improve cardiac resynchronization therapy (CRT) outcome.^{4–6} Garrigue et al⁷ studied 15 patients with epicardial lead implants via the coronary sinus and compared them with 8 patients with endocardial leads placed by conventional transseptal puncture secondary to unsuitable coronary sinus anatomy. They reported a significant improvement in echocardiographic and Doppler variables in the patients who had undergone endocardial pacing. In addition, Bracke et al⁸ reported that endocardial LV pacing improved clinical efficacy in a nonresponder who previously had been implanted with a traditional CRT system. As such, implementation of endocardial LV pacing ultimately will depend on safe, effective, durable instrumentation and reliable, reproducible intraprocedural methods to identify the optimal LV pacing site. Another key to the future success of this pacing technique will be the ability to demonstrate significant benefit of LV endocardial pacing over the risk associated with thromboembolism in advanced heart failure patients with chronic pacing leads in the LV. Rademakers et al⁹ observed thromboembolic complications with endocardial pacing; however, the risk seemed to be strongly correlated with a subtherapeutic level of anticoagulation. Interestingly, endocardial pacing did not aggravate mitral regurgitation in these patients. Preliminary results from the ALSYNC (ALternate Site Cardiac ResYNChronization) study, which used the same techniques and delivery system demonstrated here, indicate that implantation of an LV endocardial pacing system is feasible, safe, and clinically successful.¹⁰ However, long-term follow-up data are needed to assess the long-term safety and efficacy of this approach to LV pacing/CRT.

In this case study, direct visualization aided in LV endocardial lead placement and demonstrated the feasibility of a novel LV endocardial lead delivery system. There was no impingement on the chordae tendineae or leaflets when the lead was placed across the mitral valve; however, the lead may be more difficult to position as precisely as when fluoroscopy is used in the clinical setting. Although placement of an LV lead using direct visualization is not representative of the visualization techniques available in a

clinical setting, the images presented here have notable educational value for both clinicians and design engineers.

Acknowledgment

We thank Gary Williams for video editing.

Appendix

Supplementary data

Supplementary data associated with this article can be found in the online version at <http://dx.doi.org/10.1016/j.hrcr.2015.01.001>.

References

1. Bordachar P, Derval N, Ploux S, Garrigue S, Ritter P, Haïssaguerre M, Jais P. Left ventricular endocardial stimulation for severe heart failure. *J Am Coll Cardiol* 2010;56:747–753.
2. Hill AJ, Laske TG, Coles JA Jr, Sigg DC, Skadsberg ND, Vincent SA, Soule CL, Gallagher WJ, Iaizzo PA. In vitro studies of human hearts. *Ann Thorac Surg* 2005;79:168–177.
3. Quill JL, Hill AJ, Menk AR, McHenry BT, Iaizzo PA. Multimodal imaging of a transcatheter aortic valve implantation within an isolated heart. *JACC Cardiovasc Imaging* 2011;4:11381139.
4. Bordachar P, Ploux S, Lumens J. Endocardial pacing: the wave of the future? *Curr Cardiol Rep* 2012;14:547–551.
5. Bordachar P, Grenz N, Jais P, et al. Left ventricular endocardial or triventricular pacing to optimize cardiac resynchronization therapy in a chronic canine model of ischemic heart failure. *Am J Physiol Heart Circ Physiol* 2012;303:H207–H215.
6. Bracke FA, van Gelder BM, Dekker LR, Houthuizen P, Ter Woortst JF, Teijink JA. Left ventricular endocardial pacing in cardiac resynchronisation therapy: moving from bench to bedside. *Neth Heart J* 2012;20:118–124.
7. Garrigue S, Jaïs P, Espil G, Labeque JN, Hocini M, Shah DC, Haïssaguerre M, Clementy J. Comparison of chronic biventricular pacing between epicardial and endocardial left ventricular stimulation using Doppler tissue imaging in patients with heart failure. *Am J Cardiol* 2001;88:858–862.
8. Bracke FA, Houthuizen P, Rahel BM, van Gelder BM. Left ventricular endocardial pacing improves the clinical efficacy in a non-responder to cardiac resynchronization therapy: role of acute haemodynamic testing. *Europace* 2010;12:1032–1034.
9. Rademakers LM, van Gelder BM, Scheffer MG, Bracke FA. Mid-term follow up of thromboembolic complications in left ventricular endocardial cardiac resynchronization therapy. *Heart Rhythm* 2014;11:609–613.
10. Morgan JM, Biffi M, Gellér LA, Ruffa F, Leclercq C, Tung S, Gerritse B, Ginneken M, Yang Z, Yee R, Jais P. Safety and efficacy of left ventricular endocardial lead pacing for cardiac resynchronization therapy: primary results of the ALternate Site Cardiac ResYNChronization (ALSYNC) study (abstract). Presented at the Heart Rhythm annual meeting, San Francisco, CA, May 7–10, 2014. Late Breaking Clinical Trials Abstract LB02-05.