

# Cryotherapy for the management of refractory hypotony secondary to post-goniotomy cyclodialysis cleft

David S. Portney<sup>a</sup>, Sarah J. Michelson<sup>b</sup>, Cagri G. Besirli<sup>b</sup>, Manjool Shah<sup>b,\*</sup>

<sup>a</sup> University of Michigan Medical School, 1301 Catherine St, Ann Arbor, MI, 48109, USA

<sup>b</sup> Department of Ophthalmology and Visual Sciences, Kellogg Eye Center, University of Michigan, 1000 Wall St, Ann Arbor, MI, 48105, USA

## ARTICLE INFO

### Keywords:

Cryotherapy  
Hypotony  
Cyclodialysis cleft

## ABSTRACT

**Purpose:** To report on the management of an unusual case of post-goniotomy hypotony.

**Observation:** A 41-year-old female with pigmentary glaucoma presented with a post-goniotomy cyclodialysis cleft and signs of hypotony maculopathy. Indirect cyclohexy closed the visible cleft but did not resolve her hypotony, despite neither ultrasonographic nor gonioscopic evidence of an open cleft or communication channel. Cryotherapy-induced cyclohexy and subsequent viscoelastic agent fill increased the intraocular pressure back to baseline.

**Conclusions:** This is the first reported case of cryotherapy correcting hypotony in a patient with no gonioscopic or ultrasonographic evidence of a cyclodialysis cleft. It demonstrates the utility of cryotherapy in the management of persistent ocular hypotony despite no detectable channel of aqueous outlet.

## 1. Introduction

Cyclodialysis clefts are a rare cause of ocular hypotony arising from the disruption of the circumferential insertion of the meridional ciliary muscle fibers into the scleral spur. An abnormal secondary pathway for the drainage of aqueous humor into the suprachoroidal space is established, resulting in chronic ocular hypotony through both increased aqueous outflow and decreased aqueous production.<sup>1</sup> Blunt ocular trauma is the most common cause of cyclodialysis clefts, though iatrogenic causes secondary to ocular surgery are not uncommon.<sup>2</sup>

Many medically refractory glaucoma patients require surgical intervention to decrease intraocular pressure (IOP) and prevent vision loss. One surgical option, goniotomy, has been shown to be a safe and effective means to treat such patients. In multiple studies, there were no reports of hypotony at 6 months.<sup>3,4</sup> However, in 2019, Shue et al. described a patient who developed a cyclodialysis cleft following a routine cataract extraction with intraocular lens implant and Kahook Dual Blade (KDB, New World Medical, Rancho Cucamonga, CA) goniotomy.<sup>5</sup> Closure of this patient's cyclodialysis cleft by repeated argon laser photocoagulation was achieved following failure of medical management.<sup>5</sup>

Many treatment options exist for the management of cyclodialysis clefts. Medical management with cycloplegic agents such as atropine, a

common first line treatment, typically only shows benefit in small clefts. Other treatment modalities include laser photocoagulation, transscleral diathermy, surgical intervention, and cryotherapy.<sup>2</sup> We report a case of a post-goniotomy cyclodialysis cleft presenting with hypotony, for which the visible cleft was closed with indirect surgical repair, yet the IOP remained low. Ultimately, the hypotony was successfully treated with cryotherapy. This case presents the unique role of cryotherapy for the successful treatment of persistent ocular hypotony after failure of resolution following indirect cyclohexy, despite lack of gonioscopic or ultrasonographic evidence of a residual cyclodialysis cleft.

## 2. Case report

A 41-year-old female with pigmentary glaucoma of the right eye presented to our institution for evaluation of hypotony. The patient was diagnosed with pigmentary glaucoma three years prior. Selective laser trabeculoplasty initially improved the IOP for over one year; however, following inadequate sustained pressure control, a goniotomy was performed. Postoperatively, the IOP ranged from 6 to 8 mmHg in the right eye despite treatment with atropine and prednisolone, raising suspicion of a cyclodialysis cleft.

At initial evaluation, her corrected visual acuity was 20/400 in the right eye and 20/20- in the left eye. She improved to 20/70- in the right

\* Corresponding author.

E-mail address: [manjool@med.umich.edu](mailto:manjool@med.umich.edu) (M. Shah).

<https://doi.org/10.1016/j.ajoc.2020.100876>

Received 7 May 2020; Received in revised form 17 July 2020; Accepted 18 July 2020

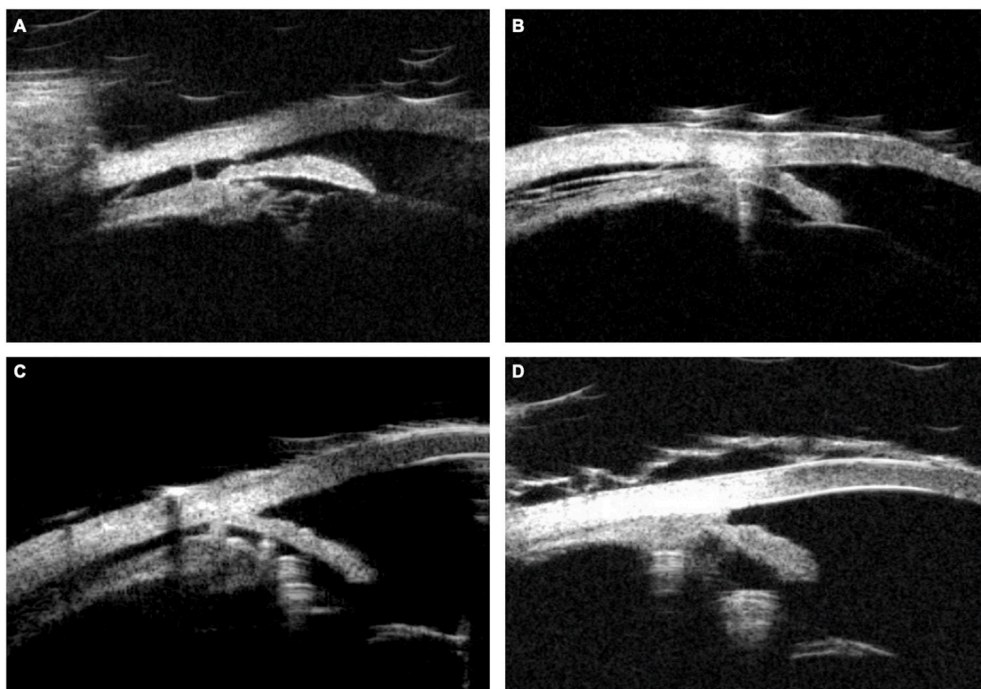
Available online 18 August 2020

2451-9936/© 2020 The Authors.

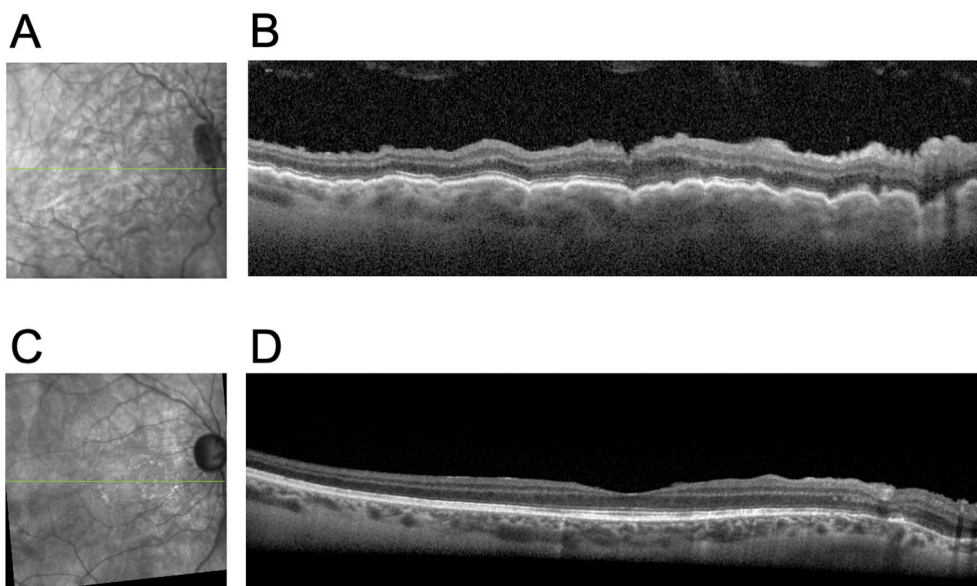
Published by Elsevier Inc.

This is an open access article under the CC BY-NC-ND license

(<http://creativecommons.org/licenses/by-nc-nd/4.0/>).



**Fig. 1.** Ultrasound biomicroscopy at the 4 o'clock region of the patient's right eye. Fig. 1A (initial presentation) shows the cyclodialysis cleft at this region. Fig. 1B (after indirect cyclopexy) demonstrates closure of the cleft, but there are residual supraciliary irregularities and fluid. Fig. 1C (after second indirect cyclopexy and subsequent viscoelastic fill) shows maintained closure of the cleft, but fluid remains in the supraciliary space. Fig. 1D (resolution after cryo- and subsequent viscoelastic fill) shows a closed space and no supraciliary fluid.

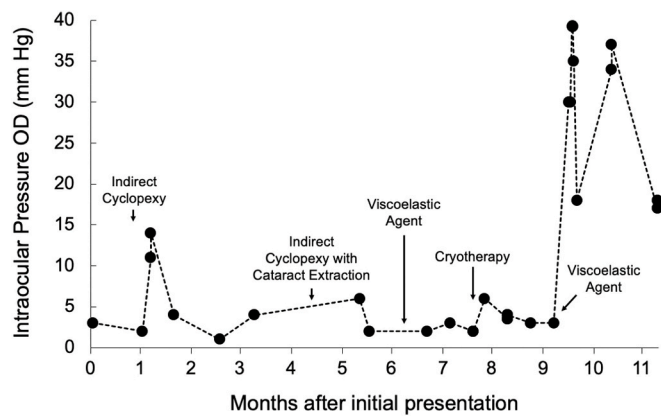


**Fig. 2.** Fundus images (A and C) and OCT findings (B and D) of patient's right eye. Figures A and B are from initial presentation and show hypotony maculopathy. Figures C and D show resolution of hypotony maculopathy.

eye with a new manifest refraction, which demonstrated a marked unilateral hyperopic shift with over five diopters of anisometropia. Applanation tonometry was 3 mmHg and 30 mmHg in the right and left eyes, respectively. Slit lamp examination of the right eye demonstrated a shallow anterior chamber and a Krukenberg spindle. Indirect gonioscopy demonstrated a cyclodialysis cleft to extend from 2 o'clock to 4 o'clock at the limbus. Fundus examination showed a full optic disc, macular folds, tortuous vasculature, and chorioretinal folds throughout the periphery, which was attached for 360° without visible choroidal effusions. Ultrasound biomicroscopy (UBM) confirmed the presence of a focal cyclodialysis cleft at 4 o'clock (Fig. 1A). Fundus images and optical coherence tomography (OCT) illustrated the presence of macular folds and choroidal thickening consistent with hypotony maculopathy

(Fig. 2A).

An indirect cyclodialysis cleft repair was performed. After creation of a paracentesis incision 180° opposite the cleft, cohesive viscoelastic was used to inflate the ciliary sulcus. Each arm of a double-armed 10–0 polypropylene suture on a long, straight STC-6 needle was brought through the paracentesis, into the sulcus, and out the sclera in order to reattach the ciliary body to the sclera in an ab-interno indirect manner. A concurrent goniotomy was done to limit the anticipated post-operative IOP spike. Repeat UBM post-operatively did not show a cyclodialysis cleft (Fig. 1B), however, IOP in the right eye remained low. After five months of consistent hypotony, a second indirect cyclopexy combined with cataract extraction and intraocular lens placement was performed in an attempt to close any remaining cleft with both the



**Fig. 3.** Intraocular pressure (OD) during patient course. The patient's right eye remained hypotonus after two indirect cyclohexy procedures. Initial viscoelastic agent fill did not lead to sustained increase in IOP. Cryotherapy followed by a second viscoelastic agent led to significant increase in IOP. Patient was then started on medical management for high IOP.

surgery and the subsequent inflammatory response. Following this procedure, repeat UBM combined with a viscoelastic agent fill showed persistent fluid in the supraciliary space at the same location as the prior cleft. Still, no cleft could be identified by UBM or gonioscopy (Fig. 1C). Of note, the patient reported transient discomfort and a brief period of improved acuity in the two days following the viscoelastic fill, which suggested the possibility of a transient closure of the cleft due to internal viscoelastic tamponade.

Cryotherapy-induced cyclohexy was performed to induce scarring of the presumed persistent track between the anterior segment and the suprachoroidal space. The right eye was anesthetized with topical proparacaine followed by subconjunctival 2% lidocaine. Under indirect ophthalmoscopic control, transconjunctival cryotherapy at  $-80$  C was delivered in contiguous applications around the area of cyclodialysis cleft at 4:00 and 4:30 positions with double freeze thaw of 20 seconds each (Cryomatic Console MKII, 2.5mm mid-reach retinal probe, Keeler, Malvern, PA). Indirect ophthalmoscopy confirmed freezing of ciliary processes in the treated area. Despite IOP remaining low one month postoperatively, the patient reported subjective improvement. A subsequent viscoelastic agent fill resulted in a sustained increase in intraocular pressure, illustrating full closure of remaining communication channels (Fig. 1D). Repeat imaging showed resolution of macular folds and normal choroidal thickness (Fig. 2B). Her visual acuity improved to 20/60+ with a new manifest refraction, which demonstrated reversal of the previous hyperopic shift. The patient resumed treatment for her pigmentary glaucoma with medical management and plans for filtration surgery. Right eye IOP throughout patient course is presented in Fig. 3.

### 3. Discussion

The literature surrounding the development of cyclodialysis clefts secondary to adult glaucoma procedures is sparse; one instance following goniotomy<sup>5</sup> and two following Trabectome<sup>6,7</sup> are chronicled in case reports. Our patient represents the second reported case of cyclodialysis cleft formation post-goniotomy. It is likely, however, that there are non-reported cases of cyclodialysis clefts and hypotony, possibly due to minimal hypotony or spontaneous resolution. In our patient's case, in particular, difficulty to distinguish the heavily pigmented trabecular meshwork from other angle structures may have increased the likelihood of iatrogenic cyclodialysis cleft formation. However, a prior study comparing results of Trabectome in patients with pigmentary glaucoma to primary open angle glaucoma showed no increase in post-operative complications.<sup>8</sup>

Treatment of post-operative hypotony maculopathy requires

correction of underlying low IOP, generally through anterior segment surgery. Improved prognosis tends to be tied to earlier detection and correction of hypotony maculopathy.<sup>1</sup> However, according to one case report, correction of hypotony led to visual improvement despite seven years of hypotony maculopathy.<sup>9</sup>

Cryotherapy is a less commonly used approach to treating cyclodialysis clefts, though it has been used successfully to close cyclodialysis clefts and normalize intraocular pressures in multiple cases.<sup>10-13</sup> Cryotherapy was utilized in these instances as a less invasive procedure prior to the more invasive cyclohexy, whereas our patient underwent cryotherapy after failed response to two indirect cyclohexies.

The most unique quality of our patient's case was her continued hypotony despite ultrasound evidence of cyclodialysis cleft closure. With continued hypotony, suspicion remained for a small residual fluid channel unable to be detected via gonioscopy or on ultrasound. Examination of clefts is often difficult, as any undue pressure on the globe can appear to reapproximate the defect. However, a true cleft remained unseen even when viscoelastic was used to fill the anterior chamber. Cryotherapy to the region of the prior cleft ultimately corrected the patient's hypotony. The increase in IOP secondary to cryotherapy and viscoelastic agent fill was primarily due to the closure of the communication channel, temporary blockage of the trabecular meshwork, and direct pressure from the viscoelastic agent. Additionally, post-cryotherapy under-perfusion of the nearby trabecular meshwork can lead to reduced aqueous outflow and a spike in pressure. This is the first reported case of cryotherapy correcting hypotony in a patient with no gonioscopic or ultrasonographic evidence of a cyclodialysis cleft.

### 4. Conclusions

Our patient's case demonstrates the utility of cryotherapy in the management of a patient with persistent ocular hypotony despite no visual evidence of a cyclodialysis cleft, but in which a clinical history suggests continued aqueous egress into the suprachoroidal space. Cryotherapy of the region near a previous cyclodialysis cleft should be considered as a treatment option for patients with hypotony refractory to cyclohexy.

### Patient consent

The patient consented to publication of the case in writing.

### Funding

No funding or grant support.

### Authorship

All authors attest that they meet the current ICMJE criteria for authorship.

### Declaration of competing interest

Manjool Shah: Glaukos Corp (consultant), Allergan, Inc (consultant), Katena (consultant). The following authors have no financial disclosures; DSP, SM, CGB.

### Acknowledgements

None.

### References

1. Besirli CG, Johnson MW. Uveal effusion syndrome and hypotony maculopathy. In: *Retina Fifth Edition*. vol. 2. 2012:1306-1317. <https://doi.org/10.1016/B978-1-4557-0737-9.00073-4>.

2. Ioannidis AS, Barton K. Cyclodialysis cleft: causes and repair. *Curr Opin Ophthalmol*. 2010;21(2):150–154. <https://doi.org/10.1097/ICU.0b013e3283366a4d>.
3. Salinas L, Chaudhary A, Berdahl JP, et al. Goniotomy using the kahook dual blade in severe and refractory glaucoma: 6-month outcomes. *J Glaucoma*. 2018;27(10):849–855. <https://doi.org/10.1097/IJG.0000000000001019>.
4. Greenwood MD, Seibold LK, Radcliffe NM, et al. Goniotomy with a single-use dual blade: Short-term results. *J Cataract Refract Surg*. 2017;43(9):1197–1201. <https://doi.org/10.1016/j.jcrs.2017.06.046>.
5. Shue A, Levine RM, Gallousis GM, Teng CC. Cyclodialysis cleft associated with kahook dual blade goniotomy. *J Curr Glaucoma Pract*. 2019;13(2):74–76. <https://doi.org/10.5005/jp-journals-10078-1255>.
6. Berk TA, An JA, Ahmed IIK. Inadvertent cyclodialysis cleft and hypotony following ab-interno trabeculotomy using the trabectome device requiring surgical repair. *J Glaucoma*. 2017;26(8):742–746. <https://doi.org/10.1097/IJG.0000000000000719>.
7. Osman EA, Al Mobarak F. Ciliochoroidal effusion with persistent hypotony after trabectome surgery. *Indian J Ophthalmol*. 2015;63(3):272–274. <https://doi.org/10.4103/0301-4738.156936>.
8. Akil H, Chopra V, Huang A, Loewen N, Noguchi J, Francis BA. Clinical results of ab interno trabeculotomy using the Trabectome in patients with pigmentary glaucoma compared to primary open angle glaucoma. *Clin Exp Ophthalmol*. 2016;44(7):563–569. <https://doi.org/10.1111/ceo.12737>.
9. Delgado MF, Daniels S, Pascal S, Dickens CJ. Hypotony maculopathy: improvement of visual acuity after 7 years. *Am J Ophthalmol*. 2001;132(6):931–933. [https://doi.org/10.1016/S0002-9394\(01\)01146-1](https://doi.org/10.1016/S0002-9394(01)01146-1).
10. Krohn J. Cryotherapy in the treatment of cyclodialysis cleft induced hypotony. *Acta Ophthalmol Scand*. 1997;75(1):96–98. <https://doi.org/10.1111/j.1600-0420.1997.tb00260.x>.
11. Pinheiro-Costa J, Benevides Melo A, Carneiro AM, Falcão-Reis F. Cyclodialysis cleft treatment using a minimally invasive technique. *Case Rep Ophthalmol*. 2015;6(1):66–70. <https://doi.org/10.1159/000375442>.
12. Ceruti P, Tosi R, Marchini G. Gas tamponade and cyclocryotherapy of a chronic cyclodialysis cleft. *Br J Ophthalmol*. 2009;93(3):414–416. <https://doi.org/10.1136/bjo.2008.146266>.
13. Helbig H, Foerster MH. Management of hypotonous cyclodialysis with pars plana vitrectomy, gas tamponade, and cryotherapy. *Ophthalmic Surg Laser*. 1996;27(3):188–191. <https://doi.org/10.3928/1542-8877-19960301-06>.