

Bloodstream Infection Combined with Thoracic Infection Caused by *Mycoplasma hominis*: A Case Report and Review of the Literature

Xuehong Duan^{1,*}, Le Wang^{2,*}, Ning Fan¹, Teng Li³, Jian Guo³

¹Department of Laboratory Medicine, The First People's Hospital of Xianyang, Xianyang, People's Republic of China; ²Department of Laboratory Medicine, Xianyang Hospital of Yan'an University, Xianyang, People's Republic of China; ³Department of Laboratory Medicine, Shanghai East Hospital, School of Life Sciences and Technology, Tongji University, Shanghai, People's Republic of China

*These authors contributed equally to this work

Correspondence: Jian Guo; Teng Li, Department of Laboratory Medicine, Shanghai East Hospital, School of Life Sciences and Technology, Tongji University, Shanghai, 200123, People's Republic of China, Email guojian1110@126.com; drliteng@163.com

Objective: *Mycoplasma hominis* is usually found in urogenital tract infections and is associated with several extra-genitourinary infections, including septic arthritis, bacteremia, and meningitis. Here, we report a rare case of *M. hominis* induced bloodstream infection with thoracic inflammation in a surgical patient.

Methods: A 56-year-old male who underwent surgery for multiple pelvic and rib fractures developed fever, pleural effusion, and wound exudation despite receiving prophylactic anti-infection treatment with cefotiam. Then, replacing the broad-spectrum antimicrobial drugs such as biapenem, imipenem, linezolid still had no obvious curative effect. Meanwhile, a total of 4 groups of blood cultures were collected from patients, of which 2 groups reported positive results 2 to 3 days after specimen collection. At the same time, the patient's pleural effusion and wound pus were also cultured, and transparent needle-like small colonies grew on Columbia blood agar plates within 2 to 3 days after inoculation.

Results: The cultured transparent pinpoint-like small colonies were identified as *M. hominis* by matrix-assisted laser desorption-ionization time-of-flight mass spectrometry (MALDI-TOF MS) and 16SrRNA sequencing. The results of antibiotic susceptibility testing (AST) showed that *M. hominis* was susceptible to doxycycline, minocycline, josamycin, sparfloxacin, and spectinomycin but resistant to azithromycin, clarithromycin, norfloxacin, roxithromycin, and ofloxacin. According to the AST results and clinical symptoms, moxifloxacin was selected as targeted therapy for *M. hominis* infection, and cefoperazone/sulbactam was combined to prevent the infection of other gram-negative bacteria. Finally, the patient was cured successfully.

Conclusion: Although *M. hominis* bloodstream and thoracic infections are rare, they cannot be ignored. *M. hominis* is intrinsically resistant to agents that work on bacterial cell wall synthesis used. Fluoroquinolones could be kept as potential active and thus a likely curative factor. When routine empirical anti-infection treatment is ineffective, the pathogen should be identified as early as possible. If necessary, gene sequencing technology should be used for diagnosis and sensitive anti-infection drug treatment should be promptly administered to reduce the risk of bloodstream infections.

Keywords: *Mycoplasma hominis*, infection, 16SrRNA sequencing, critical illness

Introduction

Mycoplasma belongs to the class Mollusca, which is characterized by the absence of a cell wall. Generally, *Mycoplasma hominis* colonizes the urogenital tract and can cause urogenital tract infections such as pelvic inflammatory disease or chorioamniotic infection.¹ Although infections outside the urogenital tract are relatively rare, there are still reports of *M. hominis* causing bacteremia combined with pneumonia,² mediastinitis after cardiac surgery,³ endocarditis,⁴ neonatal meningitis,⁵ etc. More importantly, treatment can be challenging because of *M. hominis* is the intrinsic antibiotic resistance to agents that work on bacterial cell wall synthesis, such as vancomycin, ceftriaxone, meropenem,

metronidazole, etc.² In addition, *M. hominis* infection has no typical clinical manifestations. Because of the lack of a cell wall, *Mycoplasma* cannot be observed by common staining methods, such as Gram staining, which increases the difficulty of clinical diagnosis and treatment of *M. hominis* infection.⁶ In this case, *M. hominis* was precisely identified as the pathogen using matrix-assisted laser desorption-ionization time-of-flight mass spectrometry (MALDI-TOF MS) or 16SrRNA sequencing, and bacteremia and pleural infection were effectively controlled by timely treatment based on the results of antibiotic susceptibility testing (AST).

Case

A 56-year-old man with multiple left rib fractures (4–12 ribs), pelvic fractures with retroperitoneal hematoma, and the traumatic diaphragmatic hernia was treated with internal fixation of rib fractures, pleural adhesion release and diaphragmatic hernia repair in emergency surgery, then cefotiam was used as a prophylactic to prevent and control infection. On the fourth postoperative day, the patient had severe symptoms of infection, with the highest temperature of 39.2°C and a small amount of fluid (approximately 160 mL) in the right thoracic cavity. The procalcitonin levels were 1.76 ng/mL (reference range, 0–0.05ng/mL) and rapid C-reactive protein levels were 63.41 mg/L (reference range, 0–5.0mg/L), these indicators of infection were significantly increased. The antibacterial drug was immediately replaced with biapenem, and no improvement in the clinical symptoms was observed. Imipenem and linezolid were successively administered on postoperative day 9. However, on postoperative day 20, the patient still had a fever, pleural effusion, and suppurative wound exudation.

Blood cultures were collected on postoperative day 7 and 9. Blood Culture Instruments (Thermo Field, USA) all indicated positive after two days of blood culture, and no pathogen was detected in the positive cultures by Gram or Wright's staining. Tiny, non-hemolytic, transparent colonies were observed on the third day of inoculation with the Columbia blood agar plate (Thermo Field, USA). (Figure 1A). Similarly, tiny, non-hemolytic, and transparent colonies

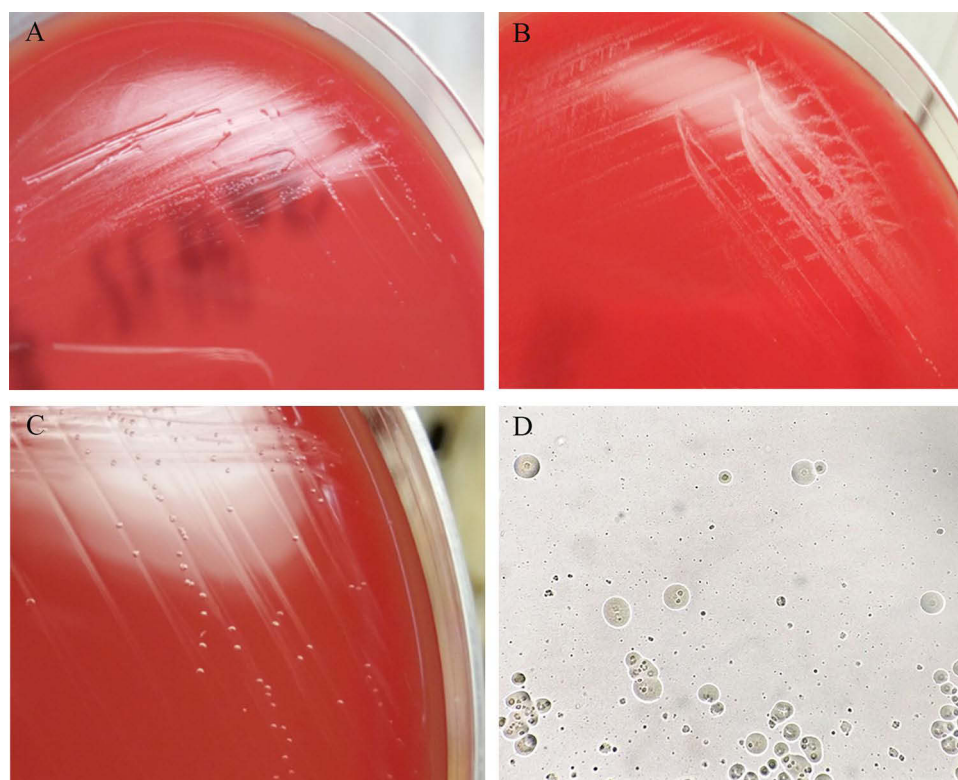


Figure 1 Representative results of sample culture (A) Tiny, non-hemolytic, and transparent colonies grew on the Columbia blood agar plate of blood-positive cultures three days after inoculation. (B) Tiny, non-hemolytic, and transparent colonies grew on the Columbia blood agar plate of pleural fluid sample cultures three days after inoculation. (C) On day 5, transparent and tiny colonies were observed on the blood agar plates with blood cultures. (D) Fried egg-type colonies were observed on mycoplasma medium after 5 days of incubation.

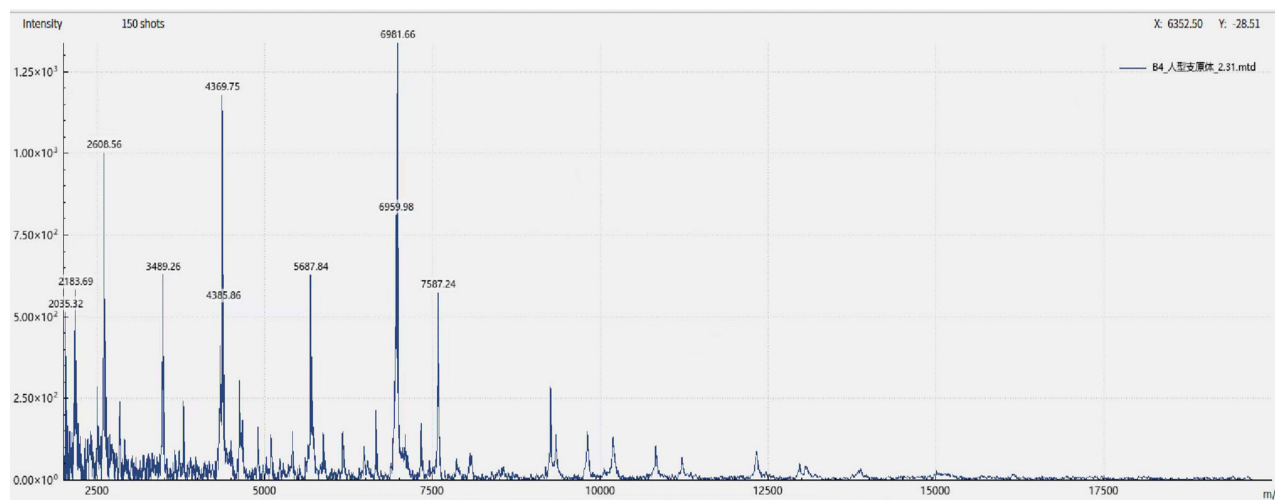


Figure 2 Peaks information of *M. hominis* using MALDI-TOF MS.

grew on the Columbia blood agar plate of pleural fluid sample cultures three days later. (Figure 1B). Thus, the Columbia blood agar plate was cultured for five days, and transparent and tiny colonies were still observed (Figure 1C). However, typical pathogen structures were not detected by Gram or Wright's staining. A subculture of blood and pleural fluid samples on the mycoplasma medium (A7 solid medium) presents as fried egg-type colonies after 5 days of incubation. (Figure 1D).

These tiny colonies were identified as *M. hominis* by MALDI-TOF MS EXS3000 (Zybio, China) with an identification score of 2.31 (Figure 2). Subsequently, *M. hominis* was also detected in the wound pus sample. AST using a commercial kit (broth dilution method, Zhonggaisheng, Hebei, China) after incubating at 35–37°C under aerobic conditions for 48 hours, the color change of the detection hole can be judged by visual detection. Yellow is negative, clear and transparent red is positive. The AST results showed that *M. hominis* was susceptible to doxycycline, minocycline, josamycin, sparflaxacin, and spectinomycin but resistant to azithromycin, clarithromycin, norfloxacin, roxithromycin, and ofloxacin. In addition, it is sensitive to high concentrations of ciprofloxacin and levofloxacin. (Figure 3). Based on AST and further multidisciplinary discussions, moxifloxacin was selected as targeted therapy for *M. hominis* infection, and cefoperazone/sulbactam was combined to prevent the infection of other gram-negative bacteria. The patient's infectious condition was alleviated after two weeks of medication. On postoperative day 36, the patient's blood culture results were negative and there were no other signs of clinical or microbial infection, suggesting that the infection was completely controlled. The diagnostic and treatment processes of the patient are shown in Figure 4. Colonies were further identified as *M. hominis* by 16sRNA sequencing (primers: 27F, AGAGTTTGATCMTGGCTCAG; 1492R, GGTTACCTTGTTACGACTT) with an identification rate of 99% (NCBI Sequence ID:gb|CP011538.1|).

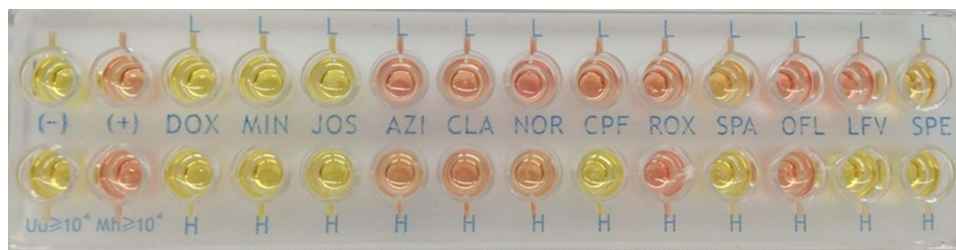

Figure 3 The results of antibiotic susceptibility testing of *M. hominis*.

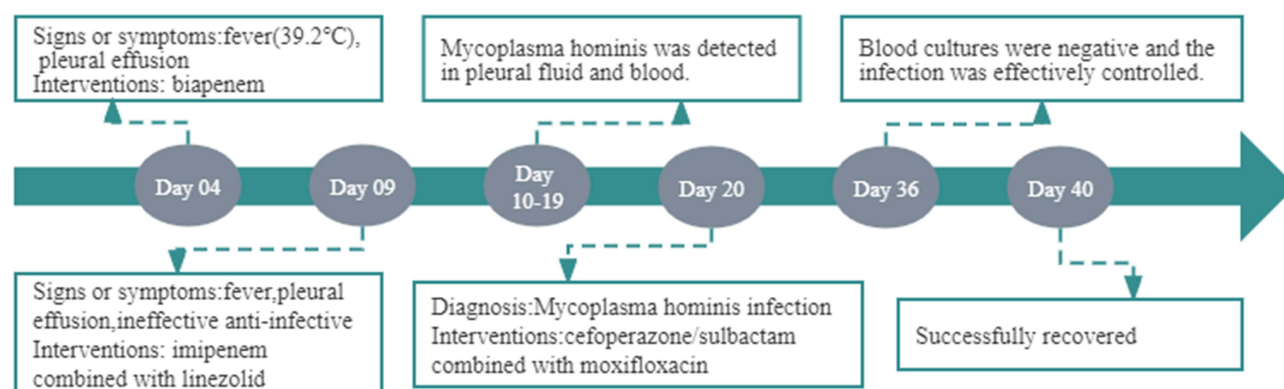


Figure 4 The diagnosis and treatment process of the patient.

Discussion

The class Mollicutes was established in the 1960s to include mycoplasmas and other related organisms. Currently, it consists of four orders, five families, eight genera, and over 200 known species of humans, vertebrates, arthropods, and plants. Among these, at least 17 species have been documented, primarily in the respiratory or genitourinary tracts.⁷ Sixteen species of *Mycoplasma* have been isolated from humans, with six identified as pathogenic: *Mycoplasma pneumoniae*, *Mycoplasma hominis*, *Mycoplasma genitalium*, *Mycoplasma fermentans*, *Ureaplasma parvum*, and *Ureaplasma urealyticum*.⁸

Point prevalence survey of healthcare-associated infections and antimicrobial use in European acute care hospitals in 2022–2023, only 0.5% of surgical site infections were caused by other bacteria (non-gram-positive or negative bacteria), and only 0.1% of *mycoplasma species* have been reported in HIV-infected people in France.⁹ Here, we present a rare case of bloodstream and pleural infections caused by *M. hominis* following multiple pelvic and rib fractures. We reviewed the literature over the past decade and found three reports of bloodstream infections combined with pleural infections caused by *M. hominis* after trauma or surgery and nine reports of pleural infections caused by *M. hominis* after trauma or surgery (Table 1).

Postoperative fever, often accompanied by pleural effusion or wound suppurative inflammation, was the most common clinical feature observed in these cases. All the patients recovered after receiving targeted antimicrobial therapy. Notably, 91.67% (11/12) of the patients underwent relevant surgical interventions. Invasive surgical procedures, such as endotracheal intubation and urinary catheterization, have been identified as potential factors contributing to the opportunistic invasion of *M. hominis* and subsequent bloodstream infections or infections at other sites.

Due to the lack of a cell wall and the high polymorphism of *M. hominis*, Gram staining is ineffective in identifying this pathogen, leading to challenges in clinical detection and potentially missed diagnoses. In addition, the transition from clinical empiric antimicrobial therapy to targeted antimicrobial therapy has also been challenged and jeopardised. Slow-growing *M. hominis* often requires several days for colony formation on traditional culture media, delaying diagnosis.^{6,17} Extending the culture time can effectively enhance detection rates, and some studies suggest culturing under anaerobic conditions.^{1,3,16} Aerobic and anaerobic cultures can be inoculated simultaneously to enhance the detection rate of *M. hominis*. Despite this approach, some cases of *M. hominis* infection may still be overlooked. Therefore, molecular detection methods such as 16sRNA sequencing and metagenomic next-generation sequencing (mNGS) are considered timely and effective diagnostic techniques for detecting *M. hominis* infection. The absence of effective or rapid microbial identification and targeted therapy with antimicrobials can lead to persistent infections, prolonged hospital stays and unnecessary waste of medical resources. The successful management of this case hinged on culturing *M. hominis* from both the blood and pleural effusion, followed by 16sRNA sequencing analysis to confirm the pathogen. Based on drug sensitivity experiments and expert advice, targeted moxifloxacin treatment was chosen, resulting in a successful outcome. Laboratory identification and clinical diagnosis of *M. hominis* infection can be challenging, with the routine clinical empirical use of broad-spectrum antibiotics often proving ineffective. Therefore, early, rapid, and accurate detection of

Table 1 The Summary of Bloodstream Infections and Pleural Infections Caused by *M. hominis* After Trauma or Surgery

Case	Age (Years), Sex	Underlying Disease Surgery	Signs or Symptoms (Days after Surgery)	Positive Sample (Method)	Targeted Treatment	Outcome	Reference
1	50, male	Aortic coarctation, ascending aorta replacement	Fever, (38.3°C) pleural effusion (5 days)	Wound secretions, urine (culture, MALDI-TOF MS, whole-genome sequencing)	Moxifloxacin	Recovered	Gen Li et al (2024) ⁸
2	63, male	Antineutrophil cytoplasmic antibody (ANCA)-associated vasculitis	Fever (38°C) lung inflammation with increased pleural effusion (16 days)	Blood (culture, MALDI-TOF MS, Next-generation sequencing, qPCR)	Levofloxacin , polymyxin B and meropenem	Recovered	Yili Chen et al (2023) ⁶
3	58, male	Pulmonary fibrosis and peripheral vascular disease bilateral lung transplantation	Significant bibasilar atelectasis and worsened right pleural effusion (7 days)	Pleural fluid (culture, MALDI-TOF MS, 16SrDNA sequencing)	Doxycycline	Recovered	Afrinash Ahamad et al (2023) ¹⁰
4	21, male	Becker Muscular Dystrophy and cardiomyopathy, orthotopic heart transplant	Purulent respiratory Secretions and right basilar consolidation (4 days)	Bronchoalveolar lavage fluid (culture, 16SrDNA sequencing)	Minocycline and levofloxacin	Recovered	Afrinash Ahamad et al (2023) ¹⁰
5	43, male	Multiple open traumas, surgery of multiple injuries	Fever, (38.4°C) (2 days)	Blood and wound samples (culture, MALDI-TOF MS, 16SrRNA sequencing)	Minocycline , meropenem plus teicoplanin	Recovered	Shi-Mei Huang et al (2023) ¹¹
6	56, male	Left basal ganglia hemorrhage, microsurgery and decompression Craniectomy	High fever, (38.6°C) inflammation of the lungs, pleural effusion (8 days)	Blood, bronchoalveolar lavage (BAL) fluid (culture, MALDI-TOF MS, 16SrRNA sequencing, next-generation sequencing)	Doxycycline combined with moxifloxacin	Recovered	Qiang Wang et al (2022) ²
7	22, male	Pelvic ring injury and urethral injury, surgical	Fever, (38.6°C), anterior abdominal wall effusion (3 days)	Pus Samples (culture, MALDI-TOF MS)	Clindamycin	Recovered	Jordan Bethel et al (2022) ¹²
8	63, male	Pneumonia in the right lower lobe	Fever, (40°C), pleural fluid (14 days)	Pleural effusion, blood, lung tissue (PCR)	Levofloxacin and doxycycline	Recovered	Isabelle Moneke et al (2021) ¹³
9	54, male	Aortic valve stenosis and patent foramen ovale (PFO), cardiac surgery	Fever, pleural effusion, wound abscess (11 days)	Abscess, tissue, and urine samples (culture, MALDI-TOF MS, PCR)	Levofloxacin and vancomycin	Recovered	Hiroki Kitagawa et al (2021) ³
10	28, female	Cesarean section	Fever, (38.6°C), pleural effusion (2 days)	Pleural fluid, vaginal secretions (culture, PCR)	Clindamycin	Recovered	Masatoshi Yamazoe et al (2018) ¹⁴
11	18, female	Stem cell and lung transplant	Pleural effusion (5 days) fever, (38.2°C) (8 days)	Pleural effusion (culture, 16SrRNA sequencing)	Moxifloxacin and clindamycin, doxycycline, clindamycin.	Recovered	Avika Dixit, et al (2017) ¹⁵
12	37, male	A type A aortic dissection, cardiac surgery	Fever (39.6°C) A purulent discharge from the sternotomy (20 days)	Bone biopsy and abscess samples (culture, 16SrDNA sequencing, Bruker Daltonics MALDI-TOF MS undetectable)	Levofloxacin	Recovered	Re'mi Le Guern et al (2015) ¹⁶

Note: Bolded text indicates antimicrobials reported in the literature to be effective in targeted therapy.

pathogens is essential. The possibility of *M. hominis* infection should be considered in patients showing symptoms of infection postsurgery, such as persistent fever and elevated levels of C-reactive protein (CRP), procalcitonin (PCT), and interleukin-6 (IL-6), where conventional broad-spectrum antibiotic treatment fails, consideration should be given to the possibility of *M. hominis* infection. More importantly, antibiotic susceptibility testing for *M. hominis* is crucial but poses challenges for most laboratories. Quinolone antibiotics such as levofloxacin and moxifloxacin are typically effective against *M. hominis*, although instances of drug resistance due to genetic mutations have been reported.^{18,19} Our study involved antibiotic susceptibility testing of cultured *M. hominis*, which revealed that doxycycline, minocycline, josamycin, and spectinomycin exhibited higher sensitivity.

According to literature descriptions, *M. hominis* has been detectable in urine samples in 20–40% of healthy individuals.²⁰ The patient in this report had multiple pelvic fractures. Whitson et al suggested that urogenital trauma may contribute to urinary tract injury. Genital commensal bacteria create pathways for invasion of the pelvis and abdomen.²¹ Therefore, it is hypothesized that the infection originated from an ascending thoracic infection due to pelvic fractures, leading to bloodstream infection after surgery involving multiple pelvic and thoracic fractures, although this hypothesis was not confirmed. *M. hominis* was isolated from the pleural effusion and blood, but no homology analysis was conducted between the pelvic effusion, pleural effusion, or blood samples. Nonetheless, this speculation provides valuable clinical insights. Patients undergoing invasive procedures through the genitourinary tract following trauma or surgery, especially those with postpelvic urinary system trauma, are at a high risk of *M. hominis* infection. Bloodstream infections can occur simultaneously with infections at other sites. Therefore, postoperative wound fluid irrigation and drainage are crucial interventions along with appropriate antibiotic therapy.¹² Based on this case report, we recommend preoperative screening for *M. hominis* in the urinary and respiratory systems of these patients to proactively identify potential risks.

Conclusion

This case demonstrates that *M. hominis* can lead to infections beyond the genitourinary system, particularly in patients who have undergone invasive procedures or experienced trauma in the genitourinary tract. In cases where patients exhibit postoperative fever and do not respond to standard broad-spectrum antibiotic therapy, clinicians should consider the potential presence of mycoplasma infection.

Data Sharing Statement

The original contributions of this study are included in the article. Further inquiries can be directed to the corresponding authors.

Ethics Approval and Consent

Ethical approval was obtained from the Shanghai East Hospital (Tongji University School of Medicine). The patient provided written informed consent to participate in this study.

Acknowledgments

We are grateful to the patients for their cooperation in the diagnostic process.

Author Contributions

All authors made a significant contribution to the work reported, whether that is in the conception, sample culture and isolation, antibiotic susceptibility testing, analysis, and interpretation, or in all these areas, took part in drafting, revising, or critically reviewing the article; gave final approval of the version to be published; agreed on the journal to which the article has been submitted; and agreed to take responsibility and be accountable for the content of the article.

Funding

The authors declare that they received no funding for this study.

Disclosure

The authors have no competing interests to declare relevant to the content of this article.

References

1. Stabler S, Faure E, Duployez C, et al. The Brief Case: *mycoplasma hominis* Extragenital Abscess. *J Clin Microbiol*. 2021;59(4):e02343–20. doi:10.1128/JCM.02343-20
2. Wang Q, Tang X, van der Veen S. *Mycoplasma hominis* bloodstream infection and persistent pneumonia in a neurosurgery patient: a case report. *BMC Infect Dis*. 2022;22(1):169. doi:10.1186/s12879-022-07137-4
3. Kitagawa H, Shimizu H, Katayama K, et al. Postoperative mediastinitis after cardiac surgery caused by *Mycoplasma hominis*: a case report. *Surg Case Rep*. 2021;7(1):248. doi:10.1186/s40792-021-01326-0
4. Bustos-Merlo A, Rosales-Castillo A, Cobo F, et al. Blood culture-negative infective endocarditis by *Mycoplasma hominis*: case report and literature review. *J Clin Med*. 2022;11(13):3841. doi:10.3390/jcm11133841
5. Xi M, Cui S, Zhong YL, et al. Meningitis in neonate caused by *Mycoplasma hominis*: a case report. *Heliyon*. 2023;10(1):e23489. doi:10.1016/j.heliyon.2023.e23489
6. Chen Y, Chen H, Huang H, et al. Application of next-generation sequencing on diagnosis of bloodstream infection caused by *Mycoplasma hominis* in a patient with ANCA-associated vasculitis. *Ann Clin Microbiol Antimicrob*. 2023;22(1):28. doi:10.1186/s12941-023-00580-4
7. Waites KB, Katz B, Schelonka RL. *Mycoplasmas* and *Ureaplasmas* as neonatal pathogens. *Clin Microbiol Rev*. 2005;18(4):757–789. doi:10.1128/CMR.18.4.757-789.2005
8. Li G, Yu W, Ye Y, et al. Postoperative mediastinitis and sternal osteitis after cardiac surgery caused by *Mycoplasma hominis*: a case report. *Diagn Microbiol Infect Dis*. 2024;108(3):116170. doi:10.1016/j.diagmicrobio.2023.116170
9. European Centre for Disease Prevention and Control. Point prevalence survey of healthcare associated infections and antimicrobial use in European acute care hospitals. *Stockholm*. 2024. doi:10.2900/88011
10. Ahamad A, Zervou FN, Agüero-Rosenfeld ME. Extra-urogenital infection by *Mycoplasma hominis* in transplant patients: two case reports and literature review. *BMC Infect Dis*. 2023;23(1):601. doi:10.1186/s12879-023-08593-2
11. Huang SM, Tang YR, Wang JL, et al. Case report: double trouble: a rare case of successfully treated *Mycoplasma hominis* and *Pseudomonas aeruginosa* co-infection. *Front Cell Infect Microbiol*. 2023;13:1159891. doi:10.3389/fcimb.2023.1159891
12. Bethel J, Tissingh EK, Vasireddy A, et al. *Mycoplasma hominis*: postoperative pelvic fracture-related infection in a trauma patient. *Br J Hosp Med*. 2022;83(9):1–4. doi:10.12968/hmed.2022.0103
13. Moneke I, Hornuss D, Serr A, et al. Lung Abscess and Recurrent Empyema after infection with *Mycoplasma hominis*: a Case Report and Review of the Literature. *Open Forum Infect Dis*. 2021;9(1):ofab406. doi:10.1093/ofid/ofab406
14. Yamazoe M, Tomioka H, Yamashita S, et al. *Mycoplasma hominis* empyema following caesarean section. *Respirol Case Rep*. 2018;6(8):e00367. doi:10.1002/rccr.2.367
15. Dixit A, Alexandrescu S, Boyer D, et al. *Mycoplasma hominis* empyema in an 18-year-old stem cell and lung transplant recipient: case report and review of the literature. *J Pediatric Infect Dis Soc*. 2017;6(4):e173–e176. doi:10.1093/jpids/pix049
16. Le Guern R, Loiez C, Loobuyck V, et al. A new case of *Mycoplasma hominis* mediastinitis and sternal osteitis after cardiac surgery. *Int J Infect Dis*. 2015;31:53–55. doi:10.1016/j.ijid.2014.12.028
17. Xiang L, Lu B. Infection due to *Mycoplasma hominis* after left Hip replacement: case report and literature review. *BMC Infect Dis*. 2019;19(1):50. doi:10.1186/s12879-019-3686-z
18. Lee JY, Yang JS. Prevalence and antimicrobial susceptibility of *Mycoplasma hominis* and *Ureaplasma* species in nonpregnant female patients in South Korea indicate an increasing trend of pristinamycin-resistant isolates. *Antimicrob Agents Chemother*. 2020;64(10):e01065–20. doi:10.1128/AAC.01065-20
19. Paira DA, Olivera C, Tissera AD, et al. *Ureaplasma urealyticum* and *Mycoplasma hominis* urogenital infections associate with semen inflammation and decreased sperm quality. *J Leukoc Biol*. 2023;113(1):18–26. doi:10.1093/jleuko/qiac006
20. Divithotewala C, Sweeney EL, Burke A, et al. *Mycoplasma hominis* and *Ureaplasma urealyticum* infections in the immediate post-lung transplant period: a case series and literature review. *Transpl Infect Dis*. 2023;25(3):e14058. doi:10.1111/tid.14058
21. Whitson WJ, Ball PA, Lollis SS, et al. Postoperative *Mycoplasma hominis* infections after neurosurgical intervention. *J Neurosurg Pediatr*. 2014;14(2):212–218. doi:10.3171/2014.4.PEDS13547

Infection and Drug Resistance

Dovepress

Publish your work in this journal

Infection and Drug Resistance is an international, peer-reviewed open-access journal that focuses on the optimal treatment of infection (bacterial, fungal and viral) and the development and institution of preventive strategies to minimize the development and spread of resistance. The journal is specifically concerned with the epidemiology of antibiotic resistance and the mechanisms of resistance development and diffusion in both hospitals and the community. The manuscript management system is completely online and includes a very quick and fair peer-review system, which is all easy to use. Visit <http://www.dovepress.com/testimonials.php> to read real quotes from published authors.

Submit your manuscript here: <https://www.dovepress.com/infection-and-drug-resistance-journal>