

A bone fide atypical fibroxanthoma of penis

Roberto Cuomo¹, Maria Adesso², Roberto Altieri¹, Antonio D'Antonio³

¹Department of Medicine and Surgery, University of Salerno, ²Unit of Pathologic Anatomy, ASL Salerno, Hospital Scarlato, Scafati,

³Department of Pathologic Anatomy, A. O. U. S. Giovanni and Ruggi D' Aragona, Salerno, Italy

Abstract

Malignant mesenchymal tumors of the penis are very rare and they have vascular origin. We present a case of a 71-year-old man with a painless nodule of 2.0 cm in diameter located in the penile foreskin. There was no history of urinary or sexually transmitted disease. An excisional biopsy revealed a markedly pleomorphic sarcoma resembling atypical fibroxanthoma (AFX) associated with a squamous cell carcinoma *in situ*. The patient refused a wide re-excision and was free of disease after 36 months. Because the different therapeutic management and prognosis, differential diagnosis should be made with sarcomatoid squamous cell carcinoma and melanoma: A diagnosis of AFX or malignant fibrous histiocytoma may be considered only after the complete exclusion of these two entities.

Key Words: Atypical fibroxanthoma, CD10, differential diagnosis, penis

Address for correspondence:

Dr. Antonio D'Antonio, Unit of Pathologic Anatomy, A. O. "San Giovanni di Dio e Ruggi d'Aragona" via S. Leonardo, Salerno, Italy.
E-mail: ada66@inwind.it

Received: 08.01.2013, Accepted: 28.04.2013

INTRODUCTION

The term atypical fibroxanthoma (AFX) was used in 1961 by Helwig for indicate a typically nodular ulcerative lesion arising from the sun-exposed skin of the head and neck.^[1]

Rarely AFX has been described in young and in areas without evidence of actinic damage.

The purpose of this case report is underlining the problems of differential diagnosis and therapeutic management of AFX in this previously not described site.

CASE REPORT

A 71-year-old man presented to our hospital with a painless, erythematous, and ulcerated nodule of the penile foreskin

with rapid growth within 4 months. The lesion was 2.0 cm × 1.5 cm. The adjacent tissues were erythematous. The patient had a history of long-term condom catheter use, because incontinent following a motor vehicle accident 3 years ago. The physical examination did not reveal the presence of keratosis or other injuries consistent in damage caused by radiation or scars due to burns.^[2]

Examination of penile shaft, testicles, spermatic cord, and inguinal lymph nodes were unremarkable.

We performed an excisional biopsy with negative margins.

The surgical specimen was a crusted nodule measuring cm 2.0 in maximum diameter.

Histological examination (hematoxylin and eosin stained slides) showed a mesenchymal tumor composed of atypical cells, arranged in a vaguely fascicular patten diffusely infiltrating the subepithelial connective with a residual "grenz zone" of uninvolved tissue characterized by a dense lymphocytic infiltrate [Figure 1]. The cells were spindle and exhibited marked pleomorphism; anaplastic and multinucleated giant cells were also evident. A variable number of typical and atypical mitosis were present. Some thick rope-like collagen

Access this article online	
Quick Response Code:	Website: www.urologyannals.com
	DOI: 10.4103/0974-7796.141009

bundles and dilated capillaries were also present. Necrosis was not observed. The mesenchymal proliferation was lined by an atypical squamous epithelium (carcinoma *in situ*) [Figure 2]. Immunohistochemical analysis showed that spindle and giant cells were positive for vimentin and CD10 [Figure 3a and b], but negative for CD34, Epithelial Membrane Antigen S100 protein [Figure 3c], HMB45, CKpan [Figure 3d], CK7 and focally positive CD68. On the basis of these findings, a diagnosis of AFX was made. Wound healing was uncomplicated and 36 months follow-up did not show a recurrence although the lesion has not been re-excised.

DISCUSSION

AFX is a rare neoplastic disease of the skin. It was considered as a superficial variant of malignant fibrous histiocytoma (MFH)^[1,2] until the early 1960s. When the concept of MFH was re-evaluated and the term “undifferentiated pleomorphic sarcoma” (UPS) was introduced, the doubt about the nature and origin of AFX was increased.^[3] Current opinions and evidence of clinical and diagnostic differences between AFX and MFH are pointed to consider AFX as a distinct entity with MFH/UPS.^[4,5] The AFX generally arises on the skin damaged by radiation, particularly in solar phototype subjects below. Often it is localized in areas such as head and neck of elderly patients surrounded by areas with apparent actinic damage; moreover, it may localize on burn scars. Some patients with a diagnosis of AFX have a history of other diagnosis of other skin neoplasms. Macroscopically, it appears as a solitary nodule with sharp margins of dome shape or ulcers usually measuring less of 2 cm. It is histologically characterized by a high number pleomorphic, spindle, and multinucleated giant cells resembling a pleomorphic sarcoma of other site. Because AFX is considered a tumor with low malignancy that rarely developed metastasis; therefore, the use of this diagnosis should be made only after the exclusion of other most common malignancy. Yet, the diagnosis of AFX requires an extensive tumor-sampling to research areas with a specific pattern and a complete battery of immunohistochemical markers. Some important entities in the differential diagnosis that must be ruled out are other poorly differentiated sarcomas, sarcomatoid squamous cell carcinoma, and desmoplastic melanoma. There are no immunohistochemical markers specific for AFX; however, a panel of antibodies including S100 protein, cytokeratins, EMA, HMB45, and vimentin should be always made. The positivity of CD10 is a valuable addition to the battery of antibodies for immunophenotyping, but it is not specific because it is expressed also of other tumors. In all case, a histological and immunochemical differentiation is difficult. The pathogenetic mechanism with which induces the formation of this tumor in the scar and light skin damaged is still not very clear: It is believed that the tissues surrounding

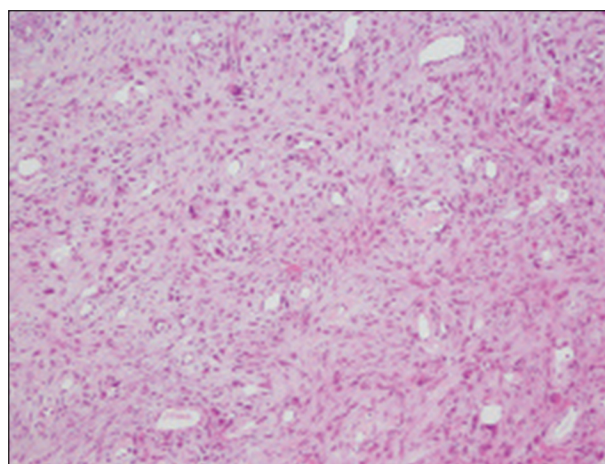


Figure 1: The tumor was composed of atypical cells arranged in a vaguely fascicular pattern diffusely infiltrating the subepithelial connective (H and E, ×20)

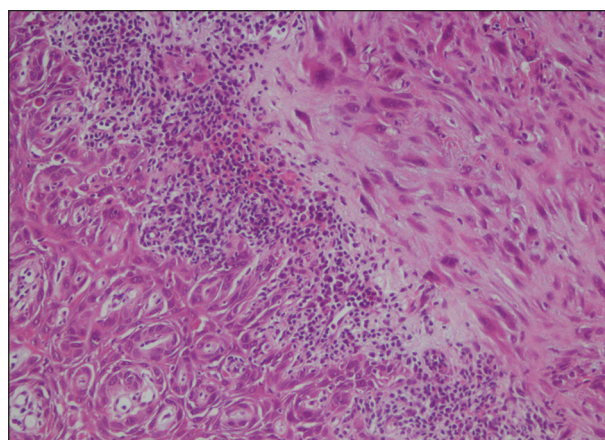


Figure 2: A residual “grenz zone” of uninvolved tissue characterized by a dense lymphocytic infiltrate was evident. Neoplastic cells exhibited marked pleomorphism with anaplastic and multinucleated giant cells. The mesenchymal proliferation was lined by an atypical squamous epithelium (H and E, ×40)

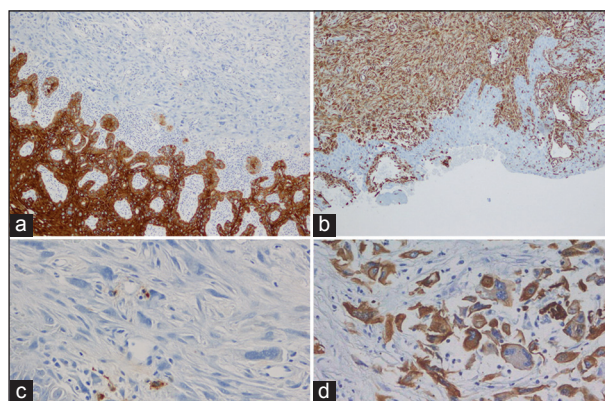


Figure 3: Immunohistochemical analysis that neoplastic cells were positive for vimentin (a) and CD10 (b), but negative for S100 protein (c), and CK (d) (immunoperoxidase)

the scar is more susceptible to carcinogens, such as ultraviolet (UV) radiation.^[2] Mutations of the p53 tumor-suppressor

gene are one of the major results of UV radiation. So, p53 mutation and UV photoproducts may play an important role in AFX development. However, the occurrence of AFX in a small subset of patients, in areas without evidence of actinic damage, suggests that there are other causative mechanisms.^[4,6] In all cases, AFX would develop from a common mesenchymal progenitor cell with the capacity to differentiate along multiple pathways. As previously described, usually the AFX showed a good prognosis and excision of tumor with wide negative margins is therapeutics.^[3,4] Conversely, an incomplete excision determines a local recurrence. Cases of MFH are generally underwent definitive treatment including re-excision if incompletely excised, and postoperative adjuvant radiotherapy. We present an unusual case of spindle cells tumor resembling at an AFX arising in non-sun-exposed sites. It is the first case of AFX in literature described in the genital area in a patient with no previous risk factor. A careful examination of excisional biopsy was made for to exclude most common malignant tumors. The superficial location of tumor, the result of immunohistochemistry and the favorable clinical behavior noted with a 36 month of follow-up, appear to confirm this diagnosis of AFX. This case is illustrative of the principle that AFX should be considered when suspected cutaneous

lesions are found, even in unusual anatomic site. Irritation and inflammation associated with long-term catheter use may be the cause for this lesion.

REFERENCES

1. Helwig EB. Atypical fibroxanthoma. Proceedings of 18th Annual Tumor Seminar of San Antonio Society of Pathologists, 1961. *Tex State J Med*. 1963; 59: 664-667.
2. Fretzin DF, Helwig EB. Atypical fibroxanthoma of the skin. A clinicopathologic study of 140 cases. *Cancer* 1973;31:1541-52.
3. Hartel PH, Jackson J, Ducatman BS, Zhang P. CD99 immunoreactivity in atypical fibroxanthoma and pleomorphic malignant fibrous histiocytoma: A useful diagnostic marker. *J Cutan Pathol* 2006;33 Suppl 2:24-8.
4. Sakamoto A, Oda Y, Itakura E, Oshiro Y, Nikaido O, Iwamoto Y, et al. Immunoexpression of ultraviolet photoproducts and p53 mutation analysis in atypical fibroxanthoma and superficial malignant fibrous histiocytoma. *Mod Pathol* 2001;14:581-8.
5. Tchernev G1, Tronnier M, Ananiev J, Taneva T, Patterson JW, Gulubova M, et al. Atypical fibroxanthoma: A diagnosis of exclusion!. *Wien Med Wochenschr* 2013;163:380-6.
6. Leong AS, Milios J. Atypical fibroxanthoma of the skin: A clinicopathological and immunohistochemical study and a discussion of its histogenesis. *Histopathology* 1987;11:463-75.

How to cite this article: Cuomo R, Adesso M, Altieri R, D'Antonio A. A bone fide atypical fibroxanthoma of penis. *Urol Ann* 2014;6:381-3.

Source of Support: Nil, **Conflict of Interest:** None.