



Intestinal Ganglioneuromatosis in a Pediatric Patient Presenting as Perforation: A Case Report and Literature Review

천공으로 발현된 소아 환자에서의 장 신경절신경종증: 증례 보고와 문헌 고찰

Nim Lee, MD¹ , Hyun-Hae Cho, MD^{1*} , Min-Sun Cho, MD²

¹Departments of Radiology, Medical Research Institute, College of Medicine, Ewha Womans University Mokdong Hospital, Seoul, Korea

²Departments of Pathology, Medical Research Institute, College of Medicine, Ewha Womans University Seoul Hospital, Seoul, Korea

Intestinal ganglioneuromatosis is an extremely rare condition, particularly in pediatric patients, and the imaging features of the disease have been rarely reported before. Herein, we present a pediatric case of intestinal ganglioneuromatosis involving the transverse colon and splenic flexure with bowel perforation, which is a rare initial manifestation of the disease.

Index terms Radiology; Pathology; Intestine; Child

INTRODUCTION

Intestinal ganglioneuromatosis is a rare benign tumorous condition. This disease can present with nonspecific, variable symptoms that depend on the location and extent of the lesion. Among the three subgroups of this tumor, the generalized type can present as a stricture of the involved bowel loop with upstream dilatation, which can cause megacolon. These findings mimic several diseases, including Crohn's and Hirschsprung's diseases, and it is therefore difficult to diagnose this condition using imaging methods. Herein, we report a case of pathologically proven intestinal ganglioneuromatosis in a pediatric patient who presented with bowel perforation, a rare initial manifestation of the disease, and provide a review of the relevant literature.

Received March 27, 2021

Revised May 29, 2021

Accepted July 17, 2021

*Corresponding author

Hyun-Hae Cho, MD
 Department of Radiology,
 Medical Research Institute,
 College of Medicine,
 Ewha Womans University
 Mokdong Hospital,
 1071 Anyangcheon-ro,
 Yangcheon-gu, Seoul 07985,
 Korea.

Tel 82-2-2650-5173

Fax 82-2-2650-5312

E-mail pedradchh@ewha.ac.kr

This is an Open Access article distributed under the terms of the Creative Commons Attribution Non-Commercial License (<https://creativecommons.org/licenses/by-nc/4.0>) which permits unrestricted non-commercial use, distribution, and reproduction in any medium, provided the original work is properly cited.

ORCID iDs

Nim Lee

[https://](https://orcid.org/0000-0002-5781-1424)

orcid.org/0000-0002-5781-1424

Hyun-Hae Cho

[https://](https://orcid.org/0000-0002-4865-2601)

orcid.org/0000-0002-4865-2601

Min-Sun Cho

[https://](https://orcid.org/0000-0001-8772-9686)

orcid.org/0000-0001-8772-9686

CASE REPORT

A 15-year-old boy with no relevant clinical history visited the emergency center of our institution with a complaint of uncontrolled high body temperature (39.1°C) from 1 day. He experienced abdominal pain with nausea and vomiting when he arrived at the emergency center.

The patient had fever (38.1°C) with an increased pulse rate (pulse rate, 120 beats/min). His blood pressure was slightly decreased (blood pressure, 110/60 mm Hg), but his respiratory rate was within the normal range (respiratory rate, 18 breaths/min). He showed an alert mental status, and therefore did not meet the criteria for septic shock on initial physical examination.

The patient's leukocyte count was $15.72 \times 10^3/\mu\text{L}$ (distribution of lymphocytes, 7.6%; neutrophils, 86.5%), which was higher than the normal range, but his hemoglobin level and platelet counts were within the normal ranges. The patient's serum electrolytes, liver function test results, and routine urinalysis were also within normal limits. C-reactive protein level showed marked elevation (22.52 mg/dL) with prolonged prothrombin time (16.3 seconds and 1.42 international normalized ratio). These laboratory findings indicated the possibility of bacterial infection.

Plain abdominal radiography showed mild ileus, and plain chest radiography did not show any abnormal consolidation or effusion. Abdominal CT was performed to evaluate progressive abdominal pain and vomiting with a high body temperature. Here, we noted pneumoperitoneum along the perihepatic area with localized fat infiltration, suggestive of peritonitis in the left upper quadrant of the abdomen, adjacent to the splenic flexure of the colon. Diffuse wall thickening with pericolic inflammatory changes was noted at the distal transverse colon and splenic flexure of the colon (Fig. 1A, B), and tiny scattered mesenteric free air bubbles were also observed. We further observed a focal bowel wall defect and bowel wall lesion with an outpouching-appearance at the splenic flexure of the colon (Fig. 1B).

After CT examination, the patient's symptoms worsened with an increased respiratory rate and decreased blood pressure, indicating septic shock (blood pressure, 100/50 mm Hg; respiratory rate, 27 breaths/min). Laparoscopic exploration was performed for an accurate diagnosis and management of the patient's septic condition. During the operation, dirty ascites with fecal material were noted. Bowel adhesions were noted in the splenic flexure of the colon with a sealed perforation. After initial exploration, the patient's symptoms were not controlled, and follow-up abdominal CT scan revealed progression of bowel thickening and peritoneal inflammation in the left upper quadrant of the abdomen (Fig. 1C). The previously noted outpouching-appearance at the splenic flexure of the colon showed interval improvement (Fig. 1D).

Histologic confirmation was performed for the resected bowel loop, and multiple nodular transmural ganglioneuromatous proliferations (Fig. 1E) involving the submucosa, proper muscle, and serosa were noted along with myenteric plexus and submucosal neural hyperplasia, consistent with the findings of intestinal ganglioneuromatosis (Fig. 1E). Inflammatory changes with perforation were also observed in the patient.

This study was approved by the Institutional Review Board of Ewha Womans University Mokdong Hospital and the requirement for informed consent was waived (IRB No. 2021-02-041).

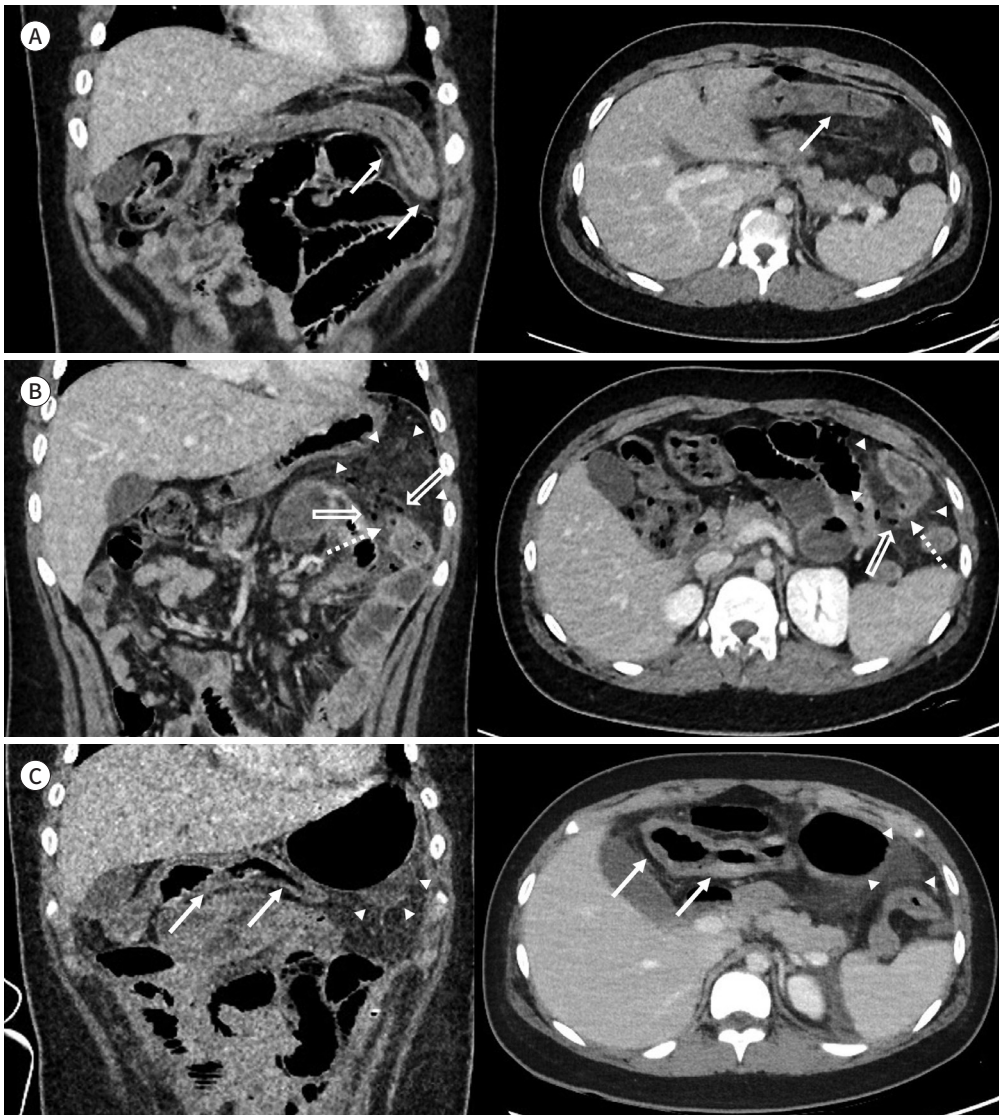
Fig. 1. A 15-year-old boy patient with bowel perforation, confirmed diagnosis of ganglioneuromatosis post-operatively.

A. Initial contrast-enhanced axial and coronal CT images were acquired at the emergency center for evaluating the abdominal pain and fever of the patient. Bowel wall thickening with the mucosal enhancement of the mid transverse to the splenic flexure of the colon is noted (arrows).

B. An outpouching appearance at the splenic flexure of the colon (dotted arrows) is noted. Peritonitis (arrowheads) with pneumoperitoneum in the LUQ area (empty arrows) adjacent to the thickened splenic flexure of the colon is also seen.

C. After exploratory laparoscopy, the patient's abdominal pain progressed, and a follow-up CT evaluation was done. Progressed bowel wall thickening (arrows) and peritonitis with fluid collection (arrowheads) is noted at the LUQ area.

LUQ = left upper quadrant



DISCUSSION

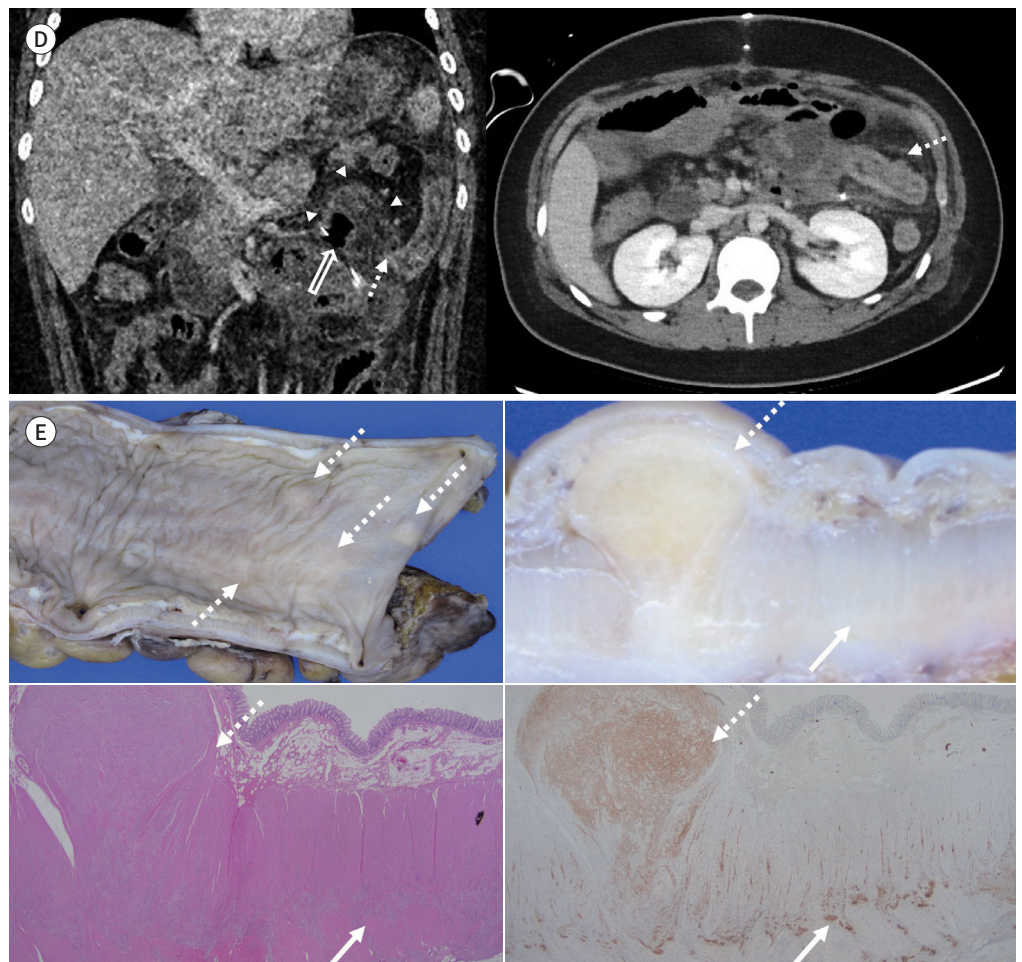
Intestinal ganglioneuromatosis is a rare, benign tumor, that is generally divided into three pathologic subgroups: polypoid (isolated type), generalized, and polyposis without known

Fig. 1. A 15-year-old boy patient with bowel perforation, confirmed diagnosis of ganglioneuromatosis post-operatively.

D. On a follow-up study, the previously noted outpouching appearance at the splenic flexure of the colon shows interval improvement (dotted arrows). Peritonitis (arrowheads) with pneumoperitoneum in the LUQ area (empty arrow) is also noted.

E. A left hemicolectomy was performed, and the splenic flexure of the colon was resected. Photograph of the gross specimen (upper left panel) demonstrates small nodular thickening (dotted arrows) of bowel loop suggest multiple nodular transmural ganglioneuromatous proliferations. The same nodular proliferations of submucosa (dotted arrow) with hypertrophied muscularis propria (arrow) is noted on the slice section of the specimen (upper right panel). Microscopic findings show nodular proliferation of neural and ganglion cells in the submucosa (dotted arrow) and hypertrophied muscularis propria (arrow) (lower left panel, hematoxylin & eosin stain, $\times 10$). And those nodular proliferation of neural and ganglion cells in the submucosa (dotted arrow) and hypertrophied muscularis propria (arrow) demonstrating diffuse positivity for S100 (lower right panel, S100 stain, $\times 10$).

LUQ = left upper quadrant



systemic disease (1, 2). The patient in this case report did not show definite discrete polyps but did exhibit poorly demarcated transmural lesions involving the myenteric plexus; therefore, this case was diagnosed as the diffuse, generalized type (1). The generalized type has two variants, either mucosal or transmural, according to the involvement of the myenteric plexus layer; combined mucosal and transmural variants are sometimes seen in pediatric patients (3, 4). The present patient showed a transmural variant, which can be associated with multiple

endocrine neoplasia type IIb (MEN IIb), and less commonly, with neurofibromatosis type 1 (NF type 1) (1, 4-6).

Intestinal ganglioneuromatosis can present with variable symptoms that depend on the location and extent of the lesion, and can furthermore have different effects on intestinal motility (2, 4). The most frequent symptoms are variable-degree abdominal pain and occlusive episodes due to stricture formation, but some patients may remain asymptomatic (4, 7). Most reported cases of ganglioneuromatosis occur within the large intestine, including the rectum, as in the present case, which involved the splenic flexure of the colon (1, 4, 6, 8, 9). Other rare complications, such as ulcers of the intestinal mucosa, intestinal hemorrhage, and obstructive jaundice, have also been reported (4).

In some cases, involvement of the myenteric plexus in this disease causes severe stricture, resulting in upstream dilatation, which can mimic megacolon (2, 4, 10). The stricture of bowel loops in this disease can be clinically misdiagnosed as other more common diseases, such as Crohn's or Hirschsprung's disease, and other rare diseases, such as cytomegalovirus infection, intestinal tuberculosis, intestinal tumors (gastrointestinal stromal tumor, lymphoma, adenocarcinoma), chronic ischemia, non-steroidal anti-inflammatory drug (NSAID) enteropathy, and amyloidosis (2, 4, 9).

This similarity in findings can lead to confusion in the imaging diagnosis of this disease, and only a small number of previous studies have reported the imaging features of this disease. In some previous reports, nonspecific circumferential intestinal wall thickening and lumen dilatation or stricture were commonly noted on CT of this disease (1-4, 9, 10). In one previous case, a comb sign was noted, which is commonly seen in Crohn's disease (4, 9). Other radiologic studies did not report specific findings for this disease. Ultrasonographic findings of this disease can also reveal bowel wall thickening with or without stricture or bowel dilatation (5).

In the present case, pneumoperitoneum with diffuse bowel wall thickening and pericolic inflammatory change without definite dilatation or stricture were noted. Therefore, the initial imaging diagnosis was diverticular perforation, which was noted as an outpouching structure with inflammatory changes of the involved bowel loop and pericolic region. To the best of our knowledge, the initial manifestation of intestinal ganglioneuromatosis as perforation has not yet been reported. Changes related to perforation in the present patient could have obscured the underlying bowel lesions. Perforation in the present patient may have been due to ulceration, considering the pathologic findings after the operation.

Endoscopy or colonoscopy is often inconclusive for intestinal ganglioneuromatosis, even in the majority of colon lesions (1, 3, 8), and full-thickness biopsy or surgical specimens are required for pathological diagnosis (3). Immunohistochemical markers of neural differentiation can be used for proper diagnosis, as in the present patient's specimen, which showed diffuse staining of the S100 protein within the Schwannian component (3, 5).

Diffuse intestinal ganglioneuromatosis generally fails to respond to conservative treatment, and surgical resection may be required in severe cases (1). Further management of other symptoms and complications is required. In addition, diagnosis of genetic disorders that may accompany them is necessary. Transmural type diffuse ganglioneuromatosis, which are similar to that seen in the present patient, can herald MEN IIb in infancy; however, fur-

ther genetic, biochemical, and ancillary testing is needed (3). Our patient also underwent an evaluation for thyroid and adrenal masses and did not show any other systemic condition suggestive of other syndromic conditions.

In summary, we report a case of diffuse intestinal ganglioneuromatosis with perforation as the first manifestation of the disease. As this is a very rare disease without any diagnosed syndromic condition, its diagnosis may be challenging, especially in cases with rare initial presentation, such as in the present case. Awareness of the different disease manifestations and accompanying genetic conditions is needed for proper diagnosis and management.

Author Contributions

Conceptualization, C.H.; data curation, C.H., L.N.; formal analysis, C.H., C.M.; investigation, C.H., L.N.; methodology, all authors; project administration, C.H.; resources, C.H., C.M.; software, C.H.; supervision, C.H., C.M.; validation, C.H.; visualization, all authors; writing—original draft, L.N.; and writing—review & editing, C.H.

Conflicts of Interest

The authors have no potential conflicts of interest to disclose.

Funding

None

REFERENCES

1. Iwamuro M, Omote R, Tanaka T, Sunada N, Nada T, Kondo Y, et al. Diffuse intestinal ganglioneuromatosis showing multiple large bowel ulcers in a patient with neurofibromatosis type 1. *Intern Med* 2017;56:3287-3291
2. Vinitzky A, Zaleski CA, Sajjad SM, McPherson EW. Intestinal ganglioneuromatosis: unusual presentation of Cowden syndrome resulting in delayed diagnosis. *Am J Med Genet A* 2013;161A:1085-1090
3. Mitra S, Mukherjee S, Chakraborty H. Isolated ileal ganglioneuromatosis in an 11-year-old boy: case report and review of literature. *Indian J Pathol Microbiol* 2016;59:365-367
4. Fernandes A, Ferreira AM, Serra P, Carvalho L. Intestinal ganglioneuromatosis: an unusual aetiology for occult gastrointestinal bleeding. *BMJ Case Rep* 2015;2015:bcr2015211764
5. AHmad Z, Khan R, Barakzai A, Ahmed A, Qureshi A. Diffuse ganglioneuromatosis of intestine in a 15-year-old girl. *BMJ Case Rep* 2011;2011:bcr04201114151
6. Thway K, Fisher C. Diffuse ganglioneuromatosis in small intestine associated with neurofibromatosis type 1. *Ann Diagn Pathol* 2009;13:50-54
7. Kilincalp S, Hamamcı M, Akinci H, Çoban Ş, Köksal AŞ, Yüksel İ. Double-balloon enteroscopy for the detection of diffuse small-bowel polypoid ganglioneuromatosis mimicking Crohn's disease in a patient with von Recklinghausen disease. *Endoscopy* 2015;47 Suppl 1 UCTN:E4-E5
8. Kim TJ, Lim H, Kang HS, Moon SH, Kim JH, Park CK, et al. Diffuse ganglioneuromatosis of the colon presenting as a large subepithelial tumor in adults: report of two cases. *Korean J Gastroenterol* 2015;66:111-115
9. Charagundla SR, Levine MS, Torigian DA, Campbell MS, Furth EE, Rombeau J. Diffuse intestinal ganglioneuromatosis mimicking Crohn's disease. *AJR Am J Roentgenol* 2004;182:1166-1168
10. Matthews MA, Adler BH, Arnold MA, Kumar S, Carvalho R, Besner GE. Diffuse intestinal ganglioneuromatosis in a child. *J Pediatr Surg* 2013;48:1129-1133

천공으로 발현된 소아 환자에서의 장 신경절신경종증: 증례 보고와 문헌 고찰

이 님¹ · 조현혜^{1*} · 조민선²

장 신경절신경종증은 특히 소아 환자에서 매우 드물며 특히 질병의 영상의학적 소견에 대한 보고가 부족하다. 이에 저자들은 이 질환의 드문 초기 증상인 장 천공을 동반한 횡행 및 비장 굴곡의 결장을 포함하는 장 신경절신경종증의 소아 사례를 제시한다.

¹이화여자대학교 의과대학 이화여자대학교 목동병원 영상의학과,

²이화여자대학교 의과대학 이화여자대학교 서울병원 병리학과