

Efficacy of Femtosecond Laser-Assisted Capsulotomy: Experimental Evaluation Using the Zonular Dehiscence Model

Saori Yaguchi¹, Hiroko Bissen-Miyajima¹, Yuka Ota¹, Shinichi Oki¹, and Keiichiro Minami¹

¹ Department of Ophthalmology, Tokyo Dental College Suidobashi Hospital, Tokyo, Japan

Correspondence: Saori Yaguchi, Department of Ophthalmology, Tokyo Dental College Suidobashi Hospital, 2-9-18 Kandamisaki-cho, Chiyoda-ku, Tokyo, Japan. e-mail: sao213sao213@gmail.com

Received: August 12, 2020

Accepted: October 22, 2020

Published: December 4, 2020

Keywords: femtosecond laser-assisted cataract surgery; capsulotomy; zonular dehiscence; porcine eye model

Citation: Yaguchi S, Bissen-Miyajima H, Ota Y, Oki S, Minami K. Efficacy of femtosecond laser-assisted capsulotomy: Experimental evaluation using the zonular dehiscence model. *Trans Vis Sci Tech.* 2020;9(13):7, <https://doi.org/10.1167/tvst.9.13.7>

Purpose: The purpose of this study was to evaluate experimentally the efficacy of femtosecond laser (FL)-assisted capsulotomy using an eye model with different degrees of zonular dehiscence (ZD).

Methods: An eye model with ZD was created by removing the total iris and including the planned range of the ZD in porcine and human cadaver eyes. FL-assisted capsulotomies (laser group) and manual capsulotomies (manual group) were created for the eye model with 0, 45, 135, 180, and 270 degrees of ZD. The continuity, mean diameter, ellipticity, and decentration of the capsulotomy were evaluated using the captured images. The same evaluation of FL-assisted capsulotomies was done for five human cadaver eyes with 180 degrees of ZD.

Results: In the laser group, no differences were seen in the mean diameter, ellipticity, and decentration, although the manual group resulted in significantly larger, ovalized, and decentered capsulotomies with different degrees of ZD ($P < 0.001$, $P < 0.001$, and $P = 0.0317$, respectively). Continuous capsulotomies or capsulotomies with microadhesions were obtained up to 180 degrees of ZD, and incomplete treatment areas were seen in eyes with 270 degrees of ZD. Capsulotomy of the human cadaver eyes with 180 degrees of ZD showed similar results to those of porcine eyes.

Conclusions: In this experimental study, FL-assisted capsulotomy showed favorable results in eyes with between 0 and 180 degrees of ZD compared to conventional manual capsulotomy.

Translational Relevance: Our experimental model can simulate the capsulotomy in cases with ZD, the results are useful when determining the indication for FL-assisted capsulotomies.

Introduction

Different levels of zonular dehiscence (ZD) are encountered during cataract surgeries, and the quality of the capsulotomy as the first step of the procedure affects the subsequent procedures and final surgical outcomes. A major advantage of femtosecond laser (FL)-assisted cataract surgery is the capsulotomy,¹⁻³ and this becomes obvious in the presence of ZD. Clinical reports about using FL-assisted capsulotomy in Marfan syndrome have reported less traction or manipulation of the anterior capsule,⁴ and a retrospective

study of subluxated cataracts with ZD of more than 6 clock hours reported a high rate of capsular preservation.⁵ In these clinical cases, the benefit of FL-assisted capsulotomy was explained; however, the effect of the range of ZD on the quality of the capsulotomy has not been evaluated precisely, because the zonular area is covered by the iris, especially in a case with poor pupillary dilation. Further, a quantitative evaluation of the capsulotomy intraoperatively might disrupt the natural flow of the procedure. Thus, we considered that an experimental approach would be beneficial.

We created a unique porcine eye model of ZD to observe the lens capsule and the crystalline lens during

phacoemulsification^{6,7} and adapted this eye model for the current study. Our primary and secondary objectives, respectively, were to observe the relationship between the quality of the capsulotomy and the range of ZD in porcine eyes and confirm the effectiveness of FL-assisted capsulotomy in human cadaver eyes with ZD.

Methods

This is an experimental study as a laboratory investigation. The institutional review board (IRB) waived the need for IRB approval because no patients or living animals were involved.

The eye model of ZD was first created under the operating microscope using the technique that we previously reported in both porcine and human eyes.^{6,7} The anterior chamber was filled with an ophthalmic viscosurgical device (OVD; Provisc; Alcon Vision, LLC, Fort Worth, TX); the entire iris root and the planned range of the ZD were dissected using capsule diathermy (CD-1000, Tagawa Electronic Research Institute, Chiba, Japan).

Freshly extracted porcine eyes were used mainly to observe creation of the capsulotomies with different levels of ZD. Human cadaver eyes from a US eye bank (SightLife, Seattle, WA) were imported for this purpose, because the experimental use of cadaver eyes in Japan is not permitted.

Porcine Eyes: Capsulotomy Creation and Evaluation

One hundred freshly extracted porcine eyes were divided into two groups depending on the techniques of capsulotomy (i.e. the FL [laser group] and manual [manual group] groups, and in each group of 10 eyes), the eyes were classified based on the range of ZD (0, 45, 135, 180, and 270 degrees).

In the laser group, the eyes were prepared with the goal of maintaining the ocular shape during optical coherence tomography (OCT) and laser application. The OVD in the anterior chamber was replaced with balanced saline solution using a bimanual irrigating and aspirating handpiece, and 10-0 nylon sutures and the biologic cyanoacrylate adhesive glue (DERMABOND; Ethicon, Bridgewater, NJ) was applied to prevent leakage from the incisions. The porcine eye was docked to the SoftFit Patient Interface (Alcon Vision, LLC). LenSx version 2.23 (Alcon Vision, LLC) was used for the capsulotomy. The laser settings of the wet laboratory for porcine eyes were

used (i.e. scanning a cylindrical pattern using 8.0 μ J of energy, 5.0 μ m of spot separation, 4.0 μ m of layer separation, and 350- μ m anterior and posterior delta values). The capsulotomies were designed to have a 5.70-mm diameter with its center maintained in the center of the capsular bag.

In the manual group, a capsulotomy was created under the operating microscope. A stained capsulotomy marker (Hata double-ended continuous curvilinear capsulotomy marker; ASICO, Westmont, IL; diameter, 5.75 mm) was placed on the cornea and its center maintained in the center of the capsule. One surgeon (S.Y.) performed the procedures. A continuous curvilinear capsulotomy was started away from the area of ZD using a 27-gauge needle to achieve better control and completed with capsule forceps.

The continuity was observed under the operating microscope. In the laser group, the continuity was classified into four types as reported by Nagy et al.: complete, presence of microadhesions, incomplete, and irregular discontinuous.⁸

The diameter, ellipticity, and decentration were evaluated after the capsulotomy specimen was removed using capsule forceps. Any microadhesions were detached easily by counter force with capsule forceps. In cases of incomplete cuts, they were completed with the curvilinear movement of the capsule forceps. Eyes with over 60 degrees of incomplete areas were excluded from these evaluations.⁹ Images of capsulotomies were captured from the recorded videos and analyzed using ImageJ version 1.52 software (National Institutes of Health, Bethesda, MD). The size in each image was calibrated from the simultaneously recorded 5.00 mm scale by the caliper. The capsulotomy shape resembled an oval, and the mean diameter was calculated from the longest and shortest diameters of the capsulotomy. The ellipticity was defined as $1 - (\text{shortest diameter}) / (\text{longest diameter})$, and the value was zero in cases of a perfect circle. The decentration was determined as the difference between the centers of the capsulotomy and the lens capsule (Fig. 1). The homogeneity and changes in the mean diameter, ellipticity, and decentration from those of eyes with 0 degrees of ZD in the laser and manual groups were examined. The laser and manual groups in each extent of ZD then were compared.

Human Cadaver Eyes: Capsulotomy Creation and Evaluation

Five human cadaver eyes were used to compare the similarity to the behavior of the porcine eyes. ZD of 180 degrees, which was the limitation of the complete FL-assisted capsulotomy in porcine eyes, was selected.

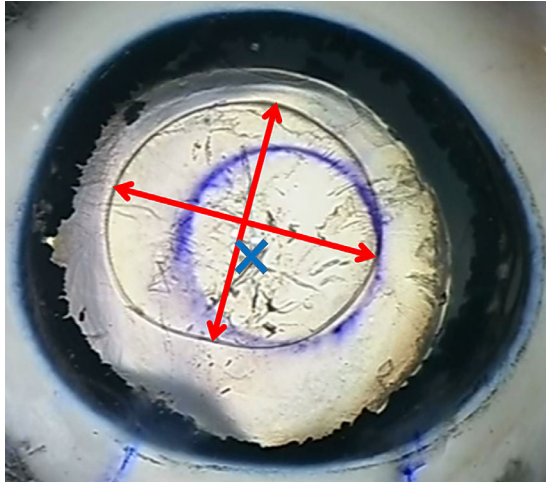


Figure 1. The longest and shortest diameters and decentration of a capsulotomy. After a capsulotomy specimen is removed, the longest and shortest diameters of the capsulotomy are measured (red arrows). The distance between the cross-section of the red arrows and center of the crystalline lens (blue cross) is evaluated as the decentration.

All eyes were immersed in Optisol-GS solution (Bausch & Lomb, Rochester, NY) and shipped to Japan via air mail. The mean duration from enucleation to the experiment was 5.2 days (range, 3–7 days). The corneal epithelium was scraped to allow better observation.

After the total iris was removed and 180 degrees of ZD with diathermy was created, OVD (Healon 5; Johnson & Johnson Surgical Vision, Santa Ana, CA) was injected into the anterior chamber. A 22-gauge needle attached to an artificial chamber pressurizer (ACP, Moria SA, Antony, France) was inserted from the equator into the vitreous cavity to maintain the pressure at 25 mm Hg.¹⁰

FL-assisted capsulotomy with a 5-mm diameter was created in the capsular center. The laser settings were as follows: energy = 10 μJ; spot separation = 5 μm; layer separation = 5 μm; and the anterior or posterior delta was increased to 1000 μm.

After laser treatment, the capsulotomy specimen was removed under the operating microscope, and the diameter, ellipticity, and decentration were evaluated in the same manner as for the porcine eyes.

Statistical Analysis

In the porcine eyes, statistical analyses were performed with GraphPad Prism version 5.00 (Graph-Pad Software, San Diego, CA) and R version 3.6.2. The variances and differences in the mean diameter, ellipticity, and decentration from those of eyes with 0 degrees of ZD in the laser and manual groups were examined using Levene’s test and the Kruskal-Wallis test or one-way analysis of variance followed by Steel’s multiple comparison. The laser and manual groups for each extent of ZD were compared using the *t*-test with the Holm multiple comparison. The results are expressed as the mean ± standard deviation (SD), unless otherwise specified. *P* < 0.05 was considered as statistically significant.

In the human eyes, because the diameter differed from that of the porcine eyes, variations and differences in the results between the mean diameter and laser setting, ellipticity, and decentration were compared with the results of the porcine eyes with ZD of 180 degrees using the F-test and *t*-test.

Results

Porcine Eyes

The continuity of the FL-assisted capsulotomy is shown in Table 1, and typical cases of each classification are shown in Figure 2. Complete continuity was achieved in 100% of the eyes with 0 and 45 degrees of ZD, 80% with 135 degrees of ZD, and 60% with 180 degrees of ZD. No eyes achieved complete continuity when the ZD extended to 270 degrees. In cases with microadhesions, the extent was 50 to 80 degrees with 135 degrees of ZD, 65 to 80 degrees with 180 degrees of ZD, and 40 to 200 degrees with 270 degrees of ZD. The microperforations in this area made it easy to complete the capsulotomy using capsule forceps.

The mean diameter, ellipticity, and decentration of the capsulotomy in the laser and manual groups are shown in Table 2. The mean diameter of the manual group was smaller than that of the laser group in eyes

Table 1. Continuity of FL-Assisted Capsulotomy in Porcine Eyes With Different Degrees of ZD

| Continuity | ZD Range | | | | |
|----------------------------|-----------|------------|-------------|-------------|-------------|
| | 0 Degrees | 45 Degrees | 135 Degrees | 180 Degrees | 270 Degrees |
| Complete | 10 | 10 | 8 | 6 | 0 |
| Presence of microadhesions | 0 | 0 | 2 | 4 | 4 |
| Incomplete | 0 | 0 | 0 | 0 | 6 |
| Irregular discontinuous | 0 | 0 | 0 | 0 | 0 |

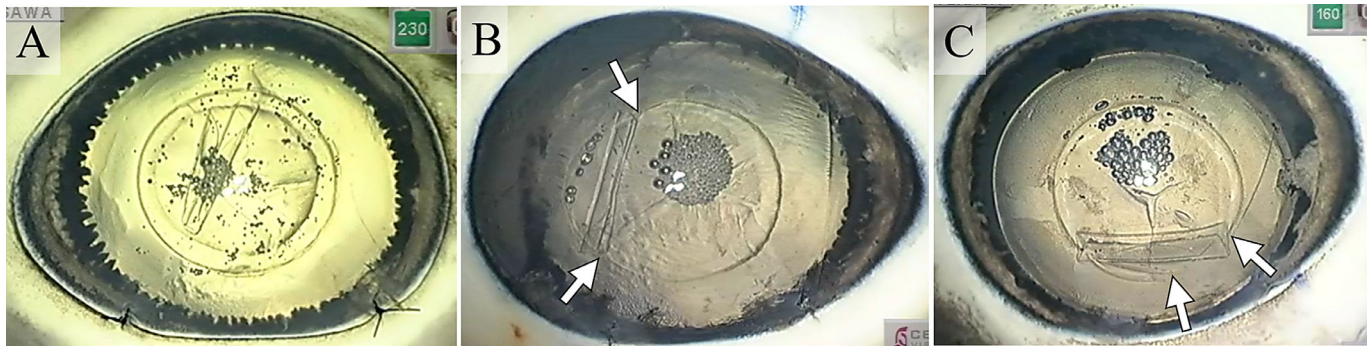


Figure 2. The continuity of the FL-assisted capsulotomy in porcine eyes. The captured image from a recorded video is used to classify the continuity of the FL-assisted capsulotomy. In each eye, the total lens and the range of the ZD can be seen without the iris. (A) A complete capsulotomy in an eye without ZD. (B) A case with microadhesions (between arrows) in an eye with 180 degrees of ZD. (C) A case of incomplete capsulotomy (between arrows) in an eye with 270 degrees of ZD.

Table 2. Mean Diameter, Ellipticity, and Decentration of Capsulotomy in Porcine Eyes With Different Degrees of ZD

| ZD Range | Diameter, mm | | | | | P Value ^{*,†} |
|----------------------|-------------------|--------------|--------------|--------------|--------------|------------------------|
| | 0 Degrees | 45 Degrees | 135 Degrees | 180 Degrees | 270 Degrees | |
| Laser group | 7.24 ± 0.24 | 7.49 ± 0.31 | 7.22 ± 0.20 | 7.33 ± 0.38 | 7.45 ± 0.31 | 0.18 |
| Manual group | 6.10 ± 0.52 | 6.16 ± 0.34 | 6.94 ± 0.46 | 7.24 ± 0.60 | 8.12 ± 0.97 | <0.001 |
| P value [‡] | 0.0005 | 0.0005 | 0.21 | 0.68 | 0.19 | |
| ZD Range | Ellipticity | | | | | P Value [†] |
| | 0 Degrees | 45 Degrees | 135 Degrees | 180 Degrees | 270 Degrees | |
| Laser group | 1.81 ± 1.05% | 1.02 ± 0.65% | 2.50 ± 1.91% | 1.97 ± 1.51% | 1.69 ± 0.83% | 0.23 |
| Manual group | 1.98 ± 1.88% | 3.47 ± 2.63% | 6.57 ± 2.70% | 9.05 ± 6.08% | 7.82 ± 2.85% | <0.001 |
| P value [‡] | 0.81 | 0.03 | 0.004 | 0.02 | <0.0005 | |
| ZD Range | Decentration (mm) | | | | | P Value [†] |
| | 0 Degrees | 45 Degrees | 135 Degrees | 180 Degrees | 270 Degrees | |
| Laser group | 0.24 ± 0.14 | 0.41 ± 0.10 | 0.35 ± 0.30 | 0.38 ± 0.19 | 0.36 ± 0.16 | 0.09 |
| Manual group | 0.39 ± 0.14 | 0.41 ± 0.24 | 0.45 ± 0.25 | 0.71 ± 0.18 | 0.57 ± 0.45 | 0.03 |
| P value [‡] | 0.12 | 0.97 | 0.87 | 0.004 | 0.60 | |

The data are expressed as the mean ± standard deviation.

*One-way analysis of variance.

†Kruskal-Wallis test.

‡The t-test with the Holm multiple comparison.

with 0 and 45 degrees of ZD; however, no significant differences were found in eyes with ZD of 135 degrees or more. No significant differences in ellipticity were seen between the two groups with 0 degrees of ZD; however, the capsulotomy shape in the manual group became more oval with increasing ZD. The amount of decentration was similar between the two groups. The only significant difference was found in eyes with 180 degrees of ZD.

Figure 3 shows the changes in the mean diameter, ellipticity, and decentration with different levels

of ZD in the laser and manual groups. In the laser group, the homogeneity of variance was retained in the diameter and decentration with all extents of ZD (mean diameter, $P = 0.46$; decentration, $P = 0.34$). No significant differences were found when 0 degrees of ZD were compared with 45, 135, 180, and 270 degrees of ZD (mean diameter, $P = 0.1762$; ellipticity, $P = 0.2255$; and decentration, $P = 0.0937$). In the manual group, the homogeneity of variance was not retained ($P < 0.02$); the capsulotomy became significantly larger, more ovalized, and decentered with increasing

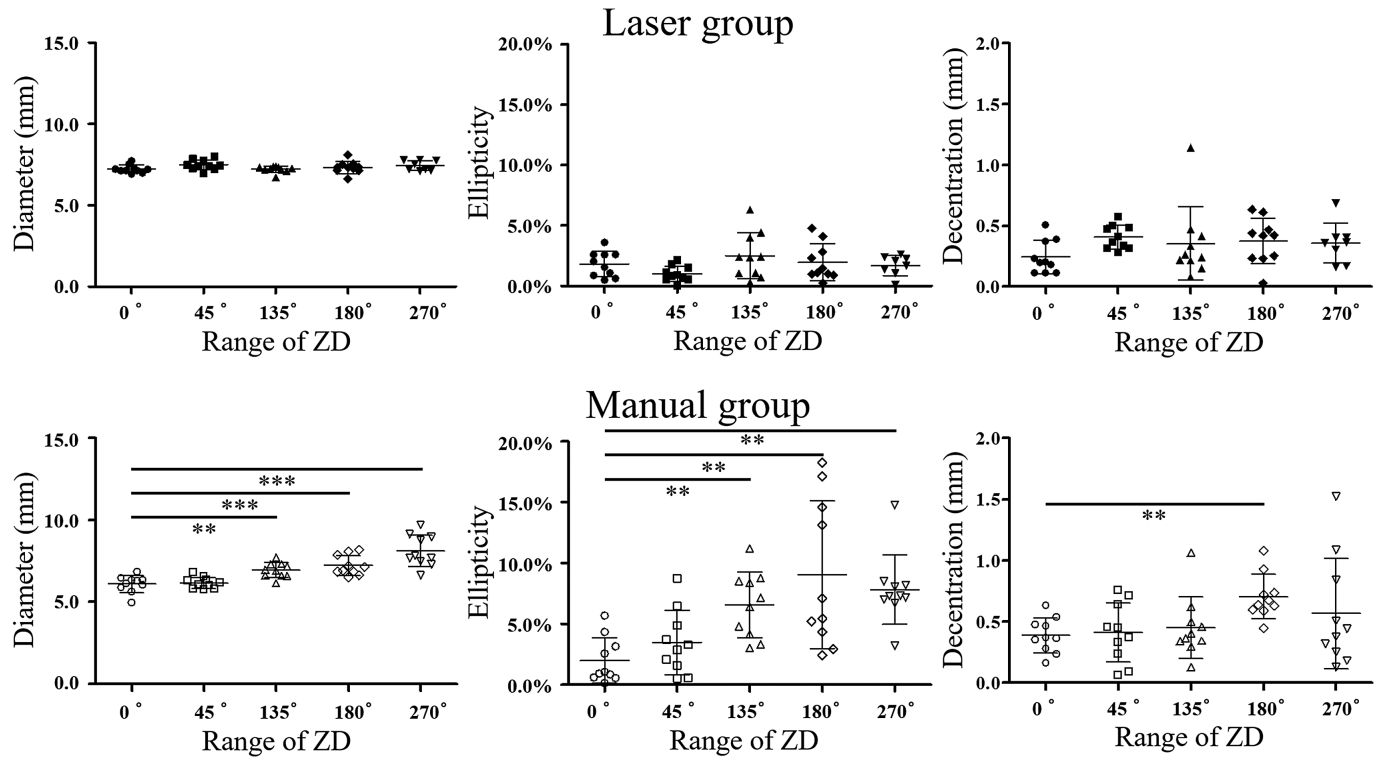


Figure 3. Changes in the mean diameter (left), ellipticity (center), and decentration (right) with increasing degrees of ZD in the laser (upper) and manual (lower) groups. ** $P < 0.001$; *** $P < 0.0001$ by Steel's multiple comparison.

ZD. The differences were significant when 0 degrees of ZD was compared with 45, 135, 180, and 270 degrees of ZD (mean diameter, $P < 0.001$; ellipticity, $P < 0.001$; and decentration, $P = 0.0317$).

Human Cadaver Eyes

The characteristics of the donor, diameter, ellipticity, and decentration are shown in Table 3. Compared to the same level of ZD in porcine eyes, the mean diameter was significantly smaller in the human eyes ($P < 0.0001$). No significant differences were found in ellipticity and decentration ($P = 0.5692$ and $P = 0.7537$, respectively).

Discussion

To the best of our knowledge, no studies have reported the relationships between the range of ZD and the quality of the capsulotomy clinically and experimentally. Our experimental eyes showed that FL-assisted capsulotomy was beneficial and maintained a good shape up to 180 degrees of ZD. Microadhesions occur as a result of the micromovements of the lens due to ZD^{5,8}; however, these areas were partially perfo-

rated and allowed easy completion with forceps. The quality of the capsulotomy remained superior to that of the manual procedure. The anterior and posterior delta of the laser settings were set at the same value for each level of ZD. The increased delta value should be considered when significant lens tilt is seen in the OCT images. No eyes with 270 degrees of ZD achieved complete continuity of the capsulotomy, and the lens tilt and movement that occurred at this wide extent of ZD seemed to limit the benefit of FL-assisted capsulotomy.

When the configurations of the FL-assisted and manual capsulotomies were compared, the diameters were larger than the settings in both the laser and manual groups. Novice surgeons frequently use porcine eyes to practice surgical techniques, and the immediate expansion of the capsulotomy opening is observed. The thick, elastic capsules of the porcine eyes seemed to play a role in the same manner as in early cases of ectopia.¹¹ In the laser group, no significant differences were seen in the diameters with different degrees of ZD, which is an advantage of laser treatment; however, the diameters enlarged when the range of ZD increased in the manual group. The counter forces of the zonulas failed in those cases, and controlling the size is difficult even for experienced surgeons. Regarding ellipticity, the capsulotomy became more oval in the manual

Table 3. Mean Diameter, Ellipticity, and Decentration of FL-Assisted Capsulotomy in Human Eyes With 180 Degrees of ZD

| | Age | Sex | Diameter, mm | Ellipticity | Decentration, mm |
|------|-----|--------|--------------|-------------|------------------|
| 1 | 38 | Male | 5.28 | 2.71% | 0.30 |
| 2 | 52 | Female | 5.15 | 0.85% | 0.38 |
| 3 | 68 | Male | 5.51 | 1.05% | 0.18 |
| 4 | 42 | Female | 5.54 | 2.62% | 0.50 |
| 5 | 42 | Female | 5.24 | 0.38% | 0.37 |
| Mean | | | 5.34 | 1.52% | 0.35 |

group, which also was the result of poor control. The degree of decentration was similar in both groups. The corneal marking and technique of manual capsulotomy (i.e. beginning away from the area of the ZD), seemed effective.

Other impressive outcomes were the homogeneity of the FL-assisted capsulotomy. FL can produce predictable and stable capsulotomy in the presence of ZD. Although the results with 270 degrees of ZD were comparable to those with lower degrees of ZD, it is noteworthy that two eyes with an incomplete area exceeding 60 degrees were excluded from these evaluations. As discussed regarding the continuity of the capsulotomy, the attempt to use FL-assisted capsulotomy in eyes with over 180 degrees of ZD should be considered carefully.

Finally, we conducted the study using human cadaver eyes to achieve our secondary objective of confirming the effectiveness of FL-assisted capsulotomy obtained from porcine eyes. The challenge with eyes imported from an eye bank is the corneal condition. Despite careful storage and shipment, some corneas did not meet the quality required for observation and laser treatment. Thus, we needed to minimize the number of eyes and used the eye model with ZD of 180 degrees because it had the largest degree of ZD to take the most advantage of FL-assisted capsulotomy. All five eyes achieved a preferable capsulotomy. Regarding the laser settings, we used the same spot and layer separations as in clinical cases. The energy was increased to enhance consistency in the ability to complete a capsulotomy in an edematous cornea.¹² Although the condition of the cornea is better in clinical cases, the higher energy is required when ZD exists.^{5,13} The risk of capsule rips and the subsequent capsular tear should be considered. The amounts of anterior and posterior delta were increased to overcome the lens movement and tilt under very loose zonula.^{13,14} In addition to the higher energy, the increased anterior and posterior delta will result in a longer duration and larger total energy of laser treatment. We believe these are the limitations of FL

capsulotomy in clinical cases with ZD. In previous studies of FL capsulotomy, the laser was applied to the extracted crystalline lens.^{3,15} Our model of the whole globe allowed the same manner of FL-assisted capsulotomy used in clinical cases. In our study, maintaining a stable intraocular pressure in extracted eyes was mandatory. After several trials, a pressurizer and OVD injected into the anterior chamber were used in human eyes. The differences in the refractive indexes between OVD and balanced saline solution had no effect on the FL-assisted capsulotomy.¹⁶

The current study had limitations. Both the extracted porcine and human eyes were postmortem eyes, and the zonulas and lens capsules may behave differently in clinical cases. In addition, zonular fibers decrease in number and are finer in eyes of elderly subjects.¹⁷

In conclusion, the porcine eye model with different levels of ZD showed that FL can create continuous capsulotomies up to 180 degrees of ZD as well as human eye models. The ZD model can simulate the capsulotomy in clinical cases with ZD. The experimental results of our study would be useful when creating FL-capsulotomies in clinical cases with ZD, especially in determining the indication for FL-assisted capsulotomies. Further investigation of clinical cases should confirm the benefit of FL-assisted capsulotomy in cases with ZD.

Acknowledgments

The authors thank Michiru Katayama for operation of the femtosecond laser.

Supported by Alcon Vision, LLC.

Disclosure: **S. Yaguchi**, Alcon Vision, LLC (F); **H. Bissen-Miyajima**, Alcon Vision, LLC (F, R); **Y. Ota**, Alcon Vision, LLC (F); **S. Oki**, None; **K. Minami**, Alcon Vision, LLC (F)

References

- Day AC, Gartry DS, Maurino V, Allan BD, Stevens JD. Efficacy of anterior capsulotomy creation in femtosecond laser-assisted cataract surgery. *J Cataract Refract Surg.* 2014;40:2031–2034.
- Zhu Y, Chen X, Chen P, et al. Lens capsule-related complications of femtosecond laser-assisted capsulotomy versus manual capsulorhexis for white cataracts. *J Cataract Refract Surg.* 2019;45:337–342.
- Friedman NJ, Palanker DV, Schuele G, et al. Femtosecond laser capsulotomy. *J Cataract Refract Surg.* 2011;37:1189–1198.
- Dryjski O, Awidi A, Daoud YJ. Femtosecond laser-assisted cataract surgery in patients with zonular weakness. *Am J Ophthalmol Case Reports.* 2019;15:100483.
- Chee SP, Wong MH, Jap A. Management of severely subluxated cataracts using femtosecond laser-assisted cataract surgery. *Am J Ophthalmol.* 2017;173:7–15.
- Yaguchi Y, Yaguchi S, Yaguchi S, Kozawa T, Tanaka Y, Negishi K. Objective evaluation of zonular weakness: measurement of lens movement at the start of capsulorhexis using extracted porcine eyes. *J Clin Exp Ophthalmol.* 2016;7:541.
- Yaguchi S, Yaguchi S, Bissen-Miyajima H. Evaluation of lens capsule stability using capsular tension ring, iris retractor, and capsule expander using a porcine model with zonular dehiscence. *Invest Ophthalmol Vis Sci.* 2019;60:3507–3513.
- Nagy ZZ, Takacs AI, Filkorn T, et al. Complications of femtosecond laser-assisted cataract surgery. *J Cataract Refract Surg.* 2014;40:20–28.
- Titlyal JS, Kaur M, Singh A, Arora T, Sharma N. Comparative evaluation of femtosecond laser-assisted cataract surgery and conventional phacoemulsification in white cataract. *Clin Ophthalmol.* 2016;10:1357–1364.
- Nishisako S, Aoki D, Sasaki C, Higa K, Shimazaki J. Comparison of artificial anterior chamber internal pressures and cutting systems for descemet's stripping automated endothelial keratoplasty. *Transl Vis Sci Technol.* 2018;7:11.
- Malyugin B, Anisimova N, Antonova O, Arbisser LB. Simultaneous pupil expansion and displacement for femtosecond laser-assisted cataract surgery in patients with lens ectopia. *J Cataract Refract Surg.* 2018;44:262–265.
- Williams GP, George BL, Wong YR, et al. Performing reliable lens capsulotomy in the presence of corneal edema with a femtosecond laser. *Invest Ophthalmol Vis Sci.* 2017;58:4490–4498.
- Grewal DS, Basti S, Singh Grewal SP. Femtosecond laser-assisted cataract surgery in a subluxated traumatic cataract. *J Cataract Refract Surg.* 2014;40:1239–1240.
- Schultz T, Ezeanosike E, Dick HB. Femtosecond laser-assisted cataract surgery in pediatric Marfan syndrome. *J Refract Surg.* 2013;29:650–652.
- Palanker DV, Blumenkranz MS, Andersen D, et al. Femtosecond laser-assisted cataract surgery with integrated optical coherence tomography. *Sci Transl Med.* 2010;2:58ra85.
- de Freitas CP, Cabot F, Manns F, Culbertson W, Yoo SH, Parel JM. Calculation of ocular viscoelastic device-induced focus shift during femtosecond laser-assisted cataract surgery. *Invest Ophthalmol Vis Sci.* 2015;56:1222–1227.
- Assia EI, Apple DJ, Morgan RC, Legler UF, Brown SJ. The relationship between the stretching capability of the anterior capsule and zonules. *Invest Ophthalmol Vis Sci.* 1991;32:2835–2839.