



Since January 2020 Elsevier has created a COVID-19 resource centre with free information in English and Mandarin on the novel coronavirus COVID-19. The COVID-19 resource centre is hosted on Elsevier Connect, the company's public news and information website.

Elsevier hereby grants permission to make all its COVID-19-related research that is available on the COVID-19 resource centre - including this research content - immediately available in PubMed Central and other publicly funded repositories, such as the WHO COVID database with rights for unrestricted research re-use and analyses in any form or by any means with acknowledgement of the original source. These permissions are granted for free by Elsevier for as long as the COVID-19 resource centre remains active.



Case Report

Optic neuritis concomitant with pituitary macroadenoma in a patient with active COVID-19 infection: A case report

Mohammed Maan Al-Salihi ^a, Md Moshir Rahman ^{b,*}, Maryam Sabah Al-Jebur ^a, Sabrina Rahman ^c, Ivan David Lozada-Martinez ^d, Raphia Rahman ^e, Luis Rafael Moscote-Salazar ^f

^a Medical Doctor College of Medicine, University of Baghdad, Baghdad, Iraq

^b Department of Neurosurgery, Holy Family Red Crescent Medical College, Dhaka, Bangladesh

^c Department of Public Health, Independent University-Bangladesh, Dhaka, Bangladesh

^d Medical and Surgical Research Center, School of Medicine, University of Cartagena, Cartagena, Colombia

^e Rowan School of Osteopathic Medicine, Stratford, NJ, USA

^f Center for Biomedical Research (CIB), Faculty of Medicine, University of Cartagena, Cartagena, Colombia

ARTICLE INFO

Article history:

Received 8 May 2021

Received in revised form

6 August 2021

Accepted 7 August 2021

Available online 25 August 2021

Keywords:

COVID-19

Optic neuritis

Pituitary macroadenoma

ABSTRACT

Introduction and importance: Several neuro-ophthalmic manifestations have been reported with coronavirus disease 2019 (COVID-19) infection. However, isolated optic neuritis was infrequently reported in humans with COVID-19. If it occurred, optic neuritis was usually a part of a demyelinating syndrome.

Case presentation: In this paper, we report a case of optic neuritis concomitant with an undiagnosed pituitary macroadenoma discovered during active COVID-19 infection. The case was a 33-year-old woman with infertility who was recently found to have a pituitary macroadenoma secreting prolactin. During active COVID-19 infection, the patient developed optic neuritis that responded well to corticosteroids. Brain imaging and hormonal profile negated the presence of any demyelinating disease or pituitary apoplexy.

Clinical discussion: A dilemma of whether optic neuritis occurring concomitantly with pituitary macroadenoma is just a coincidence, or there is an association remains unresolved. Whether COVID-19 infection might precipitate optic neuritis in patients with pituitary macroadenoma or not remains an issue to be answered by observing data from future case reports about similar findings.

Conclusion: Optic neuritis in concomitant with pituitary macroadenoma following COVID-19 infection represents a dilemma of whether the visual symptoms are attributed to the tumor or COVID-19 infection.

© 2021 The Author(s). Published by Elsevier Ltd on behalf of Surgical Associates Ltd. This is an open access article under the CC BY-NC-ND license (<http://creativecommons.org/licenses/by-nc-nd/4.0/>).

1. Introduction

Several neurological and ophthalmic manifestations have been reported with coronavirus disease 2019 (COVID-19) infection [1,2]. Common ophthalmic manifestations include dry eye, foreign body sensation, conjunctivitis, and keratoconjunctivitis [3]. Neurological manifestations of COVID-19 ranged from common indications such as headache, hyposmia, and hypogeusia to rare manifestations such as ischemic and hemorrhagic stroke, myelitis, encephalomyelitis, peripheral neuropathy, and rhabdomyolysis [2].

Optic neuritis, retinitis, uveitis, and vasculitis were reported in animals with COVID-19 infection [4]. However, the ophthalmic

manifestations in humans are usually mild [3,4]. Optic neuritis was reported in a few cases of COVID-19 infection in humans [5]. Most of these cases occurred either in the recovery phase of COVID-19 infection or as a part of a demyelination disease such as Myelin oligodendrocyte glycoprotein (MOG) antibody disease (MOGAD) or acute demyelinating encephalomyelitis (ADEM) [5]. To date, no cases of de novo pituitary dysfunction have been reported with COVID-19. Patients with pre-existing pituitary disorders have been reported to experience exacerbation of hormonal dysfunction [6] and pituitary apoplexy when infected with COVID-19 [7].

This paper reports case of optic neuritis concomitant with an undiagnosed pituitary macroadenoma discovered during active COVID-19 infection.

* Corresponding author.

E-mail address: dr.tutul@yahoo.com (M.M. Rahman).

2. Case report

A 33-year-old female patient presented to the emergency room (ER) with subacute diminution of vision bilaterally, especially on the left eye. Her condition started a couple of days before presentation with a bi-temporal tension-like headache, moderate severity, and more evident on the left side. She also experienced left eye pain associated with eye movement. She denied any diplopia, squint, other facial pain, bulbar symptoms, or other cranial nerves dysfunction. One week before her diminution of vision, the patient had a fever, loss of smell and taste, and a sore throat. Computer tomography (CT) of the chest and polymerase chain reaction (PCR) test for COVID-19 were conducted, and the tests were positive. Upon reviewing her past medical history, she reported that she did not conceive despite ten years of marriage, but her infertility had not been investigated. She said no other symptoms of hormonal dysfunction. She has no significant drug history, no relevant family history, and no remarkable psychosocial history.

On physical examination, she had an average weight and height with no special striking features. No signs of hormonal dysfunction were noted. Her neurological examination was free except for a reduced visual acuity bilaterally more evident on the left (right 6/9, left 6/36) and partial scotoma on-field examination of the left eye. Her fundus examination was unremarkable. Visual field examination using perimeter revealed bitemporal upper quadrantanopia.

A magnetic resonance imaging (MRI) of the brain and orbit was conducted and revealed an enlarged pituitary gland (pituitary macroadenoma) measuring 1.3×2.7 mm with diffuse contrast enhancement (Fig. 1a). A small enhancing patch was also visualized over the retro-bulbar segment of the optic nerve (Fig. 1b). The brain parenchyma was unremarkable for any demyelinating lesions. A complete hormonal profile was dull except for prolactinemia. The prolactin level was 375 ng/mL (normal range in non-pregnant females of matched age is 2–29 ng/mL). Aquaporin 4 antibodies and anti-MOG antibodies (using cell-based techniques) were negative. Cerebrospinal fluid analysis showed a white cell count of 2 cells/cc (100% lymphocytes), protein 29 g/dL, and glucose of 69 mg/dL. The CSF oligoclonal bands were negative, and the IgG index was 0.57.

The patient was diagnosed with pituitary macroadenoma (secretory prolactinoma resulting in infertility) concomitant with optic neuritis. Because the patient was a positive case of COVID-19 infection, treatment was delayed until complete recovery. When COVID-19 PCR turned negative, she was administered pulse corticosteroid (Methylprednisolone 1g IV daily for five consecutive days). The optic neuritis improved significantly, with full recovery being achieved three weeks from the onset of the corticosteroids course. The pituitary macroadenoma was surgically removed via an endonasal transsphenoidal approach. The operation was performed

by a senior consultant in neurosurgery. The prolactin level normalized (22 ng/mL) one month following surgery, and the visual field defect regressed. The patient's visual and endocrine complaints improved significantly, and she returned to her regular activity of daily living. The work has been reported in line with the SCARE 2020 considerations [16].

3. Discussion

The issue of concern here is optic neuritis in a patient with macroadenoma and COVID-19 infection. We report a case of bilateral optic neuritis in a patient with previously undiagnosed pituitary macroadenoma (secretory prolactinoma) occurring in the context of-19 infection. The differential diagnoses on initial presentation were demyelinating disorder (such as ADEM, MS, or NMOSD), post-COVID-19 optic neuritis, and macroadenoma-related optic neuropathy. Demyelination disorders were excluded with normal serum and CSF tests. The question raised was whether the optic neuritis is due to COVID-19 infection or pituitary macroadenoma; and if the COVID-19 disease had a role in the precipitation of optic neuritis in the context of pituitary macroadenoma. Of note, the patient also had field defects, i.e., bitemporal quadrantanopia, which are likely due to the compressive effect of the macroadenoma. However, the optic neuritis seemed to be a different entity independent of the potential compressive impact of the pituitary macroadenoma. The optic neuritis improved significantly after a course of corticosteroids before surgical removal of the pituitary macroadenoma. The field defects, in contrast, improved after surgery.

Pointing to the first question of whether the optic neuritis is due to COVID-19 infection or pituitary adenoma, the data in the literature are of little help to answer this question. Optic neuritis was rarely reported as a manifestation of COVID-19 disease. In most studies, it was a part of a demyelinating syndrome [8–10], which is not the case in our patient giving negative radiology, negative aquaporin 4, and anti-MOG antibodies negative CSF analysis. Isolated optic neuritis was reported by Romero-Sánchez et al. in a case of COVID-19 in Spain during the recovery phase [11]. This is also different from our case, where the optic neuritis occurred within the context of active COVID-19 infection.

The second raised question was whether the COVID-19 infection had a role in the precipitation of optic neuritis in a patient with pre-existing macroadenoma. This question was presented based on data from literature reporting several cases of optic neuritis in patients with pituitary macroadenoma who developed apoplexy [12]. Pituitary apoplexy is commonly precipitated by a viral infection, pregnancy, surgery, certain medications, or head injuries [13]. Rei Yamaguchi et al. [14] reported a case of optic neuritis

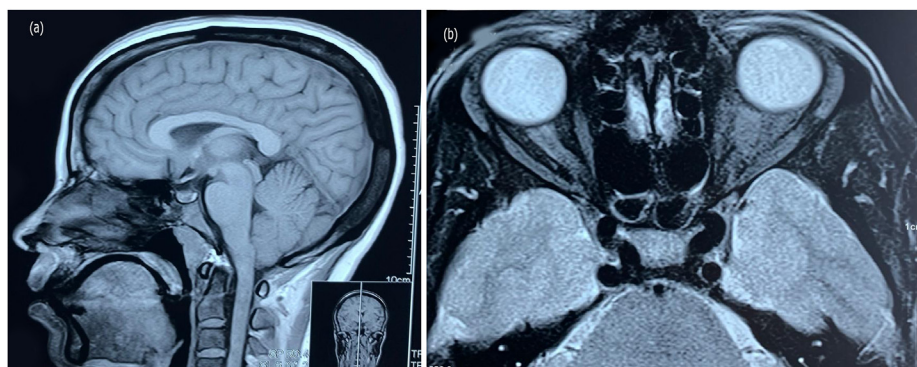


Fig. 1. Brain MRI sagittal T1 (a) film showing enlarged pituitary gland measuring 1.3×2.7 mm and axial T1 (b) film showing enlarged pituitary gland with left optic neuritis.

concomitant with pituitary macroadenoma in a 35-year-old woman during pregnancy [14]. The condition was also attributable to pituitary apoplexy. Similarly, a case of optic neuritis concomitant with pituitary apoplexy in a patient with previously undiagnosed pituitary non-secreting macroadenoma was reported in the context of active COVID-19 infection [15]. However, the case we described did not have pituitary apoplexy, and therefore, the second question could not also be answered.

To the best of our knowledge, the patient we describe is the first case to be reported with isolated regressive optic neuritis in the context of active COVID-19 infection in a patient with previously undiagnosed pituitary macroadenoma without apoplexy. The dilemma of whether optic neuritis occurring concomitantly with pituitary macroadenoma is just a coincidence, or there is an association remains unresolved. Whether COVID-19 infection might precipitate optic neuritis in patients with pituitary macroadenoma or not remains an issue to be answered by observing data from future case reports about similar findings.

This case report's main limitation and the challenge was the simultaneous discovery of optic neuritis in the context of macroadenoma following COVID-19. If macroadenoma was operated on before COVID-19, the optic neuritis could have been attributed to the causative pathology.

Sources of funding

This study did not receive any funding or financial support

Ethical approval

Hospital exempts ethics approval for reported cases.

Consent written

Written informed consent was obtained from the patient for publication of this case report and accompanying images. A copy of the written consent is available for review by the Editor-in-Chief of this journal on request.

Author contribution

All authors contributed equally to the analysis and writing of the paper.

Research registration

Not applicable.

Declaration of competing interest

The authors have no personal, financial, or institutional interest in any drugs, materials, or devices described in this article.

Acknowledgment

None.

Appendix A. Supplementary data

Supplementary data related to this article can be found at <https://doi.org/10.1016/j.ijso.2021.100390>.

Provenance and peer review

Not commissioned, externally peer-reviewed.

References

- [1] Nasiri N, Sharifi H, Bazrafshan A, Noori A, Karamouzian M, Sharifi A. Ocular manifestations of COVID-19: a systematic review and meta-analysis. *J Ophthalmic Vis Res* 2021.
- [2] Nepal G, et al. Neurological manifestations of COVID-19: a systematic review. *Crit Care* 2020;24(1).
- [3] Sen M, Honavar SG, Sharma N, Sachdev MS. COVID-19 and eye: a review of ophthalmic manifestations of COVID-19. *Indian J Ophthalmol* 2021;69(3):488–509.
- [4] Hu K, Patel J, Patel BC. Ophthalmic manifestations of coronavirus (COVID-19). 2020.
- [5] D. M. Gold and S. L. Galetta, "Neuro-ophthalmologic complications of coronavirus disease 2019 (COVID-19)," *Neurosci Lett*, vol. 742, 2021.
- [6] Fleseriu M. Pituitary disorders and COVID-19, reimagining care: the pandemic A year and counting. *Front Endocrinol* 2021;12.
- [7] Bordes SJ, Phang-Lyn S, Najera E, Borghei-Razavi H, Adada B. Pituitary Apoplexy Attributed to COVID-19 infection in the Absence of an Underlying macroadenoma or other Identifiable Cause. *Cureus*; 2021.
- [8] de Ruijter NS, Kramer G, Gons RAR, Hengstman GJD. Neuromyelitis optica spectrum disorder after presumed coronavirus (COVID-19) infection: a case report. *Mult. Scler. Relat. Disord.* 2020;46.
- [9] Zhou S, Jones-Lopez EC, Soneji DJ, Azevedo CJ, Patel VR. Myelin oligodendrocyte glycoprotein antibody-associated optic neuritis and myelitis in COVID-19. *J Neuroophthalmol* 2020;40(3):398–402.
- [10] Novi G, et al. Acute disseminated encephalomyelitis after SARS-CoV-2 infection. *Neurol. Neuroimmunol. neuroinflammation* 2020;7(5).
- [11] Romero-Sánchez CM, et al. Neurologic manifestations in hospitalized patients with COVID-19: the ALBACOV registry. *Neurology* 2020;95(8):e1060–70.
- [12] Moghadasi AN, Aghakhani R, Owji M, Togha M. Pituitary apoplexy presented with optic neuritis. *Iran. J. Neurol.* 2013;12(3):117–8.
- [13] Nawar RN, Abdelmannan D, Selman WR, Arafah BM. Pituitary tumor apoplexy: a review. *J Intensive Care Med* 2008;23(2):75–90.
- [14] Yamaguchi R, et al. A case of optic neuritis concomitant with pituitary tumor during pregnancy. *World Neurosurg* 2016;93. 488.e1–488488.e4.
- [15] Katti V, Ramamurthy L, Kanakpur S, Shet S, Dhoot M. Neuro-ophthalmic presentation of COVID-19 disease: a case report. *Indian J Ophthalmol* 2021;69(4):992–4.
- [16] Agha RA, et al. The SCARE 2020 guideline: updating consensus surgical CAse REport (SCARE) guidelines. *Int J Surg* 2020;84:226–30. <https://doi.org/10.1016/j.ijso.2020.10.034>.