



CASE REPORT

REVISED Case Report: A rare case of prosthetic valve infective endocarditis caused by *Aerococcus urinae* [version 3; referees: 2 approved]

Muhammad Adeel ^{id}1, Saman Tariq², Hisham Akthar ^{id}2, Ahmed Zaghloul³, Corina Iorgoveanu ^{id}3, Carina Dehner ^{id}4

¹Yale New Haven Health, Bridgeport Hospital, Bridgeport, CT, USA

²Galway University Hospital, Galway, Ireland

³University of Connecticut Health Center, Farmington, CT, USA

⁴School of Medicine, Yale University, New Haven, CT, USA

v3 **First published:** 13 Nov 2017, 6:1998 (doi: [10.12688/f1000research.12776.1](https://doi.org/10.12688/f1000research.12776.1))
Second version: 20 Feb 2018, 6:1998 (doi: [10.12688/f1000research.12776.2](https://doi.org/10.12688/f1000research.12776.2))
Latest published: 28 Mar 2018, 6:1998 (doi: [10.12688/f1000research.12776.3](https://doi.org/10.12688/f1000research.12776.3))

Abstract

Infective endocarditis (IE) is a serious and life-threatening cardiac condition, most commonly caused by staphylococci, *Streptococcus viridans*, and enterococci. However, in special settings, IE can be caused by rare organisms. Here we present a case of IE caused by *Aerococcus urinae* in a 75-year-old man with a bioprosthetic aortic valve. *Aerococcus urinae* is a gram-positive, catalase-negative microorganism and is usually an isolate of complicated urinary tract infections in the elderly male population. Improvements in diagnostic testing including use of matrix-assisted laser desorption ionization–a time of flight mass spectrometry (MALDI-TOF MS) have played an important role in recognition of *Aerococcus urinae*.

Open Peer Review

Referee Status:

	Invited Referees	
	1	2
REVISED		
version 3		report
published		↑
28 Mar 2018		
REVISED		
version 2	report	report
published	↑	↑
20 Feb 2018		
version 1		
published	report	report
13 Nov 2017		

1 **Magnus Rasmussen**, Lund University, Sweden

2 **Jens J Christensen**, Slagelse Hospital, Denmark

Discuss this article

Comments (0)

Corresponding author: Carina Dehner (verdaderamente88@gmail.com)

Author roles: **Adeel M:** Conceptualization, Data Curation, Investigation, Methodology, Validation, Writing – Original Draft Preparation; **Tariq S:** Investigation, Methodology; **Akthar H:** Conceptualization, Writing – Review & Editing; **Zaghloul A:** Methodology, Writing – Review & Editing; **Iorgoveanu C:** Methodology, Supervision, Writing – Review & Editing; **Dehner C:** Conceptualization, Formal Analysis, Investigation, Software, Writing – Review & Editing

Competing interests: No competing interests were disclosed.

How to cite this article: Adeel M, Tariq S, Akthar H *et al.* **Case Report: A rare case of prosthetic valve infective endocarditis caused by *Aerococcus urinae* [version 3; referees: 2 approved]** *F1000Research* 2018, **6**:1998 (doi: [10.12688/f1000research.12776.3](https://doi.org/10.12688/f1000research.12776.3))

Copyright: © 2018 Adeel M *et al.* This is an open access article distributed under the terms of the [Creative Commons Attribution Licence](#), which permits unrestricted use, distribution, and reproduction in any medium, provided the original work is properly cited. Data associated with the article are available under the terms of the [Creative Commons Zero "No rights reserved" data waiver](#) (CC0 1.0 Public domain dedication).

Grant information: The author(s) declared that no grants were involved in supporting this work.

First published: 13 Nov 2017, **6**:1998 (doi: [10.12688/f1000research.12776.1](https://doi.org/10.12688/f1000research.12776.1))

REVISED Amendments from Version 2

We rephrased the remaining, unclear points, according to Dr. Christensen's feedback. We provided the reference that *Aerococcus urinae* was first reported in 1967. This also clarified that *Aerococcus urinae* has been increasingly identified due to advancement in detection and identification techniques. We also stated that partial 16S rRNA gene sequencing analysis would be the most time-efficient method but is not performed frequently due to cost and lack of expertise. Finally, we corrected our text to say that MALD-TOFI has improved recognition, and not isolation as previously stated.

See referee reports

Introduction

IE is a serious and potentially life-threatening condition. Expedite recognition, diagnosis, and treatment is critical. The diagnosis of IE is based on Duke's criteria or its modifications¹. Risk factors for IE include advanced age (> 60 years), male gender, history of intravenous drug use, poor dentition, structural or valvular heart disease and presence of prosthesis. Here, we describe a rare case of IE caused by *Aerococcus urinae*, a gram-positive, catalase-negative coccus that grows in clusters. *Aerococcus urinae* is a rare organism and since its first reported in 1967², has been increasingly recognized as a causative pathogen of urinary tract infections and rarely IE. In the past, reported cases showed poor outcome; however recent Swedish epidemiological study reported the favorable outcome³.

Case report

A 75-year-old Caucasian man presented to his local hospital with malaise, fever, and nausea for five days. He had a bio prosthetic aortic valve replacement for mixed aortic valve disease 12 years ago; further significant past medical history included placement of a permanent pacemaker for complete heart block, right total hip replacement, hypertension and benign prostatic hyperplasia (BPH). The patient had no history of smoking, alcohol consumption or illicit drug use. The patient had no recent surgeries or dental work, and the review of systems was unremarkable. The physical exam revealed vital parameters of HR 97 bpm regular, BP 134/87, the temperature of 101.5°F, respiratory rate of 18 per minute and oxygen saturation of 96% on room air. On precordial auscultation, a systolic and a diastolic murmur were heard in the aortic area, mild bi-basal crackles, but no jugular venous distention or peripheral edema. The rest of the physical exam was unremarkable. The labs showed a normal white cell count (WCC) of $9.9 \times 10^6/L$, elevated C-reactive protein to 214.9 mg/L (normal <5 mg/L) and a hemoglobin of 11.2 g/dl, the other labs were unremarkable. His mid-stream urine showed WCC < 20; red cell count (RCC) of 20–50 and it grew mixed organisms, all considered part of the normal flora. Chest X-ray, CT scan of the brain, thorax, abdomen, and pelvis did not show any source of infection.

The patient was empirically commenced on IV piperacillin-tazobactam and vancomycin. Blood cultures collected at the time of admission grew *Aerococcus urinae* in both bottles. A repeat set of blood cultures corresponding to a spike of fever in the following 24 hours also grew *Aerococcus urinae* in both bottles;

all cultures were sensitive to ampicillin (MIC 0.064 mg/L) and gentamicin (MIC 2 mg/L).

A trans-thoracic echocardiogram showed mild aortic regurgitation and mitral regurgitation with no clear vegetation, however, trans-esophageal echocardiogram (TOE) showed normal left ventricular function with moderate aortic regurgitation due to large mobile vegetation on the bio-prosthetic aortic valve. There was no peri-valvular abscess or features of the paravalvular abscess noted (See [Image 1a and 1b](#)). Pacemaker lead and right-sided valves were not involved.

Clinical presentation, echocardiographic findings, and positive blood cultures fulfilled Duke's criteria (Hoen *et al.*, 1996) for IE. The patient was managed as prosthetic aortic valve endocarditis from *Aerococcus urinae* with IV amoxicillin 2 grams every 4 hours, and gentamicin 1 mg/kg twice daily as per hospital guidelines for IE. IV antibiotic therapy for six weeks in total with possible surgery for prosthetic valve replacement was planned (Truninger *et al.*, 1999).

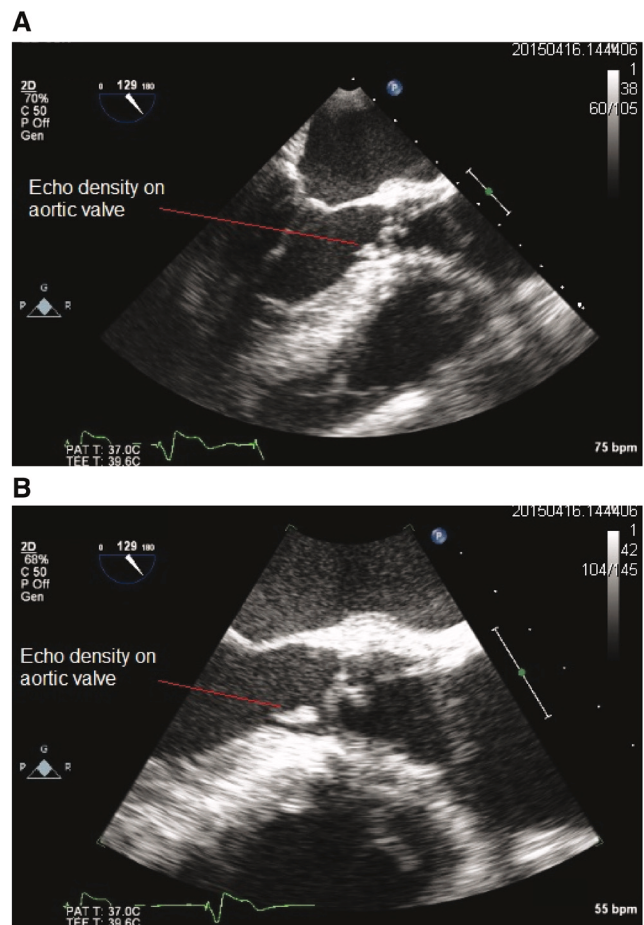


Figure 1. **1A:** Transesophageal echocardiogram (TEE), mid-esophageal view showing mobile echo density on the prosthetic aortic valve. **1B:** Transesophageal echocardiogram (TEE), mid-esophageal view enlarged to show mobile echo density on the prosthetic aortic valve.

Despite prompt initiation of appropriate antibiotic treatment and intensive clinical monitoring, the patient failed to improve this hospitalization and developed sudden pulmonary edema and worsening aortic regurgitation on repeat transthoracic echo and unfortunately died due to rapid deterioration before surgery. As per family's wishes, an autopsy was not performed.

Discussion

Aerococcus urinae is a gram-positive, catalase-negative coccus which grows in clusters. It is mostly associated with urinary tract infections in elderly men, especially in the setting of structural abnormalities, e.g. BPH, urethral strictures and nephrolithiasis. It has been associated with culture-negative infective endocarditis⁴. It is reported to be sensitive to penicillins/cephalosporins and resistant to sulfonamides and aminoglycosides⁵. By now, more than 40 cases of IE caused by *Aerococcus urinae* have been reported⁶ likely due to improvements in diagnostics.

Despite the fact that *Aerococcus urinae* is rare organism causing infective endocarditis, most cases respond well to antibiotic therapy and surgery is often not needed³. The indications for surgical intervention for PVE include severe prosthetic dysfunction, severe heart failure, large vegetation, and abscess or peri-valvular involvement⁷.

This case highlights the importance of source control by expediting prosthesis removal in the presence of overt symptoms of worsening cardiac failure and worsening prosthesis dysfunction

(regurgitation in this case), as medical therapy alone may not be sufficient to effectively treat *Aerococcus urinae* IE despite appropriate sensitivities. Early identification is crucial and can be life-saving. The current diagnostic testing for microorganisms – whereas partial 16S rRNA gene sequencing analysis would be the most time-efficient method, it's rarely done, as the expertise is limited and costs are high. Recently, there is good evidence for the use of MALDI-TOF^{8,9} due to increased detection rates, even in direct comparison to 16s sequencing.

In conclusion, *Aerococcus urinae* has been increasingly identified as the cause of infective endocarditis due to advancement in detection and identification methods. Therefore establishing a concise and broadly acknowledged protocol for diagnosis up to patient management is critical.

Consent

Written informed consent for publication of their clinical details was obtained from the patient. Permission was also granted from a next of kin for publication of the manuscript.

Competing interests

No competing interests were disclosed.

Grant information

The author(s) declared that no grants were involved in supporting this work.

References

- Li JS, Sexton DJ, Mick N, *et al.*: **Proposed modifications to the Duke criteria for the diagnosis of infective endocarditis.** *Clin Infect Dis.* 2000; **30**(4): 633–638. [PubMed Abstract](#) | [Publisher Full Text](#)
- Higgins A, Garg T: **Aerococcus urinae: An Emerging Cause of Urinary Tract Infection in Older Adults with Multimorbidity and Urologic Cancer.** *Urol Case Rep.* 2017; **13**: 24–25. [PubMed Abstract](#) | [Publisher Full Text](#) | [Free Full Text](#)
- Sunnerhagen T, Nilson B, Olaison L, *et al.*: **Clinical and microbiological features of infective endocarditis caused by aerococci.** *Infection.* 2016; **44**(2): 167–173. [PubMed Abstract](#) | [Publisher Full Text](#)
- Slany M, Freiburger T, Pavlik P, *et al.*: **Culture-negative infective endocarditis caused by *Aerococcus urinae*.** *J Heart Valve Dis.* 2007; **16**(2): 203–205. [PubMed Abstract](#)
- Skov R, Christensen JJ, Komer B, *et al.*: **In vitro antimicrobial susceptibility of *Aerococcus urinae* to 14 antibiotics, and time-kill curves for penicillin, gentamicin and vancomycin.** *J Antimicrob Chemother.* 2001; **48**(5): 653–658. [PubMed Abstract](#) | [Publisher Full Text](#)
- Tathireddy H, Settyapalli S, Farrell JJ: **A rare case of aerococcus urinae infective endocarditis.** *J Community Hosp Intern Med Perspect.* 2017; **7**(2): 126–129. [PubMed Abstract](#) | [Publisher Full Text](#) | [Free Full Text](#)
- Habib G, Tribouilloy C, Thuny F, *et al.*: **Prosthetic valve endocarditis: who needs surgery? A multicentre study of 104 cases.** *Heart.* 2005; **91**(7): 954–959. [PubMed Abstract](#) | [Publisher Full Text](#) | [Free Full Text](#)
- Senneby E, Nilson B, Petersson AC, *et al.*: **Matrix-assisted laser desorption ionization-time of flight mass spectrometry is a sensitive and specific method for identification of aerococci.** *J Clin Microbiol.* 2013; **51**(4): 1303–1304. [PubMed Abstract](#) | [Publisher Full Text](#) | [Free Full Text](#)
- Senneby E, Göransson L, Weiber S, *et al.*: **A population-based study of aerococcal bacteraemia in the MALDI-TOF MS-era.** *Eur J Clin Microbiol Infect Dis.* 2016; **35**(5): 755–762. [PubMed Abstract](#) | [Publisher Full Text](#)

Open Peer Review

Current Referee Status:  

Version 3

Referee Report 03 April 2018

doi:[10.5256/f1000research.15480.r32542](https://doi.org/10.5256/f1000research.15480.r32542)



Jens J Christensen

Department of Clinical Microbiology, Slagelse Hospital, Slagelse, Denmark

The improvement suggestions have been taken care of and the manuscript acceptable.

Competing Interests: No competing interests were disclosed.

Referee Expertise: Clinical microbiology

I have read this submission. I believe that I have an appropriate level of expertise to confirm that it is of an acceptable scientific standard.

Version 2

Referee Report 01 March 2018

doi:[10.5256/f1000research.15259.r31034](https://doi.org/10.5256/f1000research.15259.r31034)



Magnus Rasmussen

Department of Clinical Sciences, Division of Infection Medicine, Faculty of Medicine, Lund University, Lund, Sweden

Most concerns have been satisfactorily addressed. Information on method of species determination and on the size of the vegetation would still be of interest.

Competing Interests: No competing interests were disclosed.

I have read this submission. I believe that I have an appropriate level of expertise to confirm that it is of an acceptable scientific standard.

Referee Report 28 February 2018

doi:[10.5256/f1000research.15259.r31035](https://doi.org/10.5256/f1000research.15259.r31035)



Jens J Christensen

Department of Clinical Microbiology, Slagelse Hospital, Slagelse, Denmark

Follow up on previous comments. Suggests the following improvements:

Abstract

1. There are 2 dots ahead of Improvements: Delete 1.
2. MALDI-TOF MS has improved recognition not isolation. Please rephrase.

Introduction

1. Please rephrase "secondary to Aerococcus urinae"
2. Please give a reference on initial recognition of A. urinae. Is the year 1967 correct?
3. As can be seen in this case can be deleted.

Case report

1. Give entity on C-reactive protein
2. Blood-culture system used is missing
3. MALDI-TOF MS details are missing
4. Antibiotic susceptibility testing system used is missing

Discussion

1. The main problem... and the rest of the section: The 2 sentences are not clear. Please rephrase.
2. In conclusion....: it is advancements in as well detection as identification methods. The last sentence is not clear. Please rephrase

Competing Interests: No competing interests were disclosed.

Referee Expertise: Clinical microbiology

I have read this submission. I believe that I have an appropriate level of expertise to confirm that it is of an acceptable scientific standard, however I have significant reservations, as outlined above.

Author Response 05 Mar 2018

Carina Dehner, Yale University, USA

Dear Dr. Christensen,

Thank you very much for your helpful feedback. We rephrased the suggested points throughout the article.

Unfortunately we were not able to assess the points listed in the case report in our patient, however our aim was to underline the need for new techniques (like MALDI-TOF) in order to make the correct diagnosis in a timely manner.

Competing Interests: Competing Interests: No competing interests were disclosed.

Version 1

Referee Report 22 January 2018

doi:10.5256/f1000research.13841.r29616



Jens J Christensen

Department of Clinical Microbiology, Slagelse Hospital, Slagelse, Denmark

A fatal case of IE caused by *Aerococcus urinae*, in a 75-year-old man with a bioprosthetic aortic valve is presented and discussed. Very precise and covering comments have been given by reviewer 1. Microbiological data should be examined thoroughly and extended. Language correction seems indicated. The following comments can be added.

- 1) Abstract:
 - It is always important to also having focus on more rare etiologies of IE. In the abstract it is stated that the mortality rate is high. This is suggested to be modified to: Initial descriptions of collections of IE cases with *A. urinae* demonstrated a high morbidity and mortality rate, whereas a recent Swedish epidemiological study could not retrieve this.
- 2) Introduction:
 - Dukes criteria should be mentioned.
 - There is not a species named *Streptococcus viridans*.
 - Recent diagnostic improvements should be included, especially MALDI-TOF mass spectrometry.
 - a gram-positive, catalase-negative
- 3) Case description:
 - Specific description of PM electrode findings should be given.
 - A more detailed disease timespan is desirable.
 - Microbiological data are very scarce. Blood-culture system and number of positive bottles should be given. Likewise identification criteria and susceptibility methods and results, including MIC values of relevant antibiotics should be given.
 - A thorough microbiological examination of the manuscript seems indicated
 - *Aerococcus urinae* should only be fully written the first time
- 4) Discussion
 - 16S is slang: it should be partial 16S rRNA gene sequencing analysis

Is the background of the case's history and progression described in sufficient detail?

Partly

Are enough details provided of any physical examination and diagnostic tests, treatment given and outcomes?

Partly

Is sufficient discussion included of the importance of the findings and their relevance to future understanding of disease processes, diagnosis or treatment?

Partly

Is the case presented with sufficient detail to be useful for other practitioners?

No

Competing Interests: No competing interests were disclosed.

Referee Expertise: Clinical microbiology

I have read this submission. I believe that I have an appropriate level of expertise to confirm that it is of an acceptable scientific standard, however I have significant reservations, as outlined above.

Author Response 13 Feb 2018

Carina Dehner, Yale University, USA

1. The prognosis of *A. urinae* IE is not poor. Many cases with fatal outcome have been published but in the only population-based survey¹ demonstrate a relatively favourable prognosis compared to other pathogens. The risk with case reports is a publication-bias where only dramatic cases are published. The case series should be quoted and is the only reliable source on information on *A. urinae* IE. A poor prognosis is claimed in the abstract, introduction and discussion. This claim must be modified based on the findings by Sunnerhagen *et al.*

A new reference was added to the introduction about favourable outcome to IE caused by *Aerococcus urinae*

2. A diagnosis of IE is established through the Dukes criteria, I suggest a reference to Li is given². Symptoms and chest X-ray are irrelevant for the diagnostic process. Please modify introduction.

A new reference was added to diagnose IE based on Dukes criteria or their modifications

3. In the case description it is twice stated that the patient has sepsis. Sepsis-3 criteria are not fulfilled. Please rephrase.

Rephrased

4. The cultures grew *A. urinae*. How was the species determination performed? How many cultures? MIC for ampicillin and gentamycin should be given.

MICs for ampicillin and gentamicin added, description added about blood cultures

5. It is claimed that TEE demonstrates a “moderate aortic regurgitation due to a large mobile vegetation”. It is important if the regurgitation was paravalvular or through the valves. Maximum size of the vegetation is also crucial since this is important for establishing the indication for operation. Left ventricular function should also be commented on as well as if there were signs of vegetations on the pacemaker cable.

Transesophageal echo description expanded, commented on LV and pacemaker lead.

6. It is claimed that ampi+genta was commenced according to local guidelines. For which bacterial species are these guidelines meant. The use of aminoglycosides in this condition is controversial¹.

Hospital guidelines for suspected/possible IE were followed

7. How was “progressive aortic regurgitation verified? Could pacemaker failure have played a role?

Repeat transthoracic echo showed worsening of regurgitation; this is added to the case

8. Why was the patient not moved for emergency surgery when he deteriorated? This seem like an avoidable fatality!

Deterioration was sudden and rapid, arrangements were made but patient died before the surgery

9. In the discussion it is claimed that there are only 20 reports. This is not true¹. Cases up until 2015 are summarized in a review³.

Updated number of *Aerococcus urinae* IE reported

10. Surgical intervention is claimed to be common in the discussion with a quote to Wang. Please read and quote Sunnerhagen instead¹. Surgery is relatively rarely needed.

Reference added to show that surgery in most cases is not indicated

11. "Large persistent vegetation" is claimed as an indication for surgery. Large is enough.

Modified

12 "The presence of vegetation on the valve created a consistent source of bacteria that could embolize and can serve as a source of sepsis." This statement has nothing to do with the current case and should be omitted.

Omitted

13 "The main problem is current diagnostic testing for microorganisms– whereas 16s sequencing would be the most time-efficient method, it's rarely done, as the expertise is limited and costs... and so on" This is irrelevant for the case since the reason to operate is not dependent on microbiological diagnostics. Irrespective of the causative pathogen this patient would have been saved by timely heart surgery.

This is kept; we wish our readers to know that improved methods of isolation are important and could help with management

14. The claim "In conclusion, *Aerococcus urinae* used to be a rare cause of IE but rates have been increasing significantly within the last 10 years." Lacks support and should be deleted. *A. urinae* has been increasingly REPORTED as a cause of IE but incidence is likely unchanged.

This is now added that that increase in reported cases is due to better isolation methods.

15. In discussing Duke criteria in the case presentation one must keep in mind that *A. urinae* in 2/2 cultures (4/4 bottles) only fulfill Duke criteria if the cultures were taken with

Agreed

Competing Interests: No competing interests were disclosed.

Referee Report 11 December 2017

doi:10.5256/f1000research.13841.r28819



Magnus Rasmussen

Department of Clinical Sciences, Division of Infection Medicine, Faculty of Medicine, Lund University, Lund, Sweden

This work describes a case of prosthetic valve infective (IE) caused by *Aerococcus urinae* with fatal outcome. The number of case reports on this condition is increasing and it is not immediately obvious that another case with poor outcome is helpful. This case, however, has an important learning point in that a patient with prosthetic valve endocarditis, in resource-rich settings, must be treated in a centre where acute cardiac surgery can be performed or near such a centre. It is of less importance if the causative bacterium in this case were *A. urinae* or any other bacterium. I list my major concerns and minor points below:

Major concerns

1. The prognosis of *A. urinae* IE is not poor. Many cases with fatal outcome have been published but in the only population-based survey¹ demonstrate a relatively favourable prognosis compared to other pathogens. The risk with case reports is a publication-bias where only dramatic cases are published. The case series should be quoted and is the only reliable source on information on *A. urinae* IE. A poor prognosis is claimed in the abstract, introduction and discussion. This claim must be modified based on the findings by Sunnerhagen *et al.*
2. A diagnosis of IE is established through the Dukes criteria, I suggest a reference to Li is given². Symptoms and chest X-ray are irrelevant for the diagnostic process. Please modify introduction.
3. In the case description it is twice stated that the patient has sepsis. Sepsis-3 criteria are not fulfilled. Please rephrase.
4. The cultures grew *A. urinae*. How was the species determination performed? How many cultures? MIC for ampicillin and gentamycin should be given.
5. It is claimed that TEE demonstrates a "moderate aortic regurgitation due to a large mobile vegetation". It is important if the regurgitation was paravalvular or through the valves. Maximum size of the vegetation is also crucial since this is important for establishing the indication for operation. Left ventricular function should also be commented on as well as if there were signs of vegetations on the pacemaker cable.
6. It is claimed that ampi+genta was commenced according to local guidelines. For which bacterial species are these guidelines meant. The use of aminoglycosides in this condition is controversial¹.
7. How was "progressive aortic regurgitation verified? Could pacemaker failure have played a role?
8. Why was the patient not moved for emergency surgery when he deteriorated? This seem like an avoidable fatality!
9. In the discussion it is claimed that there are only 20 reports. This is not true¹. Cases up until 2015 are summarized in a review³.
10. Surgical intervention is claimed to be common in the discussion with a quote to Wang. Please read and quote Sunnerhagen instead¹. Surgery is relatively rarely needed.

11. "Large persistent vegetation" is claimed as an indication for surgery. Large is enough.
- 12 "The presence of vegetation on the valve created a consistent source of bacteria that could embolize and can serve as a source of sepsis." This statement has nothing to do with the current case and should be omitted.
- 13 "The main problem is current diagnostic testing for microorganisms– whereas 16s sequencing would be the most time-efficient method, it's rarely done, as the expertise is limited and costs... and so on" This is irrelevant for the case since the reason to operate is not dependent on microbiological diagnostics. Irrespective of the causative pathogen this patient would have been saved by timely heart surgery.
14. The claim "In conclusion, *Aerococcus urinae* used to be a rare cause of IE but rates have been increasing significantly within the last 10 years." Lacks support and should be deleted. *A. urinae* has been increasingly REPORTED as a cause of IE but incidence is likely unchanged.
15. In discussing Duke criteria in the case presentation one must keep in mind that *A. urinae* in 2/2 cultures (4/4 bottles) only fulfill Duke criteria if the cultures were taken with

Minor comments

1. I suggest another title. Something like "fatal case of *A. urinae* prosthetic valve endocarditis."
2. Why mention HACEK in the abstract? Those organisms are exceedingly rare and for example much less common than betaheamolytic strep.
3. In case presentation spell out JVD.
4. "Stable haemoglobin"- what is meant. Are the authors referring to repeated measurements?

References

1. Sunnerhagen T, Nilson B, Olaison L, Rasmussen M: Clinical and microbiological features of infective endocarditis caused by aerococci. *Infection*. 2016; **44** (2): 167-73 [PubMed Abstract](#) | [Publisher Full Text](#)
2. Li JS, Sexton DJ, Mick N, Nettles R, Fowler VG, Ryan T, Bashore T, Corey GR: Proposed modifications to the Duke criteria for the diagnosis of infective endocarditis. *Clin Infect Dis*. 2000; **30** (4): 633-8 [PubMed Abstract](#) | [Publisher Full Text](#)
3. Rasmussen M: *Aerococcus*: an increasingly acknowledged human pathogen. *Clin Microbiol Infect*. 2016; **22** (1): 22-27 [PubMed Abstract](#) | [Publisher Full Text](#)

Is the background of the case's history and progression described in sufficient detail?

Partly

Are enough details provided of any physical examination and diagnostic tests, treatment given and outcomes?

Partly

Is sufficient discussion included of the importance of the findings and their relevance to future understanding of disease processes, diagnosis or treatment?

No

Is the case presented with sufficient detail to be useful for other practitioners?

Partly

Competing Interests: No competing interests were disclosed.

Referee Expertise: endocarditis

I have read this submission. I believe that I have an appropriate level of expertise to confirm that it is of an acceptable scientific standard, however I have significant reservations, as outlined above.

Author Response 13 Feb 2018

Carina Dehner, Yale University, USA

1) Abstract:

- It is always important to also having focus on more rare etiologies of IE. In the abstract it is stated that the mortality rate is high. This is suggested to be modified to: Initial descriptions of collections of IE cases with *A. urinae* demonstrated a high morbidity and mortality rate, whereas a recent Swedish epidemiological study could not retrieve this.

New reference to the introduction was added to highlight the better outcome

2) Introduction:

- Dukes criteria should be mentioned.

- New references added to mention Duke's criteria or its modifications

- There is not a species named *Streptococcus viridans*.

Correction made

- Recent diagnostic improvements should be included, especially MALDI-TOF mass spectrometry.

Added in abstract

- a gram-positive, catalase-negative

Correction made

3) Case description: Specific description of PM electrode findings should be given.

Included in description, PM lead was not involved.

Microbiological data are very scarce. Blood-culture system and number of positive bottles should be given. Likewise identification criteria and susceptibility methods and results, including MIC values of relevant antibiotics should be given.

This is now added to the case description

4) Discussion: 16S is slang: it should be partial 16S rRNA gene sequencing analysis

Correction made

Competing Interests: No competing interests were disclosed.

The benefits of publishing with F1000Research:

- Your article is published within days, with no editorial bias
- You can publish traditional articles, null/negative results, case reports, data notes and more
- The peer review process is transparent and collaborative
- Your article is indexed in PubMed after passing peer review
- Dedicated customer support at every stage

For pre-submission enquiries, contact research@f1000.com

F1000Research