Chong et al. European Radiology (2025) 35:6745–6754
https://doi.org/10.1007/s00330-025-11660-8

EUROPEAN SOCIETY OF RADIOLOGY
European Radiology

HEAD AND NECK Open Access

Internal auditory meatus vascular loops and vestibulocochlear neurovascular contact on MRI: Are they associated with pulsatile tinnitus?

Mervyn L. Chong[1], Kyle R. S. Stephenson[2], Mehrshad Sultani Tehrani[3], Irumee Pai[4,5] and Steve E. J. Connor[2,4,6]*

Abstract

Objectives To compare the presence of internal auditory meatus vascular loops (IVLs) or vestibulocochlear neurovascular contact (CN8-NVC) between unexplained unilateral pulsatile tinnitus (PT) ears and contralateral asymptomatic ears. Furthermore, to investigate whether IVL depth or angulation, or CN8-NVC location is associated with the presence of PT.

Materials and methods Single-centre retrospective case-controlled study of patients undergoing three-dimensional T2-weighted MRI for unexplained unilateral PT from January 2012 to July 2021. Two blinded observers recorded the presence of IVLs or CN8-NVCs, whilst evaluating IVL depth and angulation. Proportions of ears with IVLs or CN8-NVCs were compared between PT ears and contralateral control ears with McNemar's test. Mann–Whitney *U* or Student's *t*-test compared the depth and angulation of IVLs and the location of CN8-NVC with respect to the transition zone between ears with and without PT.

Results Three hundred thirty-seven patients were evaluated (250 female; mean age 47 ± 16 years). There was no significant difference between the proportion of IVLs (19.3% vs 25.2%; $p = 0.06$) or CN8-NVCs (59.9% vs 65.6%; $p = 0.12$) in PT ears as compared to contralateral control ears. There was no significant difference in IVL depth (median loop-fundus distance 6.5 mm vs 6.8 mm; $p = 0.45$), IVL angulation (median interlimb distance 3.1 mm vs 3.3 mm; $p = 0.54$), or CN8-NVC location within the transition zone ($p = 0.58$) between ears with and without PT.

Conclusion Unexplained unilateral PT is not associated with the presence of an ipsilateral IVL or CN8-NVC. Likelihood of PT is not influenced by depth or angulation of an ipsilateral IVL, nor by whether CN8-NVC is at the transition zone.

Key Points

Question *The relevance of internal auditory meatus (IAM) vascular loops or vestibulocochlear NVC in the context of PT remains uncertain.*

Findings *Likelihood of unilateral PT was not influenced by the presence, depth, or angulation of IAM vascular loops, nor by the presence or location of vestibulocochlear NVC.*

Clinical relevance *This study argues against the analysis and reporting of IAM vascular loops or vestibulocochlear NVC in the context of PT, and it gives the clinician confidence to reassure the patient that these are unlikely to be an aetiology.*

Keywords Pulsatile tinnitus, Internal auditory meatus, Vascular loops, Neurovascular contact, Magnetic resonance imaging

*Correspondence:
Steve E. J. Connor
steve.connor@kcl.ac.uk
Full list of author information is available at the end of the article

Springer

© Crown 2025. **Open Access** This article is licensed under a Creative Commons Attribution 4.0 International License, which permits use, sharing, adaptation, distribution and reproduction in any medium or format, as long as you give appropriate credit to the original author(s) and the source, provide a link to the Creative Commons licence, and indicate if changes were made. The images or other third party material in this article are included in the article's Creative Commons licence, unless indicated otherwise in a credit line to the material. If material is not included in the article's Creative Commons licence and your intended use is not permitted by statutory regulation or exceeds the permitted use, you will need to obtain permission directly from the copyright holder. To view a copy of this licence, visit http://creativecommons.org/licenses/by/4.0/.

Graphical Abstract

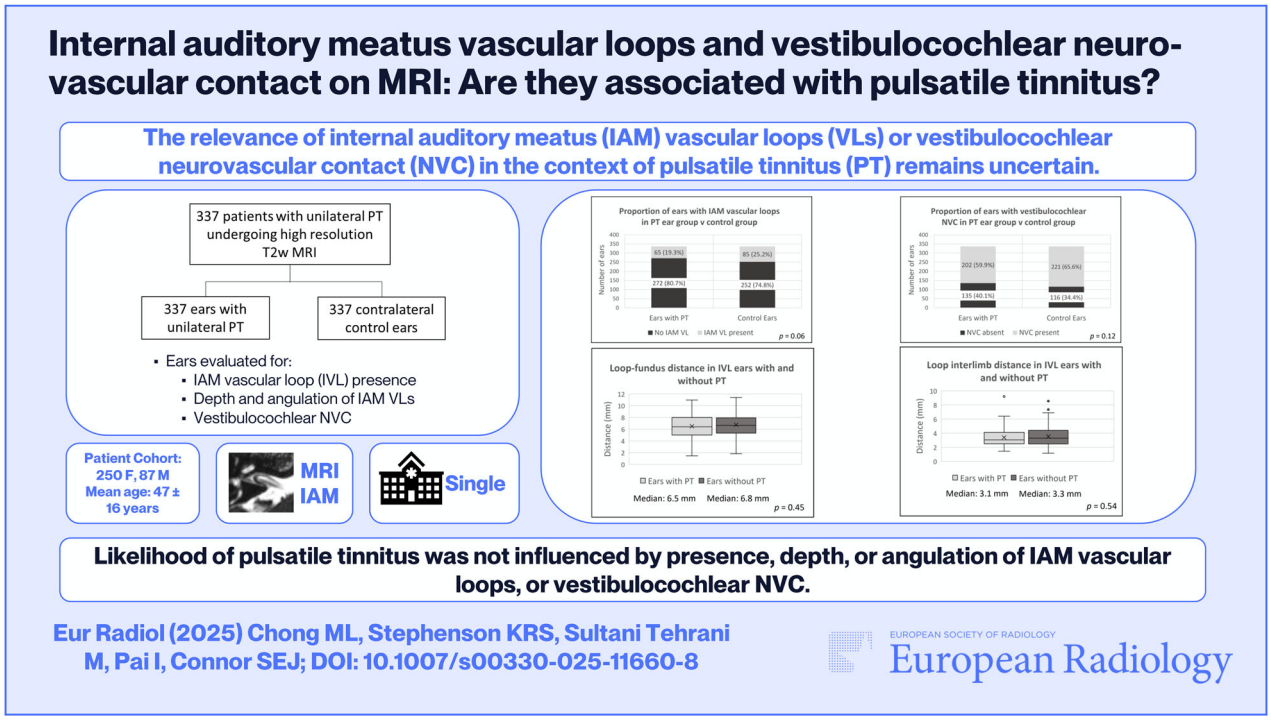

Introduction

Tinnitus is the perception of sound in the absence of a corresponding external stimulus [1]. Pulsatile tinnitus (PT) is perceived as a rhythmic sound at the rate of the cardiac cycle and is thought to represent 4–10% of tinnitus [2, 3]. Imaging is performed in order to identify the aetiology of PT, which may aid prognostication and target therapy. Evaluating the diagnostic yield of imaging in PT is challenging due to the heterogeneity of study designs, with rates of positive findings ranging from 44% to 91% [4]. The most frequent abnormalities include paragangliomas, dural arteriovenous fistulae, idiopathic intracranial hypertension, venous anatomical variants and atheromatous disease [5–7]. Both CT and MRI-based protocols with vascular imaging are recommended for the investigation of PT [8].

Previous authors have proposed that normal internal auditory meatus (IAM) vascular loops (VLs) may also be responsible for PT [9, 10]. Proposed mechanisms include neurovascular contact (NVC) and demyelination of the vestibulocochlear nerve (CN8) [10, 11], reduced vascular perfusion [12, 13] and increased transmission of pulsatile sound from turbulent blood flow through the cerebrospinal fluid [9]. The IAM internal auditory meatus vascular loop (IVLs) usually arise from the anterior inferior cerebellar artery and may be seen as an anatomical variant in 10% [14]. IVLs and CN8 NVC are optimally evaluated with three-dimensional (3D) fast spin echo or gradient echo high-resolution (HR) T2-weighted (T2w) MRI sequences, and this may be a justification for the inclusion of these sequences in PT MRI protocols.

Most case-controlled studies have shown no difference in the incidence of tinnitus in ears with IVLs [13, 15–18] or CN8 NVC [15, 16, 18, 19]. Whilst some cohorts have included PT ears, they have usually been analysed in combination with non-PT ears [13, 16, 18, 19]. The prevalence of IVLs or CN8 NVC in PT ears alone has only been investigated in small cohorts and without normal ear control groups [9, 10].

Demonstrating an association between IVLs or CN8 NVC and PT would necessitate optimisation of imaging protocols for their detection, analysis and reporting by radiologists, and that clinicians discuss their potential clinical significance and treatment with the patient.

The primary objective was to determine whether there is a difference between the proportion of ears with IVLs or CN8 NVCs on three-dimensional high-resolution (3D HR) T2w MRI when comparing unexplained unilateral PT ears with their contralateral asymptomatic controls. The secondary objectives were to determine whether

anatomical co-variates such as IVL angulation and depth influence the likelihood of PT in ears with IVLs, and whether the location of NVC with respect to the transition zone (TZ) or central myelin portion (CMP) of CN8 influences the presence of PT in ears with CN8 NVC.

Methods

Patients

Institutional approval (project number 15888) was obtained, and patient consent was waived. This was a retrospective case-controlled cross-sectional study undertaken in a tertiary referral centre. Consecutive patients undergoing MRI for the investigation of PT were identified from a search of a radiology imaging system database between 1/1/2012 to 31/07/2021. The Boolean search terms comprised the keywords tin* AND whoos* OR pulsa*. Patient demographics, laterality of PT, otoscopic findings, other audiovestibular symptoms or diagnoses, and other medical conditions were recorded. The mean air (0.5 kHz, 1 kHz, 2 kHz, 4 kHz, and 8 kHz) and bone conduction thresholds (0.5 kHz, 1 kHz, 2 kHz, and 4 kHz) were recorded from the pure tone audiogram performed at the shortest interval from the MRI study.

Exclusion criteria were bilateral tinnitus or insufficient details on lateralisation of PT, absent or degraded 3D HR T2w sequences, alternative causes of PT on imaging or medical assessment, abnormal otoscopy, air-bone gap on audiometry indicating conductive hearing loss [20], absent audiogram, and significant intracranial/ear pathology, trauma, or surgery. The study flowchart shown in Fig. 1 summarises the patient selection process.

MRI protocol and image analysis

MRI machine details and parameters are shown in Table 1. There were 335/337 (99.4%) studies performed with either 3D HR T2w CISS (constructive interference in steady state) on a 1.5-T Tesla Siemens Magnetom® Aera scanner (276/337; 81.9%) or 3D HR T2w SPACE (sampling perfection with application optimised contrasts using different flip angle evaluation) on a 3-T Tesla Siemens Magnetom® Skyra scanner (59/337; 17.5%).

Two subspecialist head and neck radiologists (M.L.C., 5 years' experience; K.R.S.S., 4 years' experience) independently analysed the 3D HR T2w axial MRI of the IAMs on a PACS workstation (Sectra workstation, Sectra AB), with the aid of multiplanar reformats. The images were

Table 1 MRI parameters

Parameter	T2-CISS	T2-SPACE
Scanner details	1.5 Tesla Siemens Magnetom® Aera	3 Tesla Siemens Magnetom® Skyra
Repetition time	5.36 ms	1000 ms
Echo time	2.41 ms	125 ms
Inversion time	N/A	N/A
Number of excitations	1	2
Refocusing flip angle	62 degrees	100 degrees
Echo train length	1	54
Pixel spacing	0.35 mm	0.5 mm
Slice thickness	0.7 mm	0.5 mm
Matrix size	384 × 512	164 × 320
Field of view	135 × 180 mm	82 × 160 mm
Pixel bandwidth	422 Hz/Px	255 Hz/Px
Number of excitations	1	2

CISS constructive interference in steady state, *SPACE* sampling perfection with application-optimised contrasts using different flip angle evaluation

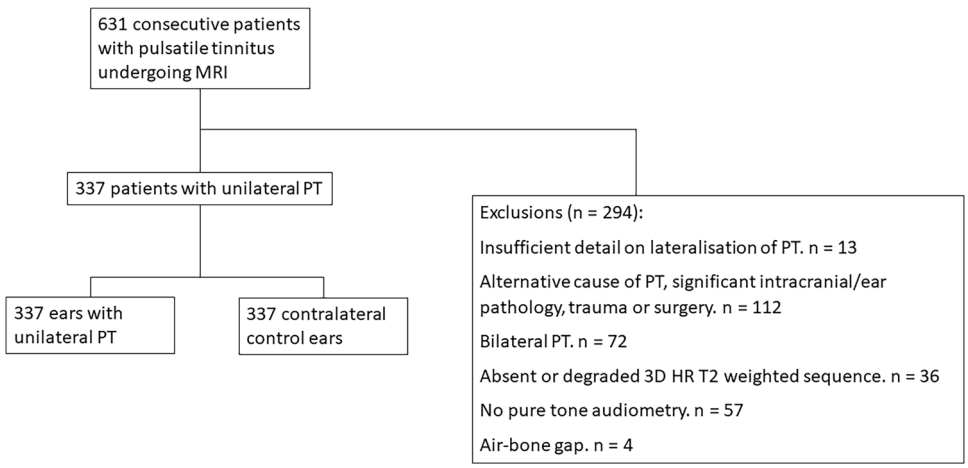

Fig. 1 Flow chart of patient selection process. 3D HR, three-dimensional high resolution; PT, pulsatile tinnitus

Table 2 Imaging criteria and definitions

Imaging criterion	Definition
Chavda I	VL is located only in the CPA but does not enter the IAM.
Chavda II	VL entering but not extending greater than 50% of the length of the IAM.
Chavda III	VL extending greater than 50% of the length of the IAM.
Loop-fundus distance	Distance (mm) from the VL apex to the base of the modiolus on axial images.
Loop interlimb distance	Distance (mm) between the proximal and distal limbs of the VL at 2 mm from the VL apex.
NVC	Identified as contact between the VL and the vestibulocochlear or cochlear nerve without a visible intervening normal cerebrospinal fluid signal.

CPA cerebellopontine angle, *IAM* internal auditory meatus, *NVC* neurovascular contact, *VL* vascular loop

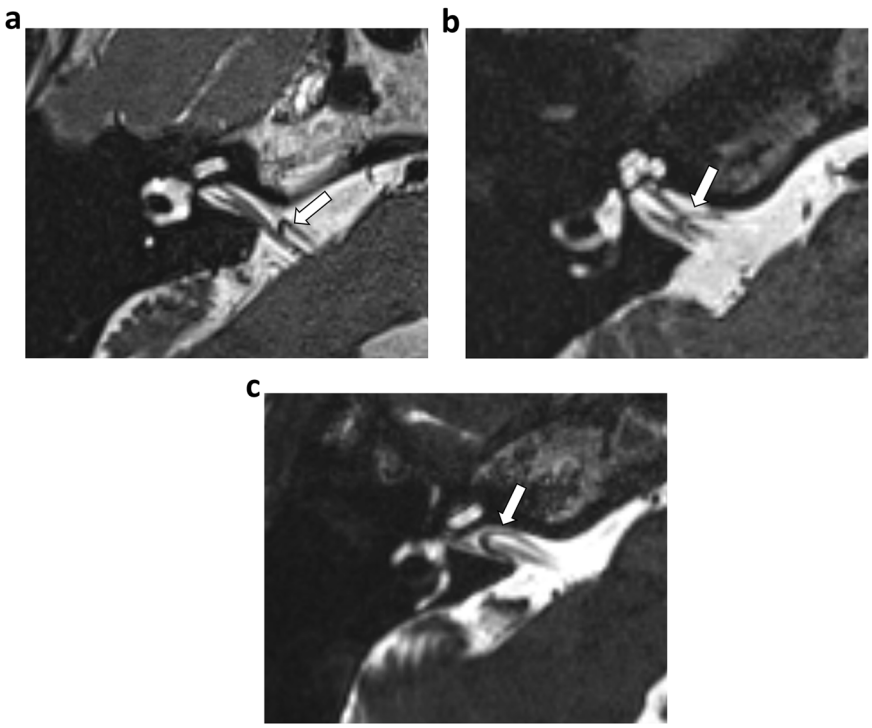

Fig. 2 Image analysis for Chavda classification. Unenhanced axial T2w CISS images demonstrate the Chavda classification. VLs are indicated by white arrows. **a** Chavda I, VL located only in the CPA but not entering the IAM. **b** Chavda II, VL entering but not extending greater than 50% of the length of the IAM. **c** Chavda III, VL extending greater than 50% of the length of the IAM. CISS, constructive interference in steady state; IAM, internal auditory meatus; T2w, T2-weighted; VL, vascular loop

reviewed with standardised magnification and window settings, with scoring and measurements performed bilaterally according to a priori criteria whilst blinded to clinical data.

Imaging criteria and definitions are shown in Table 2. VLs were identified as vascular flow voids communicating with the basilar artery and traversing the ipsilateral cerebellopontine angle (CPA). The location of a CPA/IAM VL was classified according to the Chavda classification, [21]: Chavda I, lying only in the CPA but not entering the IAM; Chavda II, entering but not extending 50% of the length of the IAM; and Chavda III, extending 50% or greater into the IAM (Fig. 2). If more than one CPA/IAM VL communicating with the basilar artery was present, the VL with the higher Chavda classification was utilised for data collection. NVC was identified by the contact of the VL with the vestibulocochlear within the CPA or IAM, or with the cochlear nerve without an intervening normal cerebrospinal fluid signal between structures (Fig. 3).

Loop-fundus distance was measured from the IVL apex to the base of the modiolus on axial images. Loop interlimb distance was proposed as a surrogate measure for

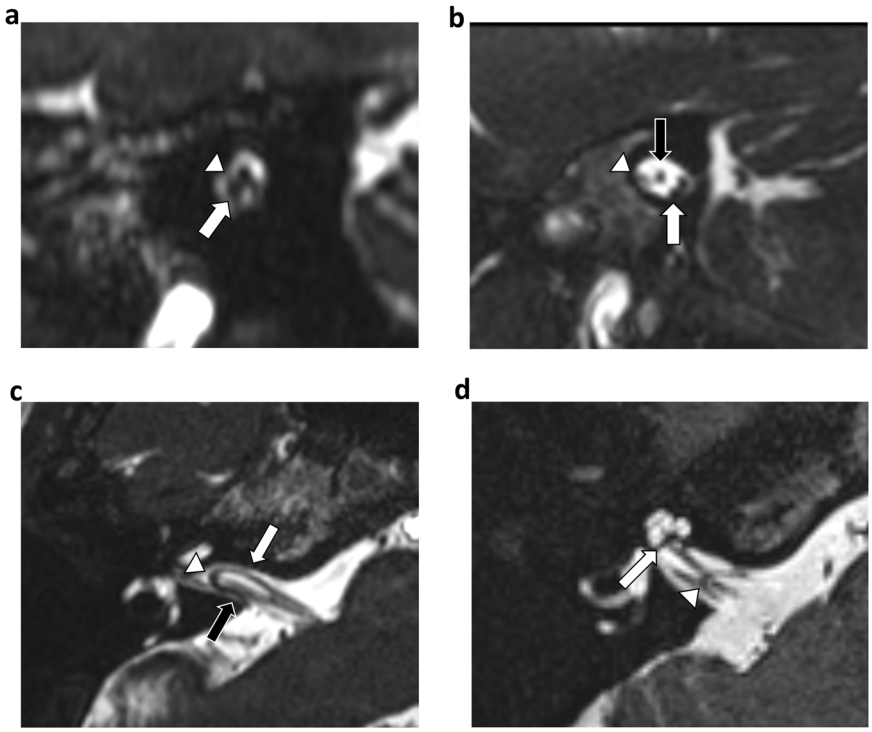

Fig. 3 Image analysis for NVC and continuous variables. **a** NVC (sagittal-oblique reformatted unenhanced T2w CISS image). NVC was identified as contact between the VL and the vestibulocochlear or cochlear nerve within the CPA or IAM without a visible intervening normal cerebrospinal fluid signal. The image shows NVC of an IVL (arrowhead) with the cochlear nerve inferiorly (white arrow). **b** An example of the absence of vestibulocochlear NVC within the IAM (sagittal-oblique reformatted unenhanced T2w CISS image). The IAM VL (arrowhead) is located anterior to the facial nerve (black arrow), with normal intervening cerebrospinal fluid signal separating the VL from the cochlear nerve (white arrow) located postero-inferiorly. **c** Loop interlimb distance (axial unenhanced T2w CISS image). Distance (mm) was measured between the proximal (black arrow) and distal (white arrow) limbs of the VL at 2 mm from the VL apex (arrowhead). **d** Loop-fundus distance (axial unenhanced T2w CISS image). Distance (mm) was measured from the VL apex (arrowhead) to the base of the modiolus (arrow). CISS, constructive interference in steady state; CPA, cerebellopontine angle; IAM, internal auditory meatus; NVC, neurovascular contact; T2w, T2-weighted; VL, vascular loop

IVL angulation and was the measured distance between the proximal and distal limbs of the IVL at a consistent 2 mm distance from the loop apex (Fig. 3).

To assess for NVC at the TZ and CMP of CN8 for ears with CN8 NVC within the CPA/IAM, the distance from each NVC to the CN8 origin at the brainstem was measured on coronal oblique images using multiplanar reformats in the line of CN8, with correlation using the axial and sagittal oblique images. The previous anatomical study by Guclu et al identified the most distal part of the TZ to be located in the range of 9.28–13.84 mm (11.50 ± 1.56 mm) from the brainstem with a TZ depth of up to 1.28 mm [22]. CN8-NVC was therefore recorded as within the TZ for distances between 8.0 and 13.8 mm from the brainstem. CN8-NVC at the combined segment of the CMP and TZ (CMP-TZ segment) was recorded for distances of up to 11.5 mm from the brainstem.

For the categorical variables of Chavda classification and CN8 NVC, consensus was obtained with disagreements reviewed by a third radiologist (S.C., 29 years' experience). For continuous variables of loop-fundus distance and loop interlimb distance, the mean of the two readers' measurements was utilised for statistical analysis.

Statistical analysis

Statistical analysis was performed using SPSS® Statistics 27.0 (IBM®).

The inter-rater reliability of the two observers was evaluated with Cohen's kappa test for the IVL Chavda classification, weighted kappa test for CN8 NVC, and intraclass correlation coefficient (Two-Way Mixed, Absolute) for continuous variables.

McNemar's paired samples compared the presence of IVLs (Chavda II or III classification) and CN8 NVC in symptomatic unilateral PT ears with their contralateral asymptomatic control ears.

The normally distributed mean air conduction thresholds were compared between the symptomatic unilateral PT ears and the contralateral asymptomatic control ears with the independent samples *t*-test.

For ears with IVLs (Chavda II or III classification), the presence of Chavda II v Chavda III classification, the loop-fundus distance, the loop interlimb distance, and patient age were compared between ears with and without PT. Depending on whether the continuous data was normally distributed according to the Shapiro-Wilk's test, these comparisons were performed with the independent samples *t*-test (parametric) or the Mann–Whitney *U*-test (non-parametric). The Chi-squared test of independence was used to compare categorical data.

For the ears with CN8 NVC, the presence or absence of contact at the TZ or CMP-TZ region was compared between ears with PT and ears without PT using the Chi-squared test of independence.

A p value of ≤ 0.05 was considered to represent statistical significance.

Results

Descriptive data of the cohort

631 consecutive patients with PT were referred for investigation with MRI, and the final cohort following application of the exclusion criteria comprised 337 patients with unilateral PT (250 female, 87 male; mean age 47 ± 16 years). Exclusion criteria were patients with bilateral PT ($n = 72$), insufficient detail on lateralisation of PT ($n = 13$), abnormal otoscopy ($n = 19$), alternative medical cause of PT ($n = 5$), alternative cause of PT on imaging ($n = 42$), other significant intracranial/ear pathology, trauma, or surgery ($n = 46$), absent or degraded 3D HR T2w sequences ($n = 36$), air-bone gap on audiometry ($n = 4$), and absent audiometry ($n = 57$) (Fig. 1). The specific exclusions are documented in Supplementary Table 1.

Patient demographics are shown in Table 3. There were 150/674 ears with IVLs and 423/674 ears with CN8 NVC.

Inter-rater reliability

There was 'almost perfect' (> 0.90) [23] level of agreement for IVL Chavda classification (Weighted kappa = 0.91, 95% CI: 0.87–0.94, $p < 0.001$) and a strong (0.80–0.90) level of agreement for CN8 NVC (kappa = 0.88, 95% CI: 0.84–0.91, $p < 0.001$). There was excellent inter-rater reliability for loop-fundus distance (intraclass correlation coefficient = 0.98, 95% CI: 0.96–0.99, $p < 0.001$) and good inter-rater reliability for loop interlimb distance (intraclass correlation coefficient = 0.87, 95% CI: 0.56–0.94, $p < 0.001$) [24].

Table 3 Patient demographics

Characteristic	Value
Number of patients with unilateral PT	$n = 337$
Age (mean ± standard deviation)	47 ± 16 years
Sex	
Male	$n = 87$
Female	$n = 250$
Mean air conduction thresholds in PT ears	$n = 337$; mean 17.2 ± 14.5 dB
Mean air conduction thresholds in asymptomatic ears	$n = 337$; mean 15.7 ± 14.6 dB

MRI findings for VL Chavda classification, CN8 NVC and anatomical variables

The MRI findings for the VL Chavda classification and CN8 NVC in the unilateral symptomatic PT ears, and ears with and without PT, are summarised in Tables 4 and 5. Bar and box plot charts for all variables are shown in Figs. 4 and 5.

IVLs and CN8 NVC in symptomatic PT ears v contralateral asymptomatic control ears

Of the symptomatic unilateral PT ears, there were 272/337 (80.7%, 95% CI: 76.1–84.8%) Chavda I, 55/337 (16.3%, 95% CI: 12.5–20.7%) Chavda II, and 10/337 (3.0%, 95% CI: 1.4–5.4%) Chavda III VLs. In the contralateral asymptomatic control ears, there were 252/337 (74.8%, 95% CI: 69.8–79.3%) Chavda I, 74/337 (22.0%, 95% CI: 17.7–26.8%) Chavda II, and 11/337 (3.3%, 95% CI: 1.6–5.8%) Chavda III VLs.

There was no statistically significant difference ($p = 0.06$) between the proportion of IVLs in PT ears (65/337; 19.3%; 95% CI: 15.2–23.9%) and that in control ears (85/337; 25.2%; 95% CI: 20.7–30.2%). There was also no statistically significant difference ($p = 0.12$) between the proportion of CN8 NVC within the CPA or IAM in PT ears (202/337; 59.9%; 95% CI: 54.5–65.2%) as compared to control ears (221/337; 65.6%; 95% CI: 60.2–70.6%).

There was no difference in the mean air conduction thresholds between PT ears (mean 17.2 ± 14.5 dB) and the control ears (mean 15.7 ± 14.6 dB) ($p = 0.17$).

Associations of anatomical variables of IVLs and patient age with PT

In ears with IVLs, the presence of PT was not influenced by the depth of the IVL according to the Chavda classification (Chavda II v Chavda III; $\chi2(1) = 0.183$; $p = 0.67$) or when evaluated by the distance from the IVL apex to the base of the modiolus (median 6.5 mm [IQR 5.1–8.0] with PT; 6.8 mm [IQR 5.4–7.8] without PT; $p = 0.45$). There was no significant difference in the IVL interlimb distance ($p = 0.54$) between ears with PT (3.1 mm [IQR 2.6–4.1]) and without PT (3.3 mm [IQR 2.5–4.4]). There was also no association between patient age and the presence of PT in ears with IVLs (median age 43 years

Table 4 Chavda classification of VLs for unilateral PT ears and contralateral asymptomatic control ears

Imaging criterion	Unilateral PT ears	Contralateral asymptomatic control ears
Chavda I VL	272/337 (80.7%; 95% CI: 76.1–84.8%)	252/337 (74.8%; 95% CI: 69.8–79.3%)
Chavda II VL	55/337 (16.3%; 95% CI: 12.5–20.7%)	74/337 (22.0%; 95% CI: 17.7–26.8%)
Chavda III VL	10/337 (3.0%; 95% CI: 1.4–5.4%)	11/337 (3.3%; 95% CI: 1.6–5.8%)

CN8 vestibulocochlear nerve, *IAM,* internal auditory meatus, *IVL* IAM vascular loop, *NVC* neurovascular contact, *PT* pulsatile tinnitus, *VL* vascular loop

Table 5 Proportion of IVLs and CN8 NVCs for unilateral PT ears and contralateral asymptomatic control ears

Imaging criterion	Unilateral PT ears	Contralateral asymptomatic control ears	*p* value
IVL present (Chavda II or Chavda III VL)	65/337 (19.3%; 95% CI: 15.2–23.9%)	85/337 (25.2%; 95% CI: 20.7–30.2%)	0.06
CN8 NVC present	202/337 (59.9%; 95% CI: 54.5–65.2%)	221/337 (65.6%; 95% CI: 60.2–70.6%)	0.12

CN8 vestibulocochlear nerve, *IAM* internal auditory meatus, *IVL* IAM vascular loop, *NVC* neurovascular contact, *PT* pulsatile tinnitus, *VL* vascular loop

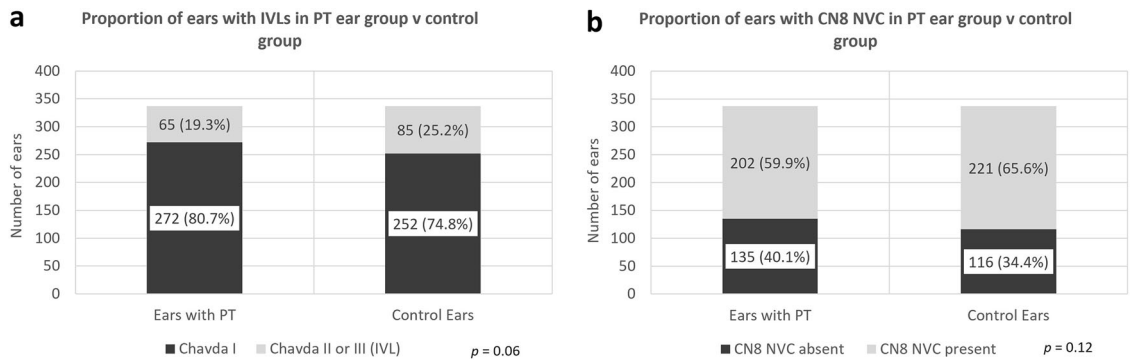

Fig. 4 Proportion of ears with IVLs and CN8 NVC in PT ears v controls. **a** IVLs in symptomatic PT ears v contralateral asymptomatic control ears. No significant association was demonstrated between the prevalence of ipsilateral IVLs and PT ($p = 0.06$). **b** CN8 NVC in symptomatic PT ears v contralateral asymptomatic control ears. No significant association was demonstrated between the presence of ipsilateral CN8 NVC and PT ($p = 0.12$). Lower proportions of PT ears were associated with IVLs and CN8 NVCs as compared to the contralateral control ears, however, these did not reach statistical significance. CN8, vestibulocochlear nerve; IAM, internal auditory meatus; IVL, IAM vascular loop; NVC, neurovascular contact; PT, pulsatile tinnitus; VL, vascular loop

[IQR 31–56] with PT; 43 years [IQR 32–54] without PT ($p = 0.97$).

Associations of NVC at the TZ or CMP-TZ region and PT in the ears with CN8 NVC

On analysis of the ears with CN8 NVC, there were 143/202 (70.8%; 95% CI: 64.0–77.0%) cases with CN8 NVC at the TZ in ears with PT and 151/221 (68.3%; 95% CI: 61.8–74.4%) cases in ears without PT. There were 166/202 (82.2%; 95% CI: 76.2–87.2%) cases with CN8 NVC at the CMP-TZ segment in ears with PT, and 190/221 (86.0%; 95% CI: 80.7–90.3%) cases in ears without PT. The presence of PT was not influenced by whether or not CN8-NVC was located at the TZ ($\chi 2(1) = 0.303$; $p = 0.58$) or whether or not it was located in the central myelinated portion or transition zone (CMP-TZ) segment ($\chi 2(1) = 1.140$; $p = 0.29$).

Discussion

The proportion of ears with IVLs ($p = 0.06$) or vestibulocochlear NVC ($p = 0.12$) did not significantly differ between 337 unexplained PT ears and their contralateral asymptomatic control ears. In ears with IVLs, the presence of PT was not associated with the depth of the VL, as indicated by a Chavda classification III ($p = 0.67$) or the distance of the VL to the fundus of the IAM ($p = 0.45$). Moreover, the angulation of the IVLs, as evaluated by the distance between the two limbs of the VL ($p = 0.54$) was not associated with the presence of PT. In ears with CN8-NVC, the presence of PT was not affected by whether or not the contact was located at the TZ ($p = 0.58$) or within the combined CMP-TZ segment ($p = 0.29$).

Most previous case-controlled studies analysing the presence of IVLs and CN8 NVC have included cohorts of

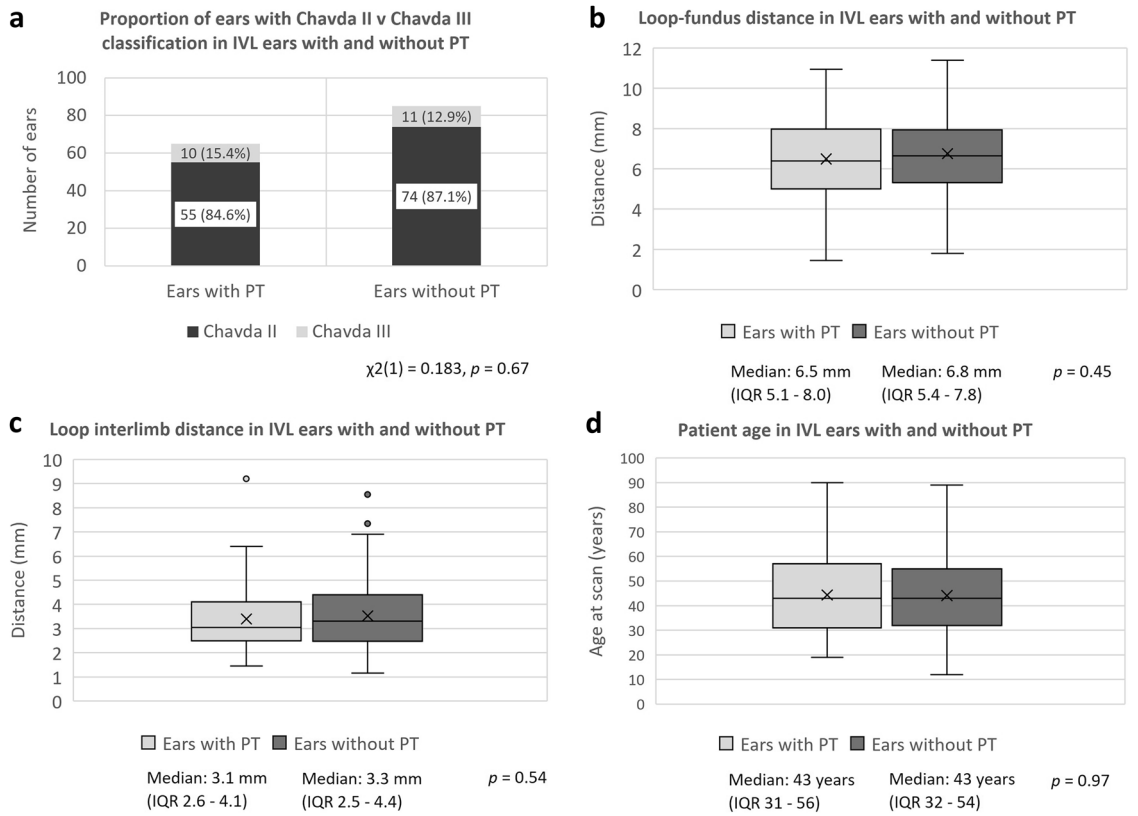

Fig. 5 Loop-fundus distance, loop angulation and patient age in IVL ears with and without PT. **a** Proportion of ears with Chavda II v Chavda III in IVL ears with and without PT. There was no difference in the incidence of PT in Chavda II when compared to Chavda III VLs ($p = 0.67$). **b** Loop-fundus distance in IVL ears with and without PT. There was no difference in the loop-fundus distance between ears with PT (median 6.5 mm, IQR 5.1–8.0 mm) and those without PT (median 6.8 mm, IQR 5.4–7.8 mm) ($p = 0.45$). **c** Loop interlimb distance in IVL ears with and without PT. There was no difference in the loop interlimb distance between ears with PT (median 3.1 mm, IQR 2.6–4.1) and those without PT (median 3.3 mm, IQR 2.5–4.4) ($p = 0.54$). **d** Age at scan and PT. There was no difference between the median patient age in ears with PT (median 43 years, IQR 31–56) and those without PT (median 43 years, IQR 32–54) ($p = 0.97$). CN8, vestibulocochlear nerve; IAM, internal auditory meatus; IVL, IAM vascular loop; NVC, neurovascular contact; PT, pulsatile tinnitus; VL, vascular loop

undefined tinnitus that have not distinguished between PT and non-PT ears. These have largely demonstrated no association between either IVLs [13, 16, 18] or CN8 NVC [16, 18, 19] and the presence of tinnitus. A single study showed a significant association between these undefined tinnitus ears and IVLs [13], whilst another reported an association with CN8 NVC [25]. A recent meta-analysis of pooled data from case-controlled studies demonstrated no statistically significant association between the presence of undefined tinnitus and that of IVL (OR 0.90 95% CI: 0.47–1.70) or CN8 NVC (OR 1.15, 95% CI: 0.68–1.95) ($p > 0.05$) [15]. PT ears alone have only been investigated in two previous small studies without asymptomatic control groups. De Ridder et al demonstrated IVLs to be significantly more frequent in 17 unilateral PT ears than in 43 with non-PT [9], whereas Nowé et al found a similar result in their study of 12 PT ears and 46 ears with non-PT [10]. This data was subject to meta-analysis [26] and the authors concluded that contacting VLs were 80 times more frequent in PT compared to non-PT, suggesting a causal relationship and the potential for surgical intervention in some cases. As a result, an IVL continues to be proposed as an aetiology for PT in contemporary imaging guidelines [27, 28]. Our study is the first to investigate the relationship between PT and IVLs or CN8 NVC in a large cohort of PT ears with an asymptomatic control ear group and has shown no association. Whilst it may remain justified to include a 3D HR T2w sequence with PT imaging protocols to identify other aetiologies for PT within the IAM and labyrinth, the present study argues that IVLs and CN8 NVC should not be analysed, reported, or identified as a therapeutic target in the context of PT.

None of the IVL anatomical features investigated were shown to influence the likelihood of PT. De Ridder et al proposed that PT results from pulsatile sound waves being conducted from the VL through the cerebrospinal fluid of

the IAM and perineural spaces to the cochlea, which prompted our analysis of the depth of the IVL within the IAM and hence its proximity to the cochlea. Similarly, it has been argued that a sharper turn of the VL may result in greater turbulence and sound transmission [9], and our measurement of the interlimb distance was a surrogate for this angulation. Moreover, it was speculated that VLs may become more tortuous or narrowed with age, however, no association was demonstrated between increasing age and the likelihood of PT symptoms in IVL ears. Other anatomical features of VLs have been explored as potential correlates for PT in previous studies with variable outcomes. Yoo et al demonstrated a relationship between the calibre of an IVL and unspecified tinnitus [13] whilst the CN8 NVC topographic relationship [10, 29] and associated neural distortion [30] have also been proposed as significant anatomical features to analyse.

There are limitations to the present study. Firstly, there was an innate bias in patient selection introduced by the case-controlled study design [31]. Secondly, it would have been optimal to exclude ears with venous variants since they are recognised as a potential aetiology of PT, however, they are inconsistently defined in the literature and some variants are difficult to identify without CT [32]. An alternative approach would have been the exclusion of patients with symptoms and signs of "venous" PT; however, this was precluded by insufficient clinical details. Thirdly, the exclusion of bilateral PT ears may introduce selection bias and limit the applicability of this patient group, however, the inclusion of a matched asymptomatic control ear in unilateral PT may also be considered a strength of the study design. Finally, the study would have benefited from a prior power analysis to ensure that the sample size was sufficient to demonstrate any association between PT and IVL or CN8 NVC and reduce type II error, however, the retrospective study design did not allow us to control the number of ears included. Although criticised as a method for interpreting negative study findings [33], a post-hoc power analysis determined the study to have 78% power for detecting an increase in the incidence of IVL or CN8 NVC by 10% if the incidence in asymptomatic ears was considered to be 30% ($\alpha = 0.05$). A power value of $>80\%$ is frequently considered sufficient for the determination of the actual effects of research studies.

In conclusion, our data indicate that the presence of an IAM VL or of vestibulocochlear NVC is no more frequent in ears with unexplained unilateral PT than in contralateral asymptomatic ears. In addition, the likelihood of PT was not influenced by the distance of the IAM VL from the IAM fundus or by the angulation of the IAM VL, and PT was no more prevalent if CN8-NVC was located within the TZ or CMP-TZ segments. This would argue against the analysis and reporting of IAM VLs or vestibulocochlear NVC in the context of PT, and it gives the clinician confidence to reassure the patient that these are unlikely to be an aetiology of PT.

Abbreviations

3D HR	Three-dimensional high resolution
CISS	Constructive interference in steady state
CMP	Central myelin portion
CN8	Vestibulocochlear nerve
CPA	Cerebellopontine angle
IAM	Internal auditory meatus
IVL	Internal auditory meatus vascular loop
NVC	Neurovascular contact
PT	Pulsatile tinnitus
T2w	T2-weighted
TZ	Transition zone
VL	Vascular loop

Supplementary information

The online version contains supplementary material available at https://doi.org/10.1007/s00330-025-11660-8.

Funding

Authors acknowledge funding support from Wellcome/Engineering and Physical Sciences Research Council Centre for Medical Engineering at King's College London (WT 203148/Z/16/Z); National Institute for Health Research Biomedical Research Centre at Guy's & St Thomas' Hospitals and King's College London; Cancer Research UK National Cancer Imaging Translational Accelerator (A27066); the UK Research & Innovation London Medical Imaging and Artificial Intelligence Centre. For the purpose of open access, the author has applied a CC BY public copyright licence to any Author Accepted Manuscript version arising from this submission.

Compliance with ethical standards

Guarantor

The scientific guarantor of this publication is Dr Steve E. J. Connor.

Conflict of interest

S.E.J.C. is a member of the Advisory Editorial Board of *European Radiology* (European Society of Head and Neck Radiology). As such, they did not participate in the selection or review processes for this article. The remaining authors of this manuscript declare no relationships with any companies, whose products or services may be related to the subject matter of the article.

Statistics and biometry

One of the authors has significant statistical expertise.

Informed consent

Written informed consent was waived by the Institutional Review Board.

Ethical approval

Institutional Review Board approval was obtained.

Study subjects or cohorts overlap

No study subjects or cohorts have been previously reported.

Methodology

- Retrospective
- Case-control study
- Performed at one institution

Author details
[1]Department of Radiology, St Bartholomew's Hospital and Royal London Hospital, Barts Health NHS Trust, London, UK. [2]Department of Radiology, Guy's Hospital and St Thomas' Hospital, London, UK. [3]Faculty of Life Sciences and Medicine, King's College London, London, UK. [4]School of Biomedical Engineering and Imaging Sciences, King's College London, London, UK. [5]Department of Ear, Nose and Throat Surgery, Guy's Hospital and St Thomas' Hospital, London, UK. [6]Department of Neuroradiology, King's College Hospital, London, UK.

Received: 1 January 2025 Revised: 14 March 2025 Accepted: 12 April 2025
Published online: 12 May 2025

References

1. Baguley D, McFerran D, Hall D (2013) Tinnitus. Lancet 382:1600–1607. https://doi.org/10.1016/S0140-6736(13)60142-7
2. Kircher ML, Leonetti JP, Marzo SJ, Standring B (2008) Neuroradiologic assessment of pulsatile tinnitus. Otolaryngol Neck Surg. https://doi.org/10.1016/j.otohns.2008.05.380
3. Liyanage SH, Singh A, Savundra P, Kalan A (2006) Pulsatile tinnitus. J Laryngol Otol 120:93–97. https://doi.org/10.1017/S0022215105001714
4. Madani G, Connor SEJ (2009) Imaging in pulsatile tinnitus. Clin Radiol 64:319–328. https://doi.org/10.1016/j.crad.2008.08.014
5. Dietz RR, Davis WL, Harnsberger HR, Jacobs JM, Blatter DD (1994) MR imaging and MR angiography in the evaluation of pulsatile tinnitus. AJNR Am J Neuroradiol 15:879–889
6. Sismanis A (1998) Pulsatile tinnitus. A 15-year experience. Am J Otol 19:472–477
7. Sonmez G, Basekim CC, Ozturk E, Gungor A, Kizilkaya E (2007) Imaging of pulsatile tinnitus: a review of 74 patients. Clin Imaging 31:102–108. https://doi.org/10.1016/j.clinimag.2006.12.024
8. National Institute of Health and Care Excellence (NICE) (2020) Tinnitus: assessment and management (NICE Guideline, No. 155). Available via https://www.ncbi.nlm.nih.gov/books/NBK557037/. Accessed 14 Oct 2024
9. De Ridder D, De Ridder L, Nowé V, Thierens H, Van de Heyning P, Møller A (2005) Pulsatile tinnitus and the intrameatal vascular loop: Why do we not hear our carotids?. Neurosurgery 57:1213–1217. https://doi.org/10.1227/01.NEU.0000186035.73828.34
10. Nowé V, De Ridder D, Van de Heyning PH et al (2004) Does the location of a vascular loop in the cerebellopontine angle explain pulsatile and non-pulsatile tinnitus?. Eur Radiol 14:2282–2289. https://doi.org/10.1007/s00330-004-2450-x
11. Haller S, Etienne L, Kövari E, Varoquaux AD, Urbach H, Becker M (2016) Imaging of neurovascular compression syndromes: trigeminal neuralgia, hemifacial spasm, vestibular paroxysmia, and glossopharyngeal neuralgia. AJNR Am J Neuroradiol 37:1384–1392. https://doi.org/10.3174/ajnr.A4683
12. Applebaum EL, Valvasorri G (1985) Internal auditory canal vascular loops: audiometric and vestibular system findings. Am J Otol Suppl:110–113
13. Yoo HS, Lee DW, Min HJ, Lee SH, Park CW (2011) The association of anterior inferior cerebellar artery in internal auditory canal with tinnitus and hearing loss. Korean J Audiol 15:67–71
14. Makins AE, Nikolopoulos TP, Ludman C, O'Donoghue GM (1998) Is there a correlation between vascular loops and unilateral auditory symptoms?. Laryngoscope 108:1739–1742. https://doi.org/10.1097/00005537-199811000-00027
15. Cowen JE, Tehrani MS, Connor SE (2024) The association of vascular loops within the internal auditory meatus or contacting the vestibulo-cochlear nerve with audio-vestibular symptoms. A systematic review and meta-analysis. AJNR Am J Neuroradiol. https://doi.org/10.3174/ajnr.A8486
16. Gultekin S, Celik H, Akpek S, Oner Y, Gumus T, Tokgoz N (2008) Vascular loops at the cerebellopontine angle: Is there a correlation with tinnitus?. AJNR Am J Neuroradiol 29:1746–1749. https://doi.org/10.3174/ajnr.A1212
17. Saraf A, Gupta N, Manhas M, Kalsotra P (2022) Anterior inferior cerebellar artery loop and tinnitus—Is there any association between them?. Egypt J Otolaryngol 38:171. https://doi.org/10.1186/s43163-022-00369-w
18. Zidan MA, Almansor N (2020) Presence of vascular loop in patients with audio-vestibular symptoms: is it a significant finding? Evaluation with 3-tesla MRI 3D constructive interference steady state (CISS) sequence. Egypt J Radiol Nucl Med 51:114. https://doi.org/10.1186/s43055-020-00238-7
19. Peters TTA, van den Berge MJC, Free RH et al (2020) The relation between tinnitus and a neurovascular conflict of the cochleovestibular nerve on magnetic resonance imaging. Otol Neurotol 41:e124–e131. https://doi.org/10.1097/MAO.0000000000002432
20. British Academy of Audiology (2023) Onward referral guidance for adult audiology service users. Available via https://www.baaudiology.org/app/uploads/2023/04/Onward-Referral-Guidance-for-Adult-Audiology-Service-Users-Sept-23.pdf. Accessed 14 Oct 2024
21. Mcdermott A-L, Dutt SN, Irving RM, Pahor AL, Chavda SV (2003) Anterior inferior cerebellar artery syndrome: fact or fiction. Clin Otolaryngol Allied Sci 28:75–80. https://doi.org/10.1046/j.1365-2273.2003.00662.x
22. Guclu B, Sindou M, Meyronet D, Streichenberger N, Simon E, Mertens P (2012) Anatomical study of the central myelin portion and transitional zone of the vestibulocochlear nerve. Acta Neurochir (Wien) 154:2277–2283. https://doi.org/10.1007/s00701-012-1479-x
23. McHugh ML (2012) Interrater reliability: the kappa statistic. Biochem Med (Zagreb) 22:276–282
24. Koo TK, Li MY (2016) A guideline of selecting and reporting intraclass correlation coefficients for reliability research. J Chiropr Med 15:155–163. https://doi.org/10.1016/j.jcm.2016.02.012
25. Di Stadio A, Dipietro L, Ralli M et al (2020) Loop characteristics and audio-vestibular symptoms or hemifacial spasm: is there a correlation? A multiplanar MRI study. Eur Radiol 30:99–109. https://doi.org/10.1007/s00330-019-06309-2
26. Chadha NK, Weiner GM (2008) Vascular loops causing otological symptoms: a systematic review and meta-analysis. Clin Otolaryngol 33:5–11. https://doi.org/10.1111/j.1749-4486.2007.01597.x
27. Pegge SAH, Steens SCA, Kunst HPM, Meijer FJA (2017) Pulsatile tinnitus: differential diagnosis and radiological work-up. Curr Radiol Rep 5:5. https://doi.org/10.1007/s40134-017-0199-7
28. Vattoth S, Shah R, Curé JK (2010) A compartment-based approach for the imaging evaluation of tinnitus. AJNR Am J Neuroradiol 31:211–218. https://doi.org/10.3174/ajnr.A1704
29. Ryu H, Yamamoto S, Sugiyama K, Nishizawa S, Nozue M (1999) Neurovascular compression syndrome of the eighth cranial nerve. Can the site of compression explain the symptoms?. Acta Neurochir 141:495–501. https://doi.org/10.1007/s007010050330
30. Gorrie A, Warren FM 3rd, de la Garza AN, Shelton C, Wiggins RH 3rd (2010) Is there a correlation between vascular loops in the cerebellopontine angle and unexplained unilateral hearing loss?. Otol Neurotol 31:48–52. https://doi.org/10.1097/MAO.0b013e3181c0e63a
31. Lijmer JG (1999) Empirical evidence of design-related bias in studies of diagnostic tests. JAMA 282:1061. https://doi.org/10.1001/jama.282.11.1061
32. Dong C, Zhao PF, Yang JG, Liu ZH, Wang ZC (2015) Incidence of vascular anomalies and variants associated with unilateral venous pulsatile tinnitus in 242 patients based on dual-phase contrast-enhanced computed tomography. Chin Med J 128:581. https://doi.org/10.4103/0366-6999.151648
33. Levine M, Ensom MH (2001) Post hoc power analysis: An idea whose time has passed?. Pharmacotherapy 21:405–409. https://doi.org/10.1592/phco.21.5.405.34503

Publisher's Note

Springer Nature remains neutral with regard to jurisdictional claims in published maps and institutional affiliations.