

Case Report

Interhemispheric Pediatric Meningioma, *YAP1* Fusion-Positive

Silvia Esposito ^{1,*}, Gianluca Marucci ², Manila Antonelli ³, Evelina Miele ⁴, Piergiorgio Modena ⁵,
Marzia Giagnacovo ⁵, Maura Massimino ⁶, Veronica Biassoni ⁶, Matilde Taddei ¹, Marco Paolo Schiariti ⁷,
Fabio Martino Doniselli ⁸, Marco Moscatelli ⁸, Luisa Chiapparini ^{8,9} and Bianca Pollo ²

- ¹ Pediatric Neuroscience Department, Fondazione IRCCS Istituto Neurologico Carlo Besta, 20133 Milan, Italy
 - ² Neuropathology Unit, Fondazione IRCCS Istituto Neurologico Carlo Besta, 20133 Milan, Italy
 - ³ Department of Radiological, Oncological and Anatomic-Pathological Sciences, Sapienza University, 00185 Rome, Italy
 - ⁴ Department of Pediatric Onco-Hematology and Cell and Gene Therapy, Bambino Gesù Children's Hospital, IRCCS, 00165 Rome, Italy
 - ⁵ Genetics Unit, ASST Lariana General Hospital, 22100 Como, Italy
 - ⁶ Pediatric Oncology Unit, Fondazione IRCCS Istituto Nazionale Tumori, 20133 Milan, Italy
 - ⁷ Department of Neurosurgery, Fondazione IRCCS Istituto Neurologico Carlo Besta, 20133 Milan, Italy
 - ⁸ Department of Neuroradiology, Fondazione IRCCS Istituto Neurologico Carlo Besta, 20133 Milan, Italy
 - ⁹ Department of Diagnostic Radiology and Neuroradiology, Fondazione IRCCS Policlinico San Matteo, 27100 Pavia, Italy
- * Correspondence: silvia.esposito@istituto-besta.it; Tel.: +39-0223942215



Citation: Esposito, S.; Marucci, G.; Antonelli, M.; Miele, E.; Modena, P.; Giagnacovo, M.; Massimino, M.; Biassoni, V.; Taddei, M.; Schiariti, M.P.; et al. Interhemispheric Pediatric Meningioma, *YAP1* Fusion-Positive. *Diagnostics* **2022**, *12*, 2367. <https://doi.org/10.3390/diagnostics12102367>

Academic Editor:
Theodosios Kalamatianos

Received: 8 September 2022
Accepted: 28 September 2022
Published: 29 September 2022

Publisher's Note: MDPI stays neutral with regard to jurisdictional claims in published maps and institutional affiliations.



Copyright: © 2022 by the authors. Licensee MDPI, Basel, Switzerland. This article is an open access article distributed under the terms and conditions of the Creative Commons Attribution (CC BY) license (<https://creativecommons.org/licenses/by/4.0/>).

Abstract: Meningiomas are uncommon in children and usually arise in the context of tumor-predisposing syndromes. Recently, *YAP1*-fusions have been identified for the first time as potential *NF2*-independent oncogenic drivers in the development of meningiomas in pediatric patients. We report a case of a *YAP1*-fusion-positive atypical meningioma in a young child and compare it with the previous ones reported. Extending the clinico-pathological features of *YAP1*-fused meningiomas, we suggest additional clues for diagnosis and emphasize the urgent need for an integrated multilayered diagnostic approach, combining data from histological and molecular analyses, neuroradiology, and clinical findings.

Keywords: *YAP1*-fusion; pediatric meningioma; interhemispheric meningioma; methylation profile

1. Introduction

Meningiomas are very common primary central nervous system tumors in adulthood, accounting for approximately 35% of all primary intracranial neoplasms, but are relatively rare in pediatric populations, comprising 0.4–4.6% of all pediatric brain tumors [1].

Pediatric meningiomas show unique features compared to their adult counterparts, both histologically and clinically (considering gender and site distribution) [2,3]. These lesions often occur in the context of tumor-predisposing syndromes, such as neurofibromatosis type 2 (NF2), schwannomatosis and multiple endocrine neoplasia type 1, of which NF2 is the most common [4].

However, the mutational spectrum of childhood sporadic meningiomas remains elusive to date: integrated genomic analyses have revealed a clonal predominance of the somatic *NF2* gene, confirming its crucial role in meningioma tumorigenesis, and some recurrent gene fusions in biologically relevant genes not well described up until now [3].

Recently, *YAP1* fusions have been identified for the first time as a potential *NF2*-independent oncogenic driver in the development of meningiomas predominantly in pediatric patients. To the best of our knowledge, only 10 *YAP1*-fusion pediatric meningiomas have been reported to date [5,6]. This report presents another case of a *YAP1*-fusion-positive atypical meningioma in a young child, suggesting additional clues for diagnosis and comparing it with the previous ones reported.

2. Case Report

A two-year-old child presented with two episodes of prolonged generalized seizures, expression of subcontinuous paramedian epileptiform activity. Brain magnetic resonance imaging (MRI) revealed a round solid mass with homogeneous enhancement located in the frontal interhemispheric space, tightly adherent to the anterior cerebral arteries, without evidence of leptomeningeal dissemination (approximate volume 9000 mm³, Figure 1b–d). No calcifications inside the tumor were detected on computed tomography (CT) images (Figure 1a). Minimal peripheral vasogenic edema was evident in frontal white matter. The mass was subtotally surgically removed, with minimal residual lesion attached to the walls of the anterior cerebral arteries. Postsurgical regularization of electroencephalographic signals and consequent seizure control were achieved.

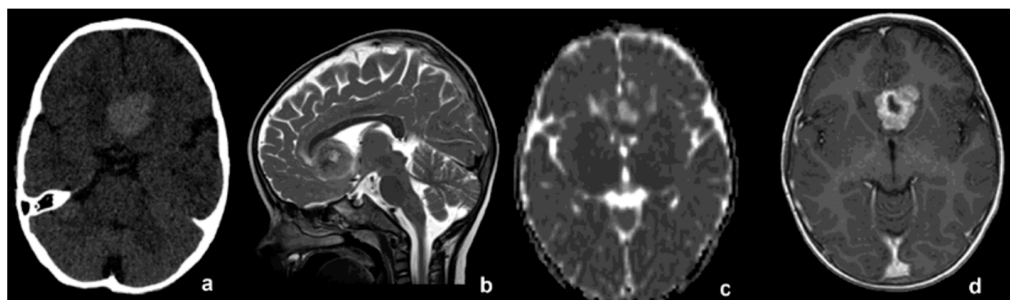


Figure 1. (a) CT without contrast medium, showing midline spontaneous hyperdense lesion. (b) T2-wi, (c) ADC map and (d) T1-wi after contrast medium. Pre-operative MRI showing close adhesion to anterior cerebral arteries.

Microscopic examination revealed a cellular neoplasm, constituted of intersecting fascicles of atypical spindle cells, alternating with hypocellular fibrous nodules of dense collagenous tissue, and some areas characterized by discohesive rhabdoid-like elements (Figure 2a,b). The tumor cells showed mitotic activity (4 mitoses \times 10 high power fields) and a proliferation label index ranging from 10% to 15%. The tumor cells invaded the brain tissue (Figure 2c). Immunohistochemical investigations did not provide a decisive immunoprofile, therefore methylation analysis of the tumor sample was performed.

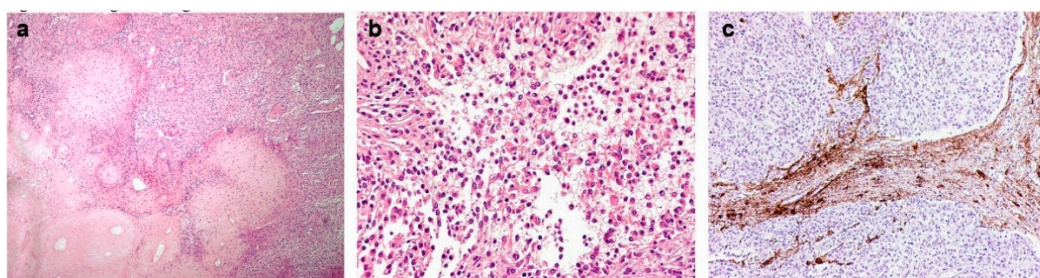


Figure 2. (a) The tumor was composed of cellular intersecting fascicles of spindle cells, alternating with hypo-cellular fibrous nodules of dense collagenous tissue (H&E, magnification 100 \times). (b) Some areas of rhabdoid cells were present (H&E, magnification 200 \times). (c) Immunohistochemistry for GFAP evidencing brain invasion (magnification 100 \times).

The methylation data of the tumor were categorized using the brain tumor classifier v11b4 and v12.5 (<https://www.moleculareuropathology.org/mnp/>, accessed on 7 June 2022) [7], which also generated a copy number variation (CNV) plot. The tumor clustered in the class meningioma with a 0.54 raw score (Supporting Information, Figure S1A) and optimal calibrated score (0.99), and as meningioma benign 3 (MNG_BEN_3) according to the v12.5 classifier (Supporting Information, Table S1). CNV analysis showed a possible gene rearrangement on chromosome 11q involving a region encoding for, among others,

MAML2 and *YAP1* (Figure 3) and a possible rearrangement on chromosome 22 not involving *NF2* gene (Figures 3 and S1C, Supporting Information and Appendix A).

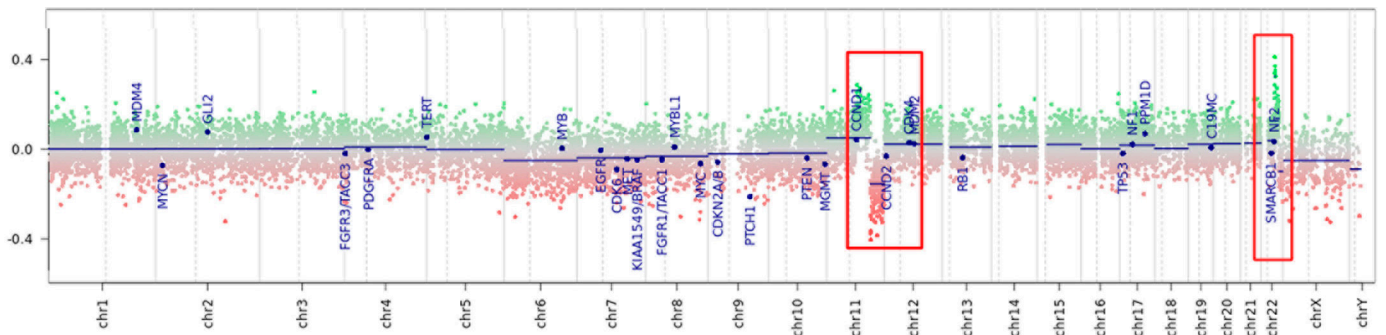


Figure 3. Copy number variation plot calculated from DNA methylation array data of the tumor sample. Depiction of structural rearrangements involving autosomes and X/Y chromosomes. Gains/amplifications represent positive (green), losses represent negative (red) deviations from the baseline. Twenty-nine tumor-relevant genomic regions are highlighted. Red boxes point out the rearranged region on chromosome 11q and on chromosome 22q (detailed in Supporting Information).

Therefore, a neoplastic fresh-frozen specimen was submitted to array-CGH investigation, revealing a complex chromosomal rearrangement of *YAP1-MAML2*, confirmed on RNA sequencing, suggestive for a chromothripsis event (Figure 4). Even with no familial history of signs and symptoms related to tumor-predisposing syndromes, genetic investigations (MLPA and NGS) were performed to rule out constitutional mutations in *NF2* and *SMARCB1* genes. The integrated diagnosis, combining biomolecular and histological findings, was that of *NF2* unrelated, sporadic, atypical meningioma (Appendix A).

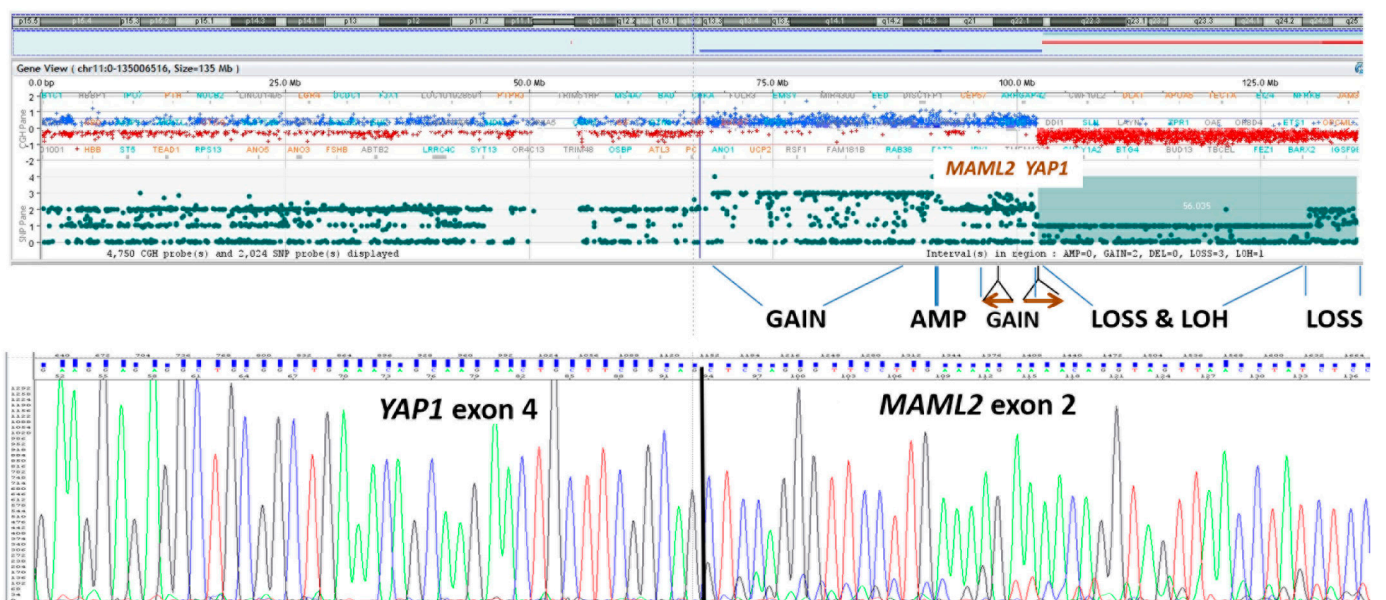

Figure 4. Array-CGH profile of chromosome 11, showing evidence of chromothripsis with breakpoints located at *YAP1* and *MAML2* gene loci. Sanger sequencing electropherogram demonstrating the presence of *YAP1*/*MAML2* fusion transcript from tumor RNA.

At the first stabilized post-surgical MRI, three months after surgery, subtotal excision was confirmed (approximately volume 400 mm³, Figure 5a). At the one-year follow-up, radiological relapse was seen (approximately 700 mm³, Figure 5b), associated with electroencephalographic worsening. Owing to residual progression which was unmanageable

with surgery, the site of the disease, and the histological findings consistent with atypical meningioma (grade 2 WHO 2021 CNS5), proton beam irradiation was proposed.

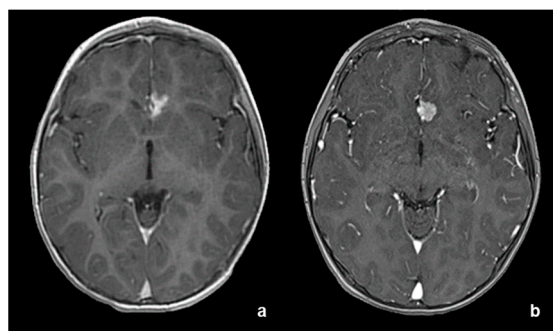


Figure 5. (a) Post-operative MRI at three months revealing minimal residual tumor and subsequent relapse at one-year follow-up (b).

3. Discussion

We report another case of a *YAP1*-fusion-positive atypical meningioma in a young child, after the original papers by Sievers [5] and Schieffers [6] in which *YAP1*-fusions were identified for the first time in 9/102 (8.8%) and 2/12 (16%) cases, respectively, as potential *NF2*-independent oncogenic drivers in the development of meningiomas, predominantly in pediatric patients (10/11 cases under 21 years of age).

Immunophenotypic features of such cases are not straightforward: some of the previous reported cases were initially diagnosed as pleomorphic xanthoastrocytoma or pediatric high-grade glioma [5], and our case required methylation profile analysis. As shown in Figure 2a, our case showed cellular intersecting fascicles of spindle cells, alternating with hypocellular fibrous nodules of dense collagenous tissue, sharing these features with case #1 from the study by Schieffer et al. [6]. Furthermore, in our case some areas of rhabdoid cells were present (Figure 2b), a feature observed in two out of the nine *YAP1*-fusions in pediatric *NF2*-wildtype meningioma reported by Sievers et al. [5]. Such morphological clues, when observed in pediatric meningiomas, might be considered suspicious for a *YAP1*-fusion-positive pathway.

NF2 tumor suppressor gene is an upstream negative regulator of the Salvador–Warts–Hippo pathway, an evolutionary conserved kinase cascade converging to *YAP/TAZ* transcriptional coactivators, and a fascinating pathway potentially regulating several hallmarks in most solid cancers [8]. *YAP1* is a transcriptional co-activator and downstream effector of the Hippo pathway, and acts through TEAD transcription factors, regulating pro-survival and pro-proliferative transcriptional programs. *YAP1* activation could be promoted by loss-of-function mutations in core Hippo pathway upstream regulators, such as *NF2*, or mutations in genes encoding proteins that can impact the core Hippo signaling pathway. In contrast, while activating point mutations in the *YAP1* coding sequence are rare, recurrent *YAP1* fusion events have been identified in several subtypes of cancers [9].

YAP activation and subsequent deregulation of the Hippo pathway is a key mechanism in pediatric meningioma tumorigenesis; somatic *NF2* gene mutations remain predominant but recent advances identify *YAP1* fusions as potential *NF2*-independent alternative oncogenic drivers in these tumors [5].

YAP1-fusion meningiomas have been rarely reported, with 11 cases described to date, 10 of which were in patients under 21 years of age. The majority of these patients, including our case, harbored *YAP1-MAML2*, with the remaining four patients harboring *YAP1-PYGO1*, *YAP1-LMO1* and *YAP1-FAM118B*. No significant correlations with age, sex and WHO grade may be evidenced in this small patient cohort (Table 1). However, our case and 3 of the 10 patients reported in the previous series (30%) were atypical meningiomas, a quite high percentage, suggesting a negative prognostic inference of *YAP1* alterations which must be confirmed in a larger series.

Table 1. Clinico-pathological features of reported pediatric patients with *YAP1*-fusion-positive meningioma.

Case	Age (Years)	Sex	Tumor Location	MNG WHO Grade	Genetic Alteration
Present case 1	2	M	Frontal interhemispheric space	II	YAP1-MAML2
Sievers et al. [5]					
2	4	F	Lateral ventricles, third ventricle	II	YAP1:MAML2
3	3	M	Temporal	I	YAP1:PYGO1
4	1	M	Third ventricle, lateral ventricle	NA	YAP1:MAML2
5	2	M	Skull base	NA	YAP1:MAML2
6	8	F	Skull base	I	YAP1:LMO1
7	17	M	Cavernous sinus	I	YAP1:MAML2
8	7	F	Parietal	NA	YAP1:MAML2
9	7	F	Frontal	I	YAP1:MAML2
Schieffer et al. [6]					
10	0, 57	F	Temporal	II	YAP1:FAM118B
11	20	M	Rolandic sulcus	II	YAP1:FAM118B

F: female; M: male; NA: no sufficient material for additional histological workup.

In comparison with the other previously reported *YAP1*-fusion-positive atypical meningiomas, our case showed a particular midline location in the frontal interhemispheric space, adherent to the anterior cerebral arteries, hitherto never reported. Despite quite incomplete radiological findings in the described cases, lobar localization was the most common (4 out of 10 patients) (Table 1). Moreover, the location of the lesion in our case is quite atypical: the absence of evident dural attachment and the slight hyperdensity visible on CT, the cystic-necrotic appearance with marked and dishomogeneous enhancement and without a real dural adhesion noted on MRI suggested firstly an intra-axial malignant lesion. Meningiomas are usually attached to the dura mater deriving from progenitor cells that originate from the arachnoidal cap cells of the leptomeninges and only rarely and mainly in pediatric population have “intraparenchymal” meningiomas been reported: these tumors represent an unusual neuroradiological/neurosurgical finding, appearing similar to other more common intra-axial brain tumors [10,11]. The close relation of our case to the anterior cerebral arteries supports the hypothesis that intraparenchymal meningiomas arise from those arachnoid cells, located within the pia mater, which enter the surface of the brain and sulci, migrating with perforating blood vessels during brain development [11].

4. Conclusions

This case extends the clinico-pathological features of *YAP1*-fused meningiomas and highlights the need for an integrated multilayered diagnostic approach, combining data from histological and molecular analyses, neuroradiology, and clinical findings. Further studies in a larger series of pediatric *NF2*-unrelated meningiomas are needed in order to determinate the prognostic role of *YAP1* alterations and therapeutic advancements in this uncommon pediatric tumor.

Supplementary Materials: The following supporting information can be downloaded at: <https://www.mdpi.com/article/10.3390/diagnostics12102367/s1>, Figure S1: DNA methylation profiling and CNV results; Table S1: Brain tumor v12.5 Calibrated Scores.

Author Contributions: Conceptualization, S.E. and G.M.; methodology, S.E., G.M., E.M., P.M., M.G. and M.P.S.; formal analysis, S.E., G.M., M.A., E.M., P.M., M.T., F.M.D., M.M. (Marco Moscatelli), L.C. and B.P.; investigation, S.E., G.M., M.A., E.M., P.M., M.T., F.M.D., M.M. (Marco Moscatelli), L.C. and B.P.; data curation, S.E., E.M. and P.M.; writing—original draft preparation, S.E., G.M., E.M., P.M., M.T., F.M.D. and M.M. (Marco Moscatelli); writing—review and editing, S.E., G.M., M.A., E.M., P.M. and V.B.; supervision, S.E., G.M., M.M. (Maura Massimino), L.C. and B.P. All authors have read and agreed to the published version of the manuscript.

Funding: This research received no external funding.

Institutional Review Board Statement: All data reported in the manuscript were obtained in accordance with the Declaration of Helsinki and its later amendments, or with comparable ethical standards.

Informed Consent Statement: Written informed consent has been obtained from the parents of the patient to approve the use of information or material for scientific purposes.

Data Availability Statement: The data presented in this study are available on request from the corresponding author.

Acknowledgments: This work was supported by the Italian Ministry of Health (RRC).

Conflicts of Interest: The authors declare no conflict of interest.

Appendix A

Material and Methods:

DNA methylation profiling was performed according to protocol approved by Bambino Gesù Children's Hospital Ethical Committee (Protocol no 1556_OPBG_2018, 15 January 2019), after obtaining written consent from the patient's parents. DNA was extracted from formalin-fixed paraffin-embedded tissues using MagPurix FFPE DNA Extraction Kit (Resnova, Rome, Italy) for automatic extraction of genomic DNA. The sample was analyzed using Illumina Infinium Human Methylation EPIC BeadChip (EPIC) arrays (Illumina, San Diego, USA) according to the manufacturer's instructions, on an Illumina iScan Platform (Illumina, San Diego, CA, USA) as previously reported [DOI: 10.3389/fgene.2019.00391, 10.1158/2159-8290.CD-19-1030]. Generated methylation data were compared to brain tumor classifier v11b4 [10.1038/nature26000] and its more recent research version v12.5. High-density DNA methylation arrays allowed for determining copy number alterations that were generated for the reported case, as described [DOI: 10.1038/nature26000]. Integrative Genomic Viewer (IGV) was used for graphical visualization of structural rearrangements and for mapping genes onto regions of interest.

DNA and total RNA were extracted using a Maxwell 16 purification system (Promega, Madison, WI, USA). The SurePrint G3 Human CGH + SNP Microarray 4 × 180 K was used for array-CGH analysis of tumor, following the manufacturer's instructions. G2565CA Agilent scanner and Cytogenomics software were employed for data analysis; data refer to GRCh37- hg19 human genome assembly. For RNA analysis, reverse transcription was performed using SuperScript II RNA polymerase (ThermoFisher). *YAP1-MAML2* was PCR amplified (Parker M et al., *Nature*. 2014 506:451-5) and bidirectionally sequenced using SeqStudio Genetic Analyzer (ThermoFisher, Waltham, MA, USA).

References

1. Szychot, E.; Goodden, J.; Whitfield, G.; Curry, S. Children's Cancer and Leukaemia Group (CCLG): Review and guidelines for the management of meningioma in children, teenagers and young adults. *Br. J. Neurosurg.* **2020**, *34*, 142–153. [[CrossRef](#)] [[PubMed](#)]
2. Toland, A.; McNulty, S.N.; Pekmezci, M.; Evenson, M.; Huntoon, K.; Pierson, C.R.; Boue, D.R.; Perry, A.; Dahiya, S. Pediatric meningioma: A clinicopathologic and molecular study with potential grading implications. *Brain Pathol.* **2020**, *30*, 1134–1143. [[CrossRef](#)] [[PubMed](#)]
3. Battu, S.; Kumar, A.; Pathak, P.; Purkait, S.; Dhawan, L.; Sharma, M.C.; Suri, A.; Singh, M.; Sarkar, C.; Suri, V. Clinicopathological and molecular characteristics of pediatric meningiomas. *Neuropathology* **2018**, *38*, 22–33. [[CrossRef](#)] [[PubMed](#)]
4. Pathmanaban, O.N.; Sadler, K.V.; Kamaly-Asl, I.D.; King, A.T.; Rutherford, S.A.; Hammerbeck-Ward, C.; McCabe, M.G.; Kilday, J.P.; Beetz, C.; Poplawski, N.K.; et al. Association of Genetic Predisposition with Solitary Schwannoma or Meningioma in Children and Young Adults. *JAMA Neurol.* **2017**, *74*, 1123–1129. [[CrossRef](#)] [[PubMed](#)]
5. Sievers, P.; Chiang, J.; Schrimpf, D.; Stichel, D.; Paramasivam, N.; Sill, M.; Gayden, T.; Casalini, B.; Reuss, D.E.; Dalton, J.; et al. YAP1-fusions in pediatric NF2-wildtype meningioma. *Acta Neuropathol.* **2020**, *139*, 215–218. [[CrossRef](#)] [[PubMed](#)]
6. Schieffer, K.M.; Agarwal, V.; LaHaye, S.; Miller, K.E.; Koboldt, D.C.; Lichtenberg, T.; Leraas, K.; Brennan, P.; Kelly, B.J.; Crist, E.; et al. YAP1-FAM118B Fusion Defines a Rare Subset of Childhood and Young Adulthood Meningiomas. *Am. J. Surg. Pathol.* **2021**, *45*, 329–340. [[CrossRef](#)] [[PubMed](#)]
7. Capper, D.; Jones, D.T.W.; Sill, M.; Hovestadt, V.; Schrimpf, D.; Sturm, D.; Koelsche, C.; Sahm, F.; Chavez, L.; Reuss, D.E.; et al. DNA methylation-based classification of central nervous system tumours. *Nature* **2018**, *555*, 469–474. [[CrossRef](#)] [[PubMed](#)]

8. Zanconato, F.; Cordenonsi, M.; Piccolo, S. YAP/TAZ at the Roots of Cancer. *Cancer Cell* **2016**, *29*, 783–803. [[CrossRef](#)] [[PubMed](#)]
9. Szulzewsky, F.; Holland, E.C.; Vasioukhin, V. YAP1 and its fusion proteins in cancer initiation, progression and therapeutic resistance. *Dev. Biol.* **2021**, *475*, 205–221. [[CrossRef](#)] [[PubMed](#)]
10. Ohba, S.; Abe, M.; Hasegawa, M.; Hirose, Y. Intraparenchymal Meningioma: Clinical, Radiologic, and Histologic Review. *World Neurosurg.* **2016**, *92*, 23–30. [[CrossRef](#)] [[PubMed](#)]
11. Guo, H.; Liang, H.; Wang, J.; Wen, S.; Wang, Y.; Wang, Y.; Ma, Z. Giant Intraparenchymal Meningioma in a Female Child: Case Report and Literature Review. *Cancer Manag. Res.* **2021**, *13*, 1989–1997. [[CrossRef](#)] [[PubMed](#)]