

# Synchronous double superficial mixed gastrointestinal mucus phenotype gastric cancer with gastritis cystica profunda and submucosal lipoma

## A case report

Dandan Huang, MD<sup>a</sup>, Qiang Zhan, PhD<sup>a</sup>, Shudong Yang, MD<sup>b</sup>, Qi Sun, PhD<sup>c</sup>, Zhiyi Zhou, PhD<sup>b,\*</sup>

### Abstract

**Introduction:** Synchronous double superficial gastric cancer with gastritis cystica profunda (GCP) and submucosal lipoma is a rare disease and is difficult to diagnose and treat.

**Case presentation:** A 61-year-old man was referred to our hospital with upper abdominal discomfort for the past 10 days. One year ago, the patient underwent surgery for duodenal ulcer and perforation. The diseases were diagnosed by magnifying endoscopy with narrowband imaging and pathological methods. Both mucosal lesions with a submucosal yellow-colored nodule were completely resected by endoscopic submucosal dissection and additional proximal gastrectomy was performed on the cancer embolus in the submucosal vena cava. The patient was finally diagnosed with synchronous double superficial well differentiated adenocarcinoma (mixed gastrointestinal mucus phenotype) with embolus in submucosal vena cava, coexisting with gastritis cystica profunda and submucosal lipoma. Final TNM classification was T1b (sm1) N0M0, and pathological stage was IA. The postoperative course was uneventful, and no recurrence or metastasis was observed during the 5-month follow-up period.

**Conclusion:** The diagnosis and treatment of synchronous double superficial gastric cancer with GCP and submucosal lipoma is challenging. In addition, elastic fiber staining and immune marker staining is effective and should be considered for diagnosis.

**Abbreviations:** EGC = early gastric cancer, ESD = endoscopic submucosal dissection, GAC = gastric adenocarcinoma, GCP = gastritis cystica profunda, IM = intestinal metaplasia, ME-NBI = magnifying endoscopy with narrow-band imaging.

**Keywords:** gastric lipoma, gastritis cystica profunda, mixed gastrointestinal mucus phenotype, superficial gastric cancer, synchronous double

## 1. Introduction

Synchronous double gastric cancer, gastritis cystica profunda (GCP) and gastric lipoma are rare diseases of the stomach that are difficult to diagnose and treat, since their pathogenesis is unclear.<sup>[1–3]</sup>

Here we report the case of a 61-year-old man with synchronous double superficial mixed gastrointestinal mucus

phenotype gastric cancer with GCP and submucosal lipoma, and examine the treatment strategies to understand the diagnosis and management these uncommon and rare gastric diseases.

## 2. Case report

A 61-year-old man complained of upper abdominal discomfort with no obvious inducement for 10 days. He had no notable past medical and family history; however, he underwent surgery for duodenal ulcer and perforation one year earlier. The patient had been smoking and drinking for >40 years and had hypertension for >10 years as well as oral levamlodipine-controlled blood pressure. There were no notable findings on physical examination. Synchronous double gastric lesions were detected by endoscopy, with a 5-mm diameter mucosal erosion in the lesser curvature side of the cardia (magnifying endoscopy with narrow-band imaging [ME-NBI] revealed a local intensive villi change) and a 10-mm mucosal irregular depression with marginal nodular elevation in the posterior wall of the gastric body and fundus junction (ME-NBI revealed an irregular villous loop pattern with a demarcation line) (Fig. 1A and B). Pathology revealed moderate chronic atrophic gastritis, with focal intestinal metaplasia and high-grade atypical hyperplasia. The possibility of gastric carcinoma was strongly suggested, with the peptic ulcer needing to be excluded. The patient was referred to our hospital for further diagnosis and treatment.

Editor: N/A.

Competing interest: The authors have no funding and conflicts of interest to disclose.

<sup>a</sup> Department of Gastroenterology, <sup>b</sup> Department of Pathology, Wuxi People's Hospital Affiliated to Nanjing Medical University, Wuxi, Jiangsu, <sup>c</sup> Department of Pathology, The Affiliated Drum Tower Hospital, Nanjing University Medical School, Nanjing, China.

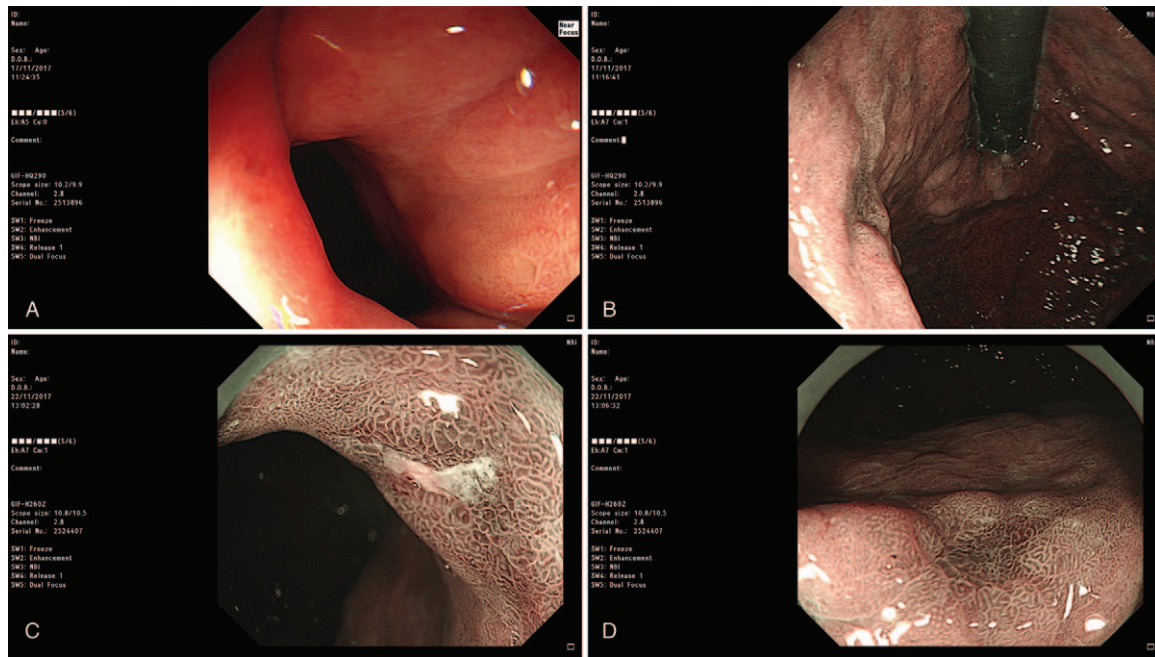
\* Correspondence: Zhiyi Zhou, Departments of Pathology, Wuxi People's Hospital Affiliated to Nanjing Medical University, Qingyang Road No. 299, Wuxi, Jiangsu, 214023, China (e-mail: wuxi\_zzy@163.com).

Copyright © 2018 the Author(s). Published by Wolters Kluwer Health, Inc. This is an open access article distributed under the terms of the Creative Commons Attribution-Non Commercial-No Derivatives License 4.0 (CCBY-NC-ND), where it is permissible to download and share the work provided it is properly cited. The work cannot be changed in any way or used commercially without permission from the journal.

Medicine (2018) 97:22(e10825)

Received: 26 March 2018 / Accepted: 29 April 2018

<http://dx.doi.org/10.1097/MD.0000000000010825>



**Figure 1.** Endoscopic findings. (A) A 5-mm diameter mucosal erosion in the lesser curvature side of the cardia. (B) A 10-mm mucosal irregular depression with marginal nodular elevation in the posterior wall of the gastric body and fundus junction; ME-NBI findings. (C) Local intensive villi change in the lesser curvature side of the cardia. (D) An irregular villous loop pattern in the posterior wall of the gastric body and fundus junction. ME-NBI=magnifying endoscopy with narrow-band imaging.

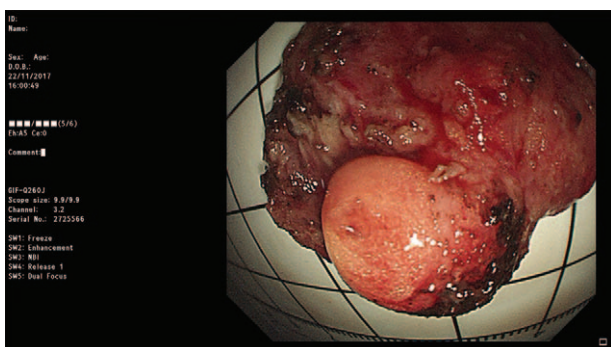
Two days after admission, magnifying endoscopy before endoscopic submucosal dissection (ESD) demonstrated that the two lesions were mucosal depressions with a clear boundary, and the irregular microvessels were located in the loop (Fig. 1C and D). Furthermore, the lesions were marked along the outer edge, and the indigo carmine diluent was injected under the mucosa. Both lesions were completely resected by submucosal dissection using a dual knife, with the procedure taking 3 hours and 20 minutes; a yellow-colored nodule was observed beneath the lesion in the posterior wall of the gastric body and fundus junction (Fig. 2) and simultaneously resected. Hemostasis was performed during the ESD process by electrocoagulation.

Macroscopically, a 6.3 × 3 cm irregular mucosa was observed, with a submucosal grayish yellow nodule (1 × 0.7 × 0.5 cm). Microscopically, routine hematoxylin–eosin-stained sections revealed 2 components (Fig. 3A and B): (the lesion of the lesser curvature side of the cardia) a well-differentiated tubular

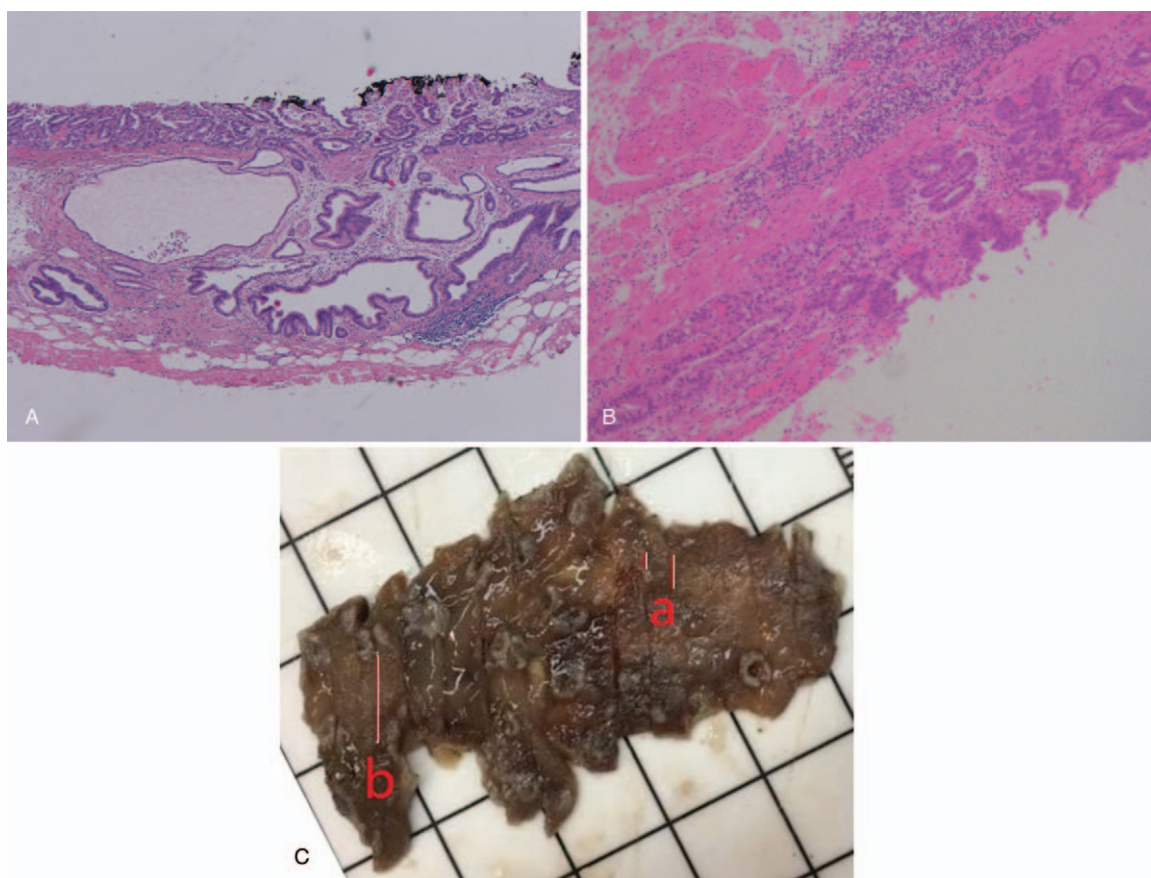
adenocarcinoma (approximately 4 × 3 mm), completely involved in the GCP below; and (the lesion of the posterior wall of the gastric body and fundus junction) a well-differentiated tubular adenocarcinoma (approximately 9 × 3 mm), locally invading mucosal muscle and involving in the GCP, no intravascular cancer embolus and ulcer formation, and submucosal lipoma was located below the lesion. The surrounding gastric mucosa revealed moderate chronic atrophic gastritis, with focal intestinal metaplasia and GCP (Fig. 3C). *Helicobacter pylori* infection was identified by histopathological examination. Elastic fiber staining and immune marker CD31 staining revealed a cancer embolus in a submucosal vena cava in the posterior wall of the gastric body and fundus junction (Fig. 4A). On immunohistochemical analysis, the tumor tissue demonstrated MUC5AC (partial +), MUC6 (partial +), CDX2 (+), P53 (+), HER2 (uncertain positive), and Ki-67 (approximately 40%+) and had a mixed gastrointestinal mucus phenotype (Fig. 4B and C). Based on the above findings, the patient was diagnosed with synchronous double superficial well-differentiated adenocarcinoma (mixed gastrointestinal mucus phenotype) with embolus in submucosal vena cava, coexisting with gastritis cystica profunda and submucosal lipoma.

The patient was discharged from the hospital on postoperative day 7 after ESD. Additional upper half gastrectomy was performed for the cancer embolus in the submucosal vena cava in the third week after ESD at another hospital, and pathology revealed no cancer tissue residue or lymph node metastasis. Final TNM classification was T1b (sm1) N0M0, and pathological stage was IA. The patient was followed-up for 5 months postoperatively and remains healthy and without evidence of recurrence and metastasis, to date.

The patient and his family provided informed consent and agreed to participate in this case report. Furthermore, our case report does not require ethical approval from ethics committee or institutional review board.



**Figure 2.** A yellow-colored nodule beneath the cancerous mucosa in the posterior wall of the gastric body and fundus junction.



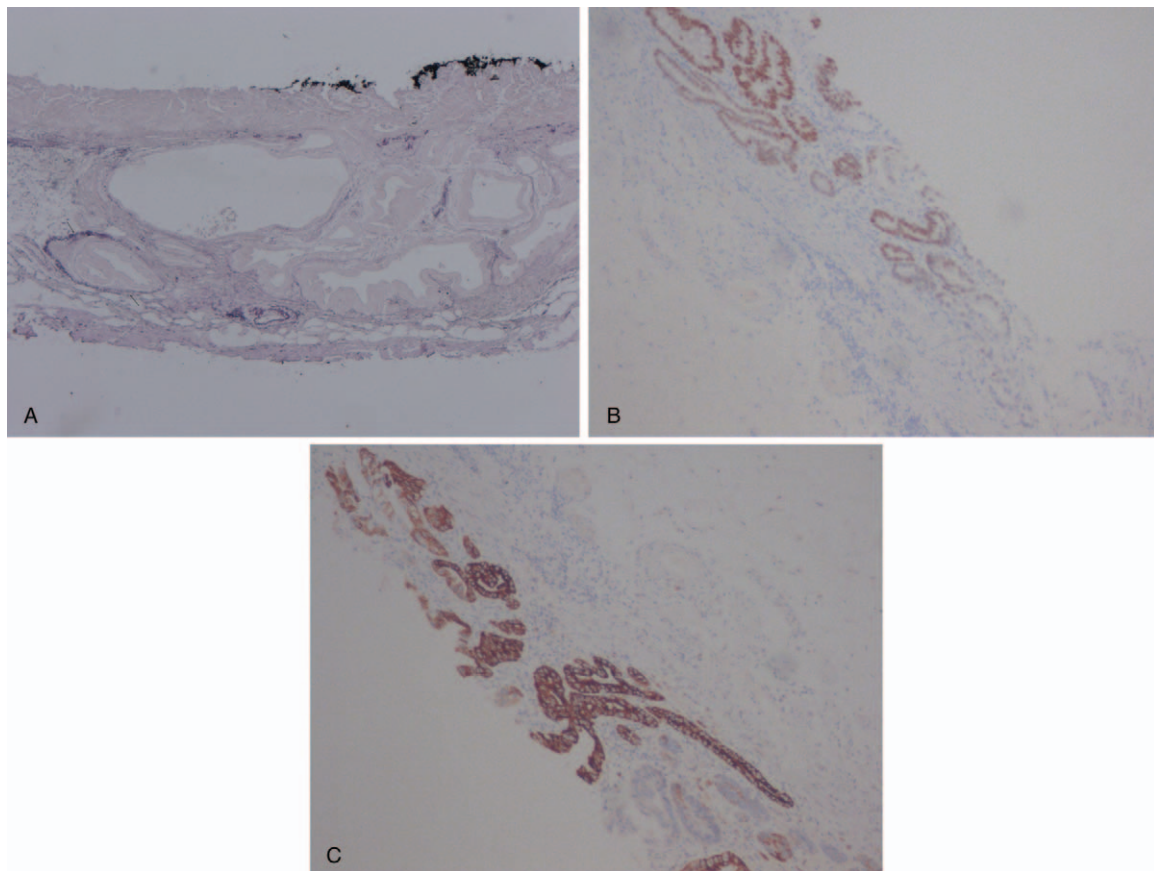
**Figure 3.** Pathological examination of the lesions showed (A) a well-differentiated tubular adenocarcinoma completely involved in the gastritis cystica profunda in the lesser curvature side of the cardia ( $10 \times 10$ ); (B) a well-differentiated tubular adenocarcinoma, locally invading mucosal muscle in the posterior wall of the gastric body and fundus junction ( $10 \times 10$ ). Mapping of the ESD specimen revealed two synchronous superficial well-differentiated tubular adenocarcinomas (C) (a: the lesser curvature side of the cardia, b: the posterior wall of the gastric body and fundus junction). ESD=endoscopic submucosal dissection.

### 3. Discussion

Based on previous reports, the synchronous multifocal gastric cancer accounts for 4.8% to 20.9% of surgically resected stomachs, is more commonly associated with early gastric cancer (EGC), and multiple EGCs account for 6% to 14% of all EGCs.<sup>[4,5]</sup> EGC frequently develops in the lower third of the stomach. However, multiple EGCs are frequently located in different parts of the stomach (upper, middle, or lower thirds), which are important blind spots in endoscopic examination.<sup>[5]</sup> In addition, male sex and submucosal invasion were predictive risk factors of synchronous multiple EGC.<sup>[1]</sup> Therefore, patients with risk factors should undergo more meticulous endoscopic examination during endoscopic screening and endoscopic tumor resection, in order to avoid being overlooked. In addition, new imaging techniques are also needed, such as mucosal staining techniques and ME-NBI. In our case, both lesions were completely resected within 3 hours and 20 minutes, and the patient was discharged on day 7 after ESD. Therefore, we consider that ESD is the ideal procedure for synchronous EGCs. Simultaneous ESD for synchronous gastric cancer can reduce the length of hospital stay and overall medical expenses. Kasuga et al<sup>[4]</sup> reported that there is a significant correlation between complications of simultaneous ESD for synchronous cancers and the long operation times. The size of the larger tumor, upper portion location, and tumors not in the standard guideline criteria may be indicators of longer operative time. Step-by-step

resection on separate days may be a favorable option to avoid complications if a long operative time is needed.

GCP is an uncommon disease, histopathologically characterized by hyperplasia and cystic dilatation of the gastric glands extending into the submucosal layer.<sup>[6]</sup> GCP is common in elderly men, mainly located in the gastric cardia, the posterior and anterior wall of the gastric body or the intermediate zone between the fundic and pyloric glands; the results of our case are similar to those in the literature. GCP often demonstrates a submucosal tumor (SMT), solitary polyps, a gastric mucosal fold, or even surface mucosa with no abnormal appearance.<sup>[2,7]</sup> Although GCP usually occurs at the anastomosis site of a gastrectomy, it can also be found in cases of an unoperated stomach; however, in our, the patient had undergone surgery for duodenal ulcer. GCP is usually considered to be related to *H pylori* infection, including in our case.<sup>[7,8]</sup> Although it is a hyperplastic benign lesion, GCP comprised 3% of gastric carcinoma cases and several reports propose GCP as a premalignant lesion on the basis of malignant progression from dysplasia to invasive carcinoma.<sup>[2,7,9–11]</sup> Endoscopic ultrasonography (EUS) is valuable for an endoscopic diagnosis of GCP. It exhibits primarily anechoic, mixed heterogeneous with thickened overlying mucosa, or hypoechoic with microcysts.<sup>[2]</sup> However, diagnosis of the EGC within GCP is difficult using endoscopy or biopsy. ESD is an effective method in diagnosis of such cases. Based on the findings of our case, we believe that GCP and EGC may have an inherent correlation.



**Figure 4.** (A) Elastic fiber staining revealed a cancer embolus in a submucosal vena cava ( $10\times$ ); (B) immunohistochemical staining of the tumor tissue showed CDX2 (+); and (C) MUC6 (partial+) (Envision,  $10\times$ ).

GCP may be associated with the occurrence of some gastric cancers, and EGC may be an important factor in the development of some GCP cases. When GCP is detected, the presence of EGC should be carefully monitored. In our case, immunohistochemistry and elastin staining played an important role in the discovery of the intravascular cancer embolus, and additional partial gastrectomy was performed to prevent the risk of recurrence and metastasis. Therefore, cases where EGC occurs in combination with GCP should be evaluated separately from submucosal invasion and intravascular cancer embolus; in addition, it should be evaluated by methods other than histological observation because of high subjectivity.

The stomach is a rare location for lipomas, and lipomas represent approximately 3% of all benign gastric tumors<sup>[12]</sup>; these can be easily ignored, resulting in misdiagnosis and delayed healing. Only few cases of gastric lipoma associated with early gastric cancer have been previously reported. In our case, the lipoma was located beneath the cancerous mucosa or both were located very close to each other, which is similar to that in previously reported cases; this suggests that these were frequently concomitant tumors.<sup>[13,14]</sup> Therefore, clinicians should perform careful examinations, considering the possibility of synchronous tumors, as demonstrated in our case as well as previous cases. Lipoma should be highly considered when a “cushion sign,” “tenting effect,” or “naked fat sign” is observed on gastroscopy.<sup>[15,16]</sup> Early diagnosis enables early endoscopic resection, with less damage and rapid recovery. In our case, no obvious submucosal tumor was observed, and ESD was performed on the

mucosal lesion. During submucosal dissection, we observed a yellow-colored nodule beneath the cancerous mucosa and simultaneously resected it with the cancerous mucosa.

The lesion in our case was a mixed gastrointestinal mucus phenotype adenocarcinoma. It is generally believed that non-cardia gastric adenocarcinoma (GAC) is usually developed through a series of mucosal changes from non-atrophic gastritis to atrophic gastritis, intestinal metaplasia (IM), dysplasia and adenocarcinoma. However, Tatematsu et al<sup>[17]</sup> proposed that IM may not be a preneoplastic change in GAC, but rather that cells of the intestinal type may appear independently in the gastric mucosa in IM or in GAC. The phenotypic expression of gastric cancer cells is not related to the phenotypic changes of the surrounding gastric mucosa, since gastric-type GACs may be surrounded by the intestinalized gastric mucosa and intestinal-type GACs may be present in the ordinary mucosa. Intestinalization of gastric mucosa and cancer cells may represent a kind of homeotic transformation. In our case, IM of gastric mucosa around the gastric cancer was not obvious, and the cancer cell may be in the process of transformation from gastric to intestinal type.

In conclusion, synchronous double superficial mixed gastrointestinal mucus phenotype gastric cancer with GCP and submucosal lipoma is rare and complicated. ESD is the ideal treatment for synchronous EGCs. When GCP is observed, the presence of EGC should be carefully monitored. Cases where EGC appears in combination with GCP should be strictly excluded from submucosal invasion and intravascular cancer embolus, and they should not only be examined by histological

observation. Elastic fiber staining and immune marker staining are useful and should be considered during diagnosis.

### Author contributions

DH and ZZ designed this study; QZ collected and collated data; DH extracted and SY confirmed the data; QS analyzed data; DH wrote the manuscript; ZZ edited the manuscript.

**Conceptualization:** dandan huang, Qiang Zhan, Zhiyi Zhou.

**Writing – original draft:** dandan huang.

**Methodology:** Qiang Zhan.

**Supervision:** Qiang Zhan.

**Validation:** Shudong Yang, Qi Sun.

**Writing – review & editing:** Zhiyi Zhou.

### References

- [1] Jeong SH, An J, Kwon KA, et al. Predictive risk factors associated with synchronous multiple early gastric cancer. *Medicine (Baltimore)* 2017;96:e7088.
- [2] Xu G, Peng C, Li X, et al. Endoscopic resection of gastritis cystica profunda: preliminary experience with 34 patients from a single center in China. *Gastrointest Endosc* 2015;81:1493–8.
- [3] Yen HH, Lin KH, Chen CJ. Gastrointestinal: gastric lipoma as a rare cause of recurrent gastrointestinal bleeding. *J Gastroenterol Hepatol* 2018;33:771.
- [4] Kasuga A, Yamamoto Y, Fujisaki J, et al. Simultaneous endoscopic submucosal dissection for synchronous double early gastric cancer. *Gastric Cancer* 2013;16:555–62.
- [5] Chen ZS, Jin XF, Wu HL, et al. Simultaneous endoscopic submucosal dissection for multiple early gastric cancers in a low volume center. *Medicine (Baltimore)* 2017;96:e7745.
- [6] Carvalho JR, Quadros AC, Meireles L, et al. Gastritis cystica profunda mimicking a GIST—a diagnostic challenge. *Gastroenterol Hepatol* 2017; S0210-5705:30187-30195.
- [7] Ogasawara N, Noda H, Kondo Y, et al. A case of early gastric cancer arising from gastritis cystica profunda treated by endoscopic submucosal dissection. *Case Rep Gastroenterol* 2014;8:270–5.
- [8] Yu XF, Guo LW, Chen ST, et al. Gastritis cystica profunda in a previously unoperated stomach: a case report. *World J Gastroenterol* 2015;21:3759–62.
- [9] Matsumoto T, Wada M, Imai Y, et al. A rare cause of gastric outlet obstruction: gastritis cystica profunda accompanied by adenocarcinoma. *Endoscopy* 2012;44(suppl 2 UCTN):E138–9.
- [10] Odze RD, Greenson J, Lauwers G, et al. Gastritis cystica profunda versus invasive adenocarcinoma. *Am J Surg Pathol* 2012;36:316.
- [11] Lee SJ, Park JK, Seo HI, et al. A case of gastric inverted hyperplastic polyp found with gastritis cystica profunda and early gastric cancer. *Clin Endosc* 2013;46:568–71.
- [12] Sato A, Irisawa A, Shibukawa G, et al. Early gastric cancer associated with a gastric lipoma. *ACG Case Rep J* 2017;4:e78.
- [13] Namikawa T, Munekeg E, Mizuta H, et al. Simultaneous occurrence of gastric lipoma and early gastric cancer. *Endoscopy* 2014;46(suppl 1 UCTN):E338–9.
- [14] Ono S, Fujishiro M, Goto O, et al. En bloc resection of cardia cancer and lipoma with endoscopic submucosal dissection. *Dig Liver Dis* 2009;41:237.
- [15] Suarez AL, Dufault DL, Mcvey MC, et al. Stepwise endoscopic resection of a large gastric lipoma causing gastric outlet obstruction and GI bleeding. *Gastrointest Endosc* 2016;84:180.
- [16] Aslan F, Akpınar Z, Cekic C, et al. En bloc resection of a 9cm giant gastro-duodenal lipoma by endoscopic submucosal dissection. *Dig Liver Dis* 2015;47:88–9.
- [17] Tatematsu M, Tsukamoto T, Inada K. Stem cells and gastric cancer: role of gastric and intestinal mixed intestinal metaplasia. *Cancer Sci* 2003;94:135–41.