

Original Article



A new technique of laparoscopic para-aortic lymphadenectomy optimizes perioperative outcome

Yonghong Lin , Li He , Youwen Mei

Department of Obstetrics and Gynecology, Chengdu Women and Children's Central Hospital, Affiliated to University of Electronic Science and Technology of China, Chengdu, China



Received: Apr 9, 2020
Revised: Aug 21, 2020
Accepted: Sep 20, 2020

Correspondence to

Yonghong Lin

Department of Obstetrics and Gynecology,
Chengdu Women and Children's Central
Hospital, Affiliated to University of Electronic
Science and Technology of China, No. 1617th,
Riyue Street, Qingyang District,
Chengdu 610091, China.
E-mail: 381001243@qq.com

Copyright © 2021. Asian Society of
Gynecologic Oncology, Korean Society of
Gynecologic Oncology, and Japan Society of
Gynecologic Oncology
This is an Open Access article distributed
under the terms of the Creative Commons
Attribution Non-Commercial License (<https://creativecommons.org/licenses/by-nc/4.0/>)
which permits unrestricted non-commercial
use, distribution, and reproduction in any
medium, provided the original work is properly
cited.

ORCID iDs

Yonghong Lin
<https://orcid.org/0000-0002-5171-5933>
Li He
<https://orcid.org/0000-0002-1735-8899>
Youwen Mei
<https://orcid.org/0000-0002-6963-3100>

Conflict of Interest

No potential conflict of interest relevant to this article was reported.

ABSTRACT

Objective: The aim of the present study was to introduce a new technique for laparoscopic para-aortic lymphadenectomy (PAL): an invented retroperitoneum suspension needle combined with modified trocar placement.

Methods: This prospective pilot study randomly categorized women with cervical cancer of stage I–II into 2 groups. The patients in the study group would have laparoscopic PAL with our new technique, while those in the control group with control method. Patients' characteristics and perioperative outcomes were compared between the 2 groups.

Results: A total of 37 patients were included in our study, of which 20 cases in the study group and 17 cases in the control group. As a result, the mean number of para-aortic lymph nodes (PALNs) resected in the study group was significantly more than that in the control group ($p < 0.001$). The time for resecting PALNs ($p < 0.001$) and total operative time ($p < 0.001$) in the study group decreased significantly than those in the control group.

Conclusions: For laparoscopic PAL, this new technique was effective and practical.

Keywords: Laparoscopy; Lymphadenectomy; Para-aortic Lymph Node; Cervical Cancer

INTRODUCTION

Globally, cervical cancer accounts for almost 12% of all female cancers, and China carries a heavy global burden [1]. It usually invades pelvic lymph nodes [2]. According to Denis's study, 4 levels of pelvic nodes are defined according to corresponding arterial anatomy: level 1, external and internal iliac artery; level 2, common iliac (including presacral) artery; level 3, aortic infra-mesenteric artery; and level 4, aortic infrarenal vein [3]. According to previous literatures, the incidence of para-aortic lymph node (PALN) metastasis for cervical cancer is relatively high [4,5]. It has been clearly pointed out that patients with cervical cancer who had the following conditions require classical para-aortic lymphadenectomy (PAL): cervical cancer of IB1 stage with tumor's diameter more than 3 cm, IB2 to IIa stage, iliac lymph node metastasis, or aortic lymph node enlargement [2]. Classical PAL refers to resecting pelvic lymph nodes of level 4.

Author Contributions

Conceptualization: L.Y.; Data curation: H.L.;
Formal analysis: M.Y.; Writing - original draft:
M.Y.; Writing - review & editing: L.Y.

In recent years, laparoscopic PAL has gradually become the major operative type in cervical cancer. There are mainly 3 surgical approaches; transperitoneal, bilateral extraperitoneal, and left extraperitoneal. The transperitoneal approach is widely adopted because it offers greater working space and familiar landmarks. However, it is usually limited under the level of inferior mesenteric artery [6] because of difficult exposure of the para-aortic area and increased rate of complication [7]. With that in mind, we have invented a retroperitoneum suspension needle and modified trocar placement to solve this problem.

MATERIALS AND METHODS

The prospective pilot study recruited patients with cervical cancer of stage IB1–IIB1. Those patients with retroperitoneal surgery history, other abdominal malignant tumors or operation contradictions were excluded. This study was approved by the Ethics Committee of Chengdu Women and Children's Center Hospital (ethical number:2018[56])). Written informed consents of clinical data for scientific use from patients were obtained. According to the guidelines of National Comprehensive Cancer Network (NCCN) guidelines for cervical cancer [8] and clinical experience [9,10], all patients in our study had extended hysterectomies, pelvic lymphadenectomy, PAL and bilateral oophorectomy if necessary before radiotherapy or chemotherapy.

Our invented retroperitoneum suspension needle is 20 cm long, which has a curved tip with a small groove (Fig. 1). The operation procedure is as follows. Firstly, a small loop is made at one end of a stitch before it is hooked up by the needle's groove. Secondly, the needle is passed through abdominal wall (Fig. 2A) and retroperitoneum (Fig. 2B) successively. Thirdly, the needle is withdrawn from retroperitoneum (Fig. 2D) after the stitch is taken out of the needle's groove (Fig. 2C). Finally, the stitch is pulled out of the abdominal wall and fixed (Fig. 2E). This procedure can be repeated several times until the surgical field of level 4 is fully exposed (Fig. 2F). Our operation video (Supplementary Video 1) showed the surgical procedure.

The laparoscopic approach consisted of 4 trocar insertions (Fig. 3): i) A 10 mm trocar is placed at periumbilical area (point A).; ii) A 5 cm trocar is placed above synchondroses pubis in the middle line (point D).; and iii) Two 5 mm trocars are placed at the “left MacBurney” and “right MacBurney” (points B and C) sites, respectively. Before PAL, the operator is positioned to the left of the patient, while the first assistant stands on the right of the patient. They face the monitor located at the foot of the patient. Trocar at the periumbilical

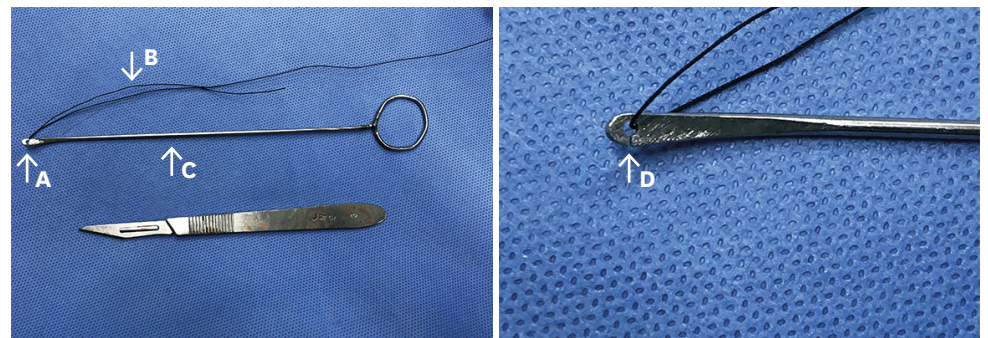


Fig. 1. A suspension needle: A, curved tip; B, circle loop; C, the needle's handle; and D, a small groove on top of the needle.

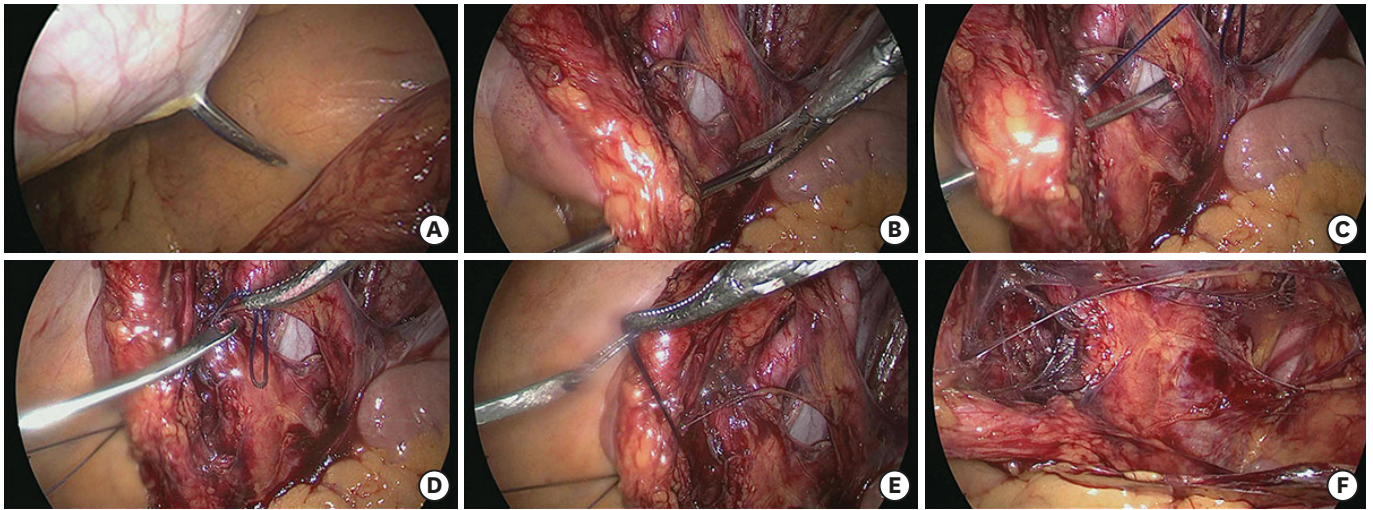


Fig. 2. The process of suspending retroperitoneum with our needle. (A) abdominal wall is punctured by the needle. (B) retroperitoneum is punctured by the needle. (C) The circle is taken out of the groove. (D) The needle is drawn out of retroperitoneum. (E) The circle is hooked up by the groove on the other side of retroperitoneum again and pulled out of abdominal wall. (F) The exposed surgical field after retroperitoneum of both sides are suspended.

area is used for camera (point A), while those at right MacBurney (point C) sites and above synchondroses pubis (point D) are used by the operator. When performing PAL, the operator and first assistant change their positions, facing the monitor located at the head of the patient. Trocar above synchondroses pubis (point D) is used for the camera, while those at the periumbilical area (point A) and left MacBurney site (point B) are used by the operator.

Fig. 4 shows the exposed surgical field of level 4, where right ovarian vein (point A), left renal vein (point B), inferior mesenteric artery (point C) are visible clearly.

Our control group requires 5 trocars: a 10 mm trocar is placed at the middle point between the umbilicus and xiphoid (LeeHuang point), which is used for the camera. Two 5-mm trocars are placed in the lower abdomen at the paramedian line at the level of umbilicus. One

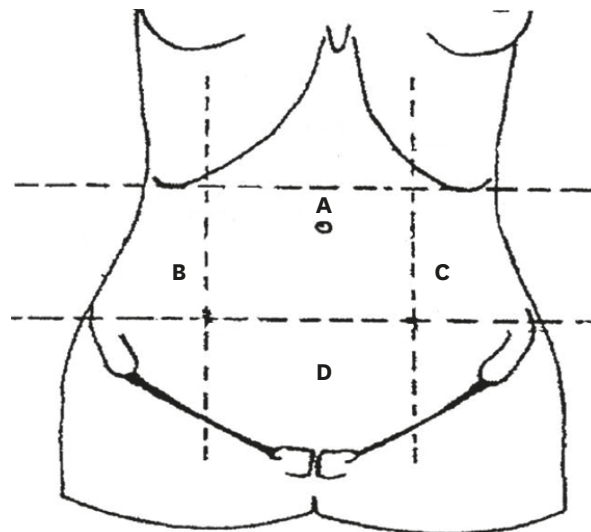


Fig. 3. Sketch map of modified trocar placement: A, a 10 mm trocar is placed at periumbilical area; B, a 5 mm trocars are placed at the “left MacBurney”; C, a 5 mm trocars are placed at the “right MacBurney”; and D, a 5 cm trocar is placed above synchondroses pubis in the middle line.

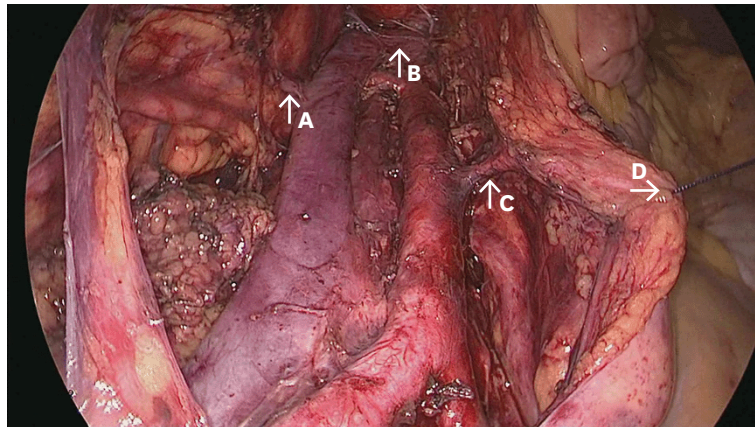


Fig. 4. The exposed surgical field of para-aortic lymph nodes: A, right ovarian vein; B, renal vein; C, inferior mesenteric artery; and D, suspended retroperitoneum.

5-mm and one 12-mm puncture site trocar are placed at the paramedian line just above the pubic hairline respectively (**Supplementary Fig. 1**) [11]. The operator always stands on the right side of the patient.

All the operations had been performed by the same surgeon with 30° optic and 2D laparoscopic technology in our study. Other devices used in laparoscopic radical surgery were the same between the 2 groups. The primary perioperative outcome measure was the number of resected PALNs. The second perioperative outcome measure included time for laparoscopic PAL and total operative time, amount of estimated blood loss (EBL), and operative complications. The number of resected PALNs was counted by 2 pathologists. The time for laparoscopic PAL referred to the amount of time only for PAL in the control group, while it referred to sum of the amount of time for PAL and exposure of surgical field with suspension needle in the study group. Total operative time referred to time from skin incision to skin suture. Amount of EBL was estimated by the amount of blood in a vacuum jar. Operative complications included ureteral injury, vascular injury, lymphocysts, intestinal obstruction, and deep vein thrombosis.

IBM SPSS Statistics for Windows, Version 19.0 (IBM Corp., Armonk, NY, USA) was used for data analysis. χ^2 analysis was used to assess categorical variables. The p-value <0.05 indicates significant differences.

RESULTS

There were 37 patients included in our study, with 20 cases in the study group and 17 cases in the control group. The average age of patients in the study group was 47.8 ± 7.5 , similar with that (52.3 ± 6.7) in the control group ($p=0.069$). And there was no difference in BMI of patients between the 2 groups (24.4 ± 1.7 vs. 24 ± 1.9 , $p=0.481$). In the study group, there were 8 (40.0%) cases of IB1 stage, 9 (45.0%) cases of IB2 stage and 3 (15.0%) cases of IIA1 stage. In the control group, there was 7 (41.2%) cases of IB2 stage, and 3 (17.6%) cases of IIA1 stage. The proportion of stage 1 (IB1 and IB2) was not significantly different between the 2 groups (85% vs. 82.5%, $p=0.828$) (**Table 1**). The patients in both groups received extended hysterectomies, pelvic lymphadenectomy and para-aortic lymphadenectomy. In addition, all of them had bilateral oophorectomy except 3 in the study group and one in the control group.

Table 1. Characteristic and outcome of 2 groups

Group	Study group (n=20)	Control group (n=17)	p
Age (yr)	47.8±7.5	52.3±6.7	0.069
BMI (kg/m ²)	24.4±1.7	24±1.9	0.481
Tumor stage (stage 1)	17 (85.0)	14 (82.4)	0.828
Number of PALN	18.2±1.2	12.2±2.4	<0.001
Time for PAL (min)	30.3±3	59.6±3.7	<0.001
Total operative time (min)	133.6±5.5	170.9±8.3	<0.001
Amount of blood loss volume (mL)	106.5±24.1	107.1±26.4	0.937
Incidence of complication	0	1 (5.9)	0.272
Aortic lymph node metastasis	3 (15.0)	2 (11.8)	0.774

BMI, body mass index; PAL, para-aortic lymphadenectomy; PALN, para-aortic lymph node.

As to the perioperative outcome, the average number of PALN resected in the study group was 18.2±1.2, significantly more than that (12.2±2.4) in the control group (p<0.001). Furthermore, the time for PAL decreased significantly in the study group than that in the control group (30.3±3 vs. 59.6±3.7, p<0.001). Similarly, total operative time was also significantly less in the study group (133.6±5.5 vs. 170.9±8.3, p<0.001). As expected, statistically significant differences were not found in terms of the average amount of EBL and incidence of complication. There was only one case who had postoperative lymphocyst in the control group. In the study group, 9 cases (45.0%) had lymph node metastases. Six (30.0%) cases of them had pelvic metastases, and the others had para-aortic metastases. In the control group, 7 cases (41.2%) had lymph node metastases. Five (29.4%) cases of them had pelvic metastases and 2 (11.8%) cases had para-aortic metastases. The incidence of aortic lymph node metastasis was not significantly different between the 2 groups (**Table 1**).

The learning curves of our new technique for 4 gynecologic surgeons showed that number of resected PALN increased (**Supplementary Fig. 2**) and time for PAL (**Supplementary Fig. 3**) decreased with increasing experience. It was presented that there was a plateau in their performance after 15 procedure.

DISCUSSION

According to previous literature, some novel technique had been introduced by other surgeons for laparoscopic PAL. Kavallaris et al. [12] modified trocar placement for PAL. A 10 mm trocar was inserted sub-umbilically for camera. A 10 mm trocar was placed in the left upper abdomen and 3 other 5 mm trocars in the lower abdomen. In his study, the number of removed PALN was 19, time for laparoscopic PAL was 64 minutes, and amount of EBL was 250 mL. Eisenkop [13] had used passive instrument positioners for PAL. In his study, the mean number of removed PALN was 10.4, the mean operative time was 140.1 minutes, and the mean amount of EBL was 72.3 mL. Zhang et al. [14] adopted a modified placement of 6 trocars for PAL. In his study, the number of removed PALN was 12 (range, 7–17), time for laparoscopic PAL was 70 minutes (range, 58–95), and amount of EBL was 200 ml (range, 100–600 mL). Da Costa reported 16 extraperitoneal laparoscopic PAL by robot-assisted laparoscopy [15]. The median lymph node number was 18 (range, 11–38), the median skin-to-skin operating time of infrarenal extraperitoneal para-aortic lymphadenectomy was 170 minutes (range, 90–225 minutes), and the median EBL was 50 mL (range, 10–600 mL). Maenpaa et al. [16] had used robotic-assisted operation with 6 trocars in upper abdomen for PAL with 83% success rate. In his study, the number of removed PALN was 12, time for the total operative time was 218 minutes (range, 140–341 minutes). Comparison with previous

Table 2. Comparison between previous literatures and our study

Author	Method	No. of trocars	No. of PALN	Time for PAL (min)	Total operative time (min)	Amount of blood loss volume (mL)
Kavallaris et al. [12]	A modified trocar placement	5	14 (12–24)	64±29	138±36	250 (120–300)
Eisenkop [13]	Passive instrument positioners	N/A	10.4±3.81	N/A	140.11±20.6	72.3±30.12
Zhang et al. [14]	A modified placement of 6 trocars	6	12 (7–17)	70 (58–95)	N/A	200 (100–600)
da Costa et al. [15]	Robot-assisted laparoscopy	6	N/A	N/A	170 (90–225)	50 (10–600)
Maenpaa et al. [16]	Six trocars in upper abdomen	6	12 (0–38)	N/A	218 (140–341)	100 (10–1,400)
Our study	An invented retroperitoneum suspension needle combined with modified trocar placement	4	18.2±1.2	30.3±3	133.6±5.5	106.5±24.1

N/A, not applicable; PAL, para-aortic lymphadenectomy; PALN, para-aortic lymph node.

studies, our new technique improved perioperative outcomes with increased resected PALN and decreased operation time. **Table 2** presented the comparison of perioperative outcome of different studies.

There are several advantages associated with our new technique. The first advantage is that with our suspension needle, the retroperitoneum could be suspended effectively and rapidly which fully expose the para-aortic area. This helps to increase the number of yielded PALN, and to reduce the operative time and the rate of complication because of improved visualization. In addition, our suspension needle could be used repeatedly with advantages of easy fabrication and low cost. Secondly, our modified trocar placement and the operator and first assistant turning around to face the monitor located at the head of the patient facilitates PAL. As the lymph nodes of level 4 are located under the umbilicus, it is difficult to resect these lymph nodes with control technique. With our new technique, the surgical field of level 4 is fully lit up by the camera placed above synchondroses pubis. And trocars at the periumbilical area, at left MacBurney site and lymph nodes of level 4 constitute a “operative triangle,” facilitating the operation procedure. Thirdly, only 4 trocars are required to complete the surgery. This reduced the wound to the patient and decreased the rate of clashing among instruments in the pelvic cavity. Lastly, it is relatively easy to control by doctors with a relatively shorter learning curve, which means that more patients would benefit from this approach.

In general, our new technique is effective and feasible for performing laparoscopic PAL in cervical cancer. Furthermore, this technique may be able to be applied to other surgeries which require laparoscopic PAL. However, studies involving a bigger sample size and different operators are needed to identify the role of the technique more comprehensively.

ACKNOWLEDGEMENTS

We thank Ping Hua, Zhimin Hu for their work on pathological results.

SUPPLEMENTARY MATERIALS

Supplementary Fig. 1

Sketch map of control trocar placement.

[Click here to view](#)

Supplementary Fig. 2

The learning curves of our new technique in terms of number of resected PALN.

[Click here to view](#)

Supplementary Fig. 3

The learning curves of our new technique in terms of time for PAL.

[Click here to view](#)

Supplementary Video 1

The process of suspending retroperitoneum with our needle.

[Click here to view](#)

REFERENCES

- Di J, Rutherford S, Chu C. Review of the cervical cancer burden and population-based cervical cancer screening in China. *Asian Pac J Cancer Prev* 2015;16:7401-7.
[PUBMED](#) | [CROSSREF](#)
- Shah M, Lewin SN, Deutsch I, Burke WM, Sun X, Herzog TJ, et al. Therapeutic role of lymphadenectomy for cervical cancer. *Cancer* 2011;117:310-7.
[PUBMED](#) | [CROSSREF](#)
- Querleu D, Morrow CP. Classification of radical hysterectomy. *Lancet Oncol* 2008;9:297-303.
[PUBMED](#) | [CROSSREF](#)
- Li D, Cai J, Kuang Y, Cao J, Wang Z. Surgical-pathologic risk factors of pelvic lymph node metastasis in stage Ib1-IIb cervical cancer. *Acta Obstet Gynecol Scand* 2012;91:802-9.
[PUBMED](#) | [CROSSREF](#)
- Dargent D, Ansquer Y, Mathevet P. Technical development and results of left extraperitoneal laparoscopic paraaortic lymphadenectomy for cervical cancer. *Gynecol Oncol* 2000;77:87-92.
[PUBMED](#) | [CROSSREF](#)
- Scribner DR Jr, Walker JL, Johnson GA, McMeekin DS, Gold MA, Mannel RS. Laparoscopic pelvic and paraaortic lymph node dissection in the obese. *Gynecol Oncol* 2002;84:426-30.
[PUBMED](#) | [CROSSREF](#)
- Recio FO, Piver MS, Hempling RE. Pretreatment transperitoneal laparoscopic staging pelvic and paraaortic lymphadenectomy in large (> or = 5 cm) stage IB2 cervical carcinoma: report of a pilot study. *Gynecol Oncol* 1996;63:333-6.
[PUBMED](#) | [CROSSREF](#)
- Koh WJ, Abu-Rustum NR, Bean S, Bradley K, Campos SM, Cho KR, et al. Cervical cancer, version 3.2019, NCCN clinical practice guidelines in oncology. *J Natl Compr Canc Netw* 2019;17:64-84.
[PUBMED](#) | [CROSSREF](#)
- Chung HH, Lee S, Sim JS, Kim JY, Seo SS, Park SY, et al. Pretreatment laparoscopic surgical staging in locally advanced cervical cancer: preliminary results in Korea. *Gynecol Oncol* 2005;97:468-75.
[PUBMED](#) | [CROSSREF](#)
- Leblanc E, Narducci F, Frumovitz M, Lesoin A, Castelain B, Baranzelli MC, et al. Therapeutic value of pretherapeutic extraperitoneal laparoscopic staging of locally advanced cervical carcinoma. *Gynecol Oncol* 2007;105:304-11.
[PUBMED](#) | [CROSSREF](#)
- Lee CL, Huang KG, Jain S, Lee PS, Soong YK. Comparison of laparoscopic and conventional surgery in the treatment of early cervical cancer. *J Am Assoc Gynecol Laparosc* 2002;9:481-7.
[PUBMED](#) | [CROSSREF](#)
- Kavallaris A, Kalogiannidis I, Chalvatzas N, Hornemann A, Bohlmann MK, Diedrich K. Standardized technique of laparoscopic pelvic and para-aortic lymphadenectomy in gynecologic cancer optimizes the perioperative outcomes. *Arch Gynecol Obstet* 2011;283:1373-80.
[PUBMED](#) | [CROSSREF](#)

13. Eisenkop SM. Total laparoscopic hysterectomy with pelvic/aortic lymph node dissection for endometrial cancer using passive instrument positioners: a retrospective case-control series. *J Minim Invasive Gynecol* 2018;25:800-9.
[PUBMED](#) | [CROSSREF](#)
14. Zhang X, Ding J, Hua K. Laparoscopic local extraperitoneal para-aortic lymphadenectomy: description of a novel technique. *Mol Clin Oncol* 2017;6:377-80.
[PUBMED](#) | [CROSSREF](#)
15. da Costa AG, Borghesi Y, Hudry D, Faes J, Bresson L, Narducci F, et al. Extraperitoneal para-aortic lymphadenectomy by robot-assisted laparoscopy. *J Minim Invasive Gynecol* 2018;25:861-6.
[PUBMED](#) | [CROSSREF](#)
16. Mäenpää MM, Nieminen K, Tomás EI, Luukkaala TH, Mäenpää JU. Robotic-assisted infrarenal para-aortic lymphadenectomy in gynecological cancers: technique and surgical outcomes. *Int J Gynecol Cancer* 2018;28:951-8.
[PUBMED](#) | [CROSSREF](#)