

## CASE REPORT

# Bacterial translocation as a cause of ventriculoperitoneal shunt infection: A case report

Brittany Owusu-Adjei<sup>1,2</sup> | Charles Ogagan<sup>1</sup>  | Jordan Smith<sup>1</sup>  | Gabrielle Luiselli<sup>1</sup> | Mark D. Johnson<sup>1,2</sup>

<sup>1</sup>Department of Neurological Surgery, University of Massachusetts Medical School, Worcester, Massachusetts, USA

<sup>2</sup>UMass Memorial Health, Worcester, Massachusetts, USA

## Correspondence

Mark D. Johnson, University of Massachusetts Medical School, Worcester, Massachusetts, USA.  
Email: mark.johnson3@umassmemorial.org

## Abstract

Bacterial translocation as a mechanism of distal catheter infection may play a larger role in ventriculoperitoneal shunt infections than previously recognized.

## KEYWORDS

bacterial translocation, shunt infection, ventriculoperitoneal shunt

## 1 | INTRODUCTION

We report the case of a patient who underwent ventriculostomy placement followed by shunt revision who developed colitis and subsequent shunt infection with *Enterococcus faecium*. We propose that infection of the shunt was the result of abdominal bacterial translocation occurring in the context of *Clostridium difficile* colitis.

Ventriculoperitoneal shunt (VPS) infection is a commonly observed complication in patients with a VPS and is associated with significant morbidity and mortality. The rate of VPS infection has been estimated to range from 5% to 10%.<sup>1</sup> Symptoms of shunt infection can be variable. Patients may develop fever, headache, nausea, vomiting, or confusion.<sup>2</sup> They may also present for care after the shunt has become obstructed and manifest symptoms caused by worsening hydrocephalus and/or elevated intracranial hypertension. VPS infections are usually caused by skin flora introduced at the time of shunt placement or from postoperative wound infection. This typically causes early shunt infection that occurs within the first few weeks to months after shunt placement.<sup>1,3,4</sup>

The most common organisms causing proximal VPS infections are coagulase negative *Staphylococcus* (60% of infections) and *Staphylococcus aureus* (30% of infections).<sup>1</sup> These bacteria attach to the surface of the catheter and form a biofilm.<sup>5</sup> Late shunt infections may occur months to years after implantation. In such cases, the most common organisms identified have been streptococcus, enterococcus or gram-negative bacteria such as pseudomonas or enterobacter.<sup>6</sup> These cases are typically seen in patients with peritonitis, peritoneal pseudocysts, or bowel perforation.<sup>6</sup>

Bacterial translocation is a process in which viable bacteria from the gastrointestinal (GI) tract migrate into the extra-intestinal space to reach lymph nodes, abdominal organs or the bloodstream. There are three proposed mechanisms by which bacterial translocation may occur: (1) disruption to the GI bacterial equilibrium leading to bacterial overgrowth, (2) increased permeability of the intestinal mucosal barrier, or (3) deficiencies in immune defenses.<sup>7</sup> In this case report, we discuss a case of a patient without bowel perforation or abdominal pseudocyst who developed an *Enterococcus faecalis* (*E. Faecalis*) infection

This is an open access article under the terms of the Creative Commons Attribution-NonCommercial-NoDerivs License, which permits use and distribution in any medium, provided the original work is properly cited, the use is non-commercial and no modifications or adaptations are made.

© 2022 The Authors. *Clinical Case Reports* published by John Wiley & Sons Ltd.

of his shunt after first developing *Clostridium difficile* (*C. difficile*) colitis. To our knowledge, there are few reports demonstrating distal shunt infection occurring as a result of bacterial translocation.

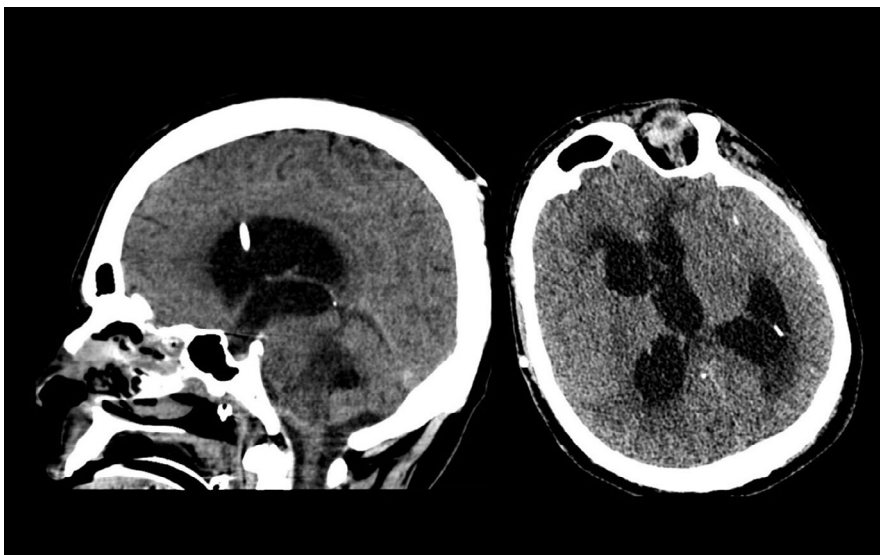
## 2 | CASE HISTORY

A 47-year-old male with a past medical history of neurocysticercosis and VPS placement for obstructive hydrocephalus 6 years earlier presented to the emergency department after being found down and unresponsive. A computerized tomogram (CT) of the head showed obstructive hydrocephalus of the lateral and third ventricles and transependymal spread of cerebrospinal fluid (CSF; Figure 1). His neurological examination was notable for pupils that were 3 mm and reactive bilaterally. He was non-verbal, his eyes were closed, and he was not following verbal commands. There was extensor posturing to painful stimulation. He was intubated for airway protection.

The shunt was tapped emergently to obtain CSF for analysis and to reduce the intracranial pressure, which was noted to be very low despite the enlarged ventricles. Results of the CSF analysis showed the following: protein 20 mg/dl, glucose 81 mg/dl, 3 WBC/mm<sup>3</sup> and 33 RBC/mm<sup>3</sup>. No organisms were seen on the gram stain and CSF culture revealed no growth. The patient was subsequently taken to the operating room for a shunt revision for VPS malfunction with the goal of re-establishing CSF drainage in hopes of improving neurologic function. Intraoperatively, the ventricular catheter was disconnected from the valve and there was no spontaneous flow of CSF. However, CSF was easily aspirated from the proximal catheter, suggesting very low intracranial pressure. Manometry was

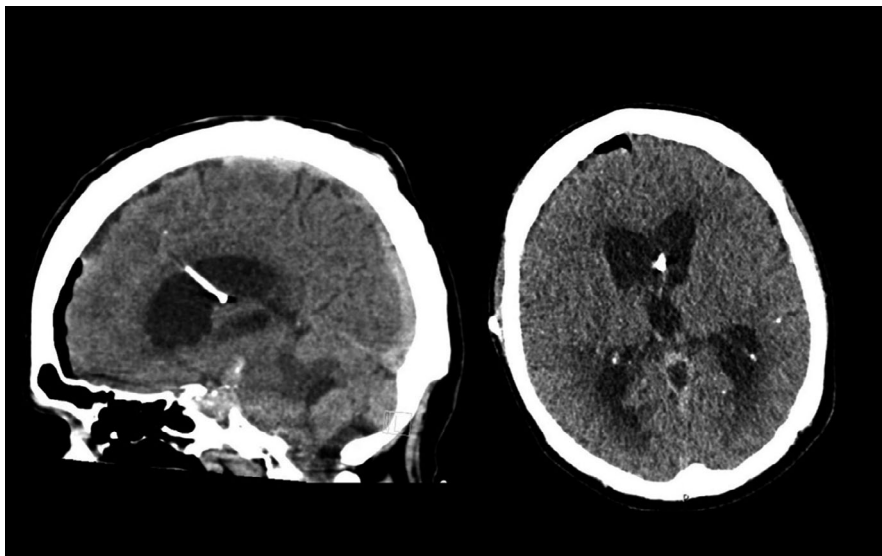
used to assess flow through the shunt valve and distal catheter, and a shunt valve obstruction was identified. The obstructed valve was removed and a new valve was connected to the ventricular and distal peritoneal catheters.

Postoperatively, the patient remained intubated and was transferred to the intensive care unit (ICU) with a continuously poor neurological examination: remained minimally responsive to noxious stimulation, no spontaneous movement, and brainstem reflexes intact. The ventricles remained markedly enlarged and his neurological examination failed to improve, despite progressively lowering the shunt valve setting to 30 mm of H<sub>2</sub>O by postoperative day 2. An external ventricular drain (EVD) was placed on postoperative day 3 and set at 5 mm Hg to increase CSF drainage and decrease ventricular size. On postoperative day 4, the ventricles were noted to have decreased in size significantly, and the patient began to follow commands in all 4 extremities. He was extubated on postoperative day 6. A repeat head CT showed that the decrease in ventricular size now resulted in the shunt ventricular catheter no longer being in the ventricle. Consequently, the EVD was weaned and on hospital day 16 and the patient underwent a shunt revision where the ventricular catheter was replaced. The valve and distal peritoneal catheter were not changed (Figure 2). The shunt valve was set at 30 mm H<sub>2</sub>O. Because the patient continued to improve neurologically and the ventricles remained small, he was transferred out of the ICU on hospital day 21. Of note, he complained of right abdominal pain, fever, and had a markedly elevated WBC for several days. An evaluation revealed an infectious colitis. This was treated with a 7-day course of flagyl, and his symptoms improved.

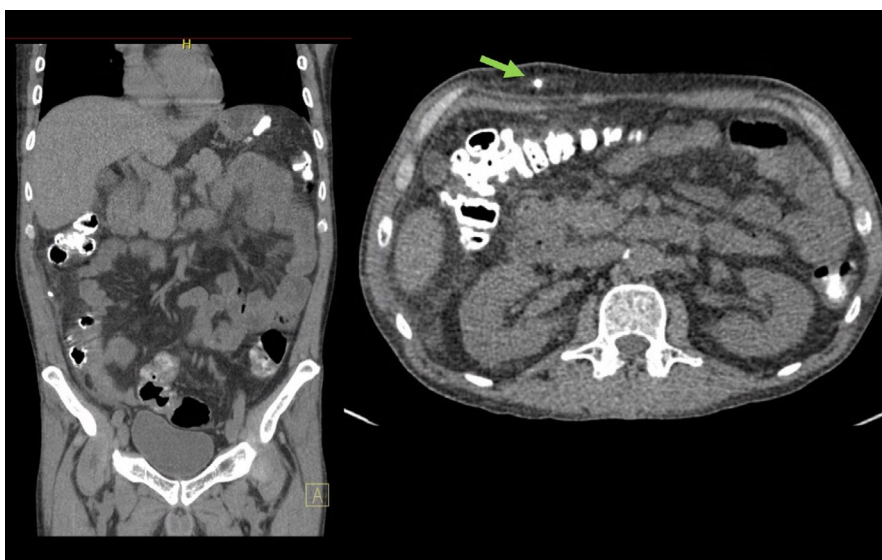

**FIGURE 1** CT of the patient's head (sagittal section on left, axial section on right) on hospital day 1 showing marked hydrocephalus of the lateral and third ventricles with evidence of transependymal flow of CSF

**FIGURE 2** CT of the patient's head (sagittal section on left, axial section on right) on hospital day 16 after shunt revision

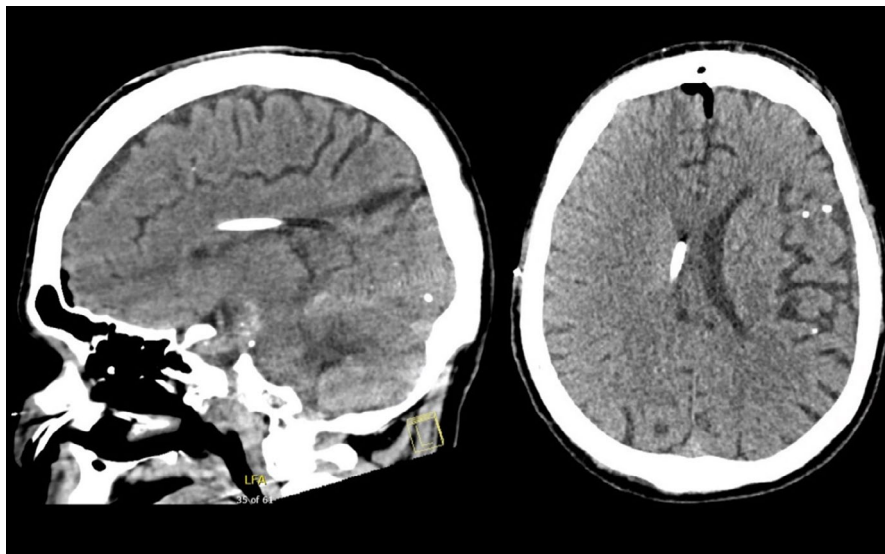


**FIGURE 3** CT of the patient's abdomen with oral contrast (coronal section on the left, axial section on the right) on hospital day 32 showing diffuse inflammation of the large colon with fat stranding in the right lower quadrant. The green arrow indicates the distal shunt catheter in the subcutaneous space



On hospital day 29 (one day after cessation of flagyl therapy for colitis), the patient complained of worsening abdominal pain, nausea, and vomiting. On hospital day 31, he became obtunded, febrile (39.2°C), tachycardic, and diaphoretic with new diarrhea. He displayed minimal withdrawal to pain and grimaced to abdominal palpation. A fever workup was completed, which revealed an elevated white blood cell count (WBC) of 24,500/ $\mu$ L, c-reactive protein of 105.1 mg/L, and an erythrocyte sedimentation rate of 33 mm/h, all indicative of an infectious process. The shunt was tapped, and the CSF WBC was found to be 126 with 75% monocytes/macrophages, glucose 55 mg/dl and protein 61 mg/dl. Empiric antibiotics (cefepime, metronidazole, and vancomycin), as well as antiparasitic agents (albendazole and praziquantel) and prednisone, were initiated. CT abdomen with PO

contrast revealed diffuse mural thickening and mucosal enhancement throughout the colon and rectum with skip areas, correlating with Crohn's disease. In addition, there were areas of adjacent fat stranding terminating in the right lower quadrant with minimal fluid adjacent to the cecum, consistent with an infectious colitis etiology (Figure 3). A stool culture was positive for *C. difficile*. After 2 days, CSF cultures grew *E. Faecalis*. A head CT showed worsening hydrocephalus and a ventriculostomy drain was placed. The entire shunt was then removed. The patient was treated with oral vancomycin for *C. difficile* and ampicillin for CNS *E. faecalis* ventriculitis. The patient's mental status improved, and a new shunt was placed on hospital day 58 (Figure 4). After discharge, the patient was seen in the outpatient clinic and was noted to have made a full neurological recovery.



**FIGURE 4** CT of the patient's head (sagittal section on left, axial section on right) on hospital day 58 showing markedly decreased size of the ventricles

### 3 | DISCUSSION

Infections occur after 2%–22% of VPS surgeries globally.<sup>1,8–10</sup> VPS infections can present with obtundation or altered mental status, especially if the infection causes shunt obstruction, ventriculomegaly, or severely elevated intracranial pressure. Most cases of VPS infection are due to proximal shunt infections caused by skin flora such as coagulase negative staphylococcus (40%–80%) or *S. aureus* (20%–30%), while gram negative bacilli like *Propionibacterium acnes* account for about 2%–15%.<sup>1,2,11,12</sup> Distal shunt catheter infections account for <10% of VPS infections, and are often accompanied by bowel perforation, peritonitis or abdominal pseudocyst.<sup>1,2,4,11–13</sup> The most common bacteria involved in distal shunt infections are *enterococcus* or *enterobacteriaceae*.<sup>2,12</sup> Thus, the bacterial flora causing distal shunt infections are more often bowel organisms and differ significantly from the skin flora that most commonly cause proximal shunt infections. Although distal shunt catheter infections are less common than proximal shunt infections, they have nevertheless been widely reported in the literature. Bowel perforation associated with VPS placement is a very rare complication.<sup>14</sup> Bowel perforation in the setting of VPS placement is a surgical emergency because it can lead to sepsis or fatal meningeal infection with a mortality rate approaching 15%.<sup>15</sup>

Peritoneal CSF pseudocyst is another abdominal complication associated with VPS infection. An abdominal pseudocyst occurs when a fibrous tissue or inflamed serosal membrane forms a CSF filled cyst, usually around the distal catheter tip. One study reported pseudocyst formation in 8.6% of VPS patients.<sup>15</sup> Although abdominal pseudocysts can be sterile, they are often felt to be a consequence of shunt infection.

The unique nature of the case reported here is that the patient developed signs of *C. difficile* colitis several days before he developed signs of early CNS infection with *E. faecalis*, which is typically found in the bowel. Whereas there was clear evidence of colitis on abdominal images, there was no evidence of bowel perforation or pseudocyst formation.

Bacterial translocation is a process by which viable gut flora migrate from the GI tract into the extra-intestinal space. There are several proposed mechanisms that may contribute to this phenomenon, including bacterial overgrowth, increased permeability of the GI epithelial barrier or immune deficiency.<sup>7</sup> Although bacterial translocation has been studied extensively, its role in VP shunt distal catheter infection has not been examined carefully. Our search of the literature identified a single report that describes a patient who was felt to have developed VPS infection via bacterial translocation. Like our patient, the patient in that report also developed an *E. faecalis* (and *E. coli*) infection in the setting of *C. difficile* colitis. In that case, the patient developed headache, nausea, vomiting, and diarrhea three months after shunt placement.<sup>16</sup> Our patient developed signs of *C. difficile* colitis several days before any evidence of CNS infection, suggesting that the infection began in the abdomen. It is important to note that the abdomen was not entered and the distal catheter was not manipulated prior to the development of shunt infection, and yet all signs pointed to an abdominal origin for the infection. After our patient developed mental status changes, CSF analysis showed signs of an early infectious process with elevated monocytes and no organisms seen on gram stain. Two days later, the CSF cultures began to grow *E. faecalis*. We propose that increased intestinal permeability caused by the *C. difficile* colitis led to *E. faecalis* translocation and subsequent infection of the shunt.

The finding that a larger proportion of bacteria infecting distal shunt catheters are from the bowel raises the question of why that is the case, since most such infections occur in the absence of bowel perforation. The case reported here suggests that bacterial translocation may be a contributor to this process. In fact, bacterial translocation may play a larger role in VPS infections than reported in the literature. At a minimum, this is a topic that needs further investigation. Practitioners should be aware of the risk of distal VP shunt infection in patients with colitis.

## ACKNOWLEDGMENTS

None.

## CONFLICT OF INTEREST

None declared.

## AUTHOR CONTRIBUTIONS

Brittany Owusu-Adjei MD: Contributed to conception, literature review and drafting. Charles Ogagan BS: Contributed to literature review, drafting and preparation of manuscript. Jordan Smith BS: Contributed to drafting and revision of manuscript. Gabrielle Luiselli BS: Contributed to drafting and revision of manuscript. Mark Johnson MD, PhD: Contributed to conception, literature review and drafting.

## CONSENT

Published with written consent of the patient.

## DATA AVAILABILITY STATEMENT

Data sharing not applicable to this article as no datasets were generated or analysed during the current study.

## ORCID

Charles Ogagan  <https://orcid.org/0000-0001-7596-0071>

Jordan Smith  <https://orcid.org/0000-0003-0460-0647>

## REFERENCES

- Javedan SP, ReKate HL. Encyclopedia of the Neurological Sciences. 2003. <https://www.sciencedirect.com/topics/medicine-and-dentistry/shunt-infection>. Accessed December 3, 2021.
- Conen A, Walti LN, Merlo A, et al. Characteristics and treatment outcome of cerebrospinal fluid shunt-associated infections in adults: a retrospective analysis over an 11-year period. *Clin Infect Dis*. 2008;47(1):73-82. <https://doi.org/10.1086/588298>
- Chakraborty A, Drake JM, Warf BC. *Schmidek and Sweet Operative Neurosurgical Techniques*, 6th edn, 2012. <https://www.sciencedirect.com/topics/medicine-and-dentistry/shunt-infection>
- Forward KR, Fewer HD, Stiver HG. Cerebrospinal fluid shunt infections. A review of 35 infections in 32 patients. *J Neurosurg*. 1983;59(3):389-394. <https://doi.org/10.3171/jns.1983.59.3.0389>
- Gutierrez-Murgas Y, Snowden JN. Ventricular shunt infections: immunopathogenesis and clinical management. *J Neuroimmunol*. 2014;276(1-2):1-8. <https://doi.org/10.1016/j.jneuroim.2014.08.006>
- Wells DL, Allen JM. Ventriculoperitoneal shunt infections in adult patients. *AACN Adv Crit Care*. 2013;24(1):6-14. <https://doi.org/10.1097/NCI.0b013e31827be1d1>
- Berg RD. Bacterial translocation from the gastrointestinal tract. *J Med*. 1992;23(3-4):217-244.
- Mayhall CG, Archer NH, Lamb VA, et al. Ventriculostomy-related infections. A prospective epidemiologic study. *N Engl J Med*. 1984;310(9):553-559. <https://doi.org/10.1056/NEJM198403013100903>
- Schoenbaum SC, Gardner P, Shillito J. Infections of cerebrospinal fluid shunts: epidemiology, clinical manifestations, and therapy. *J Infect Dis*. 1975;131(5):543-552. <https://doi.org/10.1093/infdis/131.5.543>
- Cochrane DD, Kestle JR. The influence of surgical operative experience on the duration of first ventriculoperitoneal shunt function and infection. *Pediatr Neurosurg*. 2003;38(6):295-301. <https://doi.org/10.1159/000070413>
- Wang KW, Chang WN, Shih TY, et al. Infection of cerebrospinal fluid shunts: causative pathogens, clinical features, and outcomes. *Jpn J Infect Dis*. 2004;57(2):44-48.
- Pelegrín I, Lora-Tamayo J, Gómez-Junyent J, et al. Management of ventriculoperitoneal shunt infections in adults: analysis of risk factors associated with treatment failure. *Clin Infect Dis*. 2017;64(8):989-997. <https://doi.org/10.1093/cid/cix005>
- Lee JK, Seok JY, Lee JH, et al. Incidence and risk factors of ventriculoperitoneal shunt infections in children: a study of 333 consecutive shunts in 6 years. *J Korean Med Sci*. 2012;27(12):1563-1568. <https://doi.org/10.3346/jkms.2012.27.12.1563>
- Vinchon M, Baroncini M, Laurent T, Patrick D. Bowel perforation caused by peritoneal shunt catheters: diagnosis and treatment. *Neurosurgery*. 2006;58(suppl\_1):ONS-76-ONS-82. <https://doi.org/10.1227/01.NEU.0000192683.26584.34>
- Chung JJ, Yu JS, Kim JH, et al. Intraabdominal complications secondary to ventriculoperitoneal shunts: CT findings and review of the literature. *AJR Am J Roentgenol*. 2009;193(5):1311-1317. <https://doi.org/10.2214/AJR.09.2463>
- Kang D, Wasfie T, Jackson A, Henke A. Ventriculo-peritoneal shunt infection secondary to translocation of gut bacteria without evidence of peritonitis. *J Clin Res Med*. 2019;2(1):1-2. <https://doi.org/10.31038/JCRM.2019212>

**How to cite this article:** Owusu-Adjei B, Ogagan C, Smith J, Luiselli G, Johnson MD. Bacterial translocation as a cause of ventriculoperitoneal shunt infection: A case report. *Clin Case Rep*. 2022;10:e04921. <https://doi.org/10.1002/ccr3.4921>