

Intracranial hypertension and visual loss following COVID-19: A case report

Bayazit Ilhan, Burcu G Cokal¹, Yusuf Mungan

A 40-year-old woman presented with headache, bilateral optic disc edema, and visual loss. She had been diagnosed with COVID-19 (coronavirus disease 2019) 15 days ago. Her cerebrospinal fluid opening pressure was 410 mmH₂O, and cranial imaging was normal. She had obesity as a risk factor but had not experienced any ophthalmic complaints before. COVID-19 could be a causative or precipitating factor for intracranial hypertension especially in high-risk groups even in the late phases of the disease and has not been discussed in the literature as such. This should be studied further and kept in mind to prevent permanent loss of vision.

Key words: COVID-19, intracranial hypertension, optic disc edema, visual loss

The coronavirus disease 2019 (COVID-19) pandemic, caused by severe acute respiratory syndrome coronavirus 2 (SARS-CoV-2), is the main current health issue all over the world. The main presentation is with respiratory symptoms, but neurological problems are being reported increasingly. Encephalopathy, encephalitis, Guillain-Barré syndrome, and cerebrovascular disease are the most frequently reported neurological conditions.^[1] Headache is a frequent

complaint in COVID-19 patients, and isolated intracranial hypertension (IHT) has been reported among patients who underwent lumbar puncture for refractory headaches.^[2] Elevated intracranial pressure, mostly mild, has also been reported among patients with various neurologic diseases associated with COVID-19.^[3] IHT with loss of vision has not been described in the late phases of the disease in the literature. We present such a case that developed 15 days after the diagnosis of COVID-19.

Case Report

A 40-year-old woman presented to our ophthalmology emergency room with severe headache and loss of vision. She had been diagnosed with COVID-19 15 days ago with nasopharyngeal swab PCR (polymerase chain reaction) positive test result following 3 days of upper respiratory tract infection symptoms and fever up to 38°C. She had used hydroxychloroquine and favipiravir for 5 days and recovered without further complaints.

Her visual acuity was logMAR 0.3 in both eyes. Pupillary light reactions and color vision were normal. She had optic disc edema in both eyes, and visual field testing revealed severe narrowing [Fig. 1]. She had obesity, and her BMI (body mass index) was 39. Her blood pressure was normal. Neurologic examination did not reveal further findings. Cerebrospinal fluid (CSF) pressure was 410 mmH₂O on entry and 210 mmH₂O on exit. CSF biochemical analyses were normal, and cultures for microbial analysis were negative. There were old erythrocytes (640/mm³), new erythrocytes (9600/mm³), and white blood cells (WBCs; 50/mm³) with 100% polymorphonuclear leucocytes (PMNs).

Blood tests revealed vitamin B12 deficiency (127.2 ng/L). Cranial computed tomography (CT) and magnetic resonance imaging (MRI) did not reveal any mass, hemorrhage, or cerebrovascular lesion. Magnetic resonance venography was normal. Acetazolamide 3 × 250 mg was started, and ventriculoperitoneal shunt surgery was planned to effectively decrease CSF pressure without delay because of imminent

Access this article online	
Quick Response Code:	Website: www.ijjo.in
	DOI: 10.4103/ijjo.IJO_342_21

University of Health Sciences, Ministry of Health Ulucanlar Eye Education and Research Hospital, Department of Ophthalmology, ¹University of Health Sciences, Ministry of Health Ankara Education and Research Hospital Department of Neurology, Ankara, Turkey

Correspondence to: Dr. Bayazit Ilhan, Ulucanlar Goz Egitim ve Arastirma Hastanesi Ulucanlar Caddesi No: 59 06250 Altindag, Ankara, Turkey. E-mail: ilhanbayo@yahoo.com

Received: 08-Feb-2021

Revision: 27-Feb-2021

Accepted: 09-Apr-2021

Published: 21-May-2021

This is an open access journal, and articles are distributed under the terms of the Creative Commons Attribution-NonCommercial-ShareAlike 4.0 License, which allows others to remix, tweak, and build upon the work non-commercially, as long as appropriate credit is given and the new creations are licensed under the identical terms.

For reprints contact: WKHLRPMedknow_reprints@wolterskluwer.com

Cite this article as: Ilhan B, Cokal BG, Mungan Y. Intracranial hypertension and visual loss following COVID-19: A case report. Indian J Ophthalmol 2021;69:1625-7.

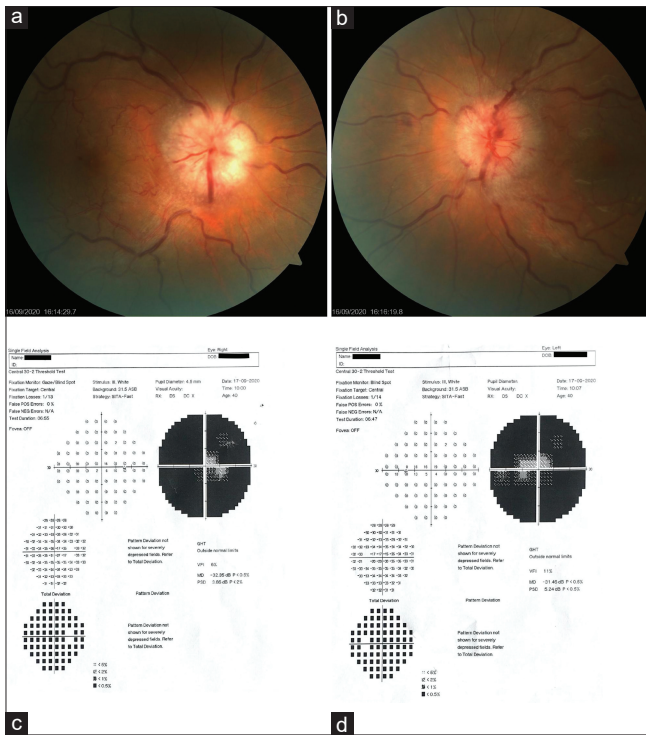


Figure 1: Fundus photographs of right (a) and left (b) eyes and visual fields of right (c) and left (d) eyes on admission

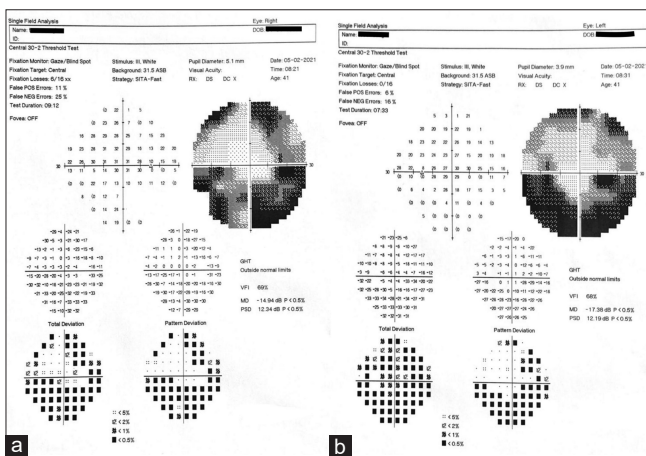


Figure 3: Visual fields of right (a) and left (b) eyes 5 months after the initiation of treatment

total visual loss, severe headache, and very high intracranial pressure. She did not accept surgical intervention. Diet and exercise programs were advised, and vitamin B12 deficiency treatment was given.

Her ophthalmic findings got better within a short time. The severity of headache decreased within 2 weeks. Forty days after the initiation of treatment, her visual acuities were logMAR 0.1 in both eyes, visual fields were better, papilledema resolved, and disc pallor appeared [Fig. 2]. She could not lose weight. Her CSF pressure was 320 mmH₂O on entry, and cell analysis revealed 210 new erythrocytes and no old erythrocytes and leukocytes. Acetazolamide dose increased to 4 × 250 mg because intracranial pressure was

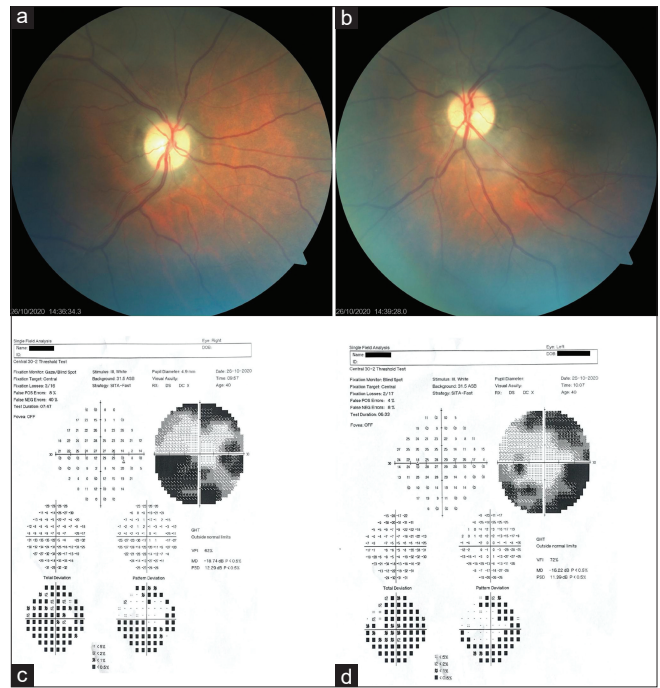


Figure 2: Fundus photographs of right (a) and left (b) eyes and visual fields of right (c) and left (d) eyes 40 days after the initiation of treatment

still high and she could not lose weight. Diet and exercise programs were strongly advised again. Five months after the initial diagnosis, visual acuities were logMAR 0 in both eyes, and visual fields were protected, close to visual fields at 40 days [Fig. 3]. She continues acetazolamide 4 × 250 mg treatment.

Discussion

In one study, CSF pressure was elevated in 30.8% of COVID-19 patients with different neurological conditions.^[3] The CSF pressure was less than 300 mmH₂O in most of them. None of the patients was a late presentation with IHT and related loss of vision.

The mechanism of IHT in COVID-19 can be variable and controversial. High CSF neurofilament light chain (NfL) proteins were reported to be associated with high CSF pressure, which could be a sign of an active and exacerbated inflammatory process.^[3] Another mechanism related to IHT is cerebral venous sinus thrombosis (CVST), which is reported in COVID-19 patients.^[4] CVST was not present in our patient.

Obesity, female gender, and childbearing age are the main risk factors for idiopathic IHT.^[5] Idiopathic IHT is still very rare, with 12 to 20 per 100,000 people affected per year in this group. The mechanisms related to these risk factors are not clear. Obesity is increasingly perceived as an inflammatory disorder. Cytokines, in particular adipokines, which are specifically produced by adipose tissue, were studied and markers of inflammation were present in the CSF of patients with idiopathic IHT. Our patient was in this high-risk group but had no history of disturbing headache, symptoms, and signs of IHT, and she had no ophthalmic complaints before COVID-19.

It is not possible to declare a cause and effect relationship with just one case, but this case shows that COVID-19 could be a precipitating factor for IHT in this high-risk group, and when we search the literature, our patient is the first case discussed on this ground.

CSF analysis in our patient revealed old erythrocytes ($640/\text{mm}^3$) and WBCs ($50/\text{mm}^3$), which were not present in the second analysis performed 40 days later. These findings could be due to the proinflammatory response of COVID-19 on brain vascular endothelium.^[6]

Treatment and prognosis of IHT have not been discussed as a different entity in COVID-19 patients in the literature. We planned the treatment as described for idiopathic IHT cases.^[5] We planned surgery to further reduce intracranial pressure because of severe loss of visual field on the first visit. She did not accept surgery, but the prognosis was still good with medical treatment.

Conclusion

COVID-19 could be a causative or precipitating factor for IHT, especially in high-risk groups, even in the late phases of the disease. This should be studied further and kept in mind to prevent severe morbidity related to permanent loss of vision in these patients.

Declaration of patient consent

The authors certify that they have obtained all appropriate patient consent forms. In the form the patient(s) has/have given his/her/their consent for his/her/their images and other clinical information to be reported in the journal. The patients

understand that their names and initials will not be published and due efforts will be made to conceal their identity, but anonymity cannot be guaranteed.

Financial support and sponsorship

Nil.

Conflicts of interest

There are no conflicts of interest.

References

1. Ellul MA, Benjamin L, Singh B, Lant S, Michael BD, Easton A, *et al.* Neurological associations of COVID-19. *Lancet Neurol* 2020;19:767-83.
2. Silva MTT, Lima MA, Torezani G, Soares CN, Dantas C, Brandão CO, *et al.* Isolated intracranial hypertension associated with COVID-19. *Cephalalgia* 2020;40:1452-8.
3. Espíndola OM, Brandão CO, Gomes YCP, Siqueira M, Soares CN, Lima MASD, *et al.* Cerebrospinal fluid findings in neurological diseases associated with COVID-19 and insights into mechanisms of disease development. *Int J Infect Dis* 2021;102:155-62.
4. Medicherla CB, Pauley RA, de Havenon A, Yaghi S, Ishida K, Torres JL. Cerebral venous sinus thrombosis in the COVID-19 pandemic. *J Neuroophthalmol* 2020;40:457-62.
5. Markey KA, Mollan SP, Jensen RH, Sinclair AJ. Understanding idiopathic intracranial hypertension: Mechanisms, management, and future directions. *Lancet Neurol* 2016;15:78-91.
6. Buzhdygan TP, DeOre BJ, Baldwin-Leclair A, Bullock TA, McGary HM, Khan JA, *et al.* The SARS-CoV-2 spike protein alters barrier function in 2D static and 3D microfluidic in-vitro models of the human blood-brain barrier. *Neurobiol Dis* 2020;146:105131.