

Efficacy of Local Anesthesia in the Face and Scalp: A Prospective Trial

Tyler Safran, MD*
 Dino Zammit, MD*
 Jonathan Kanevsky, MD, FRCSC†
 Manish Khanna, MD, FRCPC‡

Background: The use of local anesthesia has allowed for the excision and repair of lesions of the head and neck to be done in an office-based setting. There is a gap of knowledge on how surgeons can improve operative flow related to the onset of action. A prospective trial was undertaken to determine the length of time for full anesthesia effect in the head and neck regions.

Methods: Consecutive patients undergoing head and neck cutaneous cancer resection over a 3-month period were enrolled in the study. Local anesthesia injection and lesion excision were all done by a single surgeon. All patients received the standard of care of local anesthesia injection.

Results: Overall, 102 patients were included in the prospective trial. The upper face took significantly longer (153.54 seconds) compared with the lower face and ears (69.37 and 60.2 seconds, respectively) ($P < 0.001$) to become fully anesthetized. In addition, there was no significant difference found when adjusting for the amount of local anesthesia used, type, and size of lesion ($P > 0.05$). Using the time to full anesthesia effect for each local injection, a heat map was generated to show the relative times of the face and scalp to achieve full effect.

Conclusions: This prospective trial demonstrated that for the same local anesthetic and concentration, upper forehead and scalp lesions take significantly longer to anesthetize than other lesions in the lower face and ear. This can help surgeons tailor all aspects of their practice, which utilizes local anesthesia to help with patient satisfaction and operative flow. (*Plast Reconstr Surg Glob Open* 2019;7:e2243; doi: 10.1097/GOX.0000000000002243; Published online 16 May 2019.)

INTRODUCTION

The excision and repair of cutaneous cancers of the head and neck is predominantly performed in office-based procedure rooms under local anesthesia. The appeal of using local anesthesia is due to the minimal downtime and avoidance of postoperative hospitalization or observation. In addition, the benefits of local anesthesia include ease of administration, rapid onset of action, and do not require the services of an anesthesiologist. Despite the low rate of complications and well-studied safety

profile, its administration is a source of significant anxiety to patients.¹ In some cases, even more than the procedure itself. Both patients and surgeons equally wish to ensure adequate anesthesia for the entire duration of the procedure.

To this effect, a breadth of evidence exists that is dedicated to the art and science of local anesthesia to increase its effectiveness and duration while minimizing the pain of injection.² This includes, but is not limited to, buffering the anesthetic solution, adding epinephrine, warming the anesthetic, and patient distraction on injection, thereby leveraging the gate theory of pain.^{2,3} A recurrent topic of discussion in the literature is improving the time of onset, thereby improving operative flow and avoiding the need to have significant blocks of time dedicated to reassessing the anesthesia. Certain regional blocks in the head and neck can be quite difficult to perform, especially if the clinician is not familiar with the complex anatomy. With this in mind, surgeons often perform a ring block: using infiltrative local anesthesia around and beneath the lesion in the subdermal/adipose plane.

The trigeminal nerve contributes a majority of the robust sensory nerve distribution to the face and scalp.⁴ The

*From the *Division of Plastic and Reconstructive Surgery, McGill University Health Center, Montreal, QC, Canada; †Division of Plastic and Reconstructive Surgery, University of Southern California, Los Angeles, Calif.; and ‡Division of Dermatology-Oncology, Sir Mortimer B. Davis-Jewish General Hospital, Montreal, QC, Canada.*

Received for publication February 4, 2019; accepted March 8, 2019.

Copyright © 2019 The Authors. Published by Wolters Kluwer Health, Inc. on behalf of The American Society of Plastic Surgeons. This is an open-access article distributed under the terms of the Creative Commons Attribution-Non Commercial-No Derivatives License 4.0 (CCBY-NC-ND), where it is permissible to download and share the work provided it is properly cited. The work cannot be changed in any way or used commercially without permission from the journal.

DOI: 10.1097/GOX.0000000000002243

Disclosure: The authors have no financial interest to declare in relation to the content of this article.

trigeminal nerve yields 3 branches: the ophthalmic nerve (V1), the maxillary nerve (V2), and the mandibular nerve (V3).⁴ Recently, with the advent of migraine surgery and improved techniques in facial reconstruction and rejuvenation, the trigeminal nerve has been extensively studied, yielding new branches and cutaneous nerves that were not previously identified, such as the accessory nerves of the forehead.⁵ Through anatomical studies, it has been shown that the volume and quantity of main branches of the trigeminal nerve decrease in the cranial direction.^{5,6} Building on this concept, when performing head and neck cutaneous cancer excisions, the authors of the present study noticed that lesions in the mid-forehead and scalp took significantly longer for the local anesthesia to take effect. The question became, why did lesions in this region take longer to achieve anesthesia?

To address this clinical question and attempt to optimize local anesthesia administration in this patient population, the authors designed a prospective trial of head and neck cutaneous cancer patients undergoing an excision under local anesthesia. Armed with this information, surgeons will be better suited to tailor the anesthetic demands of procedures in this anatomical region.

METHODS

Comparison Trial

To assess the effectiveness of local anesthesia in the face and scalp region, consecutive patients undergoing head and neck cutaneous cancer resection over the period of 3 months (October 2017–December 2017) were enrolled into a prospective trial. The administration of local anesthesia and all surgeries were performed by a single surgeon. All patients were made aware of the trial and received the standard of care for local anesthesia administration. Data collected included type of lesion, age of patient, location of lesion, amount of local anesthesia injected, and time to adequate anesthesia. Given the inherent interest in the location of each lesion, 3 groups were created. Patients were divided into the ear category, lower face, and upper face. The temple region lateral to the lateral canthus was considered lower face, given the distribution of cutaneous nerves to that area are derived from the midface.⁴ Upper face was limited posteriorly by the occipital scalp.

Anesthesia

Lidocaine 1% with epinephrine (1:100,000) was used for all procedures. The lidocaine was buffered with sodium bicarbonate (8.4% solution) by combining 20 cc of lidocaine with 2 cc of the sodium bicarbonate solution. Lesions were first prepared and marked, followed by a single injection in the subdermal/subcutaneous plane, using a Q-tip distractor, until the infiltrative anesthesia was visible for 5 mm surrounding the lesion. The 5 mm of infiltrative anesthesia was common for all lesions in the study, and all infiltrations were performed with one introduction of the needle under the lesion. Time began once the injection was started for all lesions.

Timing

Timing would begin on injection and would end with sufficient anesthesia of the lesion. To test sufficiency, after injection, the surgeon would test pin-prick sensation at 5 points around the lesions: centrally and at each quadrant just outside the markings of the lesion. If any patient required additional local anesthesia throughout the excision, the patient was excluded from the prospective study, given the inability to compare data.

Data Collection and Synthesis

Analysis of data was performed using SPSS v.22 (IBM Corp., Armonk, N.Y.). Outcomes were compared using a *t* test. All calculated *P* values were 2-tailed and considered significant for values of $P < 0.05$.

RESULTS

Patient Demographics

Between October 1, 2017, and December 1, 2017, 114 patients underwent face and scalp cutaneous cancer excision. Twelve patients (all with lesions in the scalp) were excluded for having required additional anesthesia. In all, 102 patients were included in the prospective study. Among the patients included, 61.8% ($n = 63$) were men and 38.2% ($n = 39$) women. The average age of patients included was 74.3 years old ($n = 102$).

Location of Lesions

Lesions were mainly found in the lower region, the face (60.8%; $n = 62$), followed by the upper region (29.4%; $n = 30$), and finally the ear (9.8%; $n = 10$). Of the lesions included, 72.5% ($n = 74$) were confirmed by pathology to be basal cell carcinomas (BCC), 26.5% ($n = 27$) were squamous cell carcinomas (SCC), and 0.01% ($n = 1$) were lentigo maligna (LM).

Amount of Local Anesthesia Injected

When comparing the amount of local anesthesia injected, there were no significant differences between any of the groups ($P > 0.05$). The upper face required a mean of 6.06 cc ($n = 30$), the lower face required 4.74 cc ($n = 62$; $P = 0.08$), and the ear required 3.76 cc ($n = 10$; $P = 0.12$) of local anesthesia. Additionally, there was no significant difference between amount injected and the type of lesion (comparing SCC, BCC, and LM; $P > 0.05$).

Size of Lesion

When comparing the average size of lesions between anatomical regions, there was no significant difference between the sites ($P > 0.05$). Upper face had a mean size of 253.2 mm² ($n = 30$), lower face 187.23 mm² ($n = 62$; $P = 0.2$), and ear 199.9 mm² ($n = 10$; $P = 0.2$).

Time to Anesthesia

When comparing time to anesthesia for types of lesions, there was no significant difference between SCC, BCC, and LM ($P > 0.05$). There was, however, a significant difference between upper face (mean, 153.54 seconds)

Table 1. Time to Block and Amount Injected Per Lesion Type

Lesion Type	Time to Block (s)	Local Anesthesia Injected (cc)	n
SCC	112.2	6.4	27
BCC	86.3	4.6	74
LM	60.0	2.3	1

Table 2. Time to Block and Amount Injected Per Anatomical Location

Location	Time to Block (s)	Local Anesthesia Injected (cc)	n
Upper	153.5	6.057	30
Lower	70.8	4.74	62
Ear	60.2	3.74	10

and both lower face (mean, 69.37 seconds) ($P < 0.001$) and ears (mean, 60.2 seconds) ($P < 0.001$). There was, however, no difference when comparing lower face with ear group ($P = 0.2$). A full breakdown of results can be seen in Tables 1–3.

DISCUSSION

This prospective trial looking at the speed of onset of local anesthesia was successful in demonstrating a significant difference in time of onset between upper and lower regions of the face, when controlling for concentration and type of anesthesia. The upper face took significantly longer time (153.54 seconds), than both lower face (69.37

Table 3. Time to Block and Amount Injected Per Specific Anatomical Location

	Location	Time to Block (s)	Local Anesthesia Injected (cc)	N	
Upper face	Occipital scalp	210.0	11.5	2	
	Vertex scalp	70.0	6.8	2	
	Mid-scalp	123.3	6.7	6	
	Parietal scalp	210.0	4.3	2	
	Upper forehead	170.2	6.8	5	
	Mid-forehead	97.6	3.92	5	
	Lower forehead	251.3	6.9	7	
	Glabella	100.0	3.2	1	
	Lower face	Temple	80.0	8.0	9
Eyebrow		30.0	1.5	1	
Medial canthus		60.0	4.3	2	
Lower eyelid		52.5	2.9	4	
Nasal dorsum		57.7	4.2	3	
Upper nose		42.5	2.5	2	
Nasal tip		80.8	3.3	9	
Nasal ala		62.6	4.5	7	
Cheek		75.9	5.4	15	
Lip		75.0	2.5	1	
Chin		67.3	5.0	3	
Mandible		60.0	4.0	2	
Upper neck		73.8	5.8	4	
Ear		Preauricular	71.0	5.2	5
		Postauricular	62.0	4.2	1
	Helix	47.5	1.3	2	
	Ear lobule	45.0	2.4	2	

seconds) and ear (60.2 seconds), although showing no differences in amount injected nor type and size of lesions. In addition, the 12 patients who were excluded for having required additional anesthesia were all located in the upper face group. This would have further emphasized the longer time to full anesthetic effect. In demonstrating that more time is needed for adequate anesthesia in certain areas of the face and scalp, surgeons can better plan any local procedure for patients. This is the first study of its kind, comparing the speed of onset of local anesthesia in this anatomical region. Currently, surgeons will resort to overinjecting areas that are consistently difficult at becoming anesthetized. This has been hypothesized to possibly distort the anatomical plane and risk the surgeon losing their planned margins.^{7,8}

Using the time to full anesthesia effect for each injection for all 102 patients, the authors were able to generate a heat map showing the distribution of timing for local anesthesia (Fig. 1). As mentioned previously, the forehead and upper scalp areas took significantly longer for full anesthesia effect, whereas regions adjacent to these areas took a moderate amount of time for full anesthesia effect relative to the rest of the face. The rest of the face took significantly shorter to full anesthesia effect compared with the longer times of the forehead and upper scalp.

Local anesthesia is the mainstay of minor procedures and is consistently used as an adjunct in multimodal analgesia.¹ Understanding the pharmacology and mechanism of action of these medications can significantly help the surgeon to tailor their administration, understand how to improve the medication response, and help improve the patient's experience.

As an overview, local anesthetic agents reversibly disrupt the sodium ion channels in the neuron cell membranes, which inhibit the function of sodium channels.⁶ This inhibition decreases both the rate of repolarization and depolarization of the nociceptive (pain) receptors.⁶ The local anesthetic diffuses into cells via a gradient explained by the difference in pH. To diffuse into the neuronal cells, the chemical anesthetic needs to be in the proximity.⁶ In the present study, the only factor that differed between the patients was anatomical location. With the advent of new imaging technology and increased access to cadavers, our ability to accurately map out and understand facial anatomy has increased dramatically.⁵ Based on facial anatomy, the authors of the present study postulate 3 anatomical differences between the facial regions that can help explain the difference in time to adequate anesthesia.

First, the anesthetic agent works by diffusion into the receptors in an inverted relationship with the radius of the cross-section of the nerve. The smallest and fastest receptor to be anesthetized is the C fibers, which transmit pain.⁶ The goal of local anesthesia administration is to inhibit these fibers; however, it must be explained to the patient that pressure sensation is not always affected. In vivo, different tissue layers diffuse the agent longer than others. If a major nerve crosses deep to the injection, it may take a longer amount of time to diffuse in

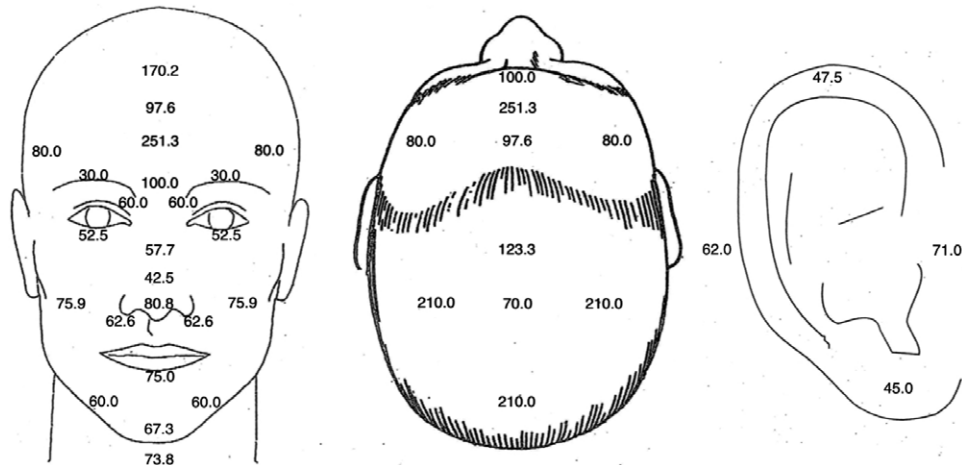


Fig. 1. Heat map of anesthetic timing (average seconds required for adequate anesthesia).

proximity to the nerve for depolarization. This is one of the major factors that the authors have postulated in explaining the findings of this prospective study. The more layers impeding its diffusion the longer its onset of action. What differs in the upper region of the face is the trajectory the nerves travel. The forehead and scalp are innervated by V1 (supratrochlear and supraorbital), V2 (auriculotemporal), and the greater occipital nerve (C1 and C2).^{4,9-15} As an example, the supratrochlear nerve emerges at the frontal notch, approximately 1 cm from midline, and supplies the conjunctiva and the skin of the upper eyelid, then curves up on the forehead, beneath the corrugator supercilii and frontalis muscles.¹¹ At this point, the supratrochlear nerve then ascends beneath the corrugator and the frontal belly of occipitofrontalis before dividing into branches that pierce these muscles to supply the skin of the lower forehead near the midline.^{4,5} The supraorbital nerve pierces through mainly the supraorbital notch, in 90% of cases, and supplies palpebral filaments to the upper eyelid and conjunctiva.^{4,12,16} It ascends on the forehead with the supraorbital artery and divides into medial (superficial) and lateral (deep) branches that supply the skin of the scalp as far back as the lambdoid suture.⁴ These branches are at first deep to the frontal belly of occipitofrontalis. The medial branch perforates the muscle to reach the skin, whereas the lateral branch travels deep to the frontalis, without reliable branching patterns.⁸ Both these major branches to the skin in the upper forehead run deep to muscle, and in some cases just along the border of the periosteum. The local anesthetic, injected into the dermal/subcutaneous plane, needs to diffuse downwards through fascia and muscle to arrive at the main cutaneous nerve. In addition, if injected in the sub/supraperiosteal plane, the local anesthesia can be dispersed and lost through plane hydrodissection, missing the nerves completely, given that they are all found above the galea plane. In contrast, the infraorbital nerve, for midface sensation, exists from the infraorbital foramen, which lies between levator labii superioris and levator anguli

oris.⁴ Here, it becomes very superficial and branches into palpebral branches, nasal branches, and superior labial branches.⁴ These branches are both superficial and very small in caliber compared with their counterparts from the forehead. Both these factors can lead to differences in time to anesthesia, given the superficial nature of the main branches and small caliber of sensory nerves, which helps improve diffusion.

Second, vascularity is a major factor in determining the effectiveness and longevity of local anesthesia. When local anesthesia is absorbed into the blood stream, it is ushered away from its primary site of action and unable to exert its effect on the target nerves. To counteract this effect, many have used epinephrine in their solution to cause vasoconstriction and thus an increase in the duration of onset. As Taylor et al. have demonstrated in their study of angiosomes, there is an abundance of vascular channels and vasculature in the scalp compared with other area of the head and neck.¹⁷ The authors of the present study have hypothesized that the high density of vessels can actually lead to the increase in absorption and thus lower the effective concentration of anesthetic that can be left to diffuse into the nerves. The authors of this study used epinephrine in entire local anesthesia, instead of plain lidocaine, to better control for this increased vascularity and achieve hemostasis during the procedure.

Finally, pain receptors (C fibers) are joined by a multitude of other receptors that transmit information, such as vibration, pressure, and temperature. These receptors are arranged within the dermis of the skin and transmit their respective information to the main nerve in their proximity. These mechanoreceptors, however, have been showed to have different dispersion across the body. Although pain receptor distribution itself has not been studied, there have been many articles examining 2-point discrimination differences and other sensation differences in the body and face. The forehead, when compared against the facial locations, has been shown to be the least sensitive while using a pressure-specified sensory device.¹⁸In addi-

tion, when testing 2-point discrimination, the forehead compared with the rest of the face had the highest static, moving, and vibratory 2-point discrimination. This difference has been explained by relative differences in mechanoreceptor distribution. Many studies have compared the lips and nose to be the most sensitive areas of the body, comparable to the tips of the fingers.¹⁹ The authors hypothesize that this difference in the concentration of mechanoreceptors correlates with a decrease in pain receptor endings, and thus less receptors to be acted on by the local anesthetic.

In all, these factors play important roles for any surgeon. Operative flow and patient preparation can be significantly impacted by organizing patients based on their anesthetic needs and potential for further interventions to ensure adequate anesthesia. By simply being conscious of certain anatomical variations as seen in this article, the surgeon can be more aware of which patients may require additional time before surgery. In addition, looking at these results, patients with lesions in the upper face, mainly the scalp and upper forehead, may simply benefit from a regional block in addition to the regular infiltrative anesthesia.

LIMITATIONS

This study is not without its limitations: first, the small sample size was unable to elicit a more precise and significant topographic map of particular areas of anesthetic difficulty. Instead, the study simply categorized the patients into upper face, lower face, and ear. This specification could allow the surgeon to better understand specific nerve distributions that may be less susceptible to infiltrative anesthesia and would rather opt for a regional block. Second, each patient has different patient-specific factors that could have impeded the result. For example, some patients when feeling pressurized, may have opted for more anesthesia saying that it was in fact painful. Lastly, certain patient comorbidities, such as poorly controlled diabetes mellitus and smoking status, could have had an influence on the result.²⁰ The mean age of the patients was 50 years or older, which has been shown in prior literature to have a negative effect on sensation and nervous distribution.²⁰ These patients and factors could have conflicted some of the stats; however, the sheer statistical significance of the results is quite favorable for the result obtained nonetheless. Finally, another nondocumented factor was patients having red hair. This phenomenon has been shown in trials compared with non-redheads, where they required significantly more anesthesia (both inhalational and local) for the same clinical effect.^{21,22}

CONCLUSIONS

In conclusion, the effectiveness of local anesthesia is determined by a wide array of specific anatomical considerations. This article was successful in showing, through a prospective trial, that for the same local anesthetic and concentration, upper forehead and scalp lesions take significantly longer to anesthetize than other lesions in the

lower face and ear. This phenomenon is hypothesized to be due to the deeper nerve route in the upper face and scalp, increased vascularity for absorption of the anesthesia, and decreased concentration of mechanoreceptors moving cranially in the head and neck regions. This study will prove useful for surgeons who have office-based surgical procedures to help improve flow and patient outcomes.

Tyler Safran, MD

McGill University Health Center
Division of Plastic & Reconstructive Surgery
1001 Decarie Blvd., Montreal, QC H4A 3J1
Email: tyler.safran@mail.mcgill.ca

REFERENCES

1. Alam M, Schaeffer MR, Geisler A, et al. Safety of local intracutaneous lidocaine anesthesia used by dermatologic surgeons for skin cancer excision and postcancer reconstruction: quantification of standard injection volumes and adverse event rates. *Dermatol Surg*. 2016;42:1320–1324.
2. Burns CA, Ferris G, Feng C, et al. Decreasing the pain of local anesthesia: a prospective, double-blind comparison of buffered, premixed 1% lidocaine with epinephrine versus 1% lidocaine freshly mixed with epinephrine. *J Am Acad Dermatol*. 2006;54:128–131.
3. Patel BK, Wendlandt BN, Wolfe KS, et al. Comparison of two lidocaine administration techniques on perceived pain from bedside procedures: a randomized clinical trial. *Chest*. 2018;154:773–780.
4. Gray H, Standring S. *Gray's Anatomy*. London, England: Arcturus Publishing; 2008.
5. Amirlak B, Chung MH, Pezeshk RA, et al. Accessory nerves of the forehead: a newly discovered frontotemporal neurovascular bundle and its implications in the treatment of frontal headache, migraine surgery, and cosmetic temple filler injection. *Plast Reconstr Surg*. 2018;141:1252–1259.
6. Bianconi ML. Mechanism of action of local anaesthetics: a practical approach to introducing the principles of pKa to medical students. *Biochem Educ*. 1998;26:11–13.
7. Amsterdam JT, Kilgore KP. Regional anesthesia of the head and neck. In: *Roberts and Hedges' Clinical Procedures in Emergency Medicine*. 6th ed. Philadelphia, Pa.: Elsevier; 2014:541.e1–553.e1.
8. Gorgas DL, Greenberger S, McGrath J, et al. Development of a head and neck regional anesthesia task trainer for emergency medicine learners. *JETem*. 2017;2:1–17.
9. Mosser SW, Guyuron B, Janis JE, et al. The anatomy of the greater occipital nerve: implications for the etiology of migraine headaches. *Plast Reconstr Surg*. 2004;113:693–697; discussion 698.
10. Dash KS, Janis JE, Guyuron B. The lesser and third occipital nerves and migraine headaches. *Plast Reconstr Surg*. 2005;115:1752–1758; discussion 1759.
11. Janis JE, Ghavami A, Lemmon JA, et al. The anatomy of the corrugator supercilii muscle: part II. Supraorbital nerve branching patterns. *Plast Reconstr Surg*. 2008;121:233–240.
12. Joo W, Yoshioka F, Funaki T, et al. Microsurgical anatomy of the trigeminal nerve. *Clin Anat*. 2014;27:61–88.
13. Janis JE, Hatef DA, Ducic I, et al. Anatomy of the auriculotemporal nerve: variations in its relationship to the superficial temporal artery and implications for the treatment of migraine headaches. *Plast Reconstr Surg*. 2010;125:1422–1428.
14. Janis JE, Hatef DA, Thakar H, et al. The zygomaticotemporal branch of the trigeminal nerve: part II. Anatomic variations. *Plast Reconstr Surg*. 2010;126:435–442.
15. Janis JE, Hatef DA, Hagan R, et al. Anatomy of the supra-trochlear nerve: implications for the surgical treatment of migraine headaches. *Plast Reconstr Surg*. 2013;131:743–750.

16. Hagan RR, Fallucco MA, Janis JE. Supraorbital rim syndrome: definition, surgical treatment, and outcomes for frontal headache. *Plast Reconstr Surg Glob Open*. 2016;4:e795.
17. Houseman ND, Taylor GI, Pan WR. The angiosomes of the head and neck: anatomic study and clinical applications. *Plast Reconstr Surg*. 2000;105:2287–2313.
18. Siemionow MZ, Gharb BB, Rampazzo A. The face as a sensory organ. In: *The Know-How of Face Transplantation*. London, UK: Springer; 2011:11–23.
19. Dellon AL, Andonian E, DeJesus RA. Measuring sensibility of the trigeminal nerve. *Plast Reconstr Surg*. 2007;120:1546–1550.
20. Kesarwani A, Antonyshyn O, Mackinnon SE, et al. Facial sensibility testing in the normal and posttraumatic population. *Ann Plast Surg*. 1989;22:416–425.
21. Liem EB, Lin CM, Suleman MI, et al. Anesthetic requirement is increased in redheads. *Anesthesiology*. 2004;101:279–283.
22. Liem EB, Joiner TV, Tsueda K, et al. Increased sensitivity to thermal pain and reduced subcutaneous lidocaine efficacy in redheads. *Anesthesiology*. 2005;102:509–514.