

## Intracerebral mucormycosis after COVID-19: illustrative cases

Amin I. Nohman, MD,<sup>1</sup> Meltem Ivren, MD,<sup>1</sup> Sabrina Klein, MD,<sup>2</sup> Elham Khatamzas, MD, PhD,<sup>2</sup> Andreas Unterberg, MD, PhD,<sup>1</sup> and Henrik Giese, MD<sup>1</sup>

<sup>1</sup>Clinic of Neurosurgery, University Hospital Heidelberg, Baden-Württemberg, Germany; and <sup>2</sup>Department of Infectious Diseases, Medical Microbiology and Hygiene, University Hospital Heidelberg, Baden-Württemberg, Germany

**BACKGROUND** In this case report the authors present two female patients with intracranial mucormycosis after coronavirus disease 2019 (COVID-19).

**OBSERVATIONS** The first patient was a 30-year-old woman with no past medical history or allergies who presented with headaches and vomiting. Magnetic resonance imaging (MRI) and computed tomography of the skull showed an endonasal infection, which had already destroyed the frontal skull base and caused a large frontal intracranial abscess. The second patient was a 29-year-old woman with multiple pre-existing conditions, who was initially admitted to the hospital due to a COVID-19 infection and later developed a hemiparesis of the right side. Here, the MRI scan showed an abscess configuration in the left motor cortex. In both cases, rapid therapy was performed by surgical clearance and abscess evacuation followed by antifungal, antidiabetic, and further supportive treatment for several weeks.

**LESSONS** Both cases are indicative of a possible correlation of mucormycosis in the setting of severe immunosuppression involved with COVID-19, both iatrogenic with the use of steroids and previous medical history. Furthermore, young and supposedly healthy patients can also be affected by this rare disease.

<https://thejns.org/doi/abs/10.3171/CASE21567>

**KEYWORDS** mucormycosis; COVID-19; intracranial abscess

More than 1.5 million people worldwide have already died from or with coronavirus disease 2019 (COVID-19).<sup>1</sup> Severe COVID-19 courses are associated with chronic pre-existing conditions, such as arterial hypertension, diabetes mellitus, or pulmonary diseases.<sup>2</sup> Immunocompromised individuals receiving chemotherapy or immunotherapy for malignancies, for example, are equally part of the risk group.<sup>3</sup> In particularly severe courses with need for oxygen or ventilation, steroids such as dexamethasone have been shown to improve the probability of survival.<sup>4</sup>

Recently, an increasing number of mucormycosis cases have been observed in combination with COVID-19 pneumonia.<sup>5</sup> Mucormycosis is an acute and mostly fatal fungal disease, which shows a highly aggressive progression and requires complicated diagnostics and therapy.<sup>6</sup> Mucormycosis of the respiratory tract is typically associated with uncontrolled diabetes, immunodeficiency, or high-dose steroid therapy.<sup>7</sup> The few cases that primarily demonstrate a rhino-cerebral involvement particularly correlate with an uncontrolled diabetic status.<sup>8</sup> Infection

usually occurs through inhalation of infected aerosols.<sup>9</sup> Rhino-cerebral mucormycosis usually starts in the paranasal sinuses. It can destroy bony elements such as the frontal skull base and then spread toward the orbital cavity.<sup>10</sup> Pathophysiologically, the infection reduces perfusion of the tissue via angioinvasion, and eventually leads to formation of typically black, necrotic lesions.<sup>10</sup>

To our knowledge, only two case reports with a total of three patients with rhino-cerebral involvement of mucormycosis after COVID-19 infection have been published. In both publications, the patients had a prior medical history of diabetes mellitus.<sup>11,12</sup> Also, they had all been treated with corticosteroids.

### Illustrative Cases

#### Case 1

Our first patient was a 30-year-old woman with no previously known chronic illnesses or allergies. Initially, she presented to the emergency

**ABBREVIATIONS** BMRC = British Medical Research Council; COVID-19 = coronavirus disease 2019; CSF = cerebrospinal fluid; CT = computed tomography; ENT = ear-nose-throat; MRI = magnetic resonance imaging; PCR = polymerase chain reaction.

**INCLUDE WHEN CITING** Published June 20, 2022; DOI: 10.3171/CASE21567.

**SUBMITTED** October 17, 2021. **ACCEPTED** December 16, 2021.

© 2022 The authors, CC BY-NC-ND 4.0 (<http://creativecommons.org/licenses/by-nc-nd/4.0/>).

outpatient clinic in May 2021. Her husband had found her with a reduced general health status, reduced awareness, and fever. In the clinical examination, the patient was noticeably sleepy and partially oriented (Glasgow Coma Scale score, 13). Meningism signs were absent on physical examination. Her husband stressed that she had complained of severe headaches and an episode of vomiting. Headaches had been present for 5 to 6 weeks but reached a peak around the time of presentation. The patient did not show any chest pain, stomach-aches, dyspnea, or cough. Except for fever (38.6°C), the patient's vital signs were unremarkable.

Her husband explained that they had just returned from a family trip to India a few days before presentation and that his wife had been infected with COVID-19 there. Due to respiratory distress and high fever, she was hospitalized for approximately a week in April and had received anti-infective therapy in India. The therapy regimen contained antibacterial and antiviral medication, such as ivermectin, doxycycline, and remdesivir, as well as a high dosage of steroids. As a result of the high steroid intake, elevated blood glucose levels were noted but not treated. Only a follow-up was recommended. The respiratory situation improved constantly throughout her hospitalization, so that she was discharged with an improved general condition and a negative COVID-19 polymerase chain reaction (PCR) result after 8 days. In the course of her travel from India, the patient received further multiple COVID-19 PCR tests, all of which were negative.

On presentation to our clinic, initially performed diagnostics with electroencephalogram, chest X-ray, urinalysis, and abdominal ultrasonography did not reveal any conclusive findings. Blood analysis revealed elevated C-reactive protein and white blood cell counts. Subsequently, due to the somnolent state of the patient, the severe headaches, and increased infectious parameters, a lumbar puncture was performed prior to imaging to rule out any neurological involvement. Cerebrospinal fluid (CSF) diagnostics revealed over 550 cells/ $\mu$ g and elevated sugar and

lactate levels, indicating lymphocytic transformation (Table 1). With the suspicion of an inflammatory meningoencephalitis, we started an antibiotic and antiviral therapy with intravenous ceftriaxone and acyclovir.

Complementarily, computed tomography (CT) of the skull was performed, which showed an extensive hypodensity on the right frontal lobe. Additional images of the paranasal sinuses showed a subtotal obstruction of the sphenoid, ethmoid, and maxillary sinuses bilaterally. A confirmatory MRI scan (Fig. 1) revealed a large intracranial, right frontal mass with a ring-enhancing lesion (T1 contrast sequence), surrounding edema (T2 sequence), and diffusion restriction (diffusion-weighted imaging sequence) consistent with an intracranial abscess.

We saw a clear indication for surgical abscess removal and performed a combined transnasal and transcranial abscess evacuation together with our colleagues from the ear-nose-throat (ENT) department. First, the paranasal sinuses were cleared endoscopically. The maxillary sinus, sphenoid sinus, and ethmoid bone were opened, and purulent and necrotic abscess material was removed. Furthermore, the frontal skull base was inspected from below and a bony defect was identified. After transnasal coverage with a septomucosal flap, we continued with abscess evacuation transcranially. Using a pterional approach, we carefully cleared out the intracranial portion of the abscess. Here too, the inflammatory tissue was purulent and necrotic. The classic black, necrotic pattern of extracranial mucormycotic abscess was not seen. An abscess-typical pus configuration was found. After a complete abscess evacuation, the anterior skull base was inspected, and the bony defect was identified. Then, the defect was covered with a Galea periost flap and fibrin glue. Intraoperatively collected samples were sent to our microbiology and pathology departments.

Postoperatively, the patient presented no neurological deficits, reduced headaches, and improved awareness. After 2 days of observation on our neurosurgical intensive care unit and steady improvement of the general condition, the patient was transferred to the general ward.

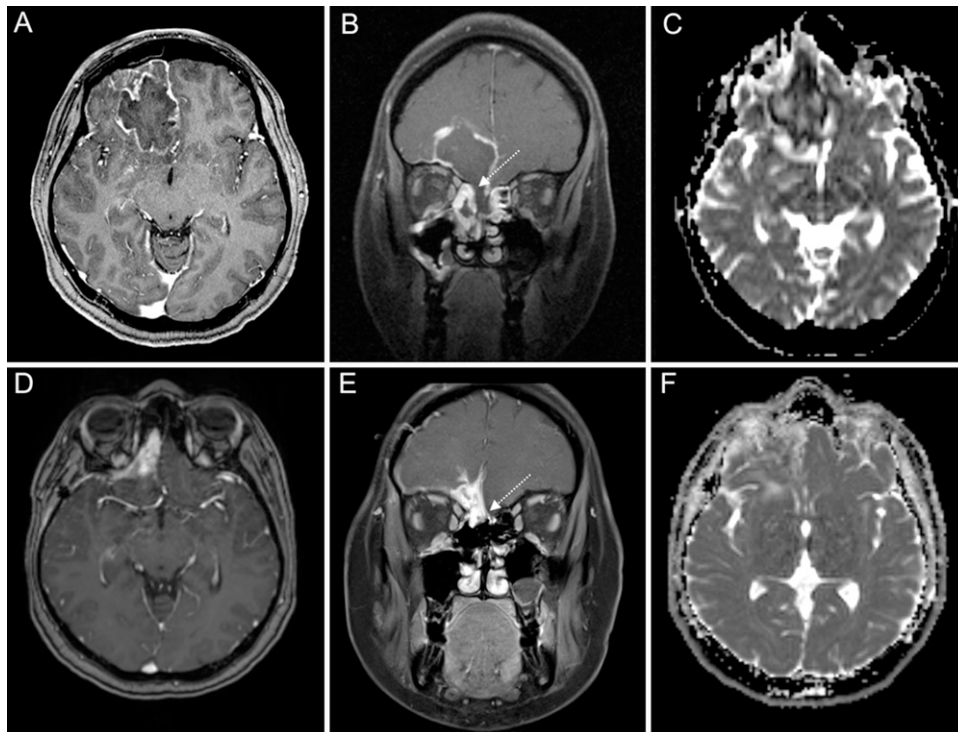
As the first results of the microbiological analysis (PCR) indicated a fungal infection, we changed the therapy regimen to liposomal amphotericin B (1 mg/kg every 24 hours) and added vancomycin intravenous (15 mg/kg) due to expression of gram-positive cocci. Thereafter, the patient's laboratory findings and clinical state improved further. *Rhizopus microsporus* as well as *Staphylococcus epidermidis* were grown from the abscess. According to the current guidelines, we subsequently increased the dosage of liposomal amphotericin B to 5 mg/kg and then 10 mg/kg body weight.<sup>6</sup> Vancomycin was continued to cover the treatment of *Staphylococcus epidermidis*. In the further course, we replaced vancomycin by linezolid (oral intake of 600 mg every 12 hours) due to deteriorating liver and kidney functions. Because diabetes is a major prognostic risk factor within mucormycosis therapy,<sup>13</sup> we tested hemoglobin A1c and the results showed a value of 10.4%. We treated the elevated blood glucose levels with an insulin injection regimen. We started to take blood counts on a daily basis, paying special attention to electrolytes, blood sugar levels, liver, and kidney parameters. Within the course of treatment, the patient started to complain about headaches and vomited once. An MRI scan of the skull showed an unremarkable resection cavity without signs of diffusion restriction or signs of a recurrent abscess. A chest CT scan showed parenchymal changes compatible with the post-COVID-19 history. However, the patient continued to have more frequent episodes of vomiting leading to electrolyte derailment and difficulties in proper food intake. Taking

**TABLE 1. Case 1: CSF diagnostics by lumbar puncture**

Parameter	Value	Reference Value
Appearance/CSF	Clear	
Glucose/CSF, mg/dL	81.0	49–75
Lactate/CSF, mmol/L	2.84	1.5–2.1
Protein/CSF, mg/dL	60.8	15–46
CSF cells/ $\mu$ L	608	<5
Neutrophil granulocytes	About 30%	
Lymphocytes	About 60%	
RBCs, cells/ $\mu$ L	90.0	
Phagocytes	0	
Blasts	0	
Other cells	4 Basophile Cells	
Tumor cells	0	
Barrier dysfunction	Yes	
Alb.L/S-Quo.	12.1	<6
Intrathecal IgM synthesis, %	45.14	

Alb.L/S-Quo. = albumin CSF/serum quotient; IgM = immunoglobulin M; RBCs = red blood cells.

The results show an increased cell and total protein count. In addition, a moderate blood CSF barrier disorder is seen. Intrathecal IgM synthesis reflects mixed pleocytosis with clear signs of inflammatory transformation.



**FIG. 1.** Preoperative (**A–C**) and postoperative (**D–E**) MRI scans of the first patient. Panels A and B show a preoperative T1 sequence with contrast agent in axial and coronal view with a large right frontal mass with contrast-enhancement and a defect of the anterior skull base (*white arrow*). Apparent diffusion coefficient (ADC) sequences are shown in panel C with a large restriction area inside the lesion. Postoperative images (D and E, T1 with contrast; F, ADC sequence) 14 weeks after surgical and medical treatment show a regular postoperative contrast enhancement without restriction in ADC sequences. The *white arrow* in panel E shows the covering of the anterior skull base.

deteriorating liver and kidney parameters into consideration as well, the patient was transferred to the department of internal medicine.

## Case 2

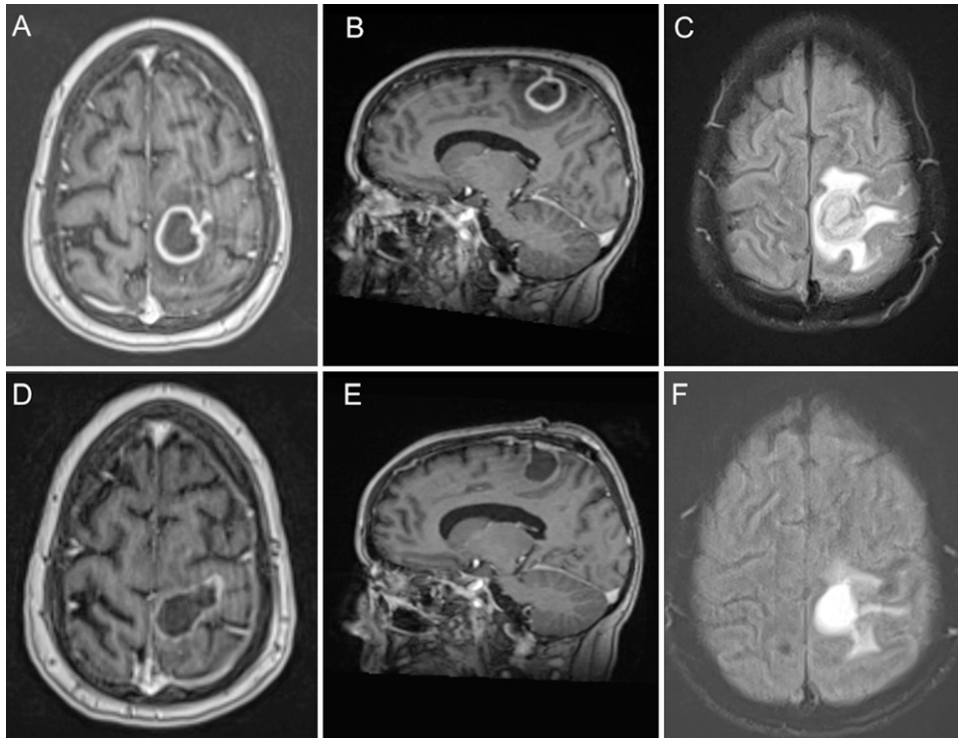
Our second patient was a 29-year-old woman who was referred to us in mid-June by the pneumology department. The patient had been receiving treatment there for COVID-19 pneumonia since early April. The course of this patient's COVID-19 infection was complicated by her medical history as she had received a heart-lung transplant 9 years earlier due to pulmonary hypertension that developed into an Eisenmenger reaction. After initial transplantation, transplant rejection occurred in 2013, so that the patient had to be treated with intensified immunosuppressants.

While being treated for COVID-19, the patient developed septic shock and received an exploratory laparotomy and duodenojejunostomy 6 days before her presentation to us. In addition, the patient underwent CT-guided puncture and drainage of an abscess in the right lower lobe of the lung. The microbiological examination of the abscess material revealed *Rhizopus microsporus*. Therapy with amphotericin B (10 mg/kg body weight) and isavuconazole intravenous (200 mg/day) was initiated.

After gradual improvement of the patient's general condition and approximately 6 weeks after her admission to the hospital, a new leg-accentuated hemiparesis on the right side was noted (right arm,

4/5; right leg, 2/5 based on the British Medical Research Council [BMRC] scale).<sup>14</sup> Subsequent MRI (Fig. 2) of the brain demonstrated a left-sided mass in the motor cortex with marginal contrast enhancement and diffusion restriction. Given the history, an intracranial fungal abscess was suspected. Consequently, the patient was transferred to our neurosurgical department for further therapy. We performed a left-sided osteoplastic craniotomy and abscess removal. The abscess was solid in texture and contained a necrotic core. Ventilation of the patient intraoperatively was difficult and sometimes showed elevated carbon dioxide values. The high carbon dioxide levels caused severe swelling of the cortex, so that rapid removal of the abscess was necessary.

Postoperatively, the patient showed a mild worsening of her hemiparesis (right arm, 3/5; right leg, 2/5 BMRC scale) that recovered later in the course. Other new neurological deficits did not occur. Grocott staining confirmed an intracerebral fungal infection, although cultures were negative. A combined antifungal therapy (amphotericin B and isavuconazole) was continued according to the guidelines<sup>6</sup> and was complemented with an empirical antibiotic therapy with vancomycin and meropenem. In addition, immunosuppressive therapy was reduced. After initial improvement and transfer to the normal ward, the patient required another CT-guided puncture of her pulmonary mucormycotic lesion. During her hospitalization, she experienced severe fluctuations in blood



**FIG. 2.** Preoperative (A–C) and postoperative (D–E) MRI scans of the second patient: Preoperative T1 sequence with contrast agent in axial and sagittal view (A and B) and fluid-attenuated inversion recovery (FLAIR) sequence (C) showed a contrast enhancing mass with surrounding edema localized in the motor cortex. Postoperative result one month after surgery and medical treatment (D and E, T1 with contrast; F, FLAIR sequence).

glucose levels, presenting with hyperglycemia initially and hypoglycemia later in the course.

We transferred both patients so that they could receive further internal medicine care. Following the necessary anti-infective therapy of several weeks, some drug-associated complications, such as nausea, electrolyte shifts, or possible arrhythmias, such as QT prolongation, have been monitored and treated. In both cases, no new neurological deteriorations were documented or observed. To date, both patients are in stable condition and continue to receive antifungal and anti-infective therapy.

## Discussion

In this case report we present two young women with intracranial mucormycosis after a COVID-19 infection. The aim of this report is to shed light on key aspects and difficulties in the treatment of this rare condition in the context of high lethality rates. Current literature, reports, and guidelines for treatment of COVID-19–associated intracranial mucormycosis are scarce. Considering that more and more COVID-19–associated mucormycosis cases are described, it is important to collect the existing experience to provide better recommendations in the future.<sup>15</sup>

Mucormycosis infections usually occur in immunocompromised or chronically predisposed patients and are characterized by a high mortality.<sup>16</sup> Intensive steroid therapy and diabetes mellitus have been identified as risk factors for mucormycosis.<sup>17</sup> The observations that patients develop an increased incidence of mucormycosis after

or during a COVID-19 infection should be critically evaluated and investigated. Previous studies suggest that COVID-19 itself leads to a certain disposition for bacterial or fungal superinfections and that the therapeutic procedures, such as high-dose steroid therapy regimens or other anti-infective therapies, promote superinfections.<sup>18</sup> Consequently, aggressive therapy of COVID-19 pneumonia with corticosteroids must be considered.<sup>4</sup> Patients with risk factors such as diabetes mellitus or immunodeficiency should be monitored carefully and attention should be given to early signs of a superinfection or neurological deterioration. In particular, derailed diabetes is associated with poorer outcomes and thus high blood glucose levels and complications such as ketoacidosis should be avoided or treated rapidly.<sup>19</sup> Surprisingly, both of our patients were relatively young. The first patient did not have a history of chronic disease. This illustrates that even young people can develop mycotic superinfections after COVID-19 and highly immunosuppressive therapies with corticosteroids leading to potentially fatal outcomes. The second patient was noted to have a leg paresis caused by a centrally located abscess. Mucormycosis represents an infection of the respiratory tract and usually spreads to the intracranial cavity through the transnasal passage or via the nasal sinuses. Centrally located mucormycosis abscesses are a rarity among the already rare intracranial mucormycosis abscesses.

The diagnostics of mucormycosis can be difficult and delayed. The clinical symptoms of a rhino-cerebral mucormycosis are diverse. After a COVID-19 infection, a variety of unspecific symptoms has

been reported, also known as long-COVID-19 syndrome. These unspecific symptoms may result in misinterpretation, especially in the early phase of mucormycosis.<sup>19</sup> Thus, critical evaluation is necessary and further diagnostics should not be delayed. In this context, when imaging reveals suspicious lesions, tissue samples for histopathology and microbiological examination are of major importance. As direct detection of fungi by microscopy may not be successful in every case, molecular methods to detect fungal DNA directly from the sample can be useful for early diagnosis. Nevertheless, culture of specimen is crucial to allow not only species identification, but also antifungal susceptibility testing. Cases with suspected mucormycosis should therefore be managed by a multidisciplinary team to allow optimal diagnostics and treatment.<sup>5</sup>

Surgical management with extensive debridement is necessary to stop further angioinvasive expansion.<sup>20</sup> Cerebral involvement makes surgical excision with sufficient safety margins difficult, since there are functionally important structures that should be preserved. In particular, within the rhino-orbital region where mucormycosis is most commonly located intracranially, aggressive surgery is limited. Optimal preoperative preparation by using neuroimaging and navigational systems is one way to maximize the extent of resection. In case of rhino-cerebral or rhino-orbito-cerebral extension, interdisciplinary cooperation of neurosurgery, ENT, and ophthalmic surgery is helpful. In both cases, intraoperative abscess presentation was not typical for mucormycosis, lacking the typical black, necrotic component. Nevertheless, despite the lack of a typical morphology, an aggressive surgical approach should be considered, given the high risk of further spread.<sup>21</sup>

Finally, surgical clearance should be followed by prolonged drug therapy with antifungal medications. Liposomal amphotericin B usually represents the standard therapy.<sup>6</sup> A high dosage is necessary (up to 10 mg/kg). In some cases, monotherapy is not sufficient, although experience and available data have not shown any clear superiority of a combination of antimycotic medications.<sup>22</sup> In case of severe side effects or a lack of response to amphotericin B, isavuconazole is an alternative that can also be administered orally.<sup>6</sup> A susceptibility testing and adjustment of the dosage and therapy is required, especially considering that amphotericin B has a high nephrotoxicity.<sup>23</sup> Lack of response, long hospitalization periods, and complications, such as side effects of prolonged and intensive drug therapy, may affect the overall outcome and make therapy more difficult.

## Observations

These two cases show that serious and significant fungal superinfection might be correlated with COVID-19. New neurological deterioration after COVID-19 could indicate intracranial involvement. Thus, if there is any doubt, further neurological diagnostic measures should follow. Recently, more and more such cases have been published, but usually with primary rhino-orbital involvement.<sup>10,11</sup>

## Lessons

In summary, a moderate to severe COVID-19 infection with associated therapies can be associated with mucormycosis. The first case demonstrates that even a presumed young and healthy patient can suffer such a fungal infection. An intensive steroid therapy should be well considered. Comorbidities, such as diabetes mellitus should be controlled and treated. The second case demonstrates that mucormycosis infections can also be located in different brain areas, such as the central region. Suspicious symptoms, neurological deterioration, and complaints after a COVID-19 pneumonia should not be simply

interpreted as long-term COVID-19 syndrome but should be followed up in case of doubt. Finally, intracerebral mucormycosis should be treated quickly and carefully in an interdisciplinary manner.

## References

1. World Health Organization. Coronavirus (COVID-19) Dashboard. Accessed August 28, 2021. <https://covid19.who.int/>.
2. Rod JE, Oviedo-Trespalacios O, Cortes-Ramirez J. A brief-review of the risk factors for covid-19 severity. *Rev Saude Publica*. 2020;54:60.
3. Wang H, Zhang L. Risk of COVID-19 for patients with cancer. *Lancet Oncol*. 2020;21(4):e181.
4. COVID-19 Treatment Guidelines Panel. Coronavirus Disease 2019 (COVID-19) Treatment Guidelines. Bethesda, MD: National Institutes of Health.
5. Al-Tawfiq JA, Alhumaid S, Alshukairi AN, et al. COVID-19 and mucormycosis superinfection: the perfect storm. *Infection*. 2021;49(5):833–853.
6. Cornely OA, Alastruey-Izquierdo A, Arenz D, et al. Global guideline for the diagnosis and management of mucormycosis: an initiative of the European Confederation of Medical Mycology in cooperation with the Mycoses Study Group Education and Research Consortium. *Lancet Infect Dis*. 2019;19(12):e405–e421.
7. Hamilos DL. Chronic rhinosinusitis: epidemiology and medical management. *J Allergy Clin Immunol*. 2011;128(4):693–709.
8. Roden MM, Zaoutis TE, Buchanan WL, et al. Epidemiology and outcome of zygomycosis: a review of 929 reported cases. *Clin Infect Dis*. 2005;41(5):634–653.
9. Bae MS, Kim EJ, Lee KM, Choi WS. Rapidly progressive rhino-orbito-cerebral mucormycosis complicated with unilateral internal carotid artery occlusion: a case report. *Neurointervention*. 2012;7(1):45–49.
10. Petrikos G, Tsioutis C. Recent advances in the pathogenesis of Mucormycoses. *Clin Ther*. 2018;40(6):894–902.
11. Dallalzadeh LO, Ozzello DJ, Liu CY, Kikkawa DO, Kom BS. Secondary infection with rhino-orbital cerebral mucormycosis associated with COVID-19. *Orbit*. Published online March 23, 2021. doi: <https://doi.org/10.1080/01676830.2021.1903044>.
12. Alekseyev K, Didenko L, Chaudhry B. Rhinocerebral mucormycosis and COVID-19 pneumonia. *J Med Cases*. 2021;12(3):85–89.
13. Corzo-León DE, Chora-Hernández LD, Rodríguez-Zulueta AP, Walsh TJ. Diabetes mellitus as the major risk factor for mucormycosis in Mexico: epidemiology, diagnosis, and outcomes of reported cases. *Med Mycol*. 2018;56(1):29–43.
14. Compston A. Aids to the investigation of peripheral nerve injuries. Medical Research Council: Nerve Injuries Research Committee. His Majesty's Stationery Office: 1942; pp. 48 (iii) and 74 figures and 7 diagrams; with aids to the examination of the peripheral nervous system. By Michael O'Brien for the Guarantors of Brain. Saunders Elsevier: 2010; pp. [8] 64 and 94 Figures. *Brain*. 2010;133(10):2838–2844.
15. Fouad YA, Abdelaziz TT, Askoura A, et al. Spike in rhino-orbito-cerebral mucormycosis cases presenting to a tertiary care center during the COVID-19 pandemic. *Front Med (Lausanne)*. 2021;8:645270.
16. Riley TT, Muzny CA, Swiatlo E, Legendre DP. Breaking the mold: a review of mucormycosis and current pharmacological treatment options. *Ann Pharmacother*. 2016;50(9):747–757.
17. Ardi P, Daie-Ghazvini R, Hashemi SJ, et al. Study on invasive aspergillosis using galactomannan enzyme immunoassay and determining antifungal drug susceptibility among hospitalized patients with hematologic malignancies or candidates for organ transplantation. *Microb Pathog*. 2020;147:104382.
18. Chen N, Zhou M, Dong X, et al. Epidemiological and clinical characteristics of 99 cases of 2019 novel coronavirus pneumonia in

- Wuhan, China: A descriptive study. *Lancet*. 2020;395(10223): 507–513.
19. Brunet K, Rammaert B. Mucormycosis treatment: recommendations, latest advances, and perspectives. *J Mycol Med*. 2020;30(3):101007.
  20. Vironneau P, Kania R, Morizot G, et al. Local control of rhino-orbito-cerebral mucormycosis dramatically impacts survival. *Clin Microbiol Infect*. 2014;20(5):O336–O339.
  21. Skiada A, Pavleas I, Drogari-Apiranthiou M. Rare fungal infectious agents: a lurking enemy. *F1000Res*. 2017;6:1917.
  22. Kyveritakis A, Torres HA, Jiang Y, Chamilos G, Lewis RE, Kontoyiannis DP. Initial use of combination treatment does not impact survival of 106 patients with haematologic malignancies and mucormycosis: a propensity score analysis. *Clin Microbiol Infect*. 2016;22(9): 811.e1–811.e8.
  23. Lamoth F, Lewis RE, Kontoyiannis DP. Role and interpretation of antifungal susceptibility testing for the management of invasive fungal infections. *J Fungi (Basel)*. 2020;7(1):17.

## Disclosures

The authors report no conflict of interest concerning the materials or methods used in this study or the findings specified in this paper.

## Author Contributions

Conception and design: Nohman, Ivren, Giese. Acquisition of data: Nohman, Ivren, Klein, Giese. Analysis and interpretation of data: Nohman, Ivren, Unterberg, Giese. Drafting the article: Nohman, Ivren, Klein, Giese. Critically revising the article: Ivren, Klein, Katamzas, Unterberg, Giese. Reviewed submitted version of manuscript: Ivren, Unterberg, Giese. Approved the final version of the manuscript on behalf of all authors: Nohman. Administrative/technical/material support: Ivren. Study supervision: Unterberg, Giese.

## Correspondence

Amin I. Nohman: University Hospital, Heidelberg, Baden-Württemberg, Germany. amin.nohman@med.uni-heidelberg.de.