

# Does Diffusion Tensor Tractography of the Corticospinal Tract Correctly Reflect Motor Function?

Zhi-gang Min<sup>a</sup> Netra Rana<sup>a</sup> Chen Niu<sup>a</sup> Huan-mei Ji<sup>b</sup> Ming Zhang<sup>a</sup>

<sup>a</sup>Department of Radiology, First Affiliated Hospital of Xi'an Jiaotong University, and <sup>b</sup>Department of Radiology, Shaanxi Provincial Cancer Hospital, Xi'an, PR China

## Key Words

Diffusion tensor imaging · Tractography · Corticospinal tract · Motor function · Muscle strength

## Abstract

**Objective:** To investigate the consistency of diffusion tensor tractography of the corticospinal tract on motor function.

**Clinical Presentations and Intervention:** Three patients with brain tumor were admitted to our hospital with impaired motor function. Diffusion tensor imaging (DTI) and tractography were performed in these patients to assess their affected corticospinal tract. The corticospinal tract showed interruption with moderately impaired motor function in 2 patients. The third case had significantly weakened muscle strength on the left upper limb but an intact right corticospinal tract.

**Conclusion:** These cases showed that the corticospinal tracts obtained by DTI with tractography were inconsistent with motor function. Hence, DTI should be interpreted with caution.

© 2013 S. Karger AG, Basel

## Introduction

Diffusion tensor imaging (DTI) has become a routine preoperative diagnostic tool in neurosurgery departments of various institutions. Corticospinal tracts (CSTs)

are eloquent pathways responsible for motor function and should be protected during operation. Tract displacement, deformation, infiltration, disruption, and disorganization of fibers due to tumors may alter the brain function and are well recognized by reduction in fiber bundles or decreased fractional anisotropy (FA) values on DTI tractography. DTI-based fiber-tracking has been shown to be reliable in manifesting pyramidal tracts compared with motor-evoked potentials in patients with glioma [1], but there is also a conflicting result reported by Kinoshita et al. [2] who emphasized that fiber-tracking cannot depict the entire motor tract. In our clinical practice, we found that the motor functional defect of most patients with a brain lesion could be elucidated with DTI results. However, we also noticed that the DTI results did not entirely explain the functional defect in a small number of cases. We hereby present 3 cases with brain tumor.

## Case Reports

For the 3 cases, DTI datasets were processed using DtiStudio software (Johns Hopkins University, Baltimore, Md., USA). The CST was tracked through three regions of interest, separately placed on the anterior part of the lower pons level, the posterior limb of the internal capsule and precentral gyrus. Regions of interest were defined by an author (M.Z.) with 20 years of experience for diagnostic neuroimaging and 3 years in DTI processing. The cut-off value for stop-tracking was FA <0.15 and turning angle >60°.

## KARGER

E-Mail [karger@karger.com](mailto:karger@karger.com)  
[www.karger.com/mpp](http://www.karger.com/mpp)

© 2013 S. Karger AG, Basel  
1011-7571/13/0232-0174\$38.00/0

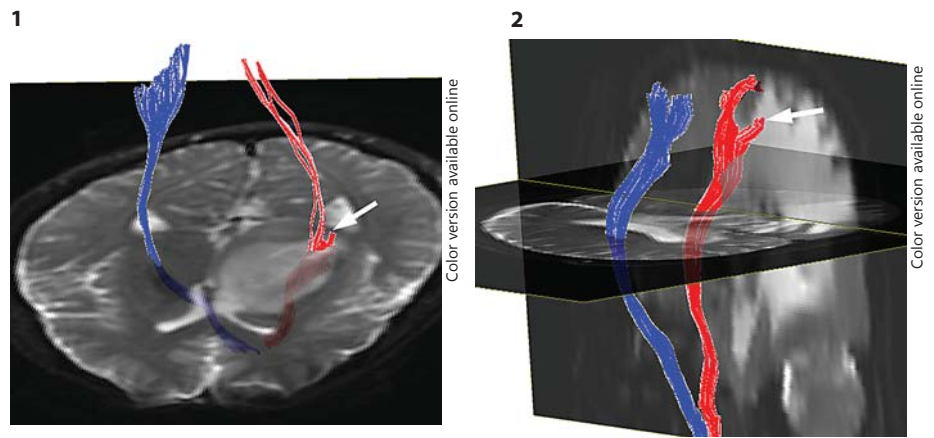


This is an Open Access article licensed under the terms of the Creative Commons Attribution-NonCommercial 3.0 Unported license (CC BY-NC) ([www.karger.com/OA-license](http://www.karger.com/OA-license)), applicable to the online version of the article only. Distribution permitted for non-commercial purposes only.

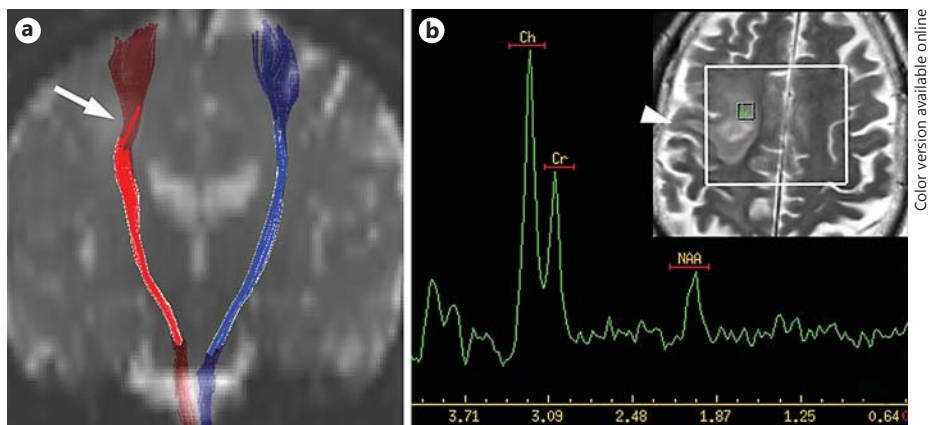
Prof. Ming Zhang  
Department of Radiology  
First Affiliated Hospital of Xi'an Jiaotong University  
277 West Yanta Road, Xi'an 710061 (PR China)  
E-Mail [profzmmri@gmail.com](mailto:profzmmri@gmail.com)

**Fig. 1.** Case 1: DTI-based fiber-tracking displays a reduced and partially interrupted fiber tract (arrow) on the left CST.

**Fig. 2.** Case 2: fiber-tracking displays interrupted fibers (arrow) distal to the right CST.



**Fig. 3.** Case 3. **a** DTI-based fiber-tracking displays a CST passing through the lesion (arrow) without interruption. **b** T2-weighted imaging shows lesions involving part of the precentral gyrus (arrowhead). MRS reveals a high choline concentration within the lesion.



#### Case 1

A 37-year-old man was admitted to our hospital with weakness of the right limbs and speech and memory loss. Muscle strength in the right-side extremities was grade 4 according to Lovett's testing. A mass lesion involving the left basal ganglia, thalamus and internal capsule was detected on routine magnetic resonance imaging (MRI) with low T1-signal intensity and high T2-signal intensity. The DTI showed a lower value of FA in the affected white matter (0.08–0.24) compared to the contralateral side. DTI-based fiber-tracking displayed a reduced fiber tract on the left CST, and partially interrupted in the lesion area (fig. 1). Fiber bundles slightly increased but were still interrupted using an FA cut-off value of 0.10 for fiber-tracking. Diagnosis of diffuse astrocytoma was made after biopsy and histopathological results.

#### Case 2

A 67-year-old man was admitted to our hospital with headache and weakened left limbs. Muscle strength on the left side was grade 4. Routine MRI displayed a mass lesion close to the posterior horn of the right lateral ventricle with low T1-signal intensity and high T2-signal intensity. Peritumoral edema was markedly presented and showed lower FA (0.08–0.22) compared to the contralateral white matter (0.40). Fibers displayed interruption distally to the right CST (fig. 2) and did not significantly improve using an FA cut-off value of 0.10 for fiber-tracking. The mass was confirmed to be a metastatic tumor from a renal cell carcinoma of the right kidney after histopathological findings.

#### Case 3

A 67-year-old man was admitted to our hospital with a history of weakened left limbs and muscle twitching. On physical examination the muscle strength of the left upper limb was grade 2 and grade 4 on the lower limb. T2-weighted MRI revealed the lesion involving the right centrum ovale and part of the precentral gyrus. The FA value of the affected white matter was slightly lower (0.28) compared with the contralateral side (0.40). DTI-based fiber-tracking displayed a right CST passing through the lesion without interruption (fig. 3). The patient refused surgery, therefore no histopathological diagnosis was made. However, an increased choline concentration (maximum choline/creatine and choline/N-acetylaspartate ratios of 3.04 and 4.51, respectively) was detected in the lesion with MRS study, which was highly suggestive of tumor.

### Discussion

DTI-based fiber-tracking showed significantly decreased and interrupted fibers of a CST within a tumor or in peritumoral edema in cases 1 and 2. However, ipsilateral muscle strength was only diminished to some extent, which means that a considerable part of the functional axon had not been destroyed although the trajectory de-

picted by DTI was broken. Fiber bundle interruption signs were perhaps due to axonal structural damage or maybe because of local FA values lower than the threshold. FA is a nonspecific parameter and can be affected by a lot of pathological changes, such as demyelination, axon disruption, tumor cell infiltration and vasogenic edema [3]. In case 1, although the left CST was partially disrupted within the tumor tissue, the motor function of left extremities was mostly preserved. We speculate that this phenomenon may be related to the fiber bundles that have not yet been substantially damaged by tumor cells. However, the presence of tumor cells expanded the extracellular space and made the FA value less than normal [4]. In a previous study, intraoperative subcortical mapping also documented the presence of functional fibers inside the tumor mass. This is often seen in patients with low-grade gliomas [5]. In the peritumoral areas of gliomas, vasogenic edema, which can induce a significant reduction of FA, often merges with infiltration of tumor cells around the glioma [6]. Fiber bundles below thresholds could not be displayed. It is therefore not strange to find 'interrupted' fibers in peritumoral edema of meningiomas and metastasis. Increased visualization of fiber bundles is achievable by using a lower FA cut-off value, however a lower cut-off value is easily affected by image noise and increased error fiber connection.

In case 3, the CST was intact but had a significantly impaired motor function in the right upper limb. The motor function damage in this case could not be explained with DTI-derived CST. Akai et al. [7] reported a case with intact fiber tracts through the tumor regions of

gliomatosis cerebri where muscle strength was also significantly weakened. A probable explanation is that hand and foot CSTs have a different origin and should have a fan-shaped configuration passing through the centrum semiovale. However, with the current algorithm, hand fibers or lip fibers connected to the lower part of the motor cortex may not be displayed [8]. With probabilistic tractography or high angular resolution diffusion imaging, these problems should be solved [9]. However, these methods are time-consuming and not currently widely used. Another probable explanation is the lesion disrupts the cortical motor neurons. Patients with functional abnormalities due to cortical involvement could have a normal FA value in the white matter [10]. An important sign that we noticed was the lesion involvement of the motor cortex. The cortical lesion can lead to impaired motor function and does not affect the structure of fibers.

## Conclusion

The significance of this report as seen in these 3 cases was that displaying DTI-derived CST could disrupt with moderately impaired motor function in low-grade glioma and peritumoral edema of a metastatic lesion but intact CST may not represent intact motor function of upper limbs. Hence, CSTs obtained by DTI with tractography may be inconsistent with motor function. In these situations, DTI results should be interpreted with caution.

## References

- Ohue S, Kohno S, Inoue A, et al: Accuracy of diffusion tensor magnetic resonance imaging-based tractography for surgery of gliomas near the pyramidal tract: a significant correlation between subcortical electrical stimulation and postoperative tractography. *Neurosurgery* 2012;70:283–293; discussion 294.
- Kinoshita M, Yamada K, Hashimoto N, et al: Fiber-tracking does not accurately estimate size of fiber bundle in pathological condition: initial neurosurgical experience using neuro-navigation and subcortical white matter stimulation. *Neuroimage* 2005;25:424–429.
- Beaulieu C: The basis of anisotropic water diffusion in the nervous system – a technical review. *NMR Biomed* 2002;15:435–455.
- Sadeghi N, Camby I, Goldman S, et al: Effect of hydrophilic components of the extracellular matrix on quantifiable diffusion-weighted imaging of human gliomas: preliminary results of correlating apparent diffusion coefficient values and hyaluronan expression level. *AJR Am J Roentgenol* 2003;181:235–241.
- Bello L, Gambini A, Castellano A, et al: Motor and language DTI fiber-tracking combined with intraoperative subcortical mapping for surgical removal of gliomas. *Neuroimage* 2008;39:369–382.
- Kinoshita M, Goto T, Okita Y, et al: Diffusion tensor-based tumor infiltration index cannot discriminate vasogenic edema from tumor-infiltrated edema. *J Neurooncol* 2010;96:409–415.
- Akai H, Mori H, Aoki S, et al: Diffusion tensor tractography of gliomatosis cerebri: fiber-tracking through the tumor. *J Comput Assist Tomogr* 2005;29:127–129.
- Yamada K, Kizu O, Kubota T, et al: The pyramidal tract has a predictable course through the centrum semiovale: a diffusion-tensor based tractography study. *J Magn Reson Imaging* 2007;26:519–524.
- Nguyen-Thanh T, Reisert M, Anastasopoulos C, et al: Global tracking in human gliomas: a comparison with established tracking methods. *Clin Neuroradiol* 2013, E-pub ahead of print.
- Chai Y, Adamolekun B: Cryptogenic gelastic epilepsy originating from the right temporal lobe. *Med Princ Pract* 2010;19:153–158.