

# Application of osteomucoperiosteal flap in large unicystic ameloblastoma to promote early bone healing: An alternative to primary bone grafting

GAGAN KHARE, SANJEEV KUMAR

## Abstract

**Background:** The unicystic variety of ameloblastoma is reported to be significantly less prone to recurrence in young patients than its conventional counterpart, and therefore can be treated conservatively. This paper describes a technique of using an osteoperiosteal flap to allow complete enucleation of a unicystic ameloblastoma. The technique maintains the continuity of the mandible and restores full thickness as well as strength of the mandible to promote early healing. It also maintains blood supply and proper facial contour so that esthetics is unimpaired. **Materials and Methods:** We describe two cases of unicystic ameloblastoma in which we used an osteoperiosteal flap. This flap was then infrafractured at the lower border to obliterate the dead space. **Results:** The sequential radiographs demonstrate early incorporation of the graft and complete filling of the defect by 3 months. At 5 years of follow-up in our first case, complete healing of bone was observed. **Conclusions:** We believe that these procedures can be the treatment of choice in such cases, especially with larger lesions, as these rapidly restore the patient's facial contour to normal as well as reduce the healing time.

**Keywords:** Early healing, osteoperiosteal flap, unicystic ameloblastoma

## Introduction

Surgical removal of large cyst/tumor leaves behind large bony cavity which should be addressed to promote early regeneration and healing. This can be accomplished by special surgical techniques or by limiting the volume of the blood clot in the cavity.<sup>[1]</sup> The former may be accomplished by approximating the bony walls of the cavity<sup>[2]</sup> or by saucerization like procedures, while the latter requires grafting with bone and bone substitutes or implantation with a variety of alloplastic materials.<sup>[3-8]</sup> Although these techniques have met with varying degrees of success clinically, their application is sometimes limited by availability, cost and propensity for additional surgical morbidity. The osteomucoperiosteal flap, as described by Yih *et al.*,<sup>[9]</sup> has been used by us with some modifications in large mandibular lesions with gratifying results. This article presents our technique of employing the

osteomucoperiosteal flap for unicystic ameloblastoma of the mandible.

## Materials and Methods

An informed consent was obtained from the patients and the study conformed to the ethical guidelines of the 1975 Declaration of Helsinki.

### Case 1

A 13-year-old boy reported to the Department of Oral and Maxillofacial Surgery, Subharti Dental College, Meerut, in April 2005, with a large unilocular, radiolucent lesion that occupied most of the left mandibular ramus and coronoid process extending from the neck of the condyle to the left 1<sup>st</sup> molar region. The lesion was well contained within the bone, with expansion of the lateral cortex but no clinical or radiological perforation of the bone. Associated with the lesion was an unerupted 2<sup>nd</sup> molar. There was resorption of the distal root of the 1<sup>st</sup> molar [Figure 1a].

An incisional biopsy of the lesion revealed it to be a unicystic follicular ameloblastoma.

### Case 2

A 28-year-old man reported to the Department of Oral and Maxillofacial Surgery, Subharti Dental College, Meerut, in October 2008, with a large, infected unilocular, radiolucent lesion of the right mandibular body, part of the ramus and extending almost to the coronoid area. Associated with the lesion was an unerupted 3<sup>rd</sup> molar [Figure 2a].

A provisional diagnosis of unicystic ameloblastoma was made which was histopathologically reported as follicular ameloblastoma.

Department of Oral and Maxillofacial Surgery, Subharti Dental College, Swami Vivekanand Subharti University, Delhi-Haridwar bypass road, Meerut – 250001, Uttar Pradesh, India

**Correspondence:** Dr. Gagan Khare, Department of Oral and Maxillofacial Surgery, Subharti Dental College, Subharti Puram, Delhi-Haridwar by-pass road, Meerut – 250001, Uttar Pradesh India. E-mail: gagankhare2002@yahoo.co.in

Access this article online	
Quick Response Code:	Website: www.contempclindent.org
	DOI: 10.4103/0976-237X.91789

## Technique

Under general anesthesia, an intraoral incision was made through mucosal and submucosal tissue, leaving the periosteum undisturbed over the bone surface. A flap was developed in this plane and reflected beyond the maximum bulge of the lesion [Figure 3a].

The periosteum was then incised along the superior and anterior margins of the proposed osteotomy cut and reflected to about a centimeter from the bone. Careful undermining of this layer was done at the posterior margin in order to preserve continuity of the periosteum across the bony cut at this site. The osteotomy was then performed using a No. 8 round bur and a No. 701 fissure bur, keeping in mind that the lesion was not perforated and that the maximum bulk of the lesion was exposed [Figure 3b].

The inferior edges of the anterior and posterior osteotomy cuts were placed just above the lower or posterior border of the mandible so as to facilitate a clean fracture at the inferior margin. An osteoperiosteal flap was then developed and hinged laterally to expose the cystic wall [Figure 3c].

The lesion was then enucleated and the resultant surgical defect was treated with *Carnoy's solution* while preserving the inferior alveolar nerve. The osteoperiosteal flap was then infrafractured at the lower border by digital pressure so that the volume of the cavity was reduced [Figure 3d].

Any discrepancy of crestal height of the medial and lateral cortices was adjusted by trimming and the lateral cortex

was stabilized with wire osteosynthesis in our first case, while the lateral cortex was kept in collapsed position in our second case. The mucosa and periosteum were sutured at the superior margin as one layer with the lingual tissues to achieve a primary closure [Figure 3e].

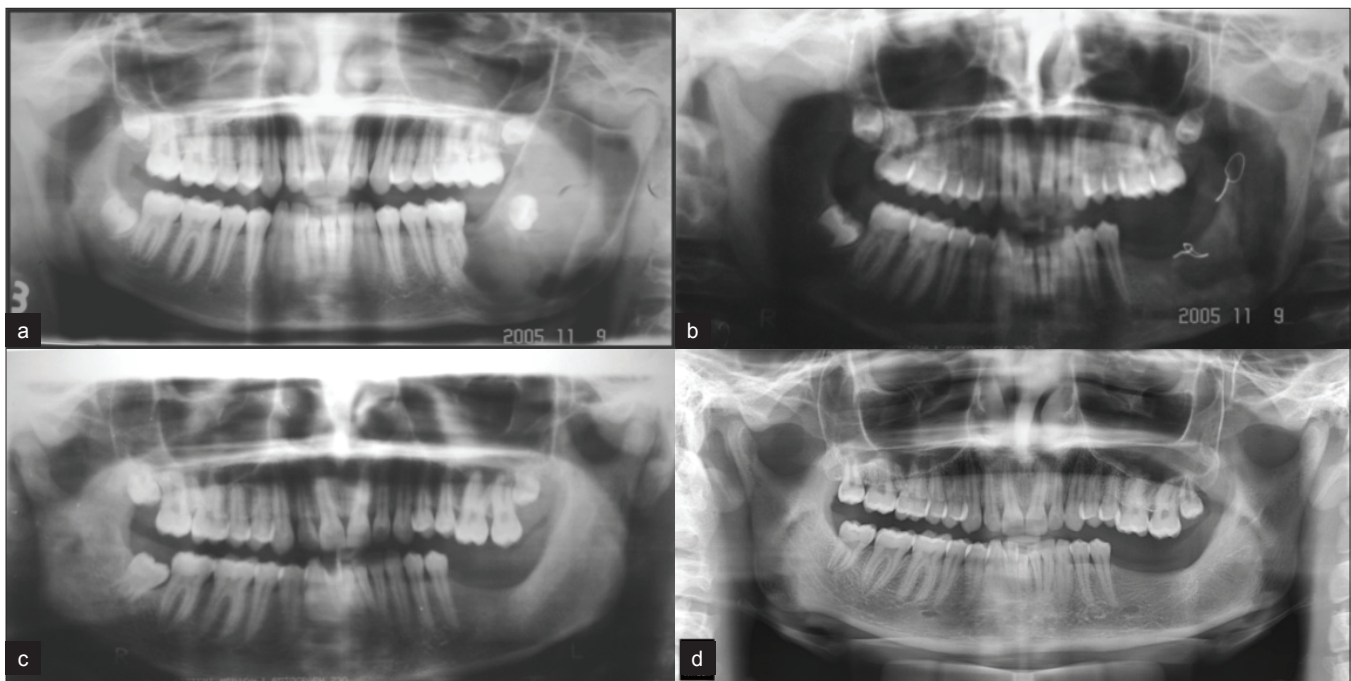
## Results

Postoperative recovery was uneventful and healing by primary intention occurred in both cases. The patients were closely followed up for early signs of infection, pathological fracture, bone resorption or recurrence of lesion. None of these complications occurred in both of the patients and radiological signs of bone regeneration and remodeling were appreciable within 3 months [Figure 2b, c]. During the follow-up period of 5 years for the first case, satisfying degree of bone architecture and good facial contour were achieved [Figure 1b–d].

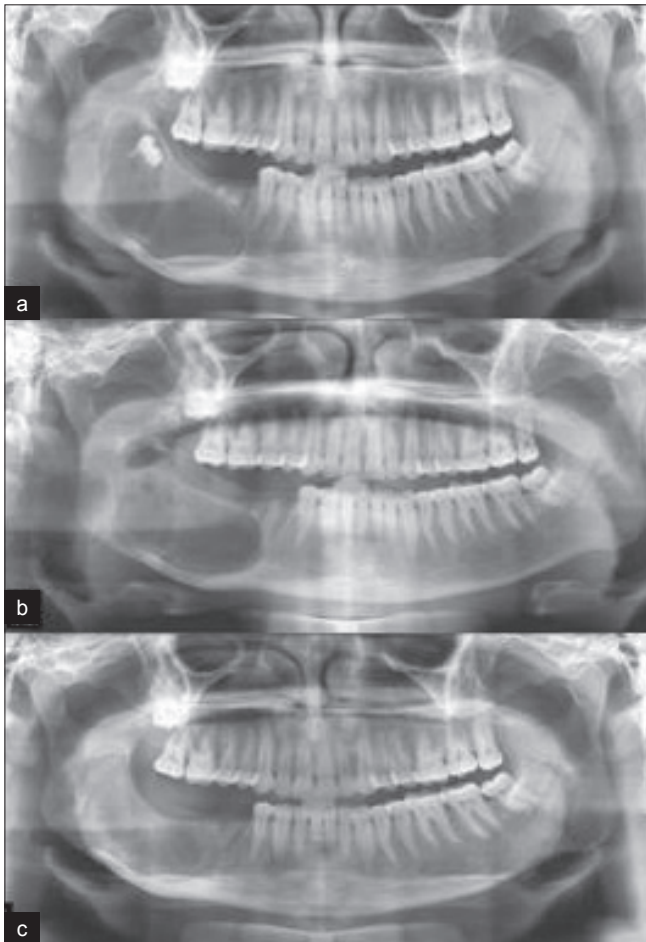
## Discussion

In the past, attempts have been made to reduce the size of the bony cavity with a variety of materials.<sup>[2-8]</sup> However, none of them was found to be successful in routine clinical practice. To overcome this, the pathologic cavity was managed by packing the defect or turning a mucosal flap into it and then packing with iodoform gauze.<sup>[10]</sup> Healing in these cases is slow and accompanied by increased morbidity.

Brosch<sup>[11]</sup> in 1957 exposed the entire buccal cortex beyond the full extent of the cyst. Decortication and removal of the lateral cortical plate was performed and the cyst was enucleated in



**Figure 1:** (a) Panoramic radiograph showing unilocular ameloblastoma of the left side of the mandible; (b) immediate post-operative; (c) 3 months post-operative; (d) 5 years post-operative

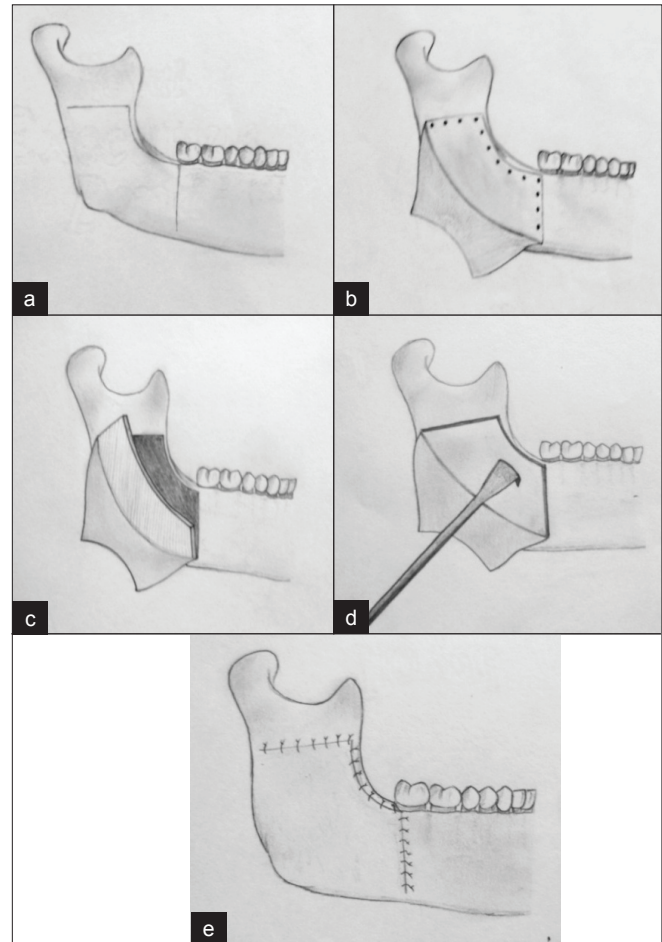


**Figure 2:** (a) Panoramic radiograph showing unilocular ameloblastoma of the right side of the mandible; (b) immediate post-operative; (c) 3 months post-operative

toto. The adjacent tissues were collapsed into the defect to reduce the dead space. Brosch procedure was modified by Hillel Ephros *et al.*<sup>[12]</sup> in 1991 in which the large Odontogenic Keratocyst, the attached impacted mandibular 3<sup>rd</sup> molar, entire coronoid process and lateral cortex of the posterior body and ramus were removed *en bloc*. Medial cortical bone in the areas of the perforation was removed, peripheral osteotomy was performed and the flap was sutured primarily.

Moose<sup>[13]</sup> used a muco-osteoperiosteal flap to reinforce the closure. Hong *et al.*<sup>[2]</sup> described a method for reducing the size of the cystic defect in which a muco-osteoperiosteal flap was developed and reflected by the removal of a strip of the mandible at the inferior aspect of the defect. After cystectomy, the dead space was obliterated by two means: firstly the space was implanted with bony chips obtained from the inferior aspect of the bony cavity and secondly by collapsing a muco-osteoperiosteal flap.

In 1991, Yung and Morita<sup>[9]</sup> described a technique of using an osteomucoperiosteal flap in the treatment of 13 cystic lesions which could obliterate large bony defects effectively. The



**Figure 3:** (a) Incision; (b) mucosal flap with osteoperiosteal incision; (c) reflected osteoperiosteal flap by fracturing the inferior osseous portion of the flap; (d) placement of the osteoperiosteal flap into the cavity after removal of the tumor; (e) closure of the mucosal flap

advantages of this technique are that it 1) obliterates dead space and hence facilitates hemostasis; 2) facilitates healing and resists infection; 3) promotes bone regeneration; 4) preserves all vital tissues and 5) avoids the use of secondary grafting procedures.

It is a well-established fact that unicystic ameloblastomas involving the ramus of the mandible do not require resection and respond well to careful enucleation and chemical cauterization.<sup>[14]</sup> In a review by Samman and Lau,<sup>[14]</sup> it was found that large unicystic ameloblastomas are usually approached extraorally with decortication followed by enucleation and application of Carnoy's solution. The wound is then either closed primarily or packed with ribbon gauze to facilitate healing. Some of the problems that may occur with this procedure are hematoma formation and delayed healing, wound breakdown and infection, facial deformity and formation of a knife-edge ridge.

We have modified the technique for the large lesions involving



the ramus and body region of the mandible by deliberately incising the periosteum at the superior and anterior margins so as to hinge the flap laterally without resistance. We find that it vastly improves access and visibility of the lesion which can then be easily enucleated. The second modification is to trim the superior margins to the same height, which prevents the development of a knife-edge ridge.

The rationale for our technique in which we used an osteoperiosteal flap was enucleation of the lesion with retention of the blood supply as the flap is pedicled. This facilitates healing and resists infection. Moreover, the flap has the potential for regeneration and obliterates the dead space. Also, it prevents collapse of the facial soft tissues and minimizes postoperative deformity. The sequential radiographs demonstrate early incorporation of the graft and complete filling of the defect by 3 months. At this time, there was normal trabecular pattern and normal facial contour with no signs of numbness of lips. At 5 years of follow-up in our first case, complete healing of bone was observed.

This technique is best suited for resection of the unilocular benign lesions in young individuals as the facial esthetics is better provided and chances of numbness of the lower lip are minimal with this technique. However, careful case selection and treatment planning is required, and patients with thinned out buccal cortex, and with the presence of aggressive lesions in which seeding of the tumor into the replaced bone is anticipated are excluded from this technique. Moreover, periosteal stripping and inadvertent fracturing of the buccal cortical plate is to be prevented for the success of the technique.

## Conclusion

We believe that these procedures can be the treatment of choice in such cases, especially with larger lesions, as these rapidly restore the patient's facial contour to normal as well as reduce the healing time. Larger studies need to be pursued to provide better evidence of its effectiveness.

## Acknowledgments

We sincerely thank Dr. Nikhil Srivastava, Principal, Subharti Dental College, and Dr. Susmita Saxena, Prof. and Head of the Department of Oral Pathology, Subharti Dental College, Meerut, for their valuable guidance and support.

## References

1. Van Doorn ME. Enucleation and primary closure of jaw cysts. *Int J Oral Surg* 1972;1:17.
2. Hong M, Wang NA, Yu J. Utilization of collapsed bone plate for the management of large mandibular cysts: Case report. *J Chin Stomatol* 1963;9:56.
3. Bahn SL. Plaster: A bone substitute. *Oral Surg Oral Med Oral Pathol* 1966;21:672.
4. Ferrari Parabita G, Derada Troletti G, Zanetti U. Use of calcium hydroxyapatite in oral and maxillofacial surgery: III, Treatment of voluminous cysts of the maxilla, surgical technique and presentation of cases. *Minerva Stomatol* 1985;34:913-22.
5. Bailey BJ, Holt GR. *Surgery of the mandible*. New York, NY: Thieme; 1987.
6. Campbell LP. Autogenous bone to repair mandibular cyst defects: Report of two cases. *J Oral Surg* 1965;23:265.
7. Marble HB. Homografts of freeze-dried bone in cystic defects of the jaws: A survey of ninety-one cases. *Oral Surg Oral Med Oral Pathol* 1968;26:118-23.
8. Hjorting-Hansen E, Quoted by Moore JR. Studies on implantation of An organic bone in cystic jaw lesions, Copenhagen, Denmark: Munksgeerd; 1970.
9. Yih WY, Morita V. A modified technique for obliteration of large bony defects after cystectomy. *J Oral Maxillofac Surg* 1991;49:689-92.
10. Waite DE. *Textbook of Practical Oral Surgery, Cysts of the Oral Cavity*. 2<sup>nd</sup> ed. Philadelphia, PA: Lea and Febiger; 1978;335-8.
11. Farmand M, Makek M. Late results following the Brosch Procedure for treating large mandibular cysts. *J Max Fac Surg* 1983;11:211-5.
12. Ephros H, Lee HY. Treatment of a large Odontogenic Keratocyst using the Brosch Procedure. *J Oral Maxillofac Surg* 1991;49:871-4.
13. Moose SM. Osteoperiosteal flap for operation of large tumors and cysts of the jaws. *J Oral Surg* 1952;10:229.
14. Lau SL, Samman N. Recurrence related to treatment modalities of unicystic ameloblastoma: A systematic review. *Int J Oral Maxillofac Surg* 2006;35:681-90.

**How to cite this article:** Khare G, Kumar S. Application of osteomucoperiosteal flap in large unicystic ameloblastoma to promote early bone healing: An alternative to primary bone grafting. *Contemp Clin Dent* 2011;2:283-6.

**Source of Support:** Nil. **Conflict of Interest:** None declared.