

Human Neurocysticercosis Case and an Endemic Focus of *Taenia solium* in Lao PDR

Hyeong-Kyu Jeon¹, Tai-Soon Yong², Woon-Mok Sohn³, Jong-Yil Chai⁴, Duk-Young Min⁵, Han-Jong Rim⁶, Bounnaloth Insiengmay⁷ and Keeseon S. Eom^{1,*}

¹Department of Parasitology and Medical Research Institute, Chungbuk National University School of Medicine, Cheongju 361-763, Korea;

²Department of Environmental Medical Biology, Yonsei University College of Medicine, Seoul 120-752, Korea; ³Department of Parasitology and Institute of Health Sciences, Gyeongsang National University School of Medicine, Jinju 660-751, Korea; ⁴Department of Parasitology and Tropical Medicine, Seoul National University College of Medicine, Seoul 110-799 Korea; ⁵Department of Microbiology and Immunology, Eulji University College of Medicine, Daejeon 301-746, Korea; ⁶Department of Parasitology, Korea University College of Medicine, Seoul 130-705, Korea;

⁷Department of Preventive Medicine, Ministry of Healthcare, Lao PDR

Abstract: A male patient with neurocysticercosis was identified in Montai Village, Xay District, Oudomxay Province, Lao PDR in February 2004. He had a history of diagnosis for neurocysticercosis by a CT scan in Thailand after an onset of epileptic seizure in 1993. A pig in the same district was found to contain *Taenia solium* metacestodes (= cysticerci); the slaughtered pig body contained more than 2,000 cysticerci. In addition to morphological identification, molecular identification was also performed on the cysticerci by DNA sequencing analysis of the mitochondrial *cox1* gene; they were confirmed as *T. solium* metacestodes. The patient is regarded as an indigenous case of neurocysticercosis infected in an endemic focus of *T. solium* taeniasis/cysticercosis in Oudomxay Province, Lao PDR.

Key words: *Taenia solium*, human cysticercosis, neurocysticercosis, pig, Lao PDR

Taeniasis and cysticercosis are caused by *Taenia solium*, *Taenia saginata*, and *Taenia asiatica* in human and intermediate host animals. The pork tapeworm *T. solium* is of medical and veterinary importance because it causes human and porcine cysticercosis. The most severe clinical manifestation is neurocysticercosis, caused by *T. solium* metacestodes developed from *T. solium*. It is distributed throughout Latin America, Africa, and Asia, including China, Indonesia, Nepal, India, Korea, Thailand, Cambodia, and Vietnam [1-5].

Documented data regarding human taeniasis and cysticercosis, as well as porcine cysticercosis, in Lao PDR, are quite limited. As far as the literature is concerned, human neurocysticercosis cases in Lao PDR have not been clearly demonstrated except for a few anecdotal cases. However, outside of Lao PDR, there had been some neurocysticercosis cases which were considered as the ones acquired in Lao PDR and then immigrated

to Australia [6,7]. Another case of human cysticercosis found in the United States which had some possibility related to Lao PDR was a 14-year-old girl with cysticercosis in the eyelid [8]. Before visiting a clinic, she spent 2 years (1971 and 1972) in Vietnam and Laos and showed no evidence of neurocysticercosis except for a metacestode exhibited from the eyelid [8].

As is well recognized, porcine cysticercosis is endemic to Vietnam and Cambodia [1,4]. Quite a number of human taeniasis in Lao PDR has been reported in Vientiane, Khammouane, and Champasak Province between 1989 and 2002 [9-12] via a nationwide survey from 2000 to 2002 [13] and a study of 814 subjects in Saravane Province [14]. The literature background on human taeniasis consisted of 9 reports on intestinal helminth infections in Lao PDR since 1989, including the most recent one [15]. The helminth infections reported were ascariasis, trichuriasis, hookworm infections, strongyloidiasis, enterobiasis, opisthorchiasis, schistosomiasis, minute intestinal trematode infections, and taeniasis. However, very little is known about the distribution and prevalence of human cysticercosis and *T. solium* taeniasis inside Lao PDR. The present study aimed to provide an evidence of the presence of the life cycle of *T. solium* and also human cysticercosis case(s) in Ou-

•Received 10 May 2013, revised 21 July 2013, accepted 9 August 2013.

*Corresponding author (kseom@chungbuk.ac.kr)

© 2013, Korean Society for Parasitology and Tropical Medicine

This is an Open Access article distributed under the terms of the Creative Commons Attribution Non-Commercial License (<http://creativecommons.org/licenses/by-nc/3.0>) which permits unrestricted non-commercial use, distribution, and reproduction in any medium, provided the original work is properly cited.

domxay Province, Lao PDR.

For molecular typing of *T. solium* metacestodes collected from a pig in the same locality of Oudomxay Province (Fig. 1), PCR-amplified fragments of *cox1* were directly sequenced. The prim-

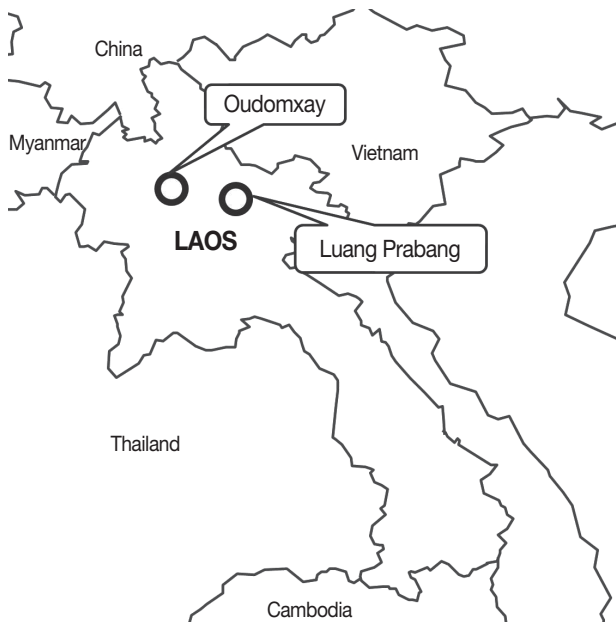

Fig. 1. The surveyed area in Lao PDR for human neurocysticercosis, *Taenia solium*, and porcine cysticercus infection.

er-walking method was employed to obtain the direct sequences for each of the amplified fragments. Cyclic sequencing from both ends of the fragments was performed using the Big-Dye Terminator sequencing kit (Applied Biosystems, Carlsbad, California, USA) and the reaction products were electrophoresed on an automated DNA sequencer (model 3730KL) (Applied Biosystems). The sequences were assembled and aligned using the BioEdit program (version 5.0.6, BIOSOFT) (Ferguson, Missouri, USA). BLAST searches were used to identify the sequenced regions through comparison with *Taenia* sequences that had been deposited in the GenBank database. Specifically, we identified *Taenia* tapeworm specimens by comparison with *cox1* nucleotide sequences of *T. solium* (GenBank no. AB086256), *T. saginata* (GenBank no. AY684274), and *T. asiatica* (GenBank no. AF445798). PCR was performed for all specimens as described previously [16].

A male patient with neurocysticercosis was identified in Montai Village, Xay District, Oudomxay Province, Lao PDR while the author's group was visiting the place for a helminthological survey in February 2004. He visited our survey team and gave a history of diagnosis by CT scan in Thailand after an onset of epileptic seizure in 1993 (Fig. 2A). After treatment with albendazole (15 mg/kg, 3 times per day for 7 days, with pred-

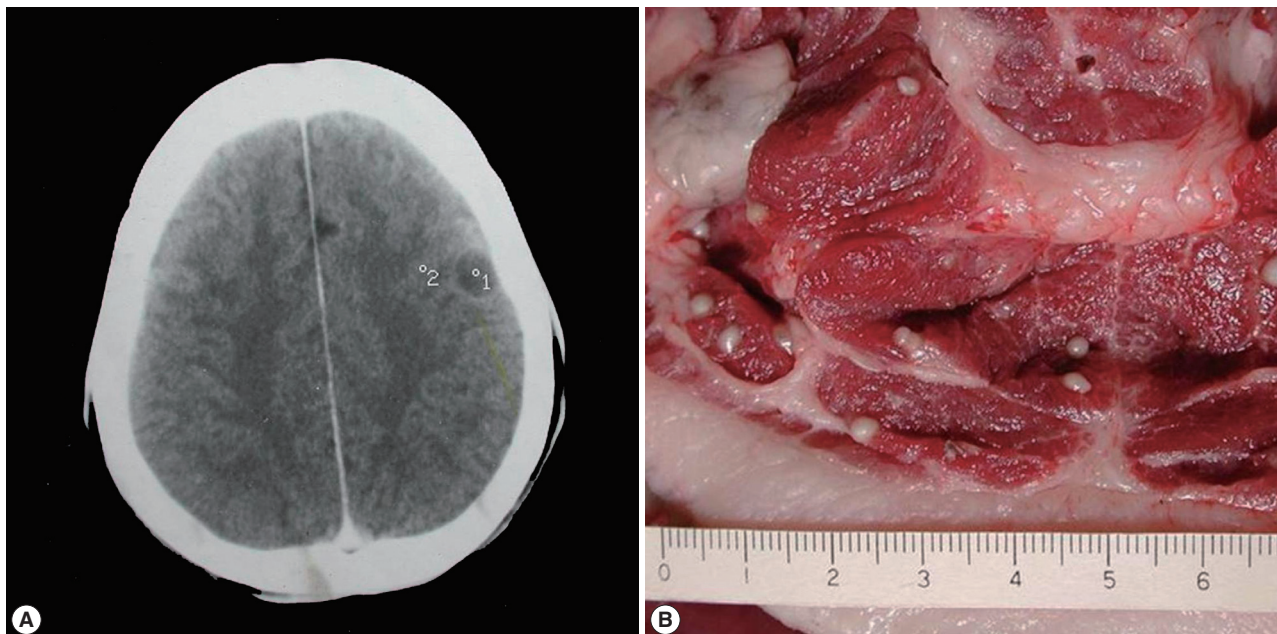


Fig. 2. (A) Vesicular cysticerci on contrasted CT scan. "1" shows a small and rounded low-density area (1.5 cm diameter) in a patient with parenchymal neurocysticercosis. "2" demonstrates a minimized calcifying lesion. (B) *T. solium* metacestodes in the flesh of a pig obtained from a slaughterhouse in Oudomxay, Lao PDR. The scale at the bottom of the picture represents a centimeter ruler with millimeter subdivisions.

Table 1. Domestic animals discarded after slaughter due to cysticercus infection in Xay District, Oudomxay, Lao PDR (October 2003-February 2004)

	Cattle (buffalos and cows)	Pigs
Slaughtered (n = 9,263)	1,437	7,826
Cysticercosis cases (n = 90)	44	46
Cysticercosis cases per month (range)	0-7	1-12
% positive for cysticercosis	3.1	0.6

nisolone), he was followed up by CT scan 3 years later in Lao PDR and minimized calcified lesions were found. Three of his family members and relatives had the same or similar symptoms, such as headache. One of their favorite foods was chopped pork wrapped with banana leaf (Sommou). Serological diagnosis of cysticercosis was conducted on his family members (n=8) using ELISA. The serum antibody levels in patients with *Taenia* tapeworm infections were quantified by micro-ELISA. *T. solium* metacestode antibodies were detected in sera collected from patients, with relative antibody levels in mean absorbance and SD of 0.20 ± 0.04 or higher. Serum samples from 5 people (0.08 ± 0.1) and 3 people (0.25 ± 0.03) displayed significant levels of reactivity with *T. solium* metacestode antigen. All of them were subjected to coprological examinations by the Kato-Katz method for *Taenia* eggs but turned out to be negative in all. Further CT scan study was not implemented and subcutaneous nodules were all negative.

A pig was found by our team infected with *T. solium* metacestodes showing rostellar hooklets (more than 2,000 cysticerci in the whole body) upon slaughter in February 2004, in the same locality of the patient (Fig. 2B). According to the data from the government veterinarian of the Oudomxay Office of Agriculture, Forestry, Livestock, and Fisheries in Xay District, the prevalence of cysticerci-infected animals between February 2003 to October 2004 was 0.6% (46/7,826) in pigs and 3.1% (44/1,437) in cattle (Table 1). The most prevalent areas for cysticerci infection in pigs were Beng (Thameun, Namet, Napa), Namong (Nathong, Nasavang, Ban Khouang), and La (Parkla Lack) villages.

Molecular identification of the cysticerci from pigs on the basis of the DNA sequence corresponding to position 90-530 of the *cox1* gene (440 bp) showed 100% similarity to the reference sequence of *T. solium* (GenBank no. AB086256) and genotypically they were identified as “Asian type” *T. solium*.

The present study suggested strongly that the life cycle of *T. solium* is maintained in the surveyed village of Xay District,

Oudomxay Province, Lao PDR causing a substantial number of human cysticercosis patients, including neurocysticercosis. Regarding adult tapeworm recovery in various localities of Lao PDR, only 3 among the total 126 strobila recovered from people were *T. solium* (123 were *T. saginata*), and all 3 specimens of *T. solium* were from Luang Prabang Province, which is located just nearby the Oudomxay Province [15]. Hence, it is presumed that the life cycle of *T. solium* may exist in the northern mountainous areas of Lao PDR, whereas *T. saginata* is distributed in almost all areas of Lao PDR, i.e., Bokeo, Bolikhamxay, Champasak, Houaphan, Khammouane, Luang Namta, Luang Prabang, Oudomxay, Phongsaly, Saysomboune, Saravane, Savannakhet, Xayaboury, Xe Kong, Xieng Khouang, and Vientiane Municipality [15].

Risk factors for *T. solium* taeniasis and cysticercosis in Lao PDR include consumption of raw pork and using human feces to fertilize vegetable gardens. The habit of eating raw pork is common in the northern highlands in Vietnam [3] and also in the northern provinces of Lao PDR. Porcine cysticercosis has been identified in pigs in northern Vietnam, primarily through slaughterhouse reports, but these have indicated low infection rates [2]. Although porcine cysticercosis has been said to be present in Cambodia and Lao PDR, the data on the prevalence are rarely available. The present case of neurocysticercosis found in Oudomxay Province was considered to have been infected indigenously in Lao PDR considering the presence of a mangled pig at the same locality as well as the survey report evidenced *T. solium* [15]. The molecular genotyping of the metacestode detected from a pig in this study, as revealed by DNA sequencing of the mitochondrial *cox1* gene, indicated that they were identical with the “Asian type *T. solium*”.

ACKNOWLEDGMENTS

We thank the staff of the Center for Laboratory and Epidemiology, Department of Hygiene and Prevention, Vientiane, and Provincial Health Department, Lao PDR for their help in collecting fecal samples and preparing Kato-Katz smears. The field survey in Lao PDR from 2000 until 2012 was implemented by 2 international collaboration projects between Korea and Lao PDR. This work was supported by a research grant from Chungbuk National University in 2011 for DNA analysis and immunoserological tests. Parasite materials used in this study were provided by the Parasite Resource Bank of Korea, National Research Center (2012-0000037), Republic of Korea.

Conflict of interest

We have no conflict of interest related to this study.

REFERENCES

1. Doanh NQ, Kim NT, De NV, Lung NV. Result of survey on taeniasis and cysticercosis in humans and pigs in BacNinh and BacKan Provinces. *Vet Sci Techn* 2002; 1: 46-49.
2. Rajshekhar V, Joshi DD, Doanh NQ, van De N, Xiaonong Z. *Taenia solium* taeniasis/cysticercosis in Asia: epidemiology, impact and issue. *Acta Trop* 2003; 87: 53-60.
3. Willingham III AL, Van De N, Doanh NQ, Cong le D, Dung TV, Dorny P, Cam PD, Dalsgaard A. Current status of cysticercosis in Vietnam. *Southeast Asian J Trop Med Public Health* 2003; 35(suppl): 35-50.
4. Dorny P, Somers R, Cam Thi Dang T, Khong Nguyen V, Vercurysse J. Cysticercosis in Cambodia, Lao PDR and Vietnam. *Southeast Asian J Trop Med Public Health* 2004; 35(suppl 1): 223-226.
5. Waikagul J, Dekumyoy P, Ananthaphruti MT. Taeniasis, cysticercosis and echinococcosis in Thailand. *Parasitol Int* 2006; 55(suppl): S175-S180.
6. McDowell D, Harper CG. Neurocysticercosis-two Australian cases. *Med J Aust* 1990; 152: 217-218.
7. Crimmins D, Collignon PJ, Dwyer D, Danta G. Neurocysticercosis: an under-recognized cause of neurological problems. *Med J Aust* 1990; 152: 434-438.
8. Perry HD, Font RL. Cysticercosis of the eyelid. *Arch Ophthalmol* 1978; 96: 1255-1257.
9. Kobayashi J, Vannachone B, Xeutvongsa A, Manivang K, Ogawa S, Sato Y, Pholsena K. Prevalence of intestinal parasitic infection among children in two villages in Lao PDR. *Southeast Asian J Trop Med Public Health* 1996; 27: 562-565.
10. Chai JY, Hongvanthong B. A small-scale survey of intestinal helminthic infections among the residents near Parkse, Laos. *Korean J Parasitol* 1998; 36: 55-58.
11. Vannachone B, Kobayashi J, Nambany S, Manivong K, Inthakone S, Sato Y. Epidemiological survey on intestinal parasite infection in Khammouane Province, Lao PDR, with special reference to *Strongyloides* infection. *Southeast Asian J Trop Med Public Health* 1998; 29: 717-722.
12. Hohmann H, Panzer S, Phimpachan C, Southivong C, Schelp PF. Relationship of intestinal parasites to the environment and to behavioral factors in children in the Bolikhamxay Province of Lao PDR. *Southeast Asian J Trop Med Public Health* 2001; 32: 4-13.
13. Rim HJ, Chai JY, Min DY, Cho SY, Eom KS, Hong SJ, Sohn WM, Yong TS, Standgaard GDH, Phommasack B, Yun CH, Hoang EH. Prevalence of intestinal parasite infections on a national scale among primary schoolchildren in Laos. *Parasitol Res* 2003; 91: 267-272.
14. Sayasone S, Odermatt P, Phoumindr N, Vongsaravane X, Somsombath V, Phetsouvavh R, Choulamany X, Strobel M. Epidemiology of *Opisthorchis viverrini* in a rural district of southern Lao PDR. *Trans R Soc Trop Med Hyg* 2007; 101: 40-47.
15. Jeon HK, Yong TS, Sohn WM, Chai JY, Min DY, Yun CH, Rim HJ, Pongvongsa T, Banouvong V, Insisiengmay B, Phommasack B, Eom KS. Current status of human taeniasis in Lao People's Democratic Republic. *Korean J Parasitol* 2013; 51: 259-263.
16. Jeon HK, Chai JY, Kong Y, Waikagul J, Insisiengmay B, Rim HJ, Eom KS. Differential diagnosis of *Taenia asiatica* using multiplex PCR. *Exp Parasitol* 2009; 121: 151-156.