



Safety and Efficacy of Left Atrial Appendage Excision Using a Vascular Stapler

Ji Hyeon Park, M.D.¹, Suk Ho Sohn, M.D.¹, Jae Woong Choi, M.D.¹, Eun Ah Park, M.D., Ph.D.², Ho Young Hwang, M.D., Ph.D.¹

Departments of ¹Thoracic and Cardiovascular Surgery and ²Radiology, Seoul National University Hospital, Seoul National University College of Medicine, Seoul, Korea

ARTICLE INFO

Received November 13, 2019

Revised December 9, 2019

Accepted December 11, 2019

Corresponding author

Ho Young Hwang

Tel 82-2-2072-3020

Fax 82-2-764-3566

E-mail scalpel@hanmail.net

ORCID

https://orcid.org/0000-0002-8935-8118

Background: This study was conducted to evaluate the safety and efficacy of left atrial appendage (LAA) excision using a vascular stapler.

Methods: Fifty consecutive patients (mean age, 68±9 years) who underwent LAA excision using a vascular stapler during concomitant cardiac surgery were enrolled. In all patients, the excision site was evaluated using computed tomography at a median of 7 days (interquartile range, 5–13.3 days) postoperatively. The safety endpoint of this study was the occurrence of LAA excision-related events, which were defined as bleeding from the excision site that required reinforcement sutures or reoperation due to excision site bleeding. The efficacy endpoint was LAA excision failure, which was defined as a remnant LAA (a stump >1 cm in maximum length) or extravasation of radiocontrast dye.

Results: LAAs were excised using 60- and 45-mm vascular staplers in 49 patients and 1 patient, respectively. Reinforcement sutures were needed in 4 patients due to staple-line bleeding and in 4 patients due to bleeding of the surrounding tissues. No patient underwent reoperation due to staple-related bleeding. A remnant LAA was observed in 2 patients, while extravasation of radiocontrast dye was not observed in any patients.

Conclusion: LAA excision using a vascular stapler may be an effective technique for LAA exclusion. Delicate handling of the stapler device and LA tissue is required to prevent procedure-related complications.

Keywords: Arrhythmia, Atrial fibrillation, Thrombosis, Computed tomography angiography

Introduction

Atrial fibrillation (AF), which is the most common cardiac arrhythmia, causes substantial morbidity and mortality. This condition is associated with a 5- to 7-fold increase in the risk of stroke, and the annual stroke risk in patients with AF is over 5% [1-3]. The left atrial appendage (LAA) is a finger-like projection extending from the main body of the left atrium (LA). The LAA is a remnant of the embryonic LA, while the rest of the left atrial cavity derives from an outgrowth of the pulmonary veins [4]. In patients with AF, the vast majority of thrombi form in the LAA; previous studies have reported that more than 90% of thrombi formed in the LAA in non-valvular AF patients [5,6]. Accordingly, exclusion of the LAA from the bloodstream plays a key role in the prevention of thromboembolic

events in patients with AF [7,8].

Various interventional and surgical techniques for LAA exclusion have been reported [8-13]. However, each procedure has advantages and disadvantages. Several studies have demonstrated the efficacy of LAA excision using a vascular stapler, but discrepancies exist in their results [1-3]. Therefore, the present study aimed to evaluate the safety and efficacy of LAA excision using a vascular stapler in AF patients undergoing open-heart surgery.

Methods

Patient characteristics

The study protocol was reviewed by the Institutional Review Board of Seoul National University Hospital and ap-



proved as a minimal-risk retrospective study (approval no., H-1910-034-1068). Based on the institutional guidelines for waiving consent, individual consent was not required. Between August 2017 and July 2019, 50 patients with AF (male:female, 25:25; mean age, 68±9 years) who underwent LAA excision with a vascular stapler and concomitant cardiac surgery were enrolled. All patients had longstanding persistent AF with an average AF duration of 67.2±70.5 months. Hypertension (40%) and dyslipidemia (30%) were the most common comorbidities (Table 1).

Operative techniques and perioperative management

All operations were performed via median sternotomy using aorto-bicaval cannulation under moderate hypothermia and cold cardioplegic arrest. LAA excision was performed using commercially available vascular staplers (Endo GIA; Medtronic, Minneapolis, MN, USA). The Cox maze procedure with cryoablation was performed in 46 patients. Concomitant cardiac procedures included mitral valve surgery (n=28), tricuspid valve surgery (n=19), aortic valve surgery (n=11), and coronary artery bypass grafting (CABG, n=2) (Table 2). When concomitant mitral valve or arrhythmia surgery was needed, LAA excision was performed after completion of all procedures, just before closing the left atriotomy. In cases of concomitant CABG, the CABG was performed after releasing the aortic cross-clamp as an on-pump beating heart procedure. The heart was completely emptied during CABG with bicaval cannulation and left ventricular venting.

Table 1. Preoperative characteristics and risk factors of patients (N=50)

Characteristic	Value
Age (yr)	68±9
Sex (male:female)	25:25
Risk factors	
Smoking	17 (34)
Hypertension	20 (40)
Diabetes mellitus	8 (16)
History of stroke	7 (14)
Chronic renal failure	14 (28)
Dyslipidemia	15 (30)
Duration of atrial fibrillation (yr)	5.5
Echocardiographic data	
Left ventricular ejection fraction (%)	58±7
Left atrium dimension (mm)	61±12

Values are presented as mean±standard deviation or number (%), unless otherwise stated.

Low-molecular-weight heparin was started in all patients as soon as possible, usually on postoperative day 1. This was followed by administration of warfarin with a target international normalized ratio between 2.0 and 3.0 based on the types of combined procedures. Aspirin (100 mg/day) was also administered to the 2 patients who underwent concomitant CABG.

Safety and efficacy endpoints of left atrial appendage excision

The safety endpoint of this study was the occurrence of LAA excision-related events, which were defined as bleeding from the excision site that required reinforcement sutures during surgery or reoperation for excision-site bleeding.

For the evaluation of the efficacy of LAA excision, electrocardiogram-gated computed tomography (CT) was performed prior to patient discharge. LAA excision failure was defined as follows: (1) presence of a remnant LAA (an LAA pouch with a maximum length greater than 1 cm) or (2) extravasation of radiocontrast dye. Electrocardiogram-gated CT angiography was performed at a median of 7 days (interquartile range, 5–13.3 days) after surgery in all patients.

Clinical and computed tomography evaluation

Early mortality was defined as any death within 30 days after surgery or during the same hospital admission. Respiratory complications included postoperative pneumonia or >48 hours of prolonged ventilator support. Postoperative stroke was defined as a newly apparent neurological deficit found on a brain imaging study, such as brain CT or brain magnetic resonance imaging; these findings were confirmed by a neurologist. Acute renal failure was defined as an increase of >50% in serum creatinine level from the

Table 2. Operative data of patients (N=50)

Variable	Value
Concomitant surgery	
Cox maze procedure	46 (92)
Mitral valve procedure	28 (56)
Aortic valve procedure	11 (22)
Coronary artery bypass grafting	2 (4)
Others	8 (16)
Aortic cross-clamp time (min)	105±42
Cardiopulmonary bypass time (min)	155±49

Values are presented as number (%) or mean±standard deviation.

preoperative value or a need for renal replacement therapy irrespective of the serum creatinine level. Low cardiac output syndrome was defined as a cardiac index <2.0 L/min/m² or a systolic arterial pressure <90 mm Hg requiring mechanical support or inotropic infusion (dopamine or dobutamine) of >5 µg/kg/min. Cardiac CT scans were performed with dual-source CT (Somatom Force; Siemens Medical Solutions, Forchheim, Germany). Image acquisition was gated to 40% of the RR interval. The contrast injection protocol included 70 mL of iopromide (Iomeron 400; Bracco Diagnostics, Milan, Italy) followed by 50 mL of an 8:2 mixture of normal saline and contrast medium at a flow rate of 4 mL/sec. Gated cardiac CT scans were performed at first pass and 2 minutes after contrast administration. Data are expressed as mean±standard deviation, median with interquartile range, or a proportion.

Results

Operative data and safety endpoint

The LAAs were excised using 60- and 45-mm-long vascular staplers in 41 patients and 1 patient, respectively. Both 60- and 45-mm staplers were used in the other 8 patients. Regarding the safety endpoint, reinforcement suturing

was required in 8 patients due to bleeding from the staple line (n=4) or bleeding from the surrounding soft tissue (n=4) (Table 3). No patient underwent reoperation related to excision site bleeding.

Early clinical results

No early mortality was observed. Postoperative complications included acute renal failure (n=12, 24%), respiratory complications (n=4, 8%), and low cardiac output syndrome (n=3, 6%). No patient suffered from stroke or any other thromboembolic event. Although 2 patients underwent reoperation for bleeding, no patient had bleeding from the LAA excision site as described above (Table 4).

Efficacy endpoint of left atrial appendage excision

A remnant LAA was seen in 2 patients (Fig. 1). Extravasation of radiocontrast dye was not found in any patients.

Discussion

This study demonstrated 2 main findings. First, LAA excision using a vascular stapler was a safe and effective tech-

Table 3. Operative data regarding the excision of the LAA and the safety endpoint (N=50)

Variable	No. of patients (%)
Cartridge used (mm)	
60	41 (82)
45	1 (2)
Both 60 and 45	8 (16)
Reinforcement suturing at the LAA excision site	8 (16)
Bleeding from staple line	4 (8)
Bleeding from surrounding tissues	4 (8)

LAA, left atrial appendage.

Table 4. Early mortality and postoperative complications (N=50)

Variable	No. of patients (%)
Early mortality	0
Morbidities	
Acute renal failure	12 (24)
Respiratory complication	4 (8)
Low cardiac output syndrome	3 (6)
Bleeding reoperation	2 (4)
Thromboembolic event	0
Stroke	0
Mediastinitis	0

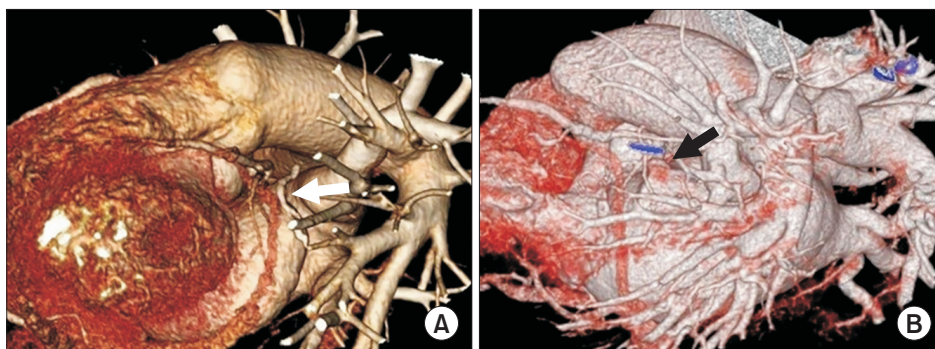


Fig. 1. Three-dimensional images of electrocardiogram-gated computed tomography from 2 patients illustrating LAA excision sites. (A) Complete excision of the LAA (white arrow). (B) Remnant of the LAA (black arrow). LAA, left atrial appendage.

nique. Second, careful handling of the stapler device and LAA tissues may prevent excision-related complications.

Concerns when dealing with the LAA include the effectiveness of the occlusion and safety issues regarding procedure-related complications, such as bleeding and thromboembolic events. Various interventional and surgical techniques for LAA exclusion have been demonstrated [8-14], each of which has advantages and disadvantages. Suture ligation and device occlusion of the LAA are frequently incomplete, leaving a communication between the LAA and the body of the LA. In contrast, the presence of an LAA remnant and bleeding that requires reinforcement are more common when excision techniques are used [10,13].

Previous studies have evaluated the efficacy of LAA excision using a vascular stapler [1-3,7,11]. A previous study enrolling 5 patients demonstrated that there was no intraoperative hemorrhage from the staple line and no intra-atrial thrombus; additionally, LAA obliteration was described as satisfactory, although no objective data was provided [7]. A previous randomized controlled trial compared the safety and efficacy of LAA exclusion techniques such as suture ligation and stapler closure performed concomitantly with CABG [15]. The authors of that study demonstrated unsatisfactory results after LAA excision using a vascular stapler; procedure-related tears occurred in 6 of 52 patients, and residual stumps larger than 1 cm were found in 9 of 33 patients in whom a stapler was used, as shown on postoperative transesophageal echocardiography [15].

In the present study, consecutive patients who underwent LAA excision using a vascular stapler during the study period were enrolled. As in previous studies, vascular staplers originally developed for endoscopic operations were used even though all patients underwent surgery via median sternotomy [10,11]. This is because bulky staplers for open surgery are very difficult to use in the limited pericardial space, with adjacent structures such as the pulmonary artery, left ventricle, and left pulmonary veins. All patients underwent contrast-enhanced gated cardiovascular CT, which has been confirmed to be effective for evaluation of the LA [16]. Although the safety endpoint rate was lower than found previously, it was still considerable (16%). Because the LAA is a remnant of the embryonic LA, the LAA has a thick wall with trabeculations. However, the base of the LAA is relatively thin and fragile because the rest of the LA wall derives from an outgrowth of the pulmonary veins [4]. Therefore, gentle manipulation of the LAA and surrounding tissues and avoidance of over-traction during clamping and firing of the vascular stapler may be required to reduce procedure-related complications. Regarding the

efficacy endpoint, remnant LAA stumps were found in only 2 patients, and extravasation of radiocontrast dye was not observed in any patients.

Several limitations of the present study should be noted. First, this study was a retrospective observational study conducted at a single institution. Second, the number of patients enrolled was relatively small, limiting the ability to draw definitive conclusions from the findings. Third, the results were not compared with those obtained using other LAA exclusion techniques, since all consecutive patients were treated with stapler excision during the study period.

In conclusion, LAA excision using vascular staplers may be a safe and effective technique for LAA exclusion during cardiac surgery. Careful handling of the stapler device and LAA tissues is required to prevent excision-related complications.

Conflict of interest

No potential conflict of interest relevant to this article was reported.

Funding

This study was supported by a Grant of the Samsung Vein Clinic Network (Daejeon, Anyang, Cheongju, Cheonan; Fund no. KTCS04-140).

ORCID

Ji Hyeon Park: <https://orcid.org/0000-0002-3272-0067>
Suk Ho Sohn: <https://orcid.org/0000-0001-7391-3415>
Jae Woong Choi: <https://orcid.org/0000-0002-0921-756X>
Eun Ah Park: <https://orcid.org/0000-0001-6203-1070>
Ho Young Hwang: <https://orcid.org/0000-0002-8935-8118>

References

1. Doty DB. *Surgical treatment of atrial fibrillation*. Heart Lung Circ 2004;13:280-7.
2. Narayan SM, Cain ME, Smith JM. *Atrial fibrillation*. Lancet 1997;350:943-50.
3. Gillinov AM, Blackstone EH, McCarthy PM. *Atrial fibrillation: current surgical options and their assessment*. Ann Thorac Surg 2002;74:2210-7.
4. Sherif HM. *The developing pulmonary veins and left atrium: implications for ablation strategy for atrial fibrillation*. Eur J Cardiothorac Surg 2013;44:792-9.
5. Blackshear JL, Odell JA. *Appendage obliteration to reduce stroke in*

- cardiac surgical patients with atrial fibrillation. *Ann Thorac Surg* 1996;61:755-9.
6. Leung DY, Black IW, Cranney GB, Hopkins AP, Walsh WF. *Prognostic implications of left atrial spontaneous echo contrast in nonvalvular atrial fibrillation.* *J Am Coll Cardiol* 1994;24:755-62.
 7. DiSesa VJ, Tam S, Cohn LH. *Ligation of the left atrial appendage using an automatic surgical stapler.* *Ann Thorac Surg* 1988;46:652-3.
 8. Salzberg SP, Plass A, Emmert MY, et al. *Left atrial appendage clip occlusion: early clinical results.* *J Thorac Cardiovasc Surg* 2010;139:1269-74.
 9. Stoddard MF, Dawkins PR, Prince CR, Ammash NM. *Left atrial appendage thrombus is not uncommon in patients with acute atrial fibrillation and a recent embolic event: a transesophageal echocardiographic study.* *J Am Coll Cardiol* 1995;25:452-9.
 10. Lee R, Vassallo P, Kruse J, et al. *A randomized, prospective pilot comparison of 3 atrial appendage elimination techniques: internal ligation, stapled excision, and surgical excision.* *J Thorac Cardiovasc Surg* 2016;152:1075-80.
 11. Gillinov AM, Pettersson G, Cosgrove DM. *Stapled excision of the left atrial appendage.* *J Thorac Cardiovasc Surg* 2005;129:679-80.
 12. Salzberg SP, Gillinov AM, Anyanwu A, Castillo J, Filsoufi F, Adams DH. *Surgical left atrial appendage occlusion: evaluation of a novel device with magnetic resonance imaging.* *Eur J Cardiothorac Surg* 2008;34:766-70.
 13. Katz ES, Tsiamtsiouris T, Applebaum RM, Schwartzbard A, Tunick PA, Kronzon I. *Surgical left atrial appendage ligation is frequently incomplete: a transesophageal echocardiographic study.* *J Am Coll Cardiol* 2000;36:468-71.
 14. Kuh JH, Song JY, Kim TY, Kim JH, Choi JB. *Treatment of atrial fibrillation in elderly patients with the Cox Maze procedure concurrently with other cardiac operations.* *Korean J Thorac Cardiovasc Surg* 2017;50:171-6.
 15. Healey JS, Crystal E, Lamy A, et al. *Left Atrial Appendage Occlusion Study (LAAOS): results of a randomized controlled pilot study of left atrial appendage occlusion during coronary bypass surgery in patients at risk for stroke.* *Am Heart J* 2005;150:288-93.
 16. Ismail TF, Panikker S, Markides V, et al. *CT imaging for left atrial appendage closure: a review and pictorial essay.* *J Cardiovasc Comput Tomogr* 2015;9:89-102.