

Received:  
10 August 2020

Accepted:  
13 October 2020

Cite this article as:

Brennan CA, Morrissey B, Dubois-Marshall S, McAteer D, Qadir A, Ramsay G. Assessing the role of the universal addition of CT thorax to CT abdomen and pelvis in the COVID era. A retrospective multicentre cohort study. *BJR Open* 2020; **2**: 20200044.

## ORIGINAL RESEARCH

# Assessing the role of the universal addition of CT thorax to CT abdomen and pelvis in the COVID era. A retrospective multicentre cohort study

<sup>1,2</sup>CHRISTOPHER ANTHONY BRENNAN, MBChB, <sup>1,3,4</sup>BRIAN MORRISSEY, BSc (Hons), MSc, MBChB, FRCR, <sup>1,3</sup>SYLVIE DUBOIS-MARSHALL, MBChB, MD, FRCR, <sup>1,3</sup>DYMPNA MCATEER, MB BCh BAO, FRCP, FRCR, <sup>1,2</sup>ABDUL QADIR, MB BS MD FRCS(Gen Surg) FACS and <sup>1,2,5</sup>GEORGE RAMSAY, MBChB PhD FRCS

<sup>1</sup>Aberdeen Royal Infirmary, Aberdeen, United Kingdom

<sup>2</sup>Department of General Surgery, Aberdeen Royal Infirmary, Aberdeen, United Kingdom

<sup>3</sup>Department of Clinical Radiology, Aberdeen Royal Infirmary, Aberdeen, United Kingdom

<sup>4</sup>Aberdeen Biomedical Imaging Centre, University of Aberdeen, Aberdeen, United Kingdom

<sup>5</sup>Rowett Institute, University of Aberdeen, Aberdeen, United Kingdom

Address correspondence to: Christopher Anthony Brennan  
E-mail: [christopher.brennan@nhs.scot](mailto:christopher.brennan@nhs.scot)

The authors Sylvie Dubois-Marshall, Dympna McAteer and Abdul Qadir contributed equally to the work.

**Objective:** The SARS-CoV2 infection is associated with high mortality for individuals who undergo emergency surgery. The United Kingdom surgical associations and Colleges of Surgeons collectively recommended the addition of CT Thorax to all emergency CT abdomen/pelvis imaging in order to help identify possible COVID-19 patients. Early identification of these patients would lead to optimal treatment strategies for the patient and protection for staff members. However, an extension of CT would be associated with increased irradiation doses for the patient, and its diagnostic relevance was unclear.

**Methods:** This was a retrospective observational review looking at all surgical admissions that required a CT Thorax/Abdomen/Pelvis across 7 weeks during the COVID-19 pandemic, across four Scottish Hospitals. CT thorax investigations (of non-surgical patients) were also re-assessed by a single radiologist to assess the extent of pathology identified at the lung bases (and therefore would be included in a standard CT abdomen and pelvis).

**Results:** Of 216 patients identified who had a CT thorax/Abdomen/Pelvis during the timeframe, 5 were diagnosed with COVID-19. During this timeframe, 77 patients underwent solely CT thorax. Across the entire cohort, 98% of COVID pathology was identified at the lung bases. The estimated sensitivity and specificity of CT thorax was 60 and 86.4% respectively.

**Conclusions:** In a region with relatively low prevalence of SARS-COV2 infection, inclusion of CT Thorax in surgical admission imaging does not significantly contribute to identification and management of SARS-COV2 patients. We therefore suggest that imaging the lung bases can be sufficient to raise clinical suspicion of COVID-19.

**Advances in knowledge:** This paper adds further evidence to that from other single UK centres that the addition of CT chest for all patients does not yield any further diagnostic information regarding coronavirus. Additionally, rapid SARS-CoV-2 testing in the UK (which is currently widely available) further demonstrates that inclusion of the entire chest during CT examination of the acute abdomen is not required.

## INTRODUCTION

SARS-CoV-2 is a highly infectious RNA virus which predominantly causes infection of the nasopharynx and upper respiratory tract. It is a novel human pathogen and, accordingly, one where no previous immunity has been encountered in the human population. It is currently causing an international pandemic, with over 6 million cases globally at the beginning of June and continued new

infections. Severe infection has significant mortality, with a reported 614 deaths per 1 million population in the United Kingdom<sup>1</sup> to date. Whilst predominantly a respiratory, infectious disease and critical care pathology, COVID-19 infection and its sequelae has influenced the care of the unvetted General Surgical Emergency admission. This is particularly germane when mortality and pulmonary complications in patients undergoing surgery with COVID infection has an associated mortality rate of 24%.<sup>2</sup>

The COVID-19 pandemic has resulted in significant changes to admission pathways within the acute setting. Both general medical and surgical pathways in most hospitals have COVID-19 assessment units and treatment wards. Patients without COVID-19 are managed in separate areas of the hospital, where possible. Guidance for management of patients with suspected COVID-19 have thus focused on early identification of individuals at risk of COVID-19. This aimed to optimise patient and staff safety. Patients who have COVID-19 are higher mortality rates individually, but also can lead to the infection of other patients and staff members alike. Furthermore, patients who may require theatre will be subject to aerosol generating procedures and may lead to further post-operative deterioration associated with this disease.

In the United Kingdom, an intercollegiate agreement was made between several surgical colleges and associations,<sup>3</sup> which made several recommendations. Specifically relating to acute admissions, the guidance states: "Any patient undergoing an abdominal CT scan for acute pain as an emergency presentation should have a CT chest at the same time, unless CT chest previously performed within 24h. Current tests for COVID-19, including CXR and chest CT, may be false negative." The inclusion of CT chest may contribute to the early recognition of patients with COVID-19, and thus optimise clinical care during the pandemic.<sup>4,5</sup> As the pandemic has developed, the British Society of Thoracic Imaging (BSTI) and Royal College of Radiologists (RCR) have recommended against the usage of CT chest in the acute surgical patient.<sup>6,7</sup> However, the Royal Colleges of Surgeons have yet to change their guidance where CT thorax is still recommended in this setting.

Such an approach involves a significant increase in radiation exposure for patients, as well as additional workload for the radiologist. Given the increased cancer risk through exposure to ionising radiation, coupled with CT chest being normal in COVID settings in up to 20% of cases,<sup>8</sup> means that the potential risks of additional imaging may outweigh the clinical gain.

Additionally, approximately 4% of patients with COVID-19 infection present solely with gastrointestinal symptoms, with all others reporting some form of upper respiratory symptom that can be identified through focused history at presentation.<sup>9</sup> Lung bases are included in abdominal imaging and can be sufficient for identification of COVID-19.<sup>10</sup> As such, through a combination of increased radiation exposure alongside minimal clinical gain, the routine inclusion of CT chest in patients presenting with abdominal pain during the pandemic has been brought into question. We therefore aimed to look at the clinical significance of routine inclusion of CT chest in emergency general surgical admissions.

## METHODS

### Study design

This was a multicentre retrospective observational cohort study.

### Study setting

All patients presenting to emergency general surgery in four hospitals in the north of Scotland were included. Aberdeen Royal

Infirmery is a tertiary referral centre in the North East of Scotland caring for a population of 580,000 patients. Dr Gray's Hospital is a district general hospital in Elgin caring for 95,000 individuals. Balfour Hospital in Orkney and the Gilbert Bain Hospital in Shetland are the main hospitals managing patients in both of these Island sets. The approximate population managed by these island hospitals is 45,000. We assume a disease prevalence of 5%. This is based on cumulative data collected during the pandemic relating to tests performed and proportion of positive results.<sup>11</sup>

### Patients

All acute adult (aged  $\geq 16$ ) surgical presentations undergoing CT Chest/Abdomen/Pelvis (CT CAP) during their admission between 25 March 2020 and 12 May 2020 were included. Patients were identified through the common server by searching for all CAP scans undertaken during the study period (PACS). CT CAP scans were excluded from analysis if undertaken due to trauma, elective investigation of surgical pathology and investigation of non-surgical pathology (e.g. staging scans for cancer). CT technique used on all CT scanners within the study centres consisted of intravenous iodinated contrast spiral volume acquisition through the whole chest, abdomen, and pelvis. CT reports were reviewed for evidence of SARS-CoV-2. A score for diagnoses of SARS-CoV-2 was then allocated to each individual CT scan based on guidance from the BSTI. The scoring system identified scans as normal findings (CVCT0), typical/classic SARS-CoV-2 pathology (CVCT1), indeterminate findings which may be in keeping with SARS-CoV-2 (CVCT2), and non-COVID-19 pathology (CVCT3).<sup>12</sup> CT findings were then correlated with results of SARS-CoV-2 throat/nasal swab. These data, and data on patient outcome, management and operative interventions were obtained from the electronic patient record (EPR Trackcare).

### Assessment of CT findings

Scans were re-assessed by a chest radiologist with particular attention to whether SARS-CoV-2 CT changes were evident in the lung bases, as this area of the chest would be routinely included in abdominal imaging. A second data set was also collected on all patients across the above sites that had CT imaging of the chest regardless of presentation or suspicion of COVID-19. These data were collected in the same time period of 7 weeks across the same hospitals used in the CT CAP cohort. These patients were again allocated a COVID score, with findings correlated with swab status. This second set was collected to better appreciate the proportion of known SARS-CoV-2 positive patients who may have had CT changes, and whether those changes were visible in the lung bases.

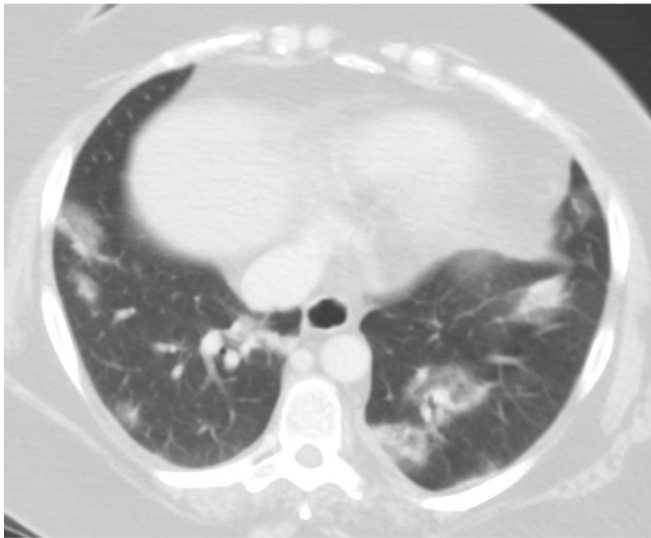
### Data analysis

Data were stored on password secured NHS computers on excel spreadsheet. Specificity and sensitivity analysis was performed using an online calculator (MedCalc.com)

### Ethical review

This retrospective study and audit of clinical practice has been registered with the NHS Grampian clinical effectiveness team.

Figure 1. Contrast-enhanced CT of the chest through the lung bases demonstrating bibasal foci of ground glass opacification, mostly in the peripheries, in keeping with SARS-CoV-2 infection.



## RESULTS

A total of 212 patients had a CT chest/abdomen and pelvis test during the study timeframe and were included in the study. There were only three cases in this cohort (the surgical cohort) where CT findings were in keeping with SARS-CoV-2, an example can be seen in [Figure 1](#), demonstrating typical features of peripheral, mostly basal, ground glass opacities and foci of consolidation. The number patients with indeterminate findings was nine. Thus, 210 patients (95%) had a CT scan of their chest with no findings of SARS-CoV-2. The demographics of the cohort are depicted in [Table 1](#).

As the number of positive patients in this cohort was low (5%), any further analysis of the diagnostic accuracy of a CT scan in this context was not possible assessing these patients individually. Accordingly, a further analysis was performed on patients who had a positive diagnosis of SARS-CoV-2 on CT chest undertaken during the same timeframe in the same hospitals (the non-surgical cohort). These patients had no clinical suspicion of surgical pathology, were managed in separate areas of the hospitals and did not have a CT of their abdomen or pelvis. There was a total of 77 patients in this cohort. The demographics of this group are depicted in [Table 2](#).

Those cases where there were findings identified on CT chest were then re-analysed by a chest radiologist to assess whether the lung pathology could be identified at the lung bases (thereby being identifiable on a standard portal venous phase protocol CT abdomen and pelvis). A total of 98% of the findings in both cohorts could be identified at the lung bases. The individual patient in the surgical cohort where the findings were above this level tested negative by swab and the indeterminate findings on their scan were approximately 5 cm above the diaphragm. This data is represented in [Table 3](#).

Table 1. Demographics of surgical cohort who had a CT Chest/Abdomen and Pelvis examination as an emergency in the timeframe during this study

	CT Chest/Abdomen/ Pelvis
Median age (IQR)	63.5 (26)
% FEMALE	(113)54%
% MALE	(95)46%
Location of scan	
Aberdeen Royal Infirmary	190
Dr Grays	16
Gilbert Bain (Shetlands)	5
Balfour (Orkneys)	1
CT Chest findings	
Normal Chest findings	(106)50%
Indeterminate findings	(9)4%
Positive findings	(3)1%
Non-COVID findings	(94)45%
Patient diagnosis	
Obstruction	32 (15%)
Perforation	20 (10%)
Malignancy	27 (12%)
Appendicitis	27 (12%)
Non-specific abdominal pain	32 (15%)
Cholecystitis	14 (6.5%)
Pancreatitis	8 (4%)
Colitis	9 (4.5%)
Diverticulitis	7 (3.5%)
Renal Calculi	6 (3%)
Ileus	5 (2.5%)
Post-operative collection	3 (1.5%)
Sigmoid volvulus	2 (1%)
Bowel Ischaemia	2 (1%)
Other	17 (8%)

IQR, interquartile range.

## DISCUSSION

Ever since the 2019 Novel Coronavirus, SARS-CoV2 (or COVID19), was identified as a human pathogen in Wuhan Province in China,<sup>13</sup> early identification of those with the disease has been of paramount importance.<sup>14</sup> Individuals diagnosed with SARS-CoV2 infection can be cared for with the appropriate precautions to reduce risk of nosocomial spread. As such, adding a CT chest to anyone who is requiring a CT assessment of the abdominal and pelvic organs was suggested by national bodies in the United Kingdom.<sup>3</sup> However, within this early snapshot review, in a population where the

Table 2. Demographic characteristics of patients who had a CT chest and were found to have SARS-CoV-2 infection

	CT Chest
Median age (IQR)	65 (21)
% FEMALE	(31)40%
% MALE	(46)60%
Aberdeen Royal Infirmary	71
Dr Grays	4
Gilbert Bain	2
Balfour	0

IQR, interquartile range.

prevalence of SARS-CoV2 is comparatively low, our data would suggest that such a practice adds little in the management of this pandemic. This is particularly pertinent now, we see the rates reducing across the western world and easier access to RT-PCR swab testing. Our analysis of sensitivity and specificity is represented in [Table 4](#).

The symptoms experienced by a patient who has contracted the virus varies greatly. Although the majority are respiratory or coryzal (cough, shortness of breath, loss of smell and taste) abdominal and gastrointestinal symptoms are recognised in up to 20% of cases.<sup>15</sup> However, only a minority (approximately 4%) will have isolated abdominal symptoms.<sup>10</sup> In the case of those with suspected surgical pathology, careful history taking, and examination is required to further stratify the possibility of COVID-19 as a cause for the presentation. With appropriate clinical acumen, patients who have had close contacts with SARS-CoV2 or upper respiratory tract symptoms can be identified, A CT chest could be considered for these individuals. However, given that the majority (98%) of lung pathology identified in this study was noted in the lung bases, missed cases of SARS-CoV2 infection is unlikely when a CT of the upper abdomen (which will inevitably include lung bases) is performed.

We have identified a similar study being performed during this time-period. This is a study performed in Southampton, which comes to a similar conclusion regarding the inclusion of CT thorax.<sup>16</sup> However, the main the difference is our inclusion of CT thorax reviews to clarify lung base findings, and our regional change in guidance as a result. This is a dynamic field

Table 3. shows the assessment of lung base pathology

	CT Chest/Abdomen/ Pelvis	CT chest
Total cases	212	77
Cases with CT changes	88	77
Changes visible in lung bases (%)	98% (87)	98% (76)

Table 4. shows the predicted sensitivity and specificity of CT chest, compared to RT-PCR swab testing in the surgical cohort ( $n = 88$ ). This assumes a prevalence of 5% during this timeframe

Statistic	Value	95% confidence interval
Sensitivity	60%	14.7–94.7%
Specificity	86.4%	77.4–92.8%
Positive predictive value	18.8%	8.7–36%
Negative predictive value	97.6%	93.3–99.2%

RT PCR, reverse transcription polymerase chain reaction.

of research,<sup>17,18</sup> and other studies have assessed the diagnostic pick up of pathology at the lung bases and confirm our findings of identification of pathology at these sites.<sup>19–21</sup> However, we have analysed the safety of excluding the formal CT scan of the thorax, as a screening tool, in patients who present with abdominal pain in a region of presumed low COVID 19 prevalence.

Interestingly, during the initial discussions about re-establishing elective practice, patient self-isolation, testing by RT PCR and CT chest were all suggested to be required before it was safe to undertake a general anaesthetic. Given the high mortality rate associated with post-operative COVID 19 infection, this was an understandably stringent precaution. However, CT chest is no longer deemed necessary in the elective setting.<sup>22</sup> The guidance has yet to be changed for the emergency surgical patients and our data would suggest that reducing the rates of CT chests performed in this cohort is appropriate.

Our review has several limitations. There have been little data published around the disease prevalence of COVID-19. We have presumed a prevalence of less than 10%, however, there are little data to support the proportion of infected patients. The number of patients swabbed and tested by RTPCR varied during the length of this study. Swabs increased when availability allowed. However, a true assessment of accuracy between CT and RT PCR is not possible in this work. It is also a retrospective study. Patient capture was however from the regional radiology network, Picture Archiving and Communications System (PACS). As such, it is unlikely that any patients will be missed from our analysis. Our surgical admission data were limited in its representation of patients with COVID-19. Only 5 patients out of a possible 216 were identified as having the disease, which gives a limited representation of the overall prevalence of COVID-19 within the community. It does however emphasise the small proportion of concurrent surgical problems with COVID-19 as acute presentations. In order to better appreciate the diagnostic significance of CT chest, the second data set was collected which strengthens this study significantly. This data set represented CT chest imaging

in those with high clinical suspicion of COVID-19, regardless of pathology.

The addition of chest imaging to acute surgical admission imaging has not significantly contributed to the identification of patients with COVID-19. These data have changed

regional practice in that we no longer include the chest imaging, unless there is a high clinical suspicion, or if on review the lung bases are suggestive of COVID-19. Given the dynamic nature of this pandemic, and the resource strain, we feel that this is safe for patients, reduces radiation and has a low false negative rate.

## REFERENCES

- COVID-19 situation update for the EU/EEA and the UK, as of 15 June 2020 [Internet]. *European Centre for Disease Prevention and Control* 2020; Available from. cited 15 June 2020.
- Collaborative C. Articles mortality and pulmonary complications in patients undergoing surgery with perioperative SARS-CoV-2 infection: an international cohort study. 2020;.
- Updated Intercollegiate general surgery guidance on COVID-19 — Royal College of surgeons., <https://www.rcseng.ac.uk/coronavirus/joint-guidance-for-surgeons-v2/>. (n.d.). Retrieved June 2, 2020 from.
- Zhai P, Ding Y, Wu X, Long J, Zhong Y, Li Y. The epidemiology, diagnosis and treatment of COVID-19. *Int J Antimicrob Agents* 2020; **55**: 105955. doi: <https://doi.org/10.1016/j.ijantimicag.2020.105955>
- Sun Q, Qiu H, Huang M, Yang Y.. (). Lower mortality of COVID-19 by early recognition and intervention: experience from Jiangsu Province. *Ann Intensive Care* 2020; **10** Springer 2020, December 1. doi: <https://doi.org/10.1186/s13613-020-00650-2>
- Updated BSGAR-BSTI statement for chest imaging in patients undergoing CT of the acute surgical abdomen.. *The British Society of Thoracic Imaging [Internet]*. cited 2020 Jul 21.
- The role of CT chest in patients presenting acutely and requiring an abdominal CT. *The Royal College of Radiologists [Internet]*. cited 2020 Jul 21.
- Isikbay M, Hope MD, Raptis CA, Shah A, Bierhals AJ, Bhalla S, et al. Ct on the diamond Princess: what might this tell us about sensitivity for COVID-19? *Radiology: Cardiothoracic Imaging* 2020; **2**: e200155.
- Docherty AB, Harrison EM, Green CA, Hardwick HE, Pius R, Norman L, et al. Features of 16,749 hospitalised UK patients with COVID-19 using the ISARIC who clinical characterisation protocol. *MedRxiv* 2020;2020.04.23.20076042.
- Siegel A, Chang PJ, Jarou ZJ, Paushter DM, Harmath CB, Arevalo JB, et al. Lung base findings of coronavirus disease (COVID-19) on abdominal CT in patients with predominant gastrointestinal symptoms. *American Journal of Roentgenology* 2020; **215**: 607–9. doi: <https://doi.org/10.2214/AJR.20.23232>
- Coronavirus (COVID-19): trends in daily data - gov.scot [Internet].. Available from: <https://www.gov.scot/publications/coronavirus-covid-19-trends-in-daily-data/> [cited 2020 Jul 21].
- COVID-19 BSTI reporting templates. *The British Society of Thoracic Imaging*.. Retrieved June 3, 2020 from].
- Zhu H, Wei L, Niu P. The novel coronavirus outbreak in Wuhan, China. *Glob Health Res Policy* 2020; **56**.. doi: <https://doi.org/10.1186/s41256-020-00135-6>
- Asif HM, Hashmi HAS. Early detection of COVID-19. *MedRxiv* 2020;2020.04.04.20053363.
- Hope MD, Raptis CA, Shah A, Hammer MM, Henry TS. A role for CT in COVID-19? what data really tell us so far. *The Lancet* 2020; **395**: 1189–90. doi: [https://doi.org/10.1016/S0140-6736\(20\)30728-5](https://doi.org/10.1016/S0140-6736(20)30728-5)
- Hamilton NE, Adam GH, Ifan DL, Lam SS, Johnson K, Vedwan KAG, et al. Diagnostic utility of additional whole-chest CT as part of an acute abdominal pain CT imaging pathway during the COVID-19 pandemic. *Clin Radiol* 2020; **75**: 592–8. doi: <https://doi.org/10.1016/j.crad.2020.06.002>
- Nair A, Rodrigues JCL, Hare S, Edey A, Devaraj A, Jacob J, et al. A British Society of thoracic imaging statement: considerations in designing local imaging diagnostic algorithms for the COVID-19 pandemic. *In Clinical Radiology* 2020;(Vol. 75, Issue 5, pp. 329–334). W.B. Saunders Ltd..
- Rodrigues JCL, Hare SS, Edey A, Devaraj A, Jacob J, Johnstone A, et al. An update on COVID-19 for the radiologist - A British society of Thoracic Imaging statement. *Clin Radiol* 2020; **75**(Issue 5): 323–5 W.B. Saunders Ltd. doi: <https://doi.org/10.1016/j.crad.2020.03.003>
- Gahide G, Frandon J, Vendrell JF. COVID-19 patients presenting with afebrile acute abdominal pain. *Clinical Medicine* 2020;.
- Dane B, Brusca-Augello G, Kim D, Katz DS. Unexpected findings of coronavirus disease (COVID-19) at the lung bases on abdominopelvic CT. *American Journal of Roentgenology* 2020;: 1–4.
- Siegel A, Chang PJ, Jarou ZJ, Paushter DM, Harmath CB, Arevalo JB, et al. Lung base findings of coronavirus disease (COVID-19) on abdominal CT in patients with predominant gastrointestinal symptoms. *American Journal of Roentgenology* 2020; **215**: 607–9. doi: <https://doi.org/10.2214/AJR.20.23232>
- The Association of Coloproctology of Great Britain and Ireland Resumption of Elective Colorectal Surgery during COVID-19 Updated ACPGIBI considerations on surgical prioritisation, patient vulnerability and environmental risk assessment. (n.d..