

Dysferlinopathy in a cohort of Chinese patients: clinical features, mutation spectrum, and imaging findings

Qi-Fu Guo¹, Zhi-Xian Ye¹, Liang-Liang Qiu¹, Xin Lin¹, Jia-He Lai¹, Min-Ting Lin¹, Zhi-Qiang Wang^{1,2}, Ning Wang^{1,2}, Feng Lin¹

¹Department of Neurology and Institute of Neurology, The First Affiliated Hospital of Fujian Medical University, Fuzhou, Fujian 350005, China;

²Fujian Key Laboratory of Molecular Neurology, Fuzhou, Fujian 350005, China.

To the Editor: Mutations in the dysferlin (DYSF) gene lead to dysferlinopathy, which is referred to as a group of muscular dystrophies with autosomal recessive inheritance. Dysferlinopathy includes Miyoshi myopathy (MM), limb-girdle muscular dystrophy (LGMD2B), and other atypical phenotypes, such as the “proximo-distal (PD)” phenotype and distal anterior compartment myopathy.^[1] Currently, the genotype-phenotype correlation in the majority of patients remains unclear. In addition, increasing cases of atypical patients and intra-familial variability of the clinical phenotype appear to complicate the correlation. Here, we combined targeted next-generation sequencing (NGS) and multiplex ligation-dependent probe amplification genetic testing for dysferlinopathy with extensive clinical data in a cohort of patients with dysferlinopathy. We aimed to assess whether the existence of specific mutations in the Chinese population provides a detailed description of clinical features, estimate the factors influencing intra-familial variability, and obtain new insights into phenotype-genotype correlations.

The study retrospectively observed 28 consecutive patients and their 27 relatives from 23 families between July 2014 and February 2019 in our hospital. Serum creatine kinase activity, electromyography, muscle biopsy, and muscle magnetic resonance imaging (MRI) were evaluated in the majority of patients. Fatty infiltration of the thigh and lower leg muscles was quantified by increased signal intensity as previously reported.^[2] Targeted NGS was performed using an inherited neuromuscular disease (NMD) panel (Agilent Technologies, Santa Clara, CA, USA) of 420 known inherited NMD associated genes. The mutations screened by NGS were further confirmed by Sanger sequencing. All novel variants were subsequently interpreted according to the American College of Medical Genetics and Genomics standards and guidelines. All procedures performed in studies involving human participants were in accordance with the ethical standards of the

institutional committee and/or national research committee (The First Affiliated Hospital of Fujian Medical University, No. FYYY2006-01-19-01) and with the 1964 Declaration of Helsinki and its later amendments or comparable ethical standards. Informed consent was obtained from all individual participants included in the study.

Among the 23 families, we identified 26 different mutations distributed over the whole coding-sequence of the *DYSF* gene [Figure 1A], of which 13 mutations were novel, including ten pathogenic and three likely pathogenic mutations [Supplementary Table 1, <http://links.lww.com/CM9/A446>]. The cosegregation analysis in eight of ten families with novel mutations supported the pathogenicity. Notably, the c.1667T>C mutation was found in five unrelated families, and was present in nine alleles (19.6%). Haplotype analyses suggested that c.1667T>C was a possible founder mutation [Supplementary Figure 1, <http://links.lww.com/CM9/A446>]. Both the c.797-798delTT and c.836A>T mutations were present in four alleles. Notably, the c.1667T>C and c.836A>T mutations have only been described in the Chinese population, while the c.1667T>C mutation was relatively more frequent in our series than in a previous report.^[3]

A total of 11 patients presented with MM, 13 patients with LGMD2B, and four patients showed a PD phenotype [Supplementary Table 2, <http://links.lww.com/CM9/A446>]. Fifteen out of 28 patients had only lower limb involvement, and their upper limbs were not clinically affected at the physical examination, which was observed in MM patients (8/11) more frequently than in LGMD2B patients (3/13). Initial symptoms and signs at examination are summarized in Supplementary Table 3, <http://links.lww.com/CM9/A446>. The mean age of patients with initial symptoms was 22.0 ± 7.2 years (range 11–42 years). MM patients had a mean age of 17.9 ± 7.2 years, while the

Access this article online

Quick Response Code:



Website:

www.cmj.org

DOI:

10.1097/CM9.0000000000001343

Correspondence to: Dr. Feng Lin, Department of Neurology and Institute of Neurology, The First Affiliated Hospital of Fujian Medical University, 20 Cha Zhong Road, Fuzhou, Fujian 350005, China
E-Mail: fenglin0621@126.com

Copyright © 2021 The Chinese Medical Association, produced by Wolters Kluwer, Inc. under the CC-BY-NC-ND license. This is an open access article distributed under the terms of the Creative Commons Attribution-Non Commercial-No Derivatives License 4.0 (CCBY-NC-ND), where it is permissible to download and share the work provided it is properly cited. The work cannot be changed in any way or used commercially without permission from the journal.

Chinese Medical Journal 2021;134(5)

Received: 30-09-2020 Edited by: Jing Ni

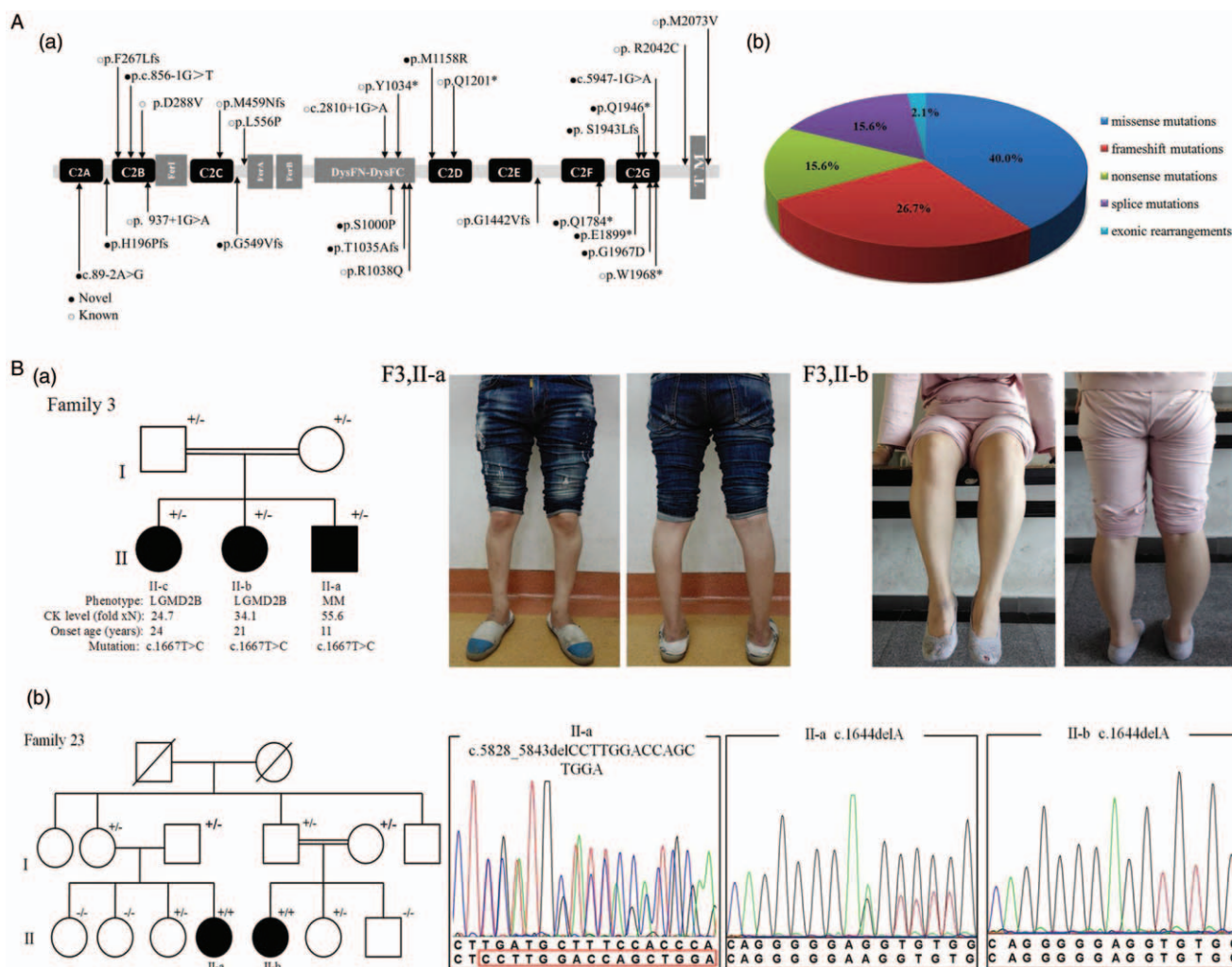


Figure 1: (A) (a) Distribution of *DYSF* mutations discovered in the cohort of our study. The *DysF* protein consists of various functional domains, including seven different C2 domains (C2A-C2G), three Fer domains (Fer1, FerA, and FerB), and two *DysF* domains. ○ denotes the variants that have been previously reported and ● denotes novel variants described in this study. (b) Relative frequency of *DYSF* gene mutations. (B) Intra-familial variability was observed in families 3 and 23. (a) In family 3, the proband (II-a) with the homozygous c.1667T>C mutation presented with the MM phenotype, while her sisters with the same mutation presented with the LGMD2B phenotype. The proband (II-a) showed severe atrophy of the posterior compartment of the leg; However, the lower leg of her affected sister (II-b) had a normal appearance. (b) In family 23, the patient (II-b) carrying the novel frameshift mutation c.1644delA had the MM phenotype, while another patient (II-a) carrying compound heterozygous mutations c.1644delA and c.5828_5843delCCTTGGACCAGCTGGA presented with a PD phenotype. *DysF*: Dysferlin; LGMD2B: Limb-girdle muscular dystrophy; MM: Miyoshi myopathy; PD: Proximo-distal.

mean age of LGMD2B patients was significantly higher, 25.0 ± 8.1 years ($P < 0.05$). The mean age was 27.5 ± 9.5 years in the group with the c.1667T>C (p.L556P) mutation and 19.6 ± 4.6 years in the group without the c.1667T>C (p.L556P) mutation. The difference between the group with the c.1667T>C (p.L556P) mutation and the group without the c.1667T>C (p.L556P) mutation was significant ($P < 0.05$).

Remarkably phenotypic variability among family members was observed in two families [Figure 1B]. In family 3, patient II-a presented with an MM phenotype and onset with distal lower limb weakness and developed proximal lower limb weakness with the progression of the disease, with no upper limb involvement after 3 years of follow-up. However, his affected sisters II-b showed LGMD2B, complained of difficulty in running at onset, and demonstrated mild proximal weakness of the lower limb in neuromuscular examination. Two affected members

had distinct phenotypes in different branches of family 23 (F23). The patient (F23, II-a) showed the PD phenotype and carried compound heterozygous mutations c.1644delA and c.5828_5843delCCTTGGACCAGCTGGA. The cosegregation analysis revealed that the mother of one patient carried heterozygous c.1644delA and her father carried another mutation. However, the patient (F23, II-b) presented with the MM phenotype and carried the homozygous mutation c.1644delA.

Muscle MRI of the lower limbs was detected in 22 patients. At the thigh level, posterior thigh muscle groups (semi-membranosus, semitendinosus, and biceps femoris), the vastus lateralis, and the adductor magnus were commonly affected, whereas rectus femoris, sartorius, and gracilis were only involved in the advanced stage. The mean scores for fat infiltration of the anterior, medial, and posterior thigh muscle groups were 1.0 (interquartile range [IQR]: 2.3), 1.0 (IQR: 3.0), and 2.0 (IQR: 2.0), respectively. For

the lower leg muscles, the posterior compartment (soleus, gastrocnemius medialis, and gastrocnemius lateralis) commonly and severely infiltrated muscles in >80% of patients. The mean scores for fat infiltration of the anterior compartment, central compartment, and posterior compartment were 1.0 (IQR: 3.0), 1.0 (IQR: 2.0), and 3.0 (IQR: 1.0), respectively. The fat infiltration of posterior compartment involvement was significantly higher than that of either the anterior or central compartment [Supplementary Figure 2, <http://links.lww.com/CM9/A446>].

In this study, we found 13 novel mutations in ten families and identified a high frequency of novel mutations (50%). Although the novel mutations found in this study were spread out along the entire *DYSF* gene, a total of 11 novel mutations were located in C2 domains or two DysF domains and more frequently in the C2G domain. C2 domains are considered as highly conserved regions and have Ca²⁺ and phospholipid binding motifs, and Ca²⁺ binding can facilitate domain interactions with membrane repair proteins.^[4] In addition, some mutations were a residue of inner DysF domains and disrupted the formation of arginine/tryptophan (R/W) stacks, likely resulting in unfolded or unstable domains, finally leading to DysF protein degradation.

Notably, both the c.1667T>C (p.L556P) and c.836A>T mutations have been reported only in Chinese patients, and the c.1667T>C (p.L556P) mutation was the most frequent in our cohort. In contrast, four common mutations in the Japanese population were not present in our study.^[5] These findings strongly supported the specificity of *DYSF* mutations, which were associated with ethnic background. Moreover, haplotype analysis revealed that the mutation c.1667T>C might be a founder mutation in southern China. In addition, in a previous study,^[3] the recurrent mutation c.1375dupA was considered a possible founder mutation in northern China, but only one patient carried this heterogeneous mutation in this study, which suggested a difference between the distribution and frequency of the *DYSF* mutation in southern and northern China.

Differences in clinical phenotypes and the course of disease progression were observed in the siblings of our families, confirming the significant intra-familial variability in dysferlinopathy. In addition, different novel mutations were detected among affected members in branches of the same family (F23) and were first documented in our cohort. This finding is a rare condition that may contribute to the different phenotypes of two affected members in the family (F23). These findings clearly indicated that the clinical phenotypes were associated with not only the *DYSF* gene but also additional factors, such as environmental factors and modifier gene(s).

In conclusion, we identified a high proportion of novel mutations and displayed a broad spectrum of the *DYSF*

gene. The mutations c.1667T>C (p.L556P) and c.836A>T appear to be unique in the Chinese population, suggesting that the distribution of *DYSF* mutations is associated with ethnic background. Additionally, the prevalent c.1667T>C mutation with later onset expands the genotype-phenotype correlation. Notably, *DYSF* mutations within families have distinct phenotypes, which suggests that the clinical phenotype is determined not only by *DYSF* mutations but also likely through a complex interplay of environmental, epigenetic, and genetic factors.

Declaration of patient consent

The authors certify that they have obtained all appropriate patient consent forms. In the form, the patients have given their consent for their images and other clinical information to be reported in the article. The patients guardians understand that their names and initials will not be published and due efforts will be made to conceal the identity of the patient, although anonymity cannot be guaranteed.

Funding

This study was supported by grants from the National Natural Science Foundation of China (No. 81701242), the Joint Fund for Program of Science Innovation of Fujian Province, China (No. 2018Y9079), and the National Natural Science Foundation of Fujian Province, China (No. 2019J05079).

Conflicts of interest

None.

References

1. Satish VK, Bhagyadhan AP, Jamshed AL. Making sense of the clinical spectrum of limb girdle muscular dystrophies. *Pract Neurol* 2018;18:201–210. doi: 10.1136/practneurol-2017-001799.
2. Lin HT, Liu X, Zhang W, Liu J, Zuo YH, Xiao JX, et al. Muscle magnetic resonance imaging in patients with various clinical subtypes of LMNA-related muscular dystrophy. *Chin Med J* 2018;131:1472–1479. doi: 10.4103/0366-6999.233957.
3. Jin SQ, Yu M, Zhang W, Lyu H, Yuan Y, Wang ZX. Dysferlin gene mutation spectrum in a large cohort of Chinese Patients with dysferlinopathy. *Chin Med J* 2016;129:2287–2293. doi: 10.4103/0366-6999.190671.
4. Julia H, Kristina B, Stefan W, Cristina M, Funsho EF, Lavanya MI, et al. Dysferlin links excitation-contraction coupling to structure and maintenance of the cardiac transverse-axial tubule system. *Europace* 2020;22:1119–1131. doi: 10.1093/europace/euaa093.
5. Izumi R, Takahashi T, Suzuki N, Niihori T, Ono H, Nakamura N, et al. The genetic profile of dysferlinopathy in a cohort of 209 cases: genotype-phenotype relationship and a hotspot on the inner DysF domain. *Hum Mutat* 2020;41:1540–1554. doi: 10.1002/humu.24036.

How to cite this article: Guo QF, Ye ZX, Qiu LL, Lin X, Lai JH, Lin MT, Wang ZQ, Wang N, Lin F. Dysferlinopathy in a cohort of Chinese patients: clinical features, mutation spectrum, and imaging findings. *Chin Med J* 2021;134:622–624. doi: 10.1097/CM9.0000000000001343