

## Original Article

# Slack brain in meningioma surgery through lateral supraorbital approach

Rossana Romani, Marja Silvasti-Lundell<sup>1</sup>, Aki Laakso, Hanna Tuominen<sup>1</sup>, Juha Hernesniemi, Tomi Niemi<sup>1</sup>

Departments of Neurosurgery and <sup>1</sup>Anesthesiology and Intensive Care Medicine, Helsinki University Central Hospital, Helsinki, Finland

E-mail: \*Rossana Romani - [rossana.romani@hus.fi](mailto:rossana.romani@hus.fi); Marja Silvasti-Lundell - [marja.silvasti-lundell@hus.fi](mailto:marja.silvasti-lundell@hus.fi); Aki Laakso - [aki.laakso@hus.fi](mailto:aki.laakso@hus.fi); Hanna Tuominen - [hanna.tuominen@hus.fi](mailto:hanna.tuominen@hus.fi); Juha Hernesniemi - [juha.hernesniemi@hus.fi](mailto:juha.hernesniemi@hus.fi); Tomi Niemi - [tomi.niemi@hus.fi](mailto:tomi.niemi@hus.fi)

\*Corresponding author

Received: 13 July 11

Accepted: 23 September 11

Published: 19 November 11

**This article may be cited as:**

Romani R, Silvasti-Lundell M, Laakso A, Tuominen H, Hernesniemi J, Niemi T. Slack brain in meningioma surgery through lateral supraorbital approach. *Surg Neurol Int* 2011;2:167.

Available FREE in open access from: <http://www.surgicalneurologyint.com/text.asp?2011/2/1/167/90029>

Copyright: © 2011 Romani R. This is an open-access article distributed under the terms of the Creative Commons Attribution License, which permits unrestricted use, distribution, and reproduction in any medium, provided the original author and source are credited.

## Abstract

**Background:** Surgery of skull base meningiomas by the lateral supraorbital (LSO) approach requires relaxed brain. Therefore, we assessed combined effects of the elements of neuroanesthesia on neurosurgical conditions during craniotomy.

**Methods:** The anesthesiological and surgical charts of 66 olfactory groove, 73 anterior clinoidal, and 52 tuberculum sellae meningioma patients operated on by the senior author (J.H.) at the Department of Neurosurgery of Helsinki University Central Hospital, Helsinki, Finland, between September 1997 and August 2010, were retrospectively analyzed.

**Results:** One-hundred fifty-four (82%) patients had good surgical conditions, and this was achieved by (1) elevating the head 20 cm above the cardiac level in all patients with only slightly lateral turn or neck flexion, (2) administering mannitol preoperatively in medium or large meningiomas ( $n = 60$ ), (3) maintaining anesthesia with propofol infusion ( $n = 46$ ) or volatile anesthetics ( $n = 107$ ) also in patients with large tumors ( $n = 37$ ), and (4) controlling intraoperative hemodynamics. Brain relaxation was satisfactory in 18 (10%) and poor in 15 (8%) patients. The median intraoperative blood loss was 200 (range, 0-2000) ml. Only 9% of patients received red blood cell transfusion. The median time to extubation was 18 (range, 8-105) min after surgery. Extubation time correlated with the patients' preoperative clinical status and the size of tumor but not with the modality of anesthesia.

**Conclusions:** Slack brain during the LSO approach is achieved by correct patient positioning, preoperative mannitol, either by propofol or in small tumors inhaled anesthetics, and optimizing cerebral perfusion pressure. Under these circumstances, intraoperative brain swelling is prevented, bleeding is minimal, and no blood transfusions are needed.

**Key Words:** Anesthesia, bleeding, lateral supraorbital approach, position, slack brain

Access this article  
online

**Website:**

[www.surgicalneurologyint.com](http://www.surgicalneurologyint.com)

**DOI:**

10.4103/2152-7806.90029

**Quick Response Code:**

## INTRODUCTION

A slack brain is necessary when treating vascular or neoplastic lesions through the small lateral supraorbital approach (LSO). This approach, used by the senior author (J.H.) for the past 25 years, enables surgery of vascular or neoplastic lesions of the anterior skull base.<sup>[2-7,15,16]</sup> However, without optimal neuroanesthesiological care, the neurosurgeon does not reach the operative site and the risk of extensive brain manipulation is increased. In addition to providing good neurosurgical conditions, the neuroanesthesiologist maintains optimal cerebral perfusion pressure (CPP) and oxygen delivery to the brain. To guarantee optimal CPP, the association between cerebral blood flow (CBF) and mean arterial pressure as well as concepts of cerebral carbon dioxide (CO<sub>2</sub>) reactivity and metabolic coupling should be kept in mind perioperatively. Furthermore, neuroanesthesia requires knowledge of the effects of various drugs on aforementioned issues.

The patient positioning, selection of optimal method of anesthesia, and osmotherapy given well in advance before the opening of dura are essential in brain tumor patients undergoing craniotomy. In neurosurgical procedures, volatile anesthetics or propofol are frequently used to maintain general anesthesia.<sup>[1]</sup> Volatile anesthetics can be safely used if there are no signs of increased intracranial pressure (ICP). Volatile agents reduce the cerebral metabolic rate, but they also have a direct vasodilatory effect on cerebral arteries. However, hyperventilation counteracts this arterial vasodilatation. Propofol also decreases cerebral metabolism, but in contrast to volatile anesthetics, propofol is a cerebral artery vasoconstrictor.

In the present study we reviewed the principles of neuroanesthesia when treating 191 anterior skull base meningiomas through the small LSO approach. The aim was to identify the clinically relevant perioperative factors providing good surgical conditions when treating these lesions through this approach. The senior author (J.H.) operated on all patients at the Department of Neurosurgery of Helsinki University Central Hospital, Helsinki, Finland, between September 1997 and August 2010.

## MATERIALS AND METHODS

### Patient selection and radiological findings

Between September 1997 and August 2010, a total of 191 patients underwent anterior skull base meningioma removal through the LSO approach by the senior author (J.H.) at the Department of Neurosurgery, Helsinki University Central Hospital, Helsinki, Finland. Patients operated on by other neurosurgeons were excluded. The patients had 66 olfactory groove meningiomas (OGMs), 73 anterior clinoidal meningiomas (ACMs),

and 52 tuberculum sellae meningiomas (TSMs). The demographic data of these patients are listed in Table 1. Preoperative clinical condition of the patients was assessed by the Karnofsky Performance Scale.<sup>[8]</sup> Magnetic resonance imaging (MRI) findings were evaluated for brain edema, brain shift, and sellar infiltration [Table 1]. The size of OGMs, ACMs, and TSMs was classified as small size when the maximum diameter was less than 2 cm, medium size between 2 and 4 cm, and large size when the diameter was more than 4 cm [Table 1].

### Anesthesiological records

Data collection included duration of anesthesia and surgery, anesthetic agents and their doses, total amount of administered vasoactive agents (phenylephrine, ephedrine, dopamine, or atropine), the total amount of administered crystalloids (Ringer's acetate), colloids [hydroxyethyl starch solution, (HES) or albumin], mannitol, red blood cell concentrates, fresh frozen plasma (FFP), and platelet concentrates. Heart rate and noninvasive blood pressure were registered before anesthesia. Intraoperatively invasive arterial blood pressures (arterial transducer set zero at the level of foramen of Monro) were registered at 5-min intervals for 40 min and thereafter at 10-min intervals until the end of surgery. Hypertension (systolic arterial pressure > 160 mmHg) was registered during the immediate postoperative phase. The evaluation of the surgical conditions during craniotomy was based on surgical charts written by the senior author (J.H.) who always mentions whether there is a slack brain (classified as good neurosurgical conditions), or if opening of the basal cisterns is needed to achieve a slack brain (classified as satisfactory), or if there is brain swelling (classified as poor neurosurgical conditions). The patients' preoperative medical comorbidities such as hypertension and the use of any medication were registered.

### Statistics

The statistical analysis was performed using SPSS 17.0 software (SPSS Inc., Chicago, IL, USA). Groups were

**Table 1: Demographic and radiological data of 191 patients**

Parameter	Measured value
Men (number of patients = N)	57
Women (N)	134
Age (years); mean (range)	59 (range, 14–87)
Karnofsky score; mean (range)	82 (range, 40–100)
Edema (N)	86
Brain shift (N)	79
Sellar infiltration (N)	58
Small size (<2 cm) (N)	33
Medium size (2–4 cm) (N)	83
Large size (>4 cm) (N)	75
Duration of surgery (min); median (range)	115 (35–442)

compared using Mann–Whitney U test, Kruskal–Wallis test, or Pearson’s  $\chi^2$  test. *P* values less than 0.05 were considered significant. Univariate and multivariate odds ratios with 95% confidence intervals were estimated using unconditional logistic regression for determining factors predicting good neurosurgical conditions and extubation time. The tested variables included age, preoperative Karnofsky score, peritumoral edema, size of meningiomas, and method of anesthesia. The maximum likelihood stepwise forward and backward elimination procedures were used with the selection of variables based on the magnitude of their probability values ( $<0.1$ ). A two-tailed probability value less than 0.05 was considered significant.

## RESULTS

The surgical data of 191 patients were included, whereas complete anesthesiological records of 187 patients were available for data analyses. Anesthesiological charts were not available for 2 patients with OGMs and 2 patients with ACMs.

### Brain relaxation and anesthesia

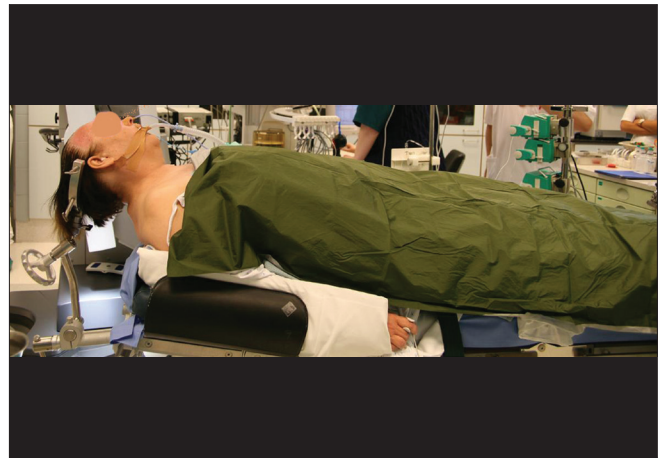Brain relaxation was good in 154 (82%) patients. In 18 patients the brain relaxation was classified as satisfactory (10%) and the optimal slack brain was achieved by opening the basal cisterns during the surgery. In 15 (8%) patients the brain was swelling intraoperatively. Thirteen of these patients had large tumors ( $P < 0.001$ ). Their median Karnofsky score was 80 (range, 50–90) and 14 of them had peritumoral edema. Nine patients out of 15 with brain swelling had either sevoflurane ( $n = 6$ ) or isoflurane ( $n = 3$ ) anesthesia. In multivariate analysis the swelling of the brain was associated with medium-to-large-sized meningiomas, peritumoral edema, volatile or combined anesthesia, and poor preoperative clinical condition (Karnofsky score  $< 70$ ) ( $P < 0.001$ ).

### Patient positioning

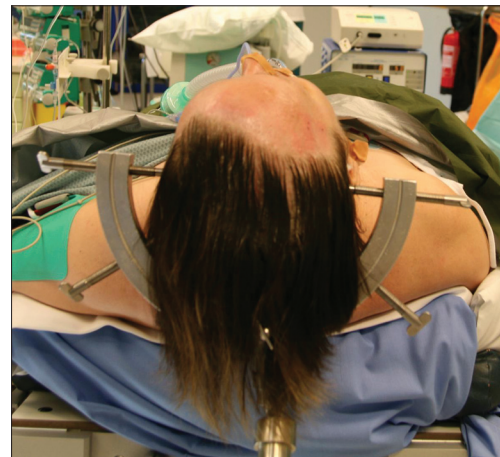The patients were in the supine position for the LSO approach [Figure 1]. The head fixed to the head frame is (a) elevated around 20 cm or more above the cardiac level and (b) rotated 20–30° toward the contralateral side of the tumor [Figure 2]; the neck is slightly flexed to obtain better view toward the anterior part of the anterior fossa, enabling optimal venous return. It is our practice also to adjust the position of the fixed head and body during the operation as needed,<sup>[4]</sup> but the frequency of this maneuver could not be assessed in retrospective. No local anesthetics were infiltrated for pins of the Sugita frame. A bolus of remifentanyl was given to prevent hypertension.<sup>[14]</sup>

### Induction of anesthesia

The method of anesthesia is summarized in Table 2. All the patients were premedicated by oral diazepam



**Figure 1:** Intraoperative picture of a patient position who underwent an lateral supraorbital approach for tuberculom sellae meningiomas surgery



**Figure 2:** The slight rotation of the head in a right lateral supraorbital approach

**Table 2: Method of anesthesia**

Method	Number of patients (%)
Intravenous anesthesia	
Propofol infusion	46 (25)
Volatile agents	
Sevoflurane	74 (40)
Isoflurane	33 (17)
Combined anesthesia	
Sevoflurane/Isoflurane + propofol infusion	34 (18)

5–15 mg 1 h before surgery. Anesthesia was induced with thiopental (median dose of 377 mg; range, 300–500 mg) in 186 patients (99%). An 80-year-old patient with congestive heart disease and a medium-sized TSM received etomidate (14 mg) at the induction of anesthesia. The mean (range) total intraoperative amount

of fentanyl was 0.56 (range, 0.15-3.0) mg, mainly given as one bolus at the induction of anesthesia.

### Maintenance of anesthesia and tumor size

Anesthesia was maintained by propofol infusion ( $n = 46$ , 25%), sevoflurane ( $n = 74$ , 40%) or isoflurane ( $n = 33$ , 17%), or a combination of propofol infusion and sevoflurane/isoflurane ( $n = 34$ , 18%) [Table 2]. Nitrous oxide ( $N_2O$ ) was given in 140 (75%) patients. Most often  $N_2O$  was combined with sevoflurane or isoflurane ( $n = 95$ , 51%).

The meningioma size was medium or large in 21 patients receiving propofol anesthesia. Only 4 patients anesthetized with propofol had a small meningioma. Twenty-four patients anesthetized with propofol presented with peritumoral edema.

Thirty-seven patients with large meningioma, 45 with medium and 25 with small meningioma received either sevoflurane or isoflurane anesthesia and 40 of them (10 medium and 30 large-sized meningiomas) presented with peritumoral edema. In univariate analysis there was no correlation between the size of tumor and the method of anesthesia.

Remifentanyl infusion was administered to 166 (89%) patients. Remifentanyl infusion was combined with sevoflurane/isoflurane in 91 (49%) patients, or with propofol in 41 (22%) patients.

Neuromuscular block was achieved by nondepolarizing muscle relaxants (rocuronium or vecuronium) in all the study patients.

### Ventilation and blood gas analyses

Mean (SD) arterial  $CO_2$  tension ( $PaCO_2$ ) ( $n = 44$ ) and oxygen tension ( $PaO_2$ ) ( $n = 46$ ) were 4.6 ( $\pm 0.5$ ) kPa and 23.3 ( $\pm 10.7$ ) kPa in patients having propofol anesthesia ( $n = 46$ ;  $n = 48$  blood gas analyses), respectively. The corresponding findings of  $PaCO_2$  ( $n = 105$ ) and  $PaO_2$  ( $n = 107$ ) were 4.6 ( $\pm 0.5$ ) kPa and 23.6 ( $\pm 9.0$ ) kPa in patients having either sevoflurane or isoflurane anesthesia.  $PaCO_2$  and  $PaO_2$  in the 15 patients with inhaled anesthetics and intraoperative brain swelling were 4.4 ( $\pm 0.5$ ) and 28.4 ( $\pm 17.7$ ), respectively. The acid-base equilibrium, i.e., pH and base excess (BE), remained within normal laboratory reference range in all the analyses ( $n = 175$ ). The median (25th/75th percentiles) body temperature was 36.2°C (35.9/36.7).

### Intravenous fluids and osmotic agents

The administered intravenous fluids are listed in Table 3. The median (25<sup>th</sup>/75<sup>th</sup> percentiles) intraoperative cumulative amount of Ringer's acetate was 2000 (1000/2000) ml. In nine patients the exact amount of Ringer's acetate could not be identified because of the short duration of the surgery. The number of patients who received colloid infusion was 49 ( $n = 48$  HES,  $n =$

1 albumin).

The administration of 15% mannitol according to the size of the meningioma is shown in Table 4. The use and the amount of mannitol were significantly associated with the size of meningioma and the preoperative cerebral edema ( $P < 0.05$ ). However, in two patients with small meningioma, without peritumoral edema, 500 ml of mannitol was administered before surgery. These two patients were operated on before the year 2000 when mannitol was administered routinely. Hypertonic saline was not given to any patient.

### Intraoperative bleeding and blood transfusion

The median (range) cumulative intraoperative blood loss was 200 (range, 0-2000) ml. Blood loss was significantly associated with the tumor size ( $P < 0.05$ ). Two patients had blood loss above 1500 ml. One of them had intraoperative blood loss of 1800 ml because of accidental laceration of the internal carotid artery (ICA) during the removal of a small ACM with an intraorbital and intracavernous component. The laceration was repaired with microsuture.<sup>[15]</sup> Intraoperative blood loss was 2000 ml in another patient with a very large vascularized (maximum diameter  $> 8$  cm) OGM meningioma. The red blood cell transfusions were administered in 17 (9%) patients [Table 5]. One hundred seventy (91%) patients did not require red blood cell transfusion. FFP

**Table 3: Intraoperative fluids, fresh frozen plasma and platelet concentrate**

		Number of patients
Ringer's acetate (ml); median, (range)	2000 (1000–2000)	183
HES (ml); median (range)	120 (500–1500)	48
FFP (unit)	2	1
	4	1
Platelet concentrate (unit)	4	2
Albumin	1	

**Table 4: Size of tumor and amount of mannitol administered**

Mannitol (ml)	Small	Medium	Large	Total number of patients
100	0	1	3	4
200	0	1	1	2
250	0	0	1	1
270	0	0	1	1
350	0	0	1	1
400	0	2	2	4
500	2	12	35	49
Total number of patients	2	16	44	62



and platelet concentrate were given to two patients each [Table 3].

### Hemodynamics, vasoactive, and antiepileptic drugs

The systolic and diastolic arterial pressures and heart rate are shown in Figure 3. The mean systolic blood pressures ranged between 95 and 110 mmHg during surgery. Heart rate remained stable. Extreme hemodynamical changes were not observed. The hemodynamical data classified according to the size and type of the tumor were comparable. The mean preoperative systolic and diastolic blood pressures were 125 and 70 mmHg, respectively. Majority of the patients ( $n = 157$ , 84%) had systolic blood pressure less than 160 mmHg until 6 h after the end of the operation. Intraoperative phenylephrine infusion was given in 60 (32%) patients and dopamine in 4 patients. The use of vasoactive agents was not related to the type or size of the tumor.

Antiepileptic drugs were given to 104 patients perioperatively. The drugs were fosphenytoin (95 cases),

carbamazepine (6 cases), phenytoin (2 cases), and lorazepam (1 case). The administration of antiepileptic drugs was not related to the location of tumors but to the size of meningiomas ( $P < 0.05$ ).

### Duration of surgery and extubation time

The median (range) duration of surgery, skin to skin, was 115 (35–442) min [Table 1]. For surgery of small tumors, the median (range) time was 74 (35–235) min. The patient with a small ACM underwent a long operation (235 min) since ICA was accidentally ruptured intraoperatively. For medium-sized meningiomas the median (range) duration of surgery was 95 (50–190) min, and for large tumors the time was 167 (73–442) min. The duration of surgery for a very large TSM meningioma of hard consistency was 442 min.

Most of the patients ( $n = 157/84%$ ) were extubated on the day of the surgery. The median time to extubation after surgery was 18 (range, 8–105) min. Fifty-three (28%) of the patients were extubated within 10 min after the completion of surgery (14 small-, 33 medium-, and 6 large-sized meningiomas). Forty-five (24%) patients were extubated within 30 min after surgery (13 small, 24 medium-, and 8 large-sized meningiomas). Fifty-nine (32%) patients were extubated either within 1 h (10 cases), 5 h (36 cases), or later than 5 h after the completion of surgery but the same day of the surgery (13 cases).

Twenty-nine patients were extubated during the following days after surgery: on the first postoperative day (21 cases), on the second postoperative day (3 cases), on the third postoperative day (1 case), on the fourth postoperative day (2 cases), or on the fifth and sixth postoperative days (1 case each). In univariate and multivariate analyses, preoperative clinical status (Karnofsky score  $< 70$ ) ( $P < 0.001$ ), size and location (OGM) of the tumor ( $P < 0.001$ ), peritumoral edema ( $P < 0.001$ ), and brain swelling at surgery ( $P < 0.05$ ) were predicting factors for prolonged extubation time after surgery (days after surgery).

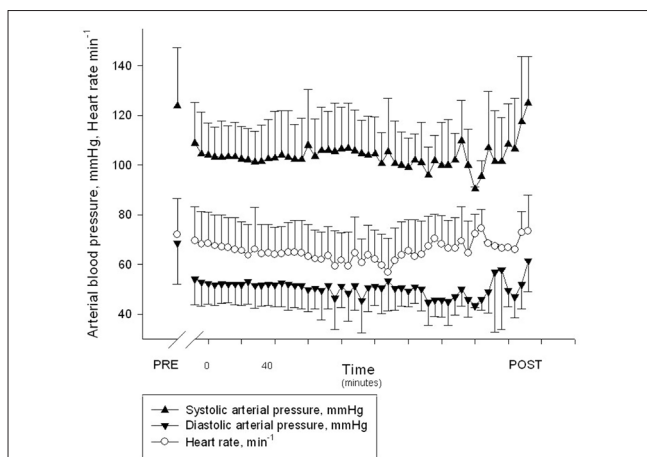
An immediate postoperative neuroradiological control was performed in 125 patients (117 CT scan and 8 MRI). Two patients (1 OGM and 1 ACM) had a postoperative hematoma requiring surgical evacuation. No other patients who underwent immediate postoperative radiological control presented signs of increased ICP or an increase of preoperative edema. The median (range) of early Karnofsky score was 80 (30–100).

## DISCUSSION

We studied the concept of neuroanesthesia enabling successful neurosurgery of 187 meningioma patients with the LSO approach and found that the combined effect of optimal patient positioning, method of anesthesia,

**Table 5: Size of tumor and red blood cells**

Red blood cells unit (ml)	Small	Medium	Large	Total number of patients
0	29	80	61	170
100	1	1	0	2
200	1	0	1	2
250	0	1	0	1
400	0	0	1	1
500	0	0	6	6
600	1	0	0	1
750	0	0	2	2
800	0	0	1	1
1000	0	0	1	1



**Figure 3: Pre-, intra-, and postoperative systolic and diastolic arterial pressures (mean) and heart rate**

osmotherapy, and adequate CPP creates good conditions for craniotomy. The neurosurgical operative conditions were good in 154 (82%) of the patients, satisfactory in 18 (10%) and poor in 15 (8%) patients during craniotomy. Two patients had unexceptionally high intraoperative blood loss due to an accidental ICA lesion or a very vascularized tumor. Otherwise the blood loss was minimal and the frequency of red blood cell transfusions was low. These findings confirm that the LSO approach with the bone flap of about 4 cm in diameter is an atraumatic approach.<sup>[3,4,15,16]</sup>

### Patient position

A 30° head elevation decreases ICP in patients undergoing craniotomy. Head and neck position needs to be adjusted as neutral as possible to enable free venous return during craniotomy. A 100% increase in ICP is possible when head is tilted extremely to the right or left with simultaneous neck flexion.<sup>[12]</sup> Head elevation does not counteract this elevation in ICP. In all the study patients, the senior author (J.H.) used a round strong pillow under the shoulders of the patient and adjusted the position of the head so that the operative area was usually 20 cm above the cardiac level. At the same time extreme tilting of the head or flexing the neck is carefully avoided in our practice.

### Anesthetic agent selection

The second option to maximize brain relaxation during craniotomy is to manipulate intracranial arterial blood volume by optimizing CBF and CPP. CBF is regulated by physiological pressure-flow autoregulation, ventilation (CO<sub>2</sub> reactivity), and the method of anesthesia.

Since the function of cerebral flow-pressure autoregulation cannot be assessed during routine anesthesia for tumor patients, the possibility of the abnormal relationship between CBF and CPP is highly relevant. Thus, in the patients of the present study, the CPP was optimized according to the systemic blood pressure measurement with the arterial transducer set zero at the level of foramen of Monro. The safe lower limit of CPP was determined individually by assessing the overall hemodynamic profile. In the present study, the systolic blood pressure varied on average between 95 and 110 mmHg providing CPP of above 60 mmHg. The targeted CPP was achieved by the use of relatively small doses of vasoactive drugs, without excessive intravenous fluid administration. During removal of a brain tumor, it is also essential to avoid peak increases in systolic arterial blood pressure to avoid bleeding. The clinical assessment of CPP was optimal in all the patients since the blood loss was minimal intraoperatively and none of the patients had ischemic brain lesions postoperatively.

Hemodynamical stability is achieved by an adequate depth of anesthesia and analgesia during craniotomy. The effect of the initial bolus of fentanyl (5–7 µg/kg),

following infusion of remifentanyl, blunts the sympathetic activity. In the present study, inhaled anesthetics were used in patients with all tumor sizes. Our observations confirm the results of previous studies showing that inhaled anesthetics or propofol are suitable in patients undergoing resection of a brain tumor.<sup>[9,17,18]</sup> Nevertheless, volatile anesthetics are contraindicated in patients with high ICP. In craniotomy patients with normal ICP, the patient has to be slightly hyperventilated to counteract the vasodilatory effect of inhaled anesthetics on cerebral arteries. Propofol anesthesia was given in 25% of the study patients, most often in patients with a medium or large tumor supporting the fact of the capacity of propofol to decrease ICP. One could speculate that the use of propofol instead of inhaled anesthetics, or more profound hyperventilation, could have prevented brain swelling in some of those patients having poor surgical conditions. In fact, the comparable PaCO<sub>2</sub> tension in patients with inhaled anesthetics (mean, PaCO<sub>2</sub>: 4.6) or propofol infusion (mean, PaCO<sub>2</sub>: 4.6) indicates that ventilation could have been increased in patients with volatile anesthetics, and slightly decreased in patients with propofol infusion to further optimize cerebral blood volume.

### Osmotic agent

The administration of mannitol before opening of the dura also optimized brain relaxation regardless of the method of anesthesia. It is notable that patients who received mannitol had a large tumor or brain edema. The routine use of mannitol is not indicated since mannitol may induce unfavorable side effects, such as disturbances in electrolyte concentrations, renal dysfunction, or coagulation disorders.<sup>[10,11]</sup>

### Blood loss

Careful microsurgical technique, optimal brain relaxation, and cerebral hemodynamics all minimize blood loss during surgery of brain tumors. Furthermore, the duration of surgery was short, even in patients with a large tumor. Indeed, the intraoperative blood loss was on average only 200 ml and very few of the patients received a red blood cell transfusion. The blood loss in the present study is much less (80%) than that previously reported.<sup>[13]</sup> The uneventful intraoperative phase is also reflected in the immediate postoperative period. Most of the patients were extubated on the first day and the median early Karnofsky score was 80.

## CONCLUSIONS

The LSO approach requires good operative site conditions and brain relaxation. This is achieved by a correct patient positioning and optimal neuroanesthesia. In small- or medium-sized meningiomas, both intravenous and volatile anesthesia can result in a slack brain. In large meningiomas, we prefer propofol anesthesia and

mannitol. Early devascularization of the tumor and good control of intraoperative hemodynamics reduce the intraoperative bleeding.

## REFERENCES

1. Burnstein R. Anesthesia for Supratentorial Surgery. Gupta AK, Gelb AW, editors. Essentials of Neuroanesthesia and Neurointensive Care. China: Saunders, Elsevier; 2008. p. 106-10.
2. Hernesniemi J. Mechanisms to improve treatment standards in neurosurgery, cerebral aneurysm surgery as example. *Acta Neurochir Suppl* 2001;78:127-34.
3. Hernesniemi J, Romani R, Niemelä M. Skull base and aneurysm surgery. *Surg Neurol* 2009;71:30-1.
4. Hernesniemi J, Ishii K, Niemelä M, Smrcka M, Kivipelto L, Fujiki M, et al. Lateral supraorbital approach as an alternative to the classical pterional approach. *Acta Neurochir Suppl* 2005;94:17-21.
5. Hernesniemi J, Dashti R, Lehecka M, Niemelä M, Rinne J, Lehto H, et al. Microneurosurgical management of anterior communicating artery aneurysms. *Surg Neurol* 2008;70:8-28.
6. Hernesniemi J, Niemelä M, Karatas A, Kivipelto L, Ishii K, Rinne J, et al. Some collected principles of microneurosurgery: Simple and fast, while preserving normal anatomy: A review. *Surg Neurol* 2005;64:195-200.
7. Hernesniemi J, Niemelä M, Dashti R, Karatas A, Kivipelto L, Ishii K, et al. Principles of microneurosurgery for safe and fast surgery. *Surg Technol Int* 2006;15:305-10.
8. Karnofsky DA, Burchenal J. The clinical evaluation of chemotherapeutic Agents in Cancer. In: MacLeod CM, editor. Evaluation of Chemotherapeutic Agents. New York: Columbia University Press 1949. p. 191-205.
9. Lauta E, Abbinante C, Del Gaudio A, Aloj F, Fanelli M, deVivo P, et al. Emergence times are similar with sevoflurane and total intravenous anesthesia: Results of a multicenter RCT of patients scheduled for elective supratentorial craniotomy. *J Neurosurg Anesthesiol* 2010;22:110-8.
10. Lindroos AC, Niiya T, Randell T, Romani R, Hernesniemi J, Niemi T. Sitting position for removal of pineal region lesions: The Helsinki experience. *World Neurosurg* 2010;74:505-13.
11. Luostarinen T, Niiya T, Schramko A, Rosenberg P, Niemi T. Comparison of hypertonic saline and mannitol on whole blood coagulation *in vitro* assessed by thromboelastometry. *Neurocrit Care* 2011;14: 238-243.
12. Mavrocordatos P, Bissonnette B, Ravussin P. Effects of neck position and head elevation on intracranial pressure in anaesthetized neurosurgical patients: Preliminary results. *J Neurosurg Anesthesiol* 2000;12:10-4.
13. Palmer JD, Francis JL, Pickard JD, Iannotti F. The efficacy and safety of aprotinin for hemostasis during intracranial surgery. *J Neurosurg* 2003;98:1208-16.
14. Randell T, Niemelä M, Kyttä J, Tanskanen P, Määttänen M, Karatas A, et al. Principles of neuroanesthesia in aneurysmal subarachnoid hemorrhage: The Helsinki experience. *Surg Neurol* 2006;66:382-8; discussion 388.
15. Romani R, Lehecka M, Gaal E, Toninelli S, Celik Ö, Niemelä M, et al. Lateral supraorbital approach applied to olfactory groove meningiomas: Experience with 66 consecutive patients. *Neurosurgery* 2009;65:39-52; discussion 52-3.
16. Romani R, Laakso A, Kangasniemi M, Lehecka M, Hernesniemi J. Lateral supraorbital approach applied to anterior clinoidal meningiomas: Experience with 73 consecutive patients. *Neurosurgery* 2011;68:1632-47.
17. Talke P, Caldwell JE, Brown R, Dodson B, Howley J, Richardson CA. A comparison of three anesthetic techniques in patients undergoing craniotomy for supratentorial intracranial surgery. *Anesth Analg* 2002;95:430-5.
18. Tanskanen PE, Kyttä JV, Randell TT, Aantaa RE. Dexmedetomidine as an anaesthetic adjuvant in patients undergoing intracranial tumour surgery: A double-blind, randomized and placebo-controlled study. *Br J Anaesth* 2006;97:658-65.