

COVID-19-associated ischaemic stroke despite use of anticoagulation

Shyam Sharma ¹, Michael Wood,² Giosue Gulli³

¹The University of Edinburgh College of Medicine and Veterinary Medicine, Edinburgh, UK

²Respiratory Department, Ashford and Saint Peter's Hospitals NHS Trust, Chertsey, UK

³Stroke Unit, Ashford and Saint Peter's Hospitals NHS Trust, Chertsey, UK

Correspondence to

Shyam Sharma;
S.Sharma-28@sms.ed.ac.uk

Accepted 16 July 2021

SUMMARY

A 64-year-old female nurse was admitted to hospital following fever, cough, shortness of breath and low blood pressure. She tested positive for COVID-19 and was treated on a high-dependency unit and prescribed enoxaparin, a prophylactic anticoagulant. Eight days later, she suffered a left middle cerebral artery ischaemic stroke. Over the next 2 weeks, her condition fluctuated, eventually leading to her death. We report her case from clinical history to investigations and outcomes, and explore the potential link between coronavirus, the use of anticoagulation and ischaemic stroke.

BACKGROUND

COVID-19 has drastically altered medical management globally. The disease principally affects the respiratory system as well as other organs.¹ While the virus can also infiltrate the brain leading to encephalitis, emerging information also provides evidence of a causative relationship with ischaemic stroke.² The aetiological mechanism is likely due to an enhanced infection induced coagulopathy.

Although varying by population, ischaemic stroke accounts for roughly 80% of all strokes worldwide.³ In the UK, there are over 100 000 new stroke cases every year which cause 38 000 deaths, making it a leading cause of death and disability.⁴ COVID-19 has been associated with ischaemic stroke, especially in the Asian community, and it has been suggested that prophylactic anticoagulation would be a useful means of prevention.^{5 6}

As COVID-19 continues to infect a growing number of people around the world, there is a large potential for an increase in affected individuals suffering from stroke. We report the case of a patient with COVID-19 and ischaemic stroke despite being on prophylactic anticoagulation therapy.

CASE PRESENTATION

A 64-year-old South Asian woman, with a medical history of mild hypertension and no other comorbidities, had returned from Malaysia in February 2020 with her partner, and possessed a negative COVID-19 reverse-transcriptase-PCR (RT-PCR) assay swab test. In March 2020, she attended hospital complaining of a dry cough, shortness of breath, loss of appetite, general malaise, diffuse muscle pain and fatigue for 10 days. During ambulance transfer, a fever of 38.7°C was recorded with a blood pressure of 85/50 mm Hg; she was hypoxic and required 10 L of oxygen/minute via a non-rebreathing mask. Her current medication prior to hospitalisation was spironolactone 25 mg once

daily, simvastatin 20 mg once daily and aspirin 75 mg once daily.

Significant findings on examination were of mild crepitations bilaterally and dyspnoea, requiring 10 L oxygen to keep saturation percentage levels above 90%. Examination otherwise was unremarkable.

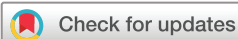INVESTIGATIONS

A chest X-ray showed right sided middle and lower zone shadowing and a clear left lung (figure 1), which raised suspicions for COVID-19. This was confirmed by a positive COVID-19 RT-PCR test the following day. Other blood tests showed a raised C reactive protein (CRP) level of 85 mg/L, normal white cell count but with low lymphocyte levels at $0.3 \times 10^9/L$, low platelet count of $54 \times 10^9/L$, high ferritin ($>3000 \mu g/L$), low vitamin D levels at 58 nmol/L and normal creatinine and urea levels. Blood gases on admission, revealed hypocapnia (pH 7.4; partial pressure of CO₂ (pCO₂) 4.43 kPa) and hypoxia (partial pressure of O₂ (pO₂) 8.94 kPa), which somewhat improved a few hours later (pCO₂ of 5.07 kPa; pO₂ of 11.9 kPa).

DIFFERENTIAL DIAGNOSIS

A diagnosis of COVID-19 infection with possible supra-added bacterial infection was made. The patient was commenced on clarithromycin and 1.2 g augmentin three times daily antibiotics, and prophylactic 40 mg enoxaparin once daily subcutaneously, which was the hospital protocol for severely unwell patients. At the time of management, use of steroids in these patients was discouraged, although only a few months later a large randomised controlled trial showed that dexamethasone reduced 28-day mortality in medium to severely ill patients.^{7 8}

On day 2 of admission, she suffered an episode of hypotension and bradycardia and was treated with intravenous fluids and placed on 40% continuous positive airway pressure (CPAP). Eventually, her blood pressure rose to 110/70 mm Hg and her O₂ saturation recovered to 94%. By day 3, she no longer needed CPAP but was maintained on nasal O₂. Further blood tests showed increased CRP levels (rising to 101 mg/L) but decreased platelets. Her renal function remained normal and lymphocyte count had both improved. On day 4, however, her condition worsened as her O₂ saturation level dropped suddenly and required assisted ventilation at 40% fraction of inspired oxygen (F_iO₂). On day 5 of admission, the patient was stable. Her dose of enoxaparin was reduced from 40 to 20 mg once daily in view of her reducing platelets.



© BMJ Publishing Group Limited 2021. No commercial re-use. See rights and permissions. Published by BMJ.

To cite: Sharma S, Wood M, Gulli G. *BMJ Case Rep* 2021;**14**:e243741. doi:10.1136/bcr-2021-243741

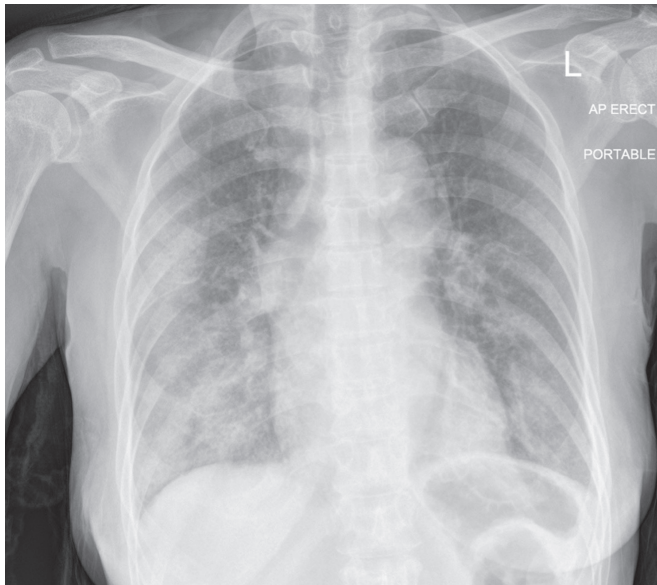


Figure 1 Anteroposterior (AP) chest X-ray at day of admission showing right-sided middle and lower zone shadowing and a clear left lung.

On day 8, the patient became drowsy with right-sided weakness. Blood tests showed a reduced Hb concentration of 105 g/L but improved CRP, platelets, estimated glomerular filtration rate (eGFR) and normal arterial blood gas. A CT scan confirmed an ischaemic stroke in the left middle cerebral artery territory (figure 2) but no thrombus or stenosis was found following CT Angiography (CTA) of arch of aorta and extracranial neck vessel imaging. An echocardiogram showed normal ventricular function and no thrombus. The patient was commenced on a reduced dose of 75 mg aspirin due to the low platelet count. That evening she became hypotensive and unresponsive with a Glasgow Coma Scale rating of 5, a modified Rankin scale of 4 and a National Institutes of Health Stroke Scale of 16.

The patient was kept on non-invasive ventilation and antibiotic treatment was changed to Tazocin 4.5 g three times daily via nasogastric tube feeding. She had regular blood tests and was

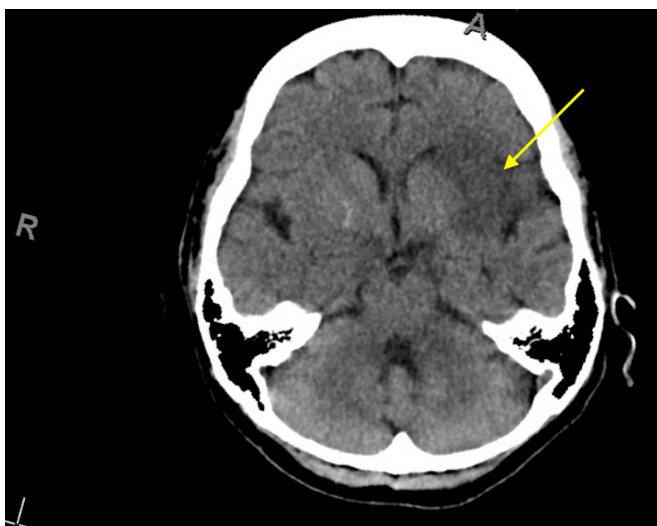


Figure 2 CT scan on day 8, showing left-sided temporoparietal ischaemic stroke (arrow).

seen daily by the physiotherapists. Despite this, her condition continued to worsen.

She further deteriorated and became acidotic and suffered type 2 respiratory failure. Her blood tests showed a further reduction in her platelet count of $13 \times 10^9/L$ with a D-dimer greater than 20 000. Her prothrombin time was 16.4 s with a prothrombin ratio of 1.17 suggesting a likely diagnosis of disseminated intravascular coagulation (DIC), which was made 12 days postadmission. She continued to receive CPAP.

OUTCOME AND FOLLOW-UP

After discussion with family, a decision was agreed to provide palliative care. She died the following day, 14 days following admission.

DISCUSSION

We present the case of a 64-year-old woman with confirmed COVID-19, who subsequently died of an ischaemic cerebral stroke despite receiving anticoagulant therapy.

Ischaemic stroke has been associated with acute cases of COVID-19.² The exact mechanism for this coagulopathy is unclear. One suggestion relates to how the SARS-CoV-2 binds to ACE2 receptors, causing a cascade of events leading to over-expression of the vasoconstricting agent angiotensin II together with under expression of the vasodilator angiotensin. Simultaneously, in some patients, an excessive production of proinflammatory cytokines leads to clot formation and platelet activation.⁹ However, risks of such coagulopathy would be expected to be ameliorated with formal anticoagulation prophylactic therapy, as prescribed in our patient.⁶ However, this theoretical benefit is clearly limited with other thrombotic events, such as incidences of COVID-19-related deep vein thrombosis, which remain high despite the use of low-molecular-weight heparin.⁹ Although there is a reported increase in the risk of COVID-19-associated stroke, there is still debate as to whether there is a causal effect of COVID-19 on the incidence of cerebrovascular events, or perhaps it is the critical illness in itself that induces an augmented risk of stroke. It is well known in clinical practice, that any critical illness, in particular infective conditions, may increase the incidence of cerebrovascular events.¹⁰ In our hospital we adopted a protocol of doubling the prophylactic enoxaparin dose to 40 mg once daily for all more seriously unwell patients with COVID-19.

A number of other possibilities for our patient's stroke, unrelated to coronavirus, should also be considered. High blood pressure is a well-recognised cause of stroke. Our patient had a history of hypertension which was being treated. Her blood pressure was only mildly elevated and during the described event, she was suffering from hypotension. Although hypotension may cause a watershed stroke, the ischaemic insult present on her brain imaging is not consistent with this. Another possibility is that the ischaemia was caused by infection. Sepsis has been associated with an increased risk of ischaemic stroke (OR of 28.4 within 15 days of sepsis).¹¹ However, as the white cell count remained normal up to the stroke, the more likely possibility is that the stroke was due to COVID-19 rather than any subsequent supra-added bacterial infection. Further, it is unlikely that DIC was responsible for the stroke, as the timeline of events indicates that it occurred after the stroke and so is more likely to have been caused by underlying infection.

The use of anticoagulant therapy, such as enoxaparin, has become common practice in management of patients with COVID-19 due to the virus's ability to trigger a coagulopathy, as

described above, leading to a high incidence of deep vein thrombosis (40%–58%) and pulmonary embolism (33%).¹² Alongside this, there is also a marked increase in D-dimer levels, which have been linked to predicting adverse outcomes.¹³ In our case, the patient's dose of enoxaparin was reduced but her D-dimer levels were not measured beforehand, which may have been able to predict an increased risk of stroke, and perhaps have given reason to delay reducing her enoxaparin dose, although this is debated.⁶

CONCLUSION

We present a case of COVID-19-related ischaemic stroke despite the use of prophylactic anticoagulation. We suggest that in cases of COVID-19, reduction in the dose of anticoagulation should be undertaken cautiously, with consideration to coagulopathy markers such as D-dimer.

Learning points

- ▶ COVID-19 is associated with ischaemic stroke.
- ▶ Anticoagulation therapy should be continued at an appropriate dose until patients are clinically much improved.
- ▶ Use of D-dimer or other surrogate markers may be appropriate for determining the risk of thromboembolic events.

Contributors SS wrote the first draft. MW was clinically in charge of the patient from the respiratory perspective and GG was clinically in charge from the stroke perspective. All authors contributed to the final version of the manuscript. GG takes overall responsibility for the work.

Funding The authors have not declared a specific grant for this research from any funding agency in the public, commercial or not-for-profit sectors.

Competing interests None declared.

Patient consent for publication Obtained.

Provenance and peer review Not commissioned; externally peer reviewed.

This article is made freely available for use in accordance with BMJ's website terms and conditions for the duration of the covid-19 pandemic or until otherwise determined by BMJ. You may use, download and print the article for any lawful, non-commercial purpose (including text and data mining) provided that all copyright notices and trade marks are retained.

ORCID iD

Shyam Sharma <http://orcid.org/0000-0003-4729-4803>

REFERENCES

- 1 Huang C, Wang Y, Li X, *et al*. Clinical features of patients infected with 2019 novel coronavirus in Wuhan, China. *Lancet* 2020;395:497–506.
- 2 Carod-Artal FJ. Neurological complications of coronavirus and COVID-19. *Rev Neurol* 2020;70:311–22.
- 3 Donkor ES. Stroke in the 21st century: a snapshot of the burden, epidemiology, and quality of life. *Stroke Res Treat* 2018;2018:3238165.
- 4 National Institute of Health and Care Excellence. Nice impact stroke, 2019
- 5 Perry RJ, Smith CJ, Roffe C, *et al*. Characteristics and outcomes of COVID-19 associated stroke: a UK multicentre case-control study. *J Neurol Neurosurg Psychiatry* 2021;92:242–8.
- 6 Rentsch CT, Beckman JA, Tomlinson L, *et al*. Early initiation of prophylactic anticoagulation for prevention of coronavirus disease 2019 mortality in patients admitted to hospital in the United States: cohort study. *BMJ* 2021;372:n311.
- 7 Horby P, Lim WS, *et al*, RECOVERY Collaborative Group. Dexamethasone in hospitalized patients with Covid-19. *N Engl J Med* 2021;384:693–704.
- 8 Russell CD, Millar JE, Baillie JK. Clinical evidence does not support corticosteroid treatment for 2019-nCoV lung injury. *Lancet* 2020;395:473–5.
- 9 Miesbach W, Makris M. COVID-19: coagulopathy, risk of thrombosis, and the rationale for anticoagulation. *Clin Appl Thromb Hemost* 2020;26:107602962093814.
- 10 Yende S, Linde-Zwirble W, Mayr F, *et al*. Risk of cardiovascular events in survivors of severe sepsis. *Am J Respir Crit Care Med* 2014;189:1065–74.
- 11 Boehme AK, Ranawat P, Luna J, *et al*. Risk of acute stroke after hospitalization for sepsis: a case-crossover study. *Stroke* 2017;48:574–80.
- 12 Iba T, Levy JH, Connors JM, *et al*. The unique characteristics of COVID-19 coagulopathy. *Crit Care* 2020;24:360.
- 13 Zi W-J, Shuai J. Plasma D-dimer levels are associated with stroke subtypes and infarction volume in patients with acute ischemic stroke. *PLoS One* 2014;9:e86465.

Copyright 2021 BMJ Publishing Group. All rights reserved. For permission to reuse any of this content visit <https://www.bmj.com/company/products-services/rights-and-licensing/permissions/>
BMJ Case Report Fellows may re-use this article for personal use and teaching without any further permission.

Become a Fellow of BMJ Case Reports today and you can:

- ▶ Submit as many cases as you like
- ▶ Enjoy fast sympathetic peer review and rapid publication of accepted articles
- ▶ Access all the published articles
- ▶ Re-use any of the published material for personal use and teaching without further permission

Customer Service

If you have any further queries about your subscription, please contact our customer services team on +44 (0) 207111 1105 or via email at support@bmj.com.

Visit casereports.bmj.com for more articles like this and to become a Fellow