

Magnetic resonance imaging of optic nerve

Foram Gala^{1,2}

¹Department of Radiology, Lifescan Imaging Centre, Mumbai, Maharashtra, India, ²Department of Neuroradiology, University Hospital of Zurich/Children's Hospital of Zurich, Switzerland

Correspondence: Dr. Foram Gala, Lifescan Imaging Centre, Malad, Mumbai - 400 064, Maharashtra, India. E-mail: drforamgala@gmail.com

Abstract

Optic nerves are the second pair of cranial nerves and are unique as they represent an extension of the central nervous system. Apart from clinical and ophthalmoscopic evaluation, imaging, especially magnetic resonance imaging (MRI), plays an important role in the complete evaluation of optic nerve and the entire visual pathway. In this pictorial essay, the authors describe segmental anatomy of the optic nerve and review the imaging findings of various conditions affecting the optic nerves. MRI allows excellent depiction of the intricate anatomy of optic nerves due to its excellent soft tissue contrast without exposure to ionizing radiation, better delineation of the entire visual pathway, and accurate evaluation of associated intracranial pathologies.

Key words: Magnetic resonance imaging; optic nerve; visual pathway

Introduction

Optic nerves are the second pair of cranial nerves and are unique as they represent an extension of the central nervous system and, hence, are myelinated by oligodendrocytes.^[1] They are the connection between eyes and brain, i.e. they relay visual impulses from retina to brain. Hence, most often, optic nerve abnormalities are associated with brain abnormalities.

This article describes the various common pathologies affecting optic nerves, such as demyelinating and inflammatory processes to less common optic nerve tumors and very rare congenital optic nerve abnormalities. Magnetic resonance imaging (MRI) is extremely useful in promptly identifying some of these pathologies to avoid permanent visual loss. In some cases, especially hereditary and congenital pathologies, unnecessary additional

work-up can be avoided as it helps in better counseling of patients and their families.

Anatomy of Optic Nerve

The first sensory bipolar cell body is located in the inner nuclear layer of retina. The central processes of bipolar cells synapse on ganglion cells in the ganglion cell layer of retina, and the central processes of the ganglion cells form the optic nerve proper. The axons leave the globe at optic disc to form the optic nerves, which then relay in lateral geniculate bodies.

Optic nerve is approximately 50 mm long and is divided into four segments [Figure 1].^[2] These are:

- Intraocular (1 mm) - when it emerges through the scleral opening
- Intraorbital (25 mm) - the longest segment and communication between subarachnoid space around the optic nerve with that in suprasellar cistern
- Intracanalicular (9 mm) - as it passes through bony optic canal along with ophthalmic artery (OA)
- Prechiasmatic (16 mm) - intracranial segment in suprasellar cistern.

It joins the contralateral optic nerve to form optic chiasma, where the nasal fibers from each optic nerve decussate and temporal fibers do not decussate.

Access this article online

Quick Response Code:



Website:
www.ijri.org

DOI:
10.4103/0971-3026.169462

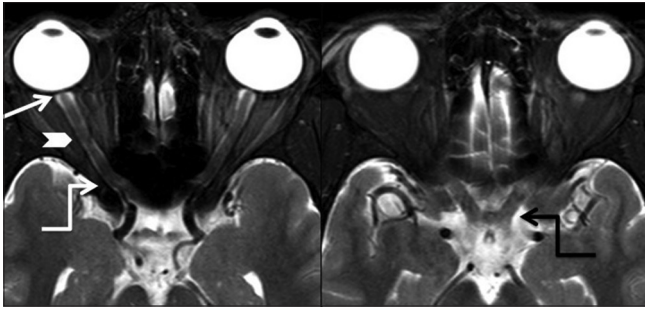


Figure 1: Normal anatomy. Axial T2 fat-saturated image shows the segmental anatomy of the optic nerve. Shortest intraocular segment or optic disc head (arrow), longest intraorbital segment (arrowhead), and intracranial segment (elbow arrow) are seen. Intracranial segment (white arrow) and optic chiasma (elbow arrow) are seen

Optic chiasma lies typically about 10 mm above the pituitary gland, separated by the suprasellar cistern. In about 80% of the population, it rests directly above the sella. However, it may rest above tuberculum sellae in 10% (prefixed chiasm) and above dorsum sellae in the remaining 10% of the population (postfixed chiasm). The prefixed chiasm has short optic nerves and long optic tracts, whereas the postfixed chiasm has long optic nerves and short optic tracts.^[3] Pituitary stalk angle is 90° or more in prefixed optic chiasm and acute angle for normal or postfixed chiasm.^[4]

From the optic chiasma, optic tracts course posterolaterally along the cerebral peduncles to synapse at lateral geniculate bodies. From the lateral geniculate nuclei, optic radiations fan out as optic radiations and reach the primary visual cortex in the occipital lobes.

MRI Protocol

MRI is the imaging modality of choice for evaluation of optic nerve pathway. The examinations were performed on 3 T MRI system (Achieva; Philips Medical Systems, Best, the Netherlands or HD.xt TwinSpeed; GE Healthcare, Milwaukee, Wisconsin). Head coil is commonly used; however, surface coil, if applied, improves the signal to noise ratio (SNR) of the globe.^[5] Imaging at 3 T MRI scanners offers superior SNR as well as spacial resolution to evaluate orbital structures as well as intracranial pathologies, as compared with 1.5 T scanners. Thin-section high-resolution spin-echo T2-weighted images at 3 T depict the optic nerves and orbital anatomy much better than 1.5 T scanner.^[6]

Thin coronal and axial T1 and short tau inversion recovery (STIR)/T2 fat-saturated sequences, as well as sagittal T2 fat-saturated sequences are obtained for optic nerve evaluation. A section thickness of 3-4 mm is preferred with an interslice gap of 0-1 mm. The entire examination takes about 30 min, and the patient is asked to refrain from eye movement during the scan.

Table 1: Pathologies affecting optic nerve and optic nerve sheath

Congenital / hereditary	Optic nerve aplasia Optic nerve hypoplasia including septo-optic dysplasia Dominant optic atrophy Lebers hereditary optic neuropathy Wolfram’s syndrome
Demyelination	Isolated optic neuritis Multiple sclerosis Neuromyelitis optica Acute disseminated encephalomyelitis
Inflammatory	Perineuritis Systemic Lupus Erythromatosus (SLE) associated optic neuritis Pseudotumor Sarcoidosis
Neoplastic	Optic nerve glioma (NF or non NF patients) Optic nerve sheath meningioma Metastases
Ischemic	Anterior Ischemic Optic Neuropathy- Arteritic or Nonarteritic Posterior Ischemic Optic Neuropathy
Miscellaneous	Idiopathic Intracranial Hypertension Secondary compressive optic atrophy i) Tumor- orbital/sellar-suprasellar masses ii) Thyroid orbitopathy iii) Vascular Traumatic optic neuropathy Toxic optic neuropathy Intraocular pathologies causing optic neuropathy

Table 2: Optic nerve pathologies based on onset of symptoms

Sudden onset	Demyelination Inflammatory Pseudotumor Infective Traumatic Ischemic optic neuropathy (AION, PION) Benign intracranial hypertension
Gradual onset	Congenital /Hereditary optic neuropathy Compressive optic atrophy Neoplastic Toxic optic atrophy

We also routinely acquire diffusion-weighted imaging (DWI), fluid-attenuated inversion recovery (FLAIR), and susceptibility-weighted imaging (SWI) for the entire brain. Contrast, if needed, is administered and fat-saturated images are obtained post- gadolinium injection.

Pathologies

The etiological spectrum ranges from congenital, demyelination, inflammatory, neoplastic, and ischemic to miscellaneous pathologies [Table 1]. Pathologies based on onset of symptoms are also described [Table 2].

Congenital and Hereditary Optic Neuropathy

Optic nerve aplasia

It includes complete lack of the optic nerve, optic disc, retinal ganglion and nerve fiber layer, and optic nerve vessels. It can be unilateral or bilateral [Figure 2]. Other ocular abnormalities like micro-ophthalmia, cataract, iris hypoplasia, anterior coloboma, persistent primary hyperplastic vitreous, cranial and systemic abnormalities are often associated.^[7,8]

Mutations in *PAX6* (paired box 6) gene (11p13) have been associated with optic nerve malformations, including optic nerve aplasia/hypoplasia, coloboma, morning glory disc anomaly, aniridia, and persistent hyperplastic primary vitreous. *PAX6* is involved in ocular morphogenesis as well as in the development of Rathke's pouch and early anterior pituitary gland.^[9]

Optic nerve colobomas

These are characterized by focal defect in the posterior globe at the optic nerve head insertion [Figures 3 and 4]. The defect can be of variable size - typically small, less than the size of the optic nerve head. It is caused by incomplete closure of the embryonic fissure and may be associated with microphthalmia and retrobulbar colobomatous cyst. Many brain abnormalities like gyration abnormalities, lateral ventricular dilatation, dilatation of the Virchow-Robin and subarachnoid spaces, white matter signal and corpus callosal abnormalities are associated.^[10]

Morning glory syndrome is an optic disc anomaly characterized by three primary features - excavated optic disc with central glial tuft, the defect is surrounded by elevated ring of peripapillary pigment, and blood vessels traversing radially from the disc margin. It is named for its fundoscopic resemblance to morning glory flower.^[8]

It can be isolated or associated with wide spectrum of congenital abnormalities like anterior midline craniofacial defects, pituitary abnormalities, corpus callosum agenesis/dysgenesis, basal encephalocele, and vascular abnormalities including Moyamoya syndrome.^[11]

Intraorbital MRI findings include funnel-shaped morphology of the optic nerve head, elevated adjacent retinal surface showing T1-hyperintense signal corresponding to peripapillary pigment, discontinuity of T2-hypointense line, and enhancement of posterior choroid-lamina cribrosa, abnormal tissue associated with the distal intraorbital segment of the optic nerve causing effacement of the subarachnoid spaces of the distal optic nerve sheath. Other findings include distal optic nerve enhancement, fatty infiltration of distal optic nerve sheath, small size of globe, asymmetry in optic nerve and chiasma,

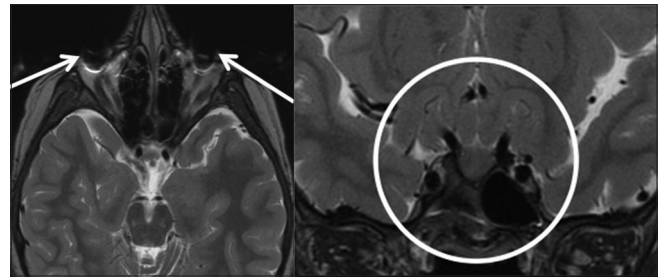


Figure 2: Congenital: Optic nerve aplasia. Axial and coronal T2W images show anophthalmia, i.e. absence of globes (arrows), along with absence of optic nerves and optic chiasma (circle)

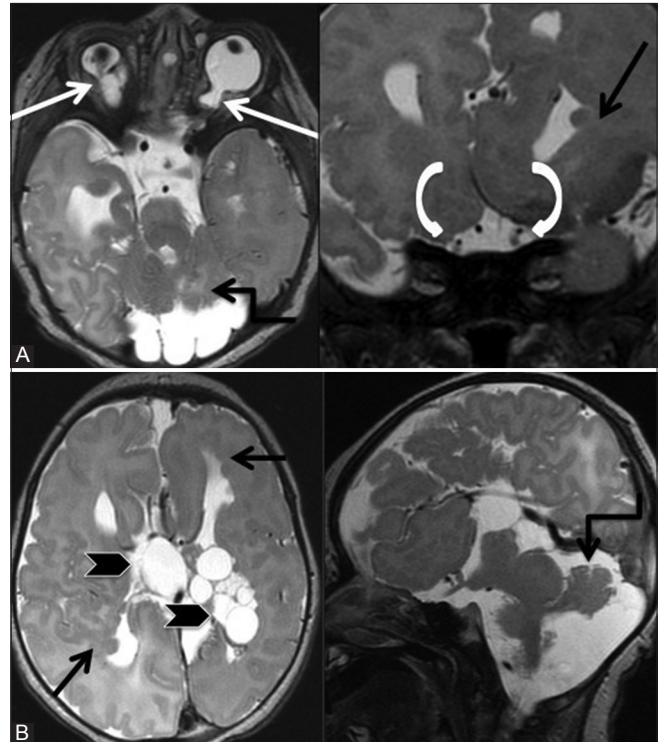


Figure 3 (A and B): Congenital: Colobomas. Axial and coronal T2W (A) images of a 5-day-old child show right microphthalmia with bilateral colobomas (arrows). Note the right optic nerve is hypoplastic and smaller as compared to the left optic nerve (curved arrows). Other brain findings on axial and sagittal T2W (B) images include multiple choroid plexus cysts (arrowheads), dysplastic cerebellum with posterior fossa cysts (elbow arrow), corpus callosal agenesis, and subependymal heterotopia (black arrow). These findings were suggestive of Aicardi syndrome

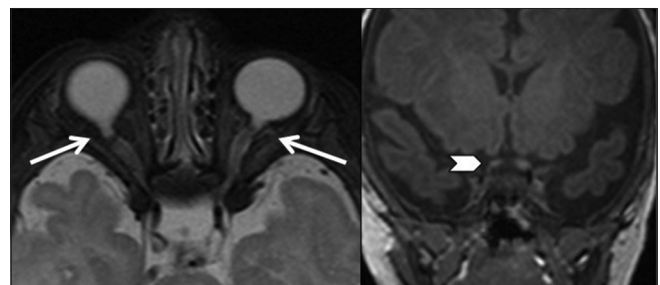


Figure 4: Congenital: Colobomas. Axial T2 fat-saturated and coronal T1W images of a 2-month-old baby who does not fixate eyes show bilateral colobomas (arrows) with hypoplastic right prechiasmatic optic nerve (arrowhead)

and optic glioma.^[12] Ocular associations include retinal detachment, congenital cataract, persistent hyperplastic primary vitreous, drusen, and eyelid hemangioma.

Intracranial findings include a range of vascular abnormalities from hypoplasia/segmental agenesis of vessels to progressive vasculopathy with Moyamoya syndrome. Basal encephaloceles including persistence of craniopharyngeal canal with herniation of pituitary gland may be seen. Agenesis/dysgenesis of corpus callosum is also well seen on MRI.

Morning glory disc anomaly is distinct from optic disc coloboma. It occurs sporadically as compared to optic disc coloboma which is commonly familial and associated with multisystem congenital malformation syndromes. Morning glory disc anomaly is also associated with PHACE syndrome (posterior fossa malformation, hemangiomas, arterial anomalies including coarctation of aorta, cardiac anomalies, and ocular anomalies), when additional finding of sternal clefting is present, it is called PHACES syndrome, CHARGE syndrome (coloboma, heart defects, atresia of the choanae, retarded growth, ear anomalies), Okiihiro syndrome (upper limb, ocular anomalies, deafness, and in some renal anomalies), and neurofibromatosis type 2.^[8] Various syndromes such as Aicardi [Figure 3] and Meckel syndrome are associated with colobomas.

Optic nerve hypoplasia

It is characterized by small optic disc affecting one or both eyes [Figures 3-6]. It can occur in isolation or in combination with endocrine (pituitary and hypothalamic dysfunction) and brain abnormalities [ventricles or white or gray matter development abnormalities, septo-optic dysplasia (SOD) [Figure 5], hydrocephalus, and corpus callosal abnormalities].^[13]

SOD is a heterogeneous condition diagnosed when two or more features of the classical triad, i.e. i) Optic nerve hypoplasia, ii) pituitary hormone abnormalities, and iii) midline brain defects – agenesis of septum pellucidum and/or corpus callosum, are present. Clinical presentations include hypopituitarism, the commonest being growth hormone deficiency presenting as short stature, failure to thrive, hypoglycemia, developmental delay, and visual impairment.^[14]

It usually occurs sporadically; however, a number of familial cases have been described. Mutations in homeobox *HESX1* gene are associated with sporadic cases and mutations of both *SOX2* and *SOX3* in the etiology of variants of SOD.^[14] Mutations have also been identified in *SOX2* in association with severe bilateral eye abnormalities (anophthalmia, microphthalmia) and defects of the corpus callosum with anterior pituitary hypoplasia. Additional features described in association with *SOX2* mutations include developmental

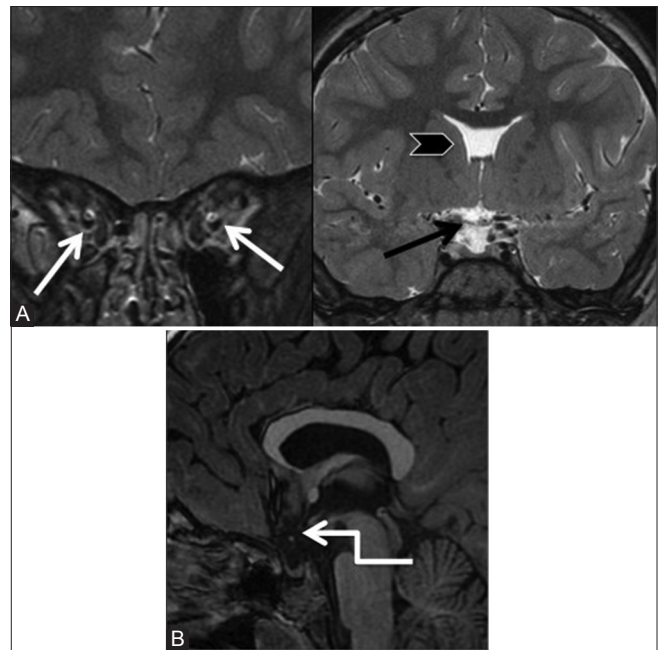


Figure 5 (A and B): Congenital: Septo-optic dysplasia. Coronal T2W (A) images of a 7-year-old girl with gradual loss of vision and short stature showing hypoplastic optic nerves (white arrow) and optic chiasma (black arrow). Sagittal T1W (B) image also shows ectopic neurohypophysis (arrow)

delay, short stature, esophageal atresia, male genital tract abnormalities, and sensorineural hearing loss.^[15,16]

MRI shows hypoplastic optic nerves and chiasma, and various other findings of hypothalamic–pituitary dysfunction, i.e. anterior pituitary hypoplasia, ectopic posterior pituitary, absent/hypoplastic infundibulum, partial or complete absence of septum pellucidum and corpus callosum. Other findings are schizencephaly, hydrocephalus, and Chiari II malformation.^[17]

Sakoda complex includes sphenothmoidal encephalomeningocele, agenesis of the corpus callosum, and cleft lip and/or palate [Figure 6]. Associated optic disc dysplasia, microphthalmia, cortical dysgenesis, mental retardation, and epilepsy may be seen.^[18]

Hereditary optic neuropathies include dominant optic atrophy and Leber hereditary optic neuropathy. Dominant optic atrophy is autosomal dominant, whereas Leber hereditary optic neuropathy has mitochondrial inheritance. These are characterized by painless loss of central vision, manifesting in childhood or adulthood.^[19] The diagnosis is based on ophthalmoscopic findings. MRI reveals diffuse bilateral optic nerve atrophy.

Wolfram's syndrome is a rare hereditary genetic disorder characterized by combination of diabetes insipidus, diabetes mellitus, optic atrophy, and deafness (DIDMOAD). It can be autosomal recessive or can have mitochondrial

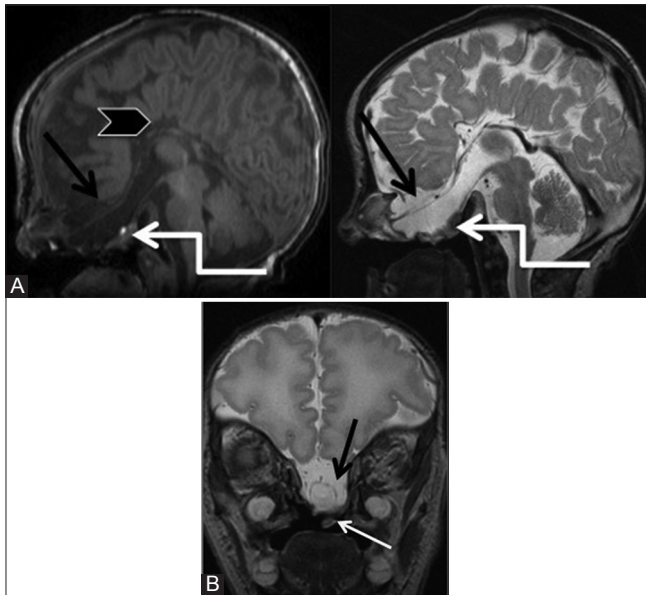


Figure 6 (A and B): Congenital: Optic nerve hypoplasia. Sagittal T1, T2W (A) and coronal T2W (B) images of a 1-day-old baby with multiple congenital anomalies showing basal (sphenoethmoidal) encephalocele (elbow arrow), corpus callosal agenesis (arrowhead), cleft lip and palate (white arrow), microphthalmia, and hypoplastic optic nerves and chiasma (black arrows)

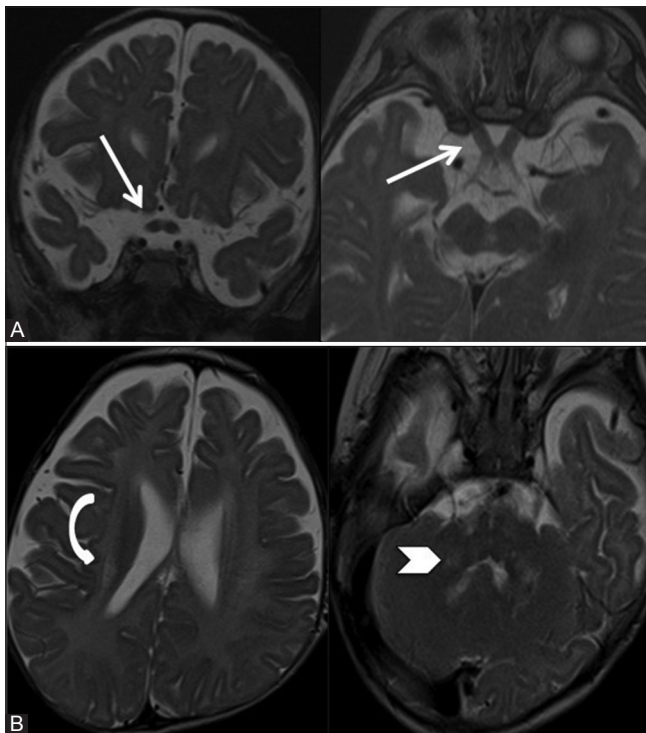


Figure 8 (A and B): Congenital: Optic nerve hypertrophy. Coronal and axial T2W (A) images of a 4-month-old boy with irritability and developmental delay with Krabbe's disease show thickened prechiasmatic optic nerves and chiasma (arrow). Axial T2W (B) images of brain show abnormal hyperintense signal in corona radiata (curved arrow) and in bilateral dentate nuclei (arrowhead)

inheritance.^[20] MRI confirms the fundoscopic findings of optic nerve atrophy and also reveals absent posterior

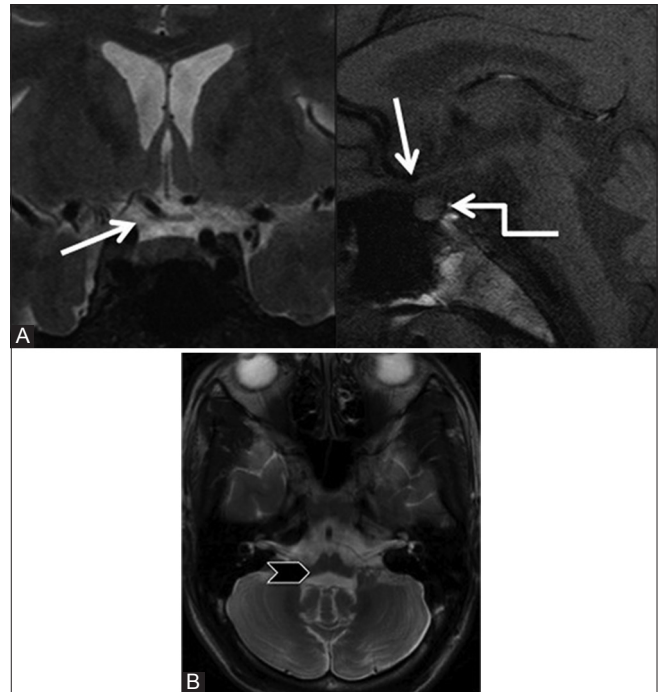


Figure 7 (A and B): Hereditary optic neuropathy. Coronal T2W and sagittal T1W (A) images of a 23-year-old male, a known juvenile diabetes mellitus, who had gradual loss of vision shows severe thinning of both optic nerves and chiasma (arrow) and absent T1-hyperintense signal of posterior pituitary (elbow arrow). Axial T2W (B) image shows severe brainstem and cerebellar atrophy (arrowhead). All these findings are suggestive of Wolfram's syndrome

pituitary T1-hyperintense signal. Cerebellar and brain stem atrophy is also seen [Figure 7].

Optic nerve hypertrophy

Hypertrophy of prechiasmatic optic nerves and optic chiasma has well been described in Krabbe's syndrome [Figure 8] which is an autosomal recessive lysosomal disorder caused due to deficiency of galactocerebroside β -galactosidase resulting in accumulation of globoid cells containing psychosine (galactosylsphingosine). Other MRI findings are white matter abnormalities, which are symmetric, patchy, and confluent involving periventricular and cerebellar white matter. High density on non-contrast CT scan is noted in basal ganglia, posterolateral thalami, and posterior limb of the internal capsule. T2-hypointense signal is seen in basal ganglia and dentate nucleus. Brain atrophy occurs later in the disease course.^[21] Enhancement of multiple cranial nerves and spinal roots has also been described. This occurs secondary to myelin breakdown and associated inflammation.^[22]

Differential diagnosis of optic nerve hypertrophy is broad [Table 3] and includes optic nerve glioma with dural ectasia, neurofibromatosis 1 (NF1), optic nerve sheath meningioma (ONSM), histiocytic or granulomatous infiltration of the optic nerves, juvenile xanthogranuloma, medulloepithelioma of the optic nerve, leukemia, and orbital pseudotumor.^[23-27]

Table 3: Optic nerve hypertrophy: Differential diagnosis

Diseases	Key features/orbital findings	Associated brain/Systemic findings
Krabbe's disease	Autosomal Recessive disease due to deficiency of galactocerebroside β -galactosidase enzyme Infantile form most common Thickened optic nerves on MRI	Non-contrast CT- hyperdense basal ganglia and posterolateral thalami MRI-Symmetric, patchy confluent periventricular and cerebellar white matter signal, T2 hypointensity in basal ganglia and dentate nucleus, Cerebral and cerebellar atrophy in late stages, Enhancement of multiple cranial nerves and spinal roots
Neurofibromatosis 1	NF1 is a neurocutaneous condition with autosomal dominant inheritance in 50% due to mutation in gene on chromosome 17. Rest of 50% cases are sporadic Ocular manifestations: 1) Lisch nodules in iris - 2 or more nodules are included in diagnostic criteria for NF1 2) Buphthalmos 3) Optic sheath dural ectasia- idiopathic expansion of CSF within optic sheath 4) Optic nerve glioma-thickened enlarged optic nerves, unilateral or bilateral, may involve optic chiasma, optic tracts 5) Plexiform neurofibroma-infiltrative lesion mainly in superior orbital soft tissue resulting in proptosis 6) Choroid hamartomas-flat ill-defined lesions usually at posterior pole 6) Retinal tumors-astrocytic hamartomas, retinal hemangiomas	Brain: 1) Hamartomas- T2 hyperintense foci in bilateral basal ganglia, thalami, dentate nuclei and white matter due to spongiform changes 2) Gliomas 3) Sphenoid wing dysplasia, enlargement of middle cranial fossa with arachnoid cyst 4) Arterial abnormalities including moya moya pattern, aneurysms Others: Neurofibromas along peripheral and spinal nerves, dural ectasia, meningoceles, kyphoscoliosis, tibial bowing, pseudoarthroses, focal overgrowth of digit or limb
Optic nerve glioma	Usually occurs in children and are associated with NF1 Imaging findings: Fusiform enlargement of nerve with nerve not seen separate from tumor Variable T2 signal and enhancement May have Perineural arachnoid gliomatosis	Can involve optic nerve, chiasma or optic tracts
Optic nerve meningioma	Usually occurs in middle aged female and in children associated with NF2 Imaging findings: Tram-tract sign-central non-enhancing optic nerve surrounded by homogenously enhancing tumor Erosion/Hyperostosis of adjacent bone	The intraorbital tumor may be extension from cavernous sinus, clinoid process, pituitary fossa, planum sphenoidale or olfactory groove
Histiocytic or granulomatous infiltration of the optic nerves	Histiocytic disease: Along with optic nerve infiltration, there are lesions involving bony orbital wall, associated soft tissue mass may show intracranial extension Granulomatous diseases like sarcoidosis may affect optic nerves. Associated findings are diffuse lacrimal gland enlargement with extra ocular muscle infiltration, eyelid and periorbital inflammation	Histiocytic disease: Bones commonly involved. Definite diagnosis by biopsy Brain findings in sarcoidosis: Thickening and enhancement of cranial nerves especially optic nerves, nodular leptomeningeal enhancement, intraparenchymal lesions, infundibular thickening with suprasellar mass, dural based enhancing T2 hypointense lesions
Juvenile xanthogranuloma	Benign self-limiting cutaneous disorder may have rarely systemic manifestations. Ocular manifestations include localized or diffuse iris tumor, unilateral glaucoma, spontaneous hyphaema, red eye with signs of uveitis, iris heterochromia	Characteristic skin lesions and Biopsy-granulomatous reaction with presence of foreign body giant cells and touton giant cells and absence of intracytoplasmic granules and lack of staining with S100 (which are present in histiocytosis) help in its diagnosis
Medulloepithelioma	Mimics optic nerve glioma. It causes fusiform enlargement of optic nerve	-
Leukemia	Both acute and chronic leukemia can present with infiltrating mass involving eyelid, optic nerve, conal and intraconal structures or with leukemic retinopathy. Relapse of disease is known to occur in orbit due to suboptimal penetration of chemotherapeutic drugs	Brain: Extradural enhancing lesions, parenchymal lesions or leukemic meningitis
Orbital pseudotumor	Acute painful diplopia, or other ocular symptoms Dramatic improvement with corticosteroids Imaging findings: T1, T2 hypointense enhancing soft tissue intraorbital mass. Optic nerve involved along with retrobulbar fat and extraocular muscles	Extension into orbital fissure and cavernous sinus may be seen-Tolosa Hunt syndrome

NF1 is much more common than Krabbe's disease. Both optic nerve glioma and optic nerve sheath ectasia may occur in NF1 patients. Orbital imaging findings in NF1 are: Enlargement of optic canal due to optic nerve glioma, dilatation of CSF within optic nerve sheath, retinal astrocytomas, infiltrating plexiform neurofibromas causing

soft tissue alterations in the globe and extraocular muscles and also causing enlargement of various foramina (foramen ovale, rotundum, vidian canal, infraorbital canal, etc.), secondary sphenoid wing dysplasia which is characterized by remodeling or decalcification of sphenoid wings with anteroposterior enlargement of middle cranial fossa

indenting the posterior orbit and causing shortening with decreased volume of orbit and proptosis. Classic egg-shaped orbital deformity has been described due to combination of anterior displacement of globe by the enlarging middle cranial fossa and downward displacement of globe due to infiltrating plexiform neurofibroma in the superior soft tissues of the orbit.^[28,29]

Hamartomatous lesions are commonly seen in MRI Brain in NF1 patients. These are T2-hyperintense non-enhancing lesions without any mass effect occurring in the brain stem, cerebral peduncles, and optic radiations. Gliomas, mostly low-grade astrocytomas, may also occur in these patients.^[30]

DEMYELINATION

Optic neuritis and its association with multiple sclerosis and acute disseminated encephalomyelitis

Optic neuritis (ON) literally means inflammation of the optic nerve. However, it is usually reserved for demyelinating events, isolated or with multiple sclerosis (MS) or acute disseminated encephalomyelitis (ADEM) or neuromyelitis optica (NMO). It results in acute monocular vision loss associated with some painful eye movements. It is two times more common in females than males.^[31] The cause is presumed to be an autoimmune reaction that results in a demyelinating inflammation of the nerve. A gradual recovery of visual acuity with time is characteristic of ON.^[32] For most patients, even without treatment, visual function improves from 1 week to several weeks after onset. In the Optic Neuritis Treatment Trial (ONTT) study, intravenous steroids improved the vision faster as compared to those treated with oral steroids or placebo. Intravenous steroids showed statistically significant benefit in contrast sensitivity, color vision, and visual field, but not in visual acuity at 6 months. At 1-year follow-up, there was no statistically significant difference in visual function among the groups.^[33] However, Plant *et al.* suggested that high-dose corticosteroids, when administered at the onset of pain, may abort the attack of ON and prevent visual loss.^[34] Intravenous steroids are recommended to reduce 2-year risk of developing MS when three or more signal abnormalities are present in MRI brain. They can also be considered to expedite recovery of vision.^[35] Disease-modifying drugs such as beta-interferon or glatiramer acetate have also been used to reduce the development and severity of clinically definite MS.^[36]

Visual outcome is better in patients with an isolated episode of ON as compared with patients who develop MS. Up to 75% of female patients and 35% of male patients initially presenting with ON ultimately develop MS.^[37,38]

In the ONTT, the 5-year risk of developing MS was 16% in patients with normal brain MRI findings, 37% in patients with one or two lesions, and 51% in those with three or more lesions.^[39]

Imaging pearls

The optic nerve is swollen with hyperintense signal on STIR/T2 fat-saturated images and has intense homogenous enhancement [Figure 9]. Occasionally, it reveals peripheral tram-track pattern of enhancement mimicking ONSM. However, ON will show enhancement limited to the nerve, rather than the sheath-like pattern of meningioma; there is absence of significant mass or expansion with clinical features of acute onset visual loss and pain.

ADEM may be also associated with ON. It is a rare multifocal, inflammatory demyelinating disorder of the central nervous system (CNS) occurring after vaccination, viral infections, or spontaneously. It is most commonly a non-progressive acute monophasic illness.^[40] Encephalopathy is a feature required for the diagnosis of ADEM, which differentiates it from MS. ADEM-associated ON is often bilateral, as compared to MS which frequently has unilateral involvement. MRI can differentiate between these two demyelinating conditions. ADEM lesions are multiple, large, usually bilateral, but asymmetrical involving subcortical white matter or centrum semiovale. Basal ganglia, thalami, and brain stem may be involved in ADEM [Figure 10]. MS typically shows ovoid, flame-shaped plaques oriented perpendicular to the lateral ventricles (Dawson's fingers) due to perivenular demyelination. The lesions in MS typically involve the calloso-septal interface in up to 93% of patients.^[41] The corpus callosum and brain stem are also commonly involved [Figure 11]. Tumefactive demyelination appears as large tumor-like mass without much mass effect or edema, has open ring-like enhancement, and often shows central dilated veins within. The lesions have reduced perfusion and show rapid resolution with steroids.^[42]

Cerebrospinal fluid pleocytosis (greater than or equal to) 50 white blood cells/mm³ can be observed in ADEM, whereas this finding is highly atypical for MS.

Neuromyelitis optica

Neuromyelitis optica (NMO) is an autoimmune demyelinating disease induced by a specific autoantibody, NMO-IgG, directed against aquaporin-4 water channels.

Imaging pearls

NMO preferentially affects the optic nerve and the spinal cord.^[43] Demyelination of the spinal cord has an appearance similar to that of transverse myelitis, involving over four to seven vertebral segments and the full transverse diameter [Figure 12].

Female are nine times more affected than males.^[43]

Brain lesions can occur and often are distinct from those seen in MS, and are around the ventricles due to high concentration of aquaporin-4 water channels. Periependymal lesions surrounding the third ventricle

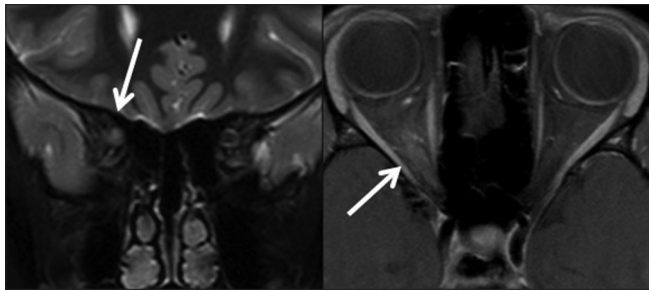


Figure 9: Demyelination: Optic neuritis. Coronal STIR and post-contrast T1 fat-saturated images of a 31-year-old female with sudden right vision loss show hyperintense signal in right intraorbital optic nerve with post-contrast enhancement (arrow)

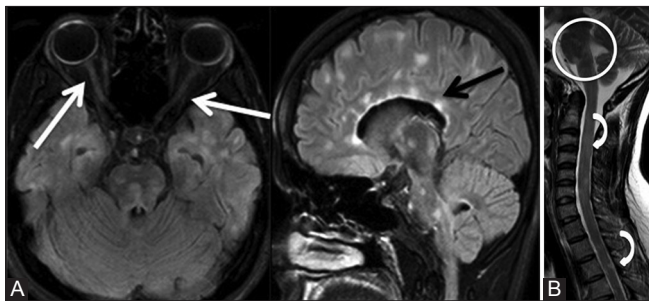


Figure 11 (A and B): Demyelination: Multiple sclerosis. Axial and sagittal FLAIR (A) images of brain in a 26-year-old female show hyperintense signal in bilateral optic nerves (white arrows) and periventricular plaques (black arrow). Sagittal T2W (B) image of posterior fossa and upper spine reveals multiple plaques in brain stem (circle) and lesions in spinal cord (curved arrows)

and cerebral aqueduct are highly characteristic, with involvement of thalamus, hypothalamus, and midbrain. The dorsal part of brain stem adjacent to the fourth ventricle may be involved in NMO.^[44] However, non-specific brain lesions are most commonly seen.

Table 4 shows the various demyelinating diseases affecting the optic nerves.

Inflammatory

Perineuritis

It is an uncommon variety of orbital inflammatory disease that is distinct from demyelinating ON. It affects the older age group as compared with ON and classically shows sparing of central vision.^[45] Optic perineuritis usually is idiopathic; however, few case reports have been described with tuberculosis, syphilis, sarcoidosis, Wegener's granulomatosis, and giant cell arteritis.^[46-52]

Imaging pearls

MRI reveals enhancement around, rather than within, the optic nerve (tram-track sign on axial and doughnut sign on coronal images) and "streaky" fat with or without extraocular muscle enhancement [Figure 13]. Associated MRI findings with secondary etiologies include multiple tuberculous

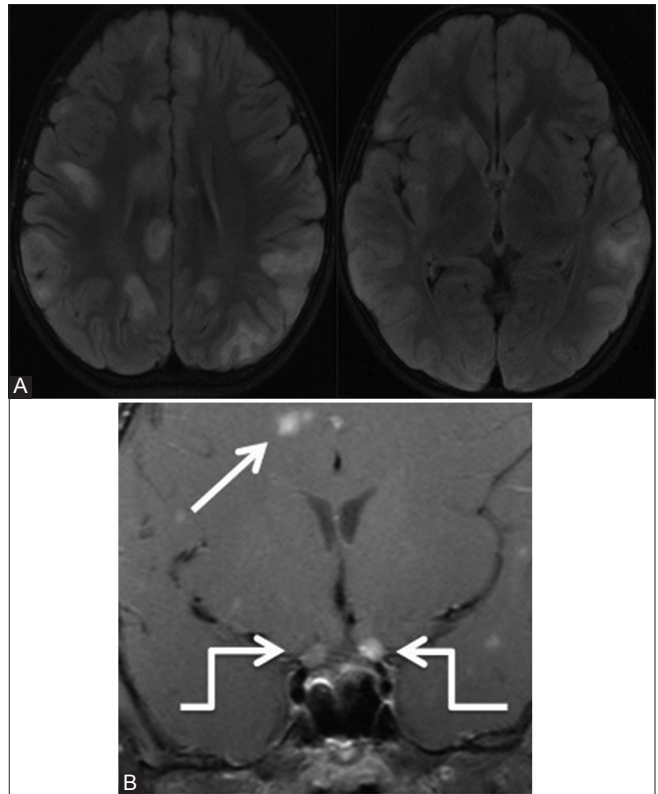


Figure 10 (A and B): Demyelination: ADEM. Axial FLAIR (A) and coronal post-contrast T1W (B) images of an 8-year-old female with sudden vision loss and altered behavior show multiple hyperintense lesions mainly in bilateral subcortical white matter and in right basal ganglia. There is enhancement of both the prechiasmatic optic nerves (elbow arrow). Few other enhancing lesions are seen in brain (arrow)

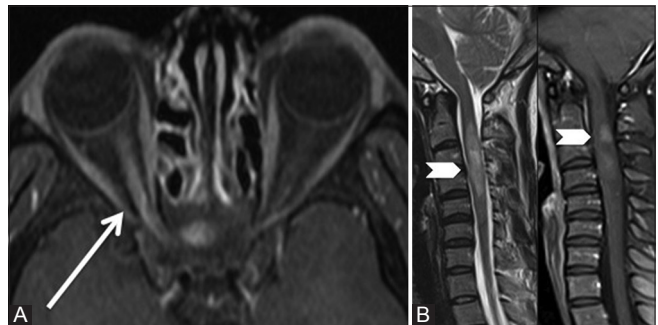


Figure 12 (A and B): Demyelination: Neuromyelitis optica. Axial post-contrast T1 fat-saturated (A) image of a 27-year-old female with sudden vision loss and tingling numbness in left arm shows enhancement in right optic nerve (arrow) suggestive of optic neuritis. Sagittal T2W and post-contrast T1 fat-saturated images (B) show hyperintense signal with heterogeneous enhancement of long segment of cervical cord (arrowhead) suggestive of myelitis. This patient had NMO antibodies positive

granulomas, enhancement of multiple intracranial nerves with dural-based or intraparenchymal lesions, infundibular thickening and nodular leptomeningeal enhancement in sarcoidosis, wall thickening and enhancement of superficial temporal arteries with adjacent fat stranding in giant cell arteritis. Often ON can be the initial presentation of these diseases.

Table 4: Demyelinating diseases: Differential diagnosis

Diseases	Key features/orbital findings	Associated brain/Systemic findings
Isolated optic neuritis	Acute painful monocular vision loss MRI- Swollen optic nerve with hyperintense signal on STIR images and intense post contrast enhancement.	MRI brain excludes MS, ADEM, and NMO
Acute disseminated encephalomyelitis (ADEM):	Acute monophasic illness occurring after vaccination, viral infections or spontaneously Encephalopathy is required feature	Brain: Multiple bilateral asymmetric lesions involving gray as well as white matter -Incomplete rim enhancement Spinal cord: Involvement of long segment of cord (>4 vertebral bodies) and extending to more than 2/3 rd of its cross section
Multiple sclerosis (MS):	Multiphasic demyelinating disorder	Brain: Dawson's finger due to flame shaped plaques perpendicular to lateral ventricular margin. Callosal-septal interface involved Spinal cord: Plaques involving short segment of cord and less than 2/3 rd of its circumference
Neuromyelitis optica (NMO):	Demyelinating disease induced by a specific autoantibody, NMO-IgG directed against aquaporin-4 water channels. It preferentially affects the optic nerve and spinal cord	Spinal cord: Involvement of long segment of cord (>4 vertebral bodies) and extending to more than 2/3 rd of its cross section Brain: Periependymal lesions surrounding the third ventricle and cerebral aqueduct, thalamus, hypothalamus and midbrain involved

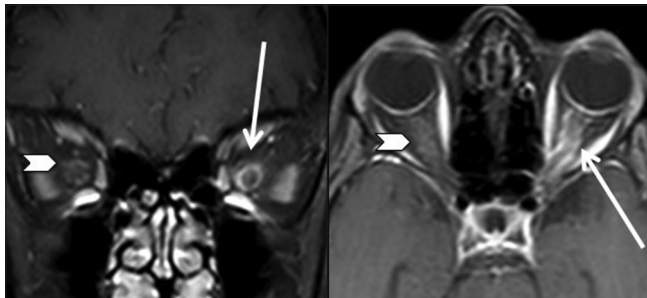

Figure 13: Inflammatory: Perineuritis. Coronal and axial post-contrast T1 fat-saturated images of a 47-year-old female with sudden onset pain and blurring in left eye show enhancement around the left optic nerve (arrow) with tram-track appearance due to perineuritis. Minimal enhancement is also seen around right optic nerve (arrowhead)

Optic perineuritis mimics ONSM on MRI, but clinically, it is more likely to be mistaken for acute demyelinating ON. Response to corticosteroids is more dramatic than in patients with ON, and patients are more likely to experience recurrence after stopping treatment.^[45] Secondary optic perineuritis patients need specific treatment often with corticosteroids for a longer time, with duration depending on response to treatment.^[47] Tuberculous perineuritis is treated with anti-tuberculous treatment for a year,^[46] syphilis with antibiotics (penicillin),^[48] giant cell arteritis needs high dose corticosteroids,^[49] Wegener's granulomatosis with high dose of corticosteroids may be followed by more complex regimen to induce remission: A combination of rituximab, steroids, and cyclophosphamide.^[50] Sarcoid optic perineuritis is treated with corticosteroids which need slow tapering. In refractory cases, immunosuppressive agents (azathioprine and cyclosporine) and antimetabolites (cyclophosphamide, chlorambucil, and methotrexate) may be given.^[51]

Systemic lupus erythematosus associated ON

Systemic lupus erythematosus (SLE) is a chronic autoimmune disease involving multiple organs. Females are nine times more affected than males.^[53] In

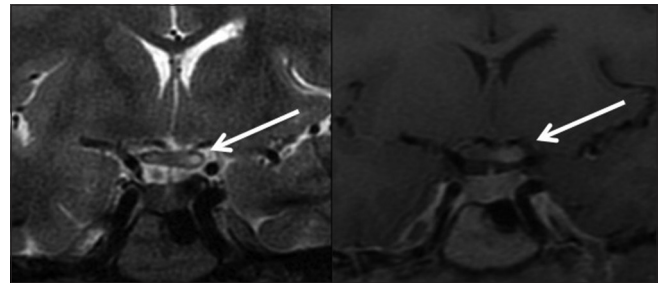


Figure 14: Inflammatory: SLE. Coronal STIR and post-contrast T1 fat-saturated images of an 18-year-old female with known SLE with intense headache and blurring of left vision, showing abnormal signal in optic chiasma (left > right) with enhancement on the left side of optic chiasma

SLE, keratoconjunctivitis sicca is the most common orbital condition; however, the most dreaded and uncommon is optic nerve involvement and retinal vaso-occlusion. It is caused by an ischemic event followed by axonal loss. Initial visual loss is severe; final outcome is variable. It is necessary to differentiate SLE-associated ON [Figure 14] from idiopathic ON because of the severe visual impairment and steroid dependence associated with the SLE-induced ON. Early diagnosis and prompt treatment are important for restoring visual function in these patients.^[53,54]

Orbital pseudotumor

An idiopathic orbital inflammatory syndrome or orbital pseudotumor is a nonspecific, non-neoplastic inflammatory process of the orbit.

Imaging pearls

Imaging shows diffuse orbital mass, uveoscleral thickening, involvement of optic nerve, extraocular muscles, and lacrimal glands. There may be presence of fluid in Tenon's capsule. The soft tissue mass is hypointense on T1 and T2W images and shows marked post-contrast enhancement. It involves the muscle bellies and tendons of extraocular

muscles. Optic perineuritis may be seen when there is involvement of optic nerve sheath with inflammatory soft tissue which also infiltrates adjacent fat. When the inflammatory soft tissue is confined to superior orbital fissure and cavernous sinus, it is known as Tolosa Hunt syndrome. Dramatic improvement with corticosteroids is the hallmark of orbital inflammatory syndrome.^[55]

Sarcoidosis

This may involve any part of the orbit, i.e. extraocular muscles, orbital fat, lacrimal glands, or globe, and can be indistinguishable from pseudotumor. Cranial nerves are commonly involved in sarcoidosis.^[56] Optic nerve involvement can be unilateral or bilateral and is involved in intraorbital segment or at the level of chiasma.^[57] The nerves are enlarged, thickened, and show hyperintense signal on STIR/T2 fat-saturated images and reveal post-contrast enhancement. The dural sheath may be involved mimicking optic nerve meningioma.

Associated orbital findings

Diffuse lacrimal gland enlargement (50-60%) with extension and involvement of lateral rectus and/or other extraocular muscles' infiltration, eyelid and periorbital inflammation.

Associated brain findings

Nodular leptomeningeal enhancement, intraparenchymal lesions, infundibular thickening with suprasellar mass, dural based enhancing T2-hypointense lesions.^[56]

TUMORS

Optic nerve glioma

These are relatively rare tumors and occur in children; they are often associated with NF1. These are mainly low-grade astrocytomas; however, their biological behavior is unpredictable.^[58] They are often multifocal and bilateral in NF1 patients. In NF1 patients, the orbital nerve is the commonest site, followed by optic chiasma and hypothalamus, whereas in non-NF1 patients, chiasma

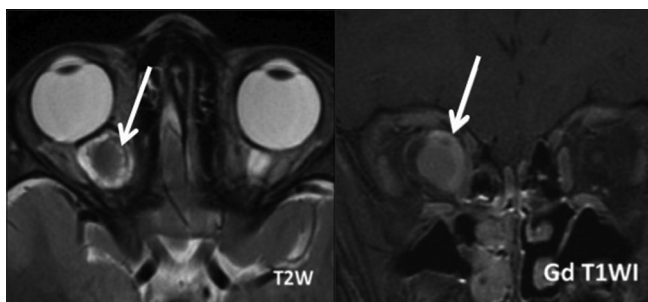


Figure 15: Tumors: Optic nerve glioma in a non-NF1 patient. Axial T2 fat-saturated and post-contrast T1 fat-saturated images show thickening with enhancement of right optic nerve. Perineural arachnoidal gliomatosis is also seen, which also shows enhancement (arrow)

is the commonest site of involvement. In NF1 group, the tumor infrequently extends beyond the optic pathway and the shape of the nerve and chiasma are preserved as compared to that in non-NF1 patients. Cystic component of the tumor is commonly seen in non-NF1 patients. Most of the patients with NF1 show stable tumor volume on follow-up, as compared to non-NF1 patients.^[58]

Imaging pearls

The tumor is isointense on T1 and iso- to-hyperintense on T2W images and shows variable contrast enhancement. On T2W images, it demonstrates central isointensity, with surrounding hyperintensity corresponding to perineural arachnoidal gliomatosis. The perineural arachnoidal gliomatosis may enhance with gadolinium administration. There is resultant fusiform enlargement of the nerve with the nerve indistinguishable from the tumor [Figures 15 and 16].

Optic nerve sheath meningioma

ONSM is the term applied either to i) primary meningioma which arises from meningoepithelial cap cells along the optic nerve from the globe to the prechiasmatic segment or to ii) secondary meningioma which is actually an extension from the cavernous sinus, clinoid process, pituitary fossa, planum sphenoidale, or olfactory groove. These are more common in middle-aged females or in children with neurofibromatosis 2.^[59]

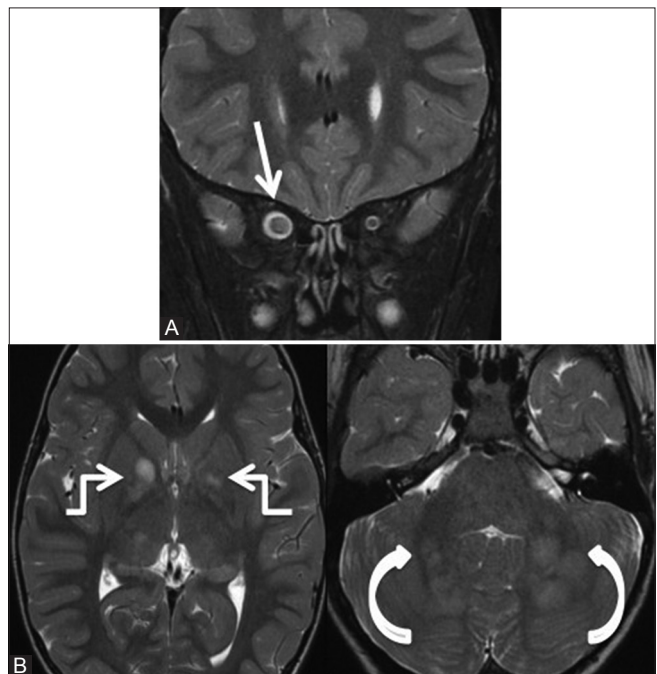


Figure 16 (A and B): Tumors: Optic nerve glioma in an NF1 patient. Coronal STIR (A) and axial T2W (B) images of a 7-year-old male with NF1 with mild decrease in vision on the right side show thickening and hyperintense signal in right optic nerve (arrow) suggestive of glioma. Hyperintense signal is seen in bilateral globus pallidi (elbow arrows), thalami, dorsal aspect of pons, and brachium pontis (curved arrows) due to spongiform changes seen in NF1

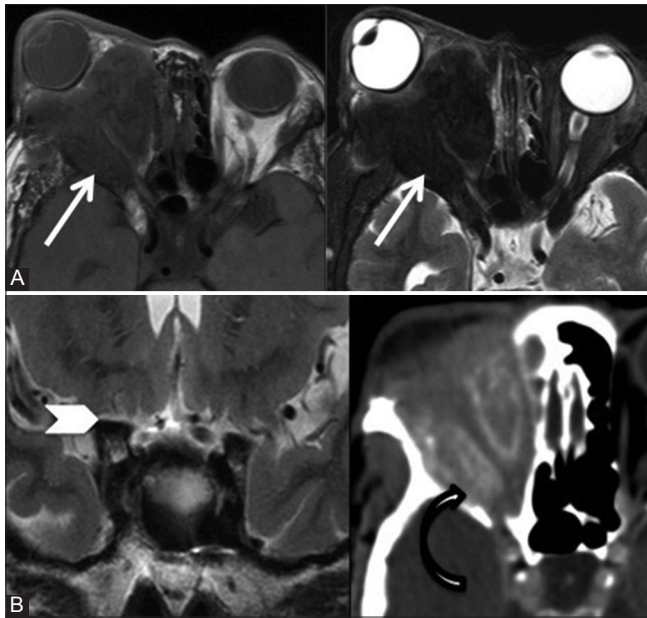


Figure 17 (A and B): Tumors: Optic nerve sheath meningioma: Axial T1 and T2 fat-saturated (A) and coronal T2W and CT scan (B) images of a 59-year-old female with right proptosis since 20 years and progressive loss of vision show T1-isointense and T2-hypointense soft tissue mass surrounding the optic nerve which shows calcification (curved arrow). Also note severe atrophy of prechiasmatic segment of right optic nerve (arrowhead) in the image

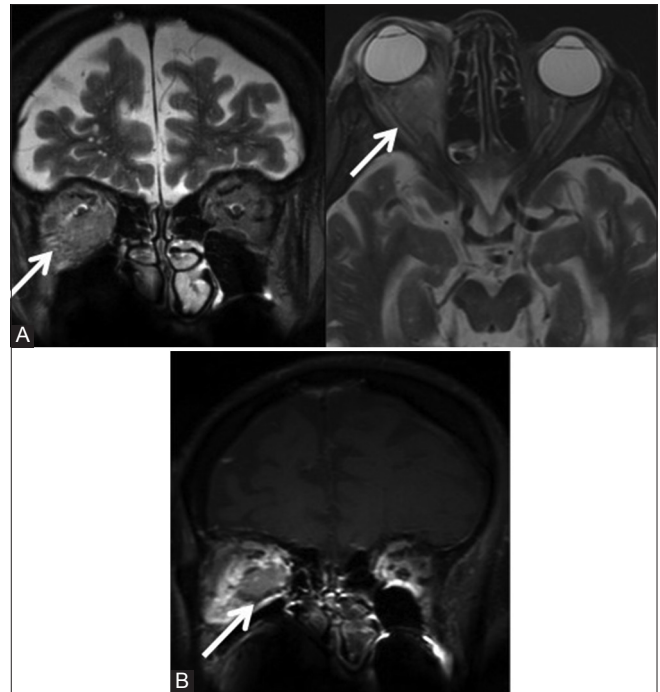


Figure 18 (A and B): Tumors: Coronal STIR, axial T2 fat-saturated (A) and coronal post-contrast T1 fat-saturated (B) images show an infiltrative soft tissue mass (arrow) in conal and intraconal compartment infiltrating the optic nerve in an 84-year-old male with metastatic plasmacytoma

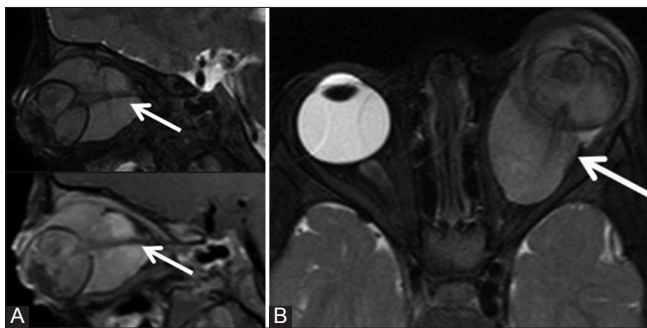


Figure 19 (A and B): Tumors: Retinoblastoma. Sagittal T2 fat-saturated and post-contrast T1 fat-saturated (A) and axial T2 fat-saturated (B) images of a 5-year-old boy show a large intensely enhancing tumor in the left globe with retrobulbar extension and infiltrating the optic nerve

Imaging pearls

These are iso- to hypointense on T1 and iso- to-hyperintense on T2W images with intense homogenous enhancement. The central hypointense, non-enhancing optic nerve results in the “ tram-track sign.” These tumors often show calcification [Figure 17] and adjacent bone hyperostosis or erosion. They appear plaque-like and grow linearly along the nerve sheath. They cause diffuse or segmental circumferential thickening of the optic nerve sheath.^[60]

Optic nerve can be separated from the tumor unlike optic nerve glioma. Posterior optic pathway may show atrophy. Other conditions showing tram-track sign include

sarcoidosis, periopic neuritis, orbital pseudotumor, periopic hemorrhage, metastases and leukemia/lymphoma, and Erdheim–Chester disease [Table 5].^[1,60,61]

Metastases

Metastases [Figures 18 and 19] to orbits are rare and when they occur, they usually involve the uveal tract. Isolated metastases to optic nerve are extremely uncommon; however, they are reported with carcinomas from breast, lung, gastrointestinal tract, etc. Radiologically, isolated metastatic optic nerve tumors appear similar to primary optic nerve tumors; however, history of previous malignancy is helpful.^[62]

Retinoblastoma is the most common tumor of globe in childhood. MRI is used to assess intraocular spread including invasion of the optic nerve, extraocular as well as intracranial extension. Inherited forms of retinoblastoma may be associated with primary tumors of the suprasellar or pineal region. Involvement of optic nerve or choroid infiltration is an important predictor of metastases in retinoblastoma [Figure 19]. Involvement of optic nerve beyond lamina cribrosa is associated with poor prognosis.^[63] MRI shows disruption of linear enhancement at choroidoretinal complex or thickening of enhancing choroidoretinal complex in prelaminar optic nerve involvement. Postlaminar optic nerve involvement is seen as focal optic nerve enhancement and/or thickening.^[63]

Table 5: Differential diagnosis for Tram-tract appearance of optic nerve

Diseases	Key features/orbital findings	Associated brain/Systemic findings
Optic nerve sheath meningioma	Tram-tract sign was first described with it Diffuse or segmental circumferential thickening of optic nerve sheath Tumor may show calcification and adjacent bony changes like hyperostosis/erosion	The intraorbital tumor may be extension from cavernous sinus, clinoid process, pituitary fossa, planum sphenoidale or olfactory groove
Perineuritis	Clinically mimics acute demyelinating optic neuritis, however MRI shows enhancement around rather than within the optic nerve. It can be idiopathic or secondary to tuberculosis, syphilis, sarcoidosis, Wegener's granulomatosis, giant cell arteritis	Wegener's granulomatosis: Cavitating lung nodules, masses in nasal cavities eroding nasal septum, cANCA+, Tuberculosis: Tuberculomas, leptomeningeal enhancement, Mantoux test positive Giant cell arteritis: Wall thickening and enhancement of superficial temporal arteries with adjacent fat standing
Pseudotumor	Acute presentation with proptosis, painful red eye. Along with enhancement of optic nerve sheath, other inflammatory findings of uveoscleral thickening, fat stranding in retrobulbar fat, fluid in tenon's space, enlargement of extraocular muscles may be seen. Dramatic response to steroid treatment	Extension into orbital fissure and cavernous sinus may be seen- Tolosa Hunt syndrome
Sarcoidosis	Associated orbital findings: Diffuse lacrimal gland enlargement with extra ocular muscle infiltration, eyelid and periorbital inflammation	Thickening and enhancement of cranial nerves especially optic nerves, Nodular leptomeningeal enhancement, intraparenchymal lesions, infundibular thickening with suprasellar mass, dural based enhancing T2 hypointense lesions
Periopic hemorrhage	Can be spontaneous or traumatic. Acute hemorrhage may not show any enhancement and appears hyperdense on CT scan. At later stages, it reveals peripheral enhancement. Clinical history is important	
Leukemia/lymphoma	Other than involvement of optic nerves, leukemia can present with an infiltrating mass involving eyelid, conal and intraconal structures or with leukemic retinopathy. Relapse occurs due to suboptimal penetration of chemotherapeutic drugs into orbit	Brain: Extradural enhancing lesions, parenchymal lesions or leukemic meningitis
Metastases	Usually history of primary malignancy is present Carcinomas from breast, lung, and gastrointestinal tract can metastasize to optic nerves Retinoblastoma may directly infiltrate optic nerve	Brain and systemic metastases
Erdheim Chester disease	Rare non-Langerhans's cell systemic xanthogranulomatosis. Orbital masses arise from optic nerve sheath	Brain lesions include T2 hypointense enhancing dural masses, intraparenchymal masses involving hypothalamus and pituitary infundibulum resulting in diabetes Insipidus. Other systems involved are appendicular skeleton, kidneys, lungs, retroperitoneum, heart, blood vessels and skin

Table 6: Blood supply of optic nerve

Optic nerve segments	Arteries
Optic nerve head	Superficial part: Branches of CRA Region around lamina cribrosa: Short posterior ciliary arteries or via circle of Zinn-Haller
Intraorbital segment (Resistant to ischemia)	Intraorbital segment is supplied by posterior ciliary arteries via pial network
Orbital apex	Collateral circulation by Middle meningeal artery
Intracanalicular segment (Prone to ischemia)	Anteriorly from collateral branches of OA and posteriorly from pial branches of ICA and superior hypophyseal arteries
Intracranial segment	Pial branches of ICA, superior hypophyseal, A1 segment of anterior cerebral and anterior communicating arteries

Ischemic Optic Neuropathy

Blood supply of optic nerve

Blood supply of the optic nerve is different for its four segments [Table 6]. Most of the optic nerve derives its blood supply from the OA, which is the first branch of supraclinoid

internal carotid artery (ICA). Occasionally, OA may have its origin from the middle meningeal artery due to enlargement of anastomoses between recurrent branch of lacrimal artery and orbital branch of middle meningeal artery, from the cavernous ICA, and rarely from the middle or anterior cerebral arteries. After its origin, OA enters the optic canal inferolateral to the optic nerve and is separated by a dural sheath. In intraorbital course, it crosses over (in 83%) or under (17%) the optic nerve to lie medial to the nerve. Further in orbit, it runs between the medial rectus and superior oblique muscles and lies close to anterior ethmoid foramen and medial orbital wall. It terminates at the superomedial angle of the orbit into supratrochlear and dorsal nasal branches. There is a wide variation in the branches of OA; however, its important branches in the orbit are two or three posterior ciliary arteries and a central retinal artery (CRA).^[64]

The superficial aspect of the optic nerve head is supplied by the branches of CRA, whereas the region around lamina cribrosa gets blood supply directly from the short posterior ciliary arteries or via circle of Zinn-Haller. Intraorbital segment is

supplied by posterior ciliary arteries via pial network. This segment is resistant to ischemia because of a plethora of pial vessels. Middle meningeal artery, branch of the external carotid artery forms collateral circulation at the orbital apex. Intracranial segment lies within the watershed zone and, hence, is prone to ischemia and vulnerable to shearing injuries in skull fracture. It derives blood supply anteriorly from the collateral branches of OA and posteriorly from the pial branches of ICA and superior hypophyseal arteries.

Intracranial segment is supplied by the pial branches of ICA, superior hypophyseal, A1 segment of anterior cerebral and anterior communicating arteries.^[65]

Anterior ischemic optic neuropathy

Anterior ischemic optic neuropathy (AION) occurs when ischemia/infarction involves optic disc. It results in acute painless monocular vision loss. Diagnosis is mainly clinical based on history, clinical examination, and fundoscopic findings of pallor/edema of the optic disc and peripapillary hemorrhage. Imaging plays no role in its diagnosis. However, MRI may be necessary in cases of significant pain with eye movement to exclude ON or MS, in patients with atypical course, i.e. with prolonged disc edema or progressive and/or recurrent visual loss more than 2 months after their initial presentation to exclude inflammatory or compressive lesions.

AION can be:

- Arteritic AION: Occurs due to blood vessel inflammation, most commonly from giant cell arteritis. Other causes include polyarteritis nodosa, Wegener's granulomatosis, connective tissue diseases such as SLE, Churg-Strauss syndrome, and rheumatoid arthritis
- Nonarteritic AION: Seen in association with

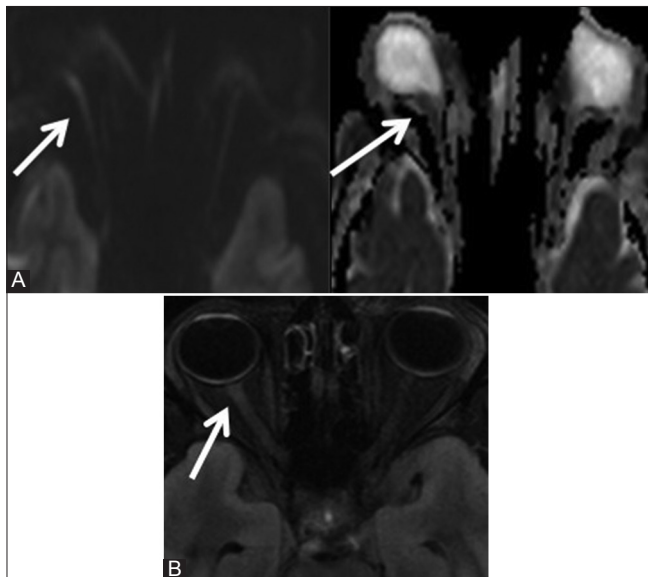


Figure 20 (A and B): Ischemic: DWI (A) and FLAIR (B) images of a 45-year-old female with sudden loss of right vision after cholecystectomy surgery 4 days back show restricted diffusion in right optic nerve (arrow) with hyperintense signal on FLAIR image

hypertension, diabetes mellitus, myocardial infarction, and hypercholesterolemia.^[66]

Posterior ischemic optic neuropathy

Posterior ischemic optic neuropathy (PION) involves the optic nerve and/or optic chiasma. Color vision loss is the presenting symptom. It is seen in the perioperative period following cardiac surgery, spine surgeries, and major abdominal surgeries. It may be associated with hypertension, diabetes mellitus, myocardial infarction, and hypercholesterolemia.

Diagnosis is by MRI, especially DWI, which shows restricted diffusion [Figure 20].^[67]

Miscellaneous Causes

Idiopathic intracranial hypertension

It is characterized by elevated CSF pressure and papilledema without focal neurological deficit. It is mostly seen in middle-aged females and is a diagnosis of exclusion.^[68]

Imaging pearls

MRI shows perioptic nerve sheath distention, posterior flattening of globe and optic nerve head protrusion, vertical buckling of the optic nerves, empty sella or partially empty sella, narrowing and decreased flow in dural sinuses (usually in transverse sinuses), which normalize after reduction in CSF pressure. Small meningoceles may often be seen [Figures 21 and 22].

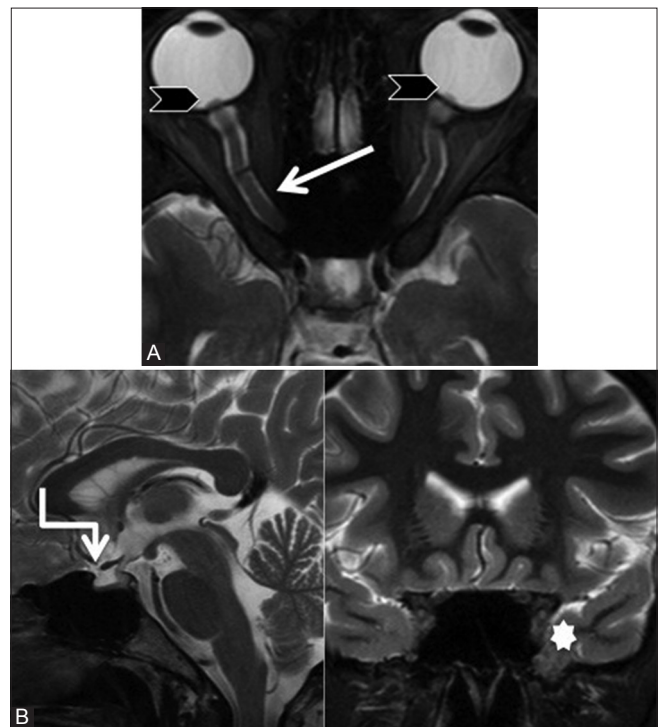

Figure 21 (A and B): Idiopathic intracranial hypertension. Axial (A) sagittal and coronal (B) T2 fat-saturated images of a 26-year-old female with blurring of vision and b/l papilledema show perioptic nerve sheath distention, flattening of posterior globe, and optic nerve head protrusion (arrowhead). Partial empty sella (elbow arrow) and meningoencephalocele are seen at left foramen rotundum (star)

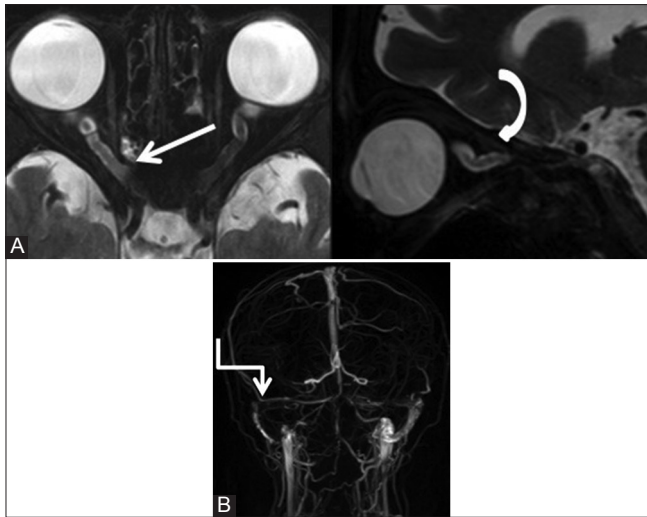


Figure 22 (A and B): Idiopathic intracranial hypertension. Axial and sagittal T2 fat-saturated (A) images with peri-optic nerve sheath distention (arrow) and vertical tortuosity of the optic nerves (curved arrow). MR venography (B) images show narrowing at the distal transverse sinuses on both the sides (elbow arrow)

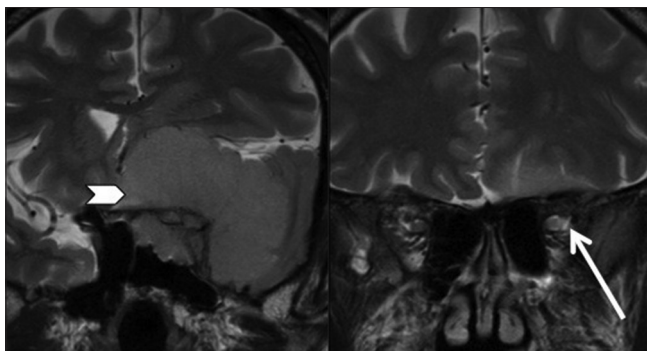


Figure 24: Compressive optic neuropathy: Tumors. Coronal STIR images of a 55-year-old male show infiltration of left optic nerve due to large sphenoid wing meningioma (arrowhead). Intraorbital left optic nerve shows hyperintense signal (arrow)

Secondary compressive optic atrophy

Tumor

The common tumors compressing prechiasmatic optic nerve and chiasma are: Pituitary macroadenoma [Figure 23], meningioma in adults [Figure 24], craniopharyngioma, and gliomas of visual pathway in children. These cause gradual and progressive loss of vision. It is important to mention whether the optic chiasm is prefixed or postfixed. Pituitary/tuberculum sellae lesions are more likely to compress prefixed chiasm than postfixed chiasm.^[69] Prefixed chiasm or prominent tuberculum sellae limits the access to suprasellar area in transcranial approach.^[70]

Other sellar/parasellar lesions include ICA aneurysm in adults. Intraorbital tumors like lymphangioma [Figure 25], hemangioma, and dermoid cysts can also compress the intraorbital optic nerve resulting in atrophy.

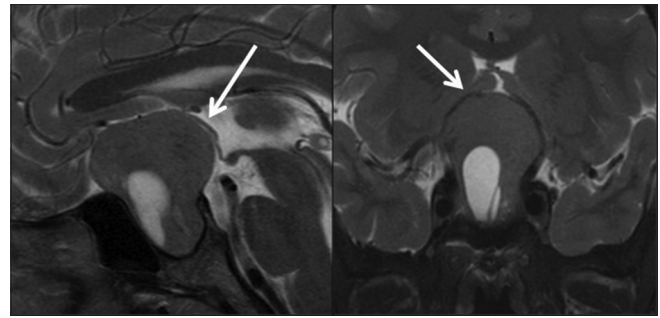


Figure 23: Compressive optic neuropathy: Tumors. Sagittal and coronal T2 fat-saturated images of a 60-year-old male with bitemporal hemianopsia show a large sellar-suprasellar mass with pituitary gland not seen separately. The lesion elevates and compresses the prechiasmatic optic nerves and optic chiasma (arrow)

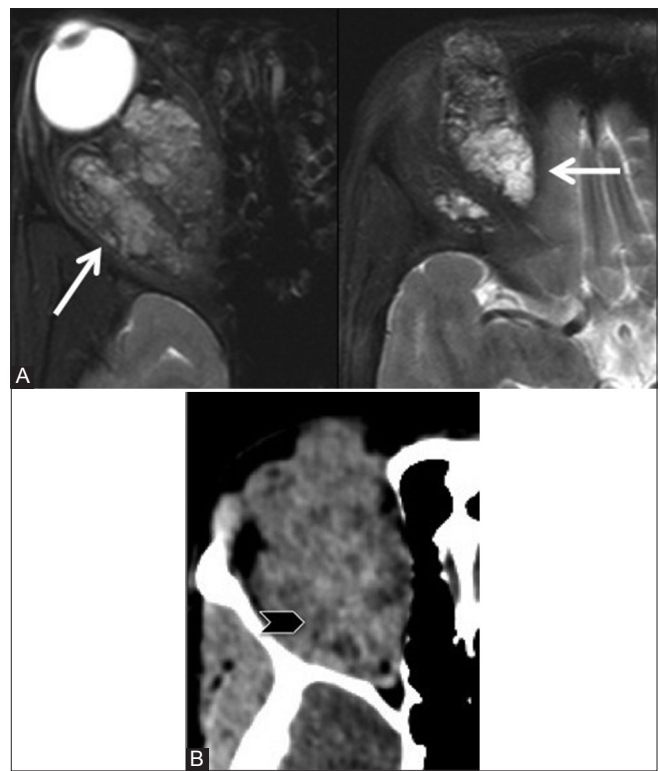


Figure 25 (A and B): Compressive optic neuropathy: Venolymphatic malformation. Axial T2 fat-saturated (A) images of a 12-year-old girl with proptosis and decreased right vision showing an encapsulated, diffuse multicompartmental T2-heterogeneous lesion with fluid-fluid levels (arrow) suggestive of venolymphatic malformation. On CT scan (B) the lesion shows minimal heterogeneous post-contrast enhancement (arrowhead)

Thyroid orbitopathy

It is characterized by fusiform enlargement of extraocular muscles with sparing of its tendinous insertions and increase in orbital fat volume resulting in compression of optic nerve at the orbital apex [Figure 26]. Inferior and medial recti are most commonly involved followed by lateral and superior recti muscles. Involvement may be symmetrical or asymmetrical, but is usually bilateral. Other findings include proptosis, bony changes in lamina

papyracea with bowing due to muscle pressure, lacrimal gland displacement and enlargement, and superior ophthalmic vein dilatation.^[71] Surgical decompression may be needed when the optic nerve is compressed.

Vascular

Optic pathway compression can rarely occur due to tortuous vessels, resulting in visual loss and optic atrophy [Figure 27]. The symptoms occur due to direct pressure compression and/or ischemia secondary to occlusion of small arterial supply branches. Visual loss is usually mild and slowly progressive. Most patients are elderly with other forms of vascular disease. It is managed conservatively; however, occasionally surgical intervention may be required when there is rapid progression.^[72]

Progressive visual loss due to optic nerve compression can also occur with ophthalmic segment carotid artery aneurysms (carotid-ophthalmic aneurysms). These aneurysms may be asymptomatic or occasionally may cause proptosis.

Ophthalmic segment of ICA gives rise to two branches – OA and superior hypophyseal artery. OA aneurysms arise from ICA, just distal to the origin of OA, point superiorly

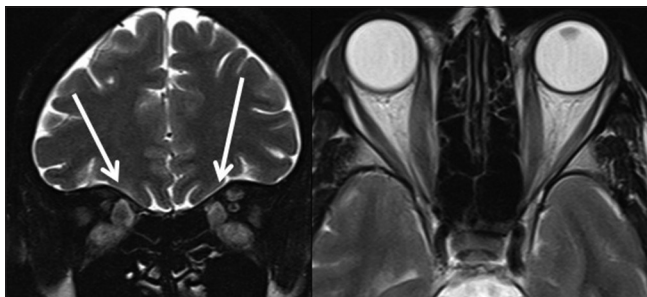


Figure 26: Compressive optic neuropathy: Thyroid orbitopathy. Coronal STIR and axial T2W images of a 50-year-old female with diplopia show thickened and hyperintense signal in both medial and inferior recti muscles (arrow) resulting in compression of optic nerve at the orbital apex (arrowhead)

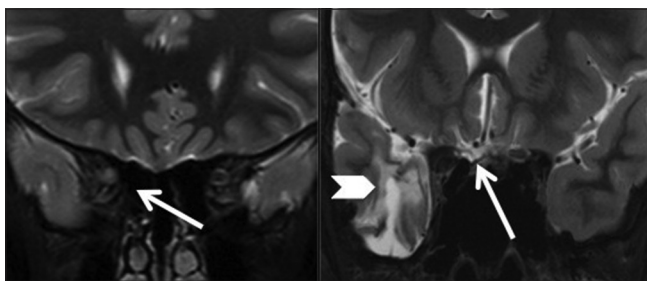


Figure 28: Traumatic optic neuropathy. Coronal STIR images of a 23-year-old male with loss of right vision following trauma show signal in intracanalicular segment of the right optic nerve with severe atrophy of prechiasmatic segment (arrow). Gliosis is also seen in the right temporal lobe (arrowhead)

or superomedially, and typically displace the optic nerve superomedially. Anatomic variations in OA origin as mentioned above are important when embolization or surgery is planned.^[73]

Superior hypophyseal artery aneurysms arise above the dural ring from the medial bend of ICA. These aneurysms are located medial to ICA and can extend beneath the chiasm (suprasellar variant) or extend anteriorly beneath anterior clinoid process (paraclinoid variant). Preoperative differentiation helps the surgeon in achieving low operative and visual morbidity.^[74]

Traumatic optic neuropathy

Injury can be direct when the optic nerve fibers are anatomically disrupted due to penetrating trauma or due to fracture fragments in optic canal or optic nerve sheath hematomas associated with craniofacial trauma. CT scan of the orbit is recommended to visualize small fracture fragments and acute orbital/intracranial hemorrhages. Indirect injury occurs due to transmission of forces to the optic canal from blunt trauma. Road traffic accidents are the most common causes of traumatic optic neuropathy [Figure 28].^[75] The condition can sometimes

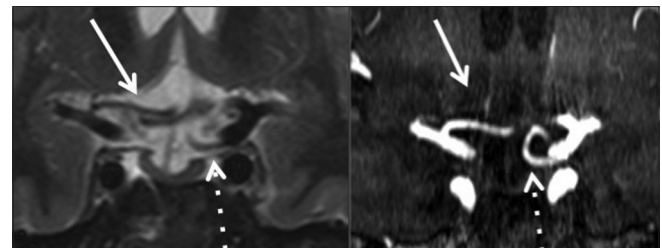


Figure 27: Compressive optic neuropathy: Vascular. Coronal STIR and MR angiography images of a 59-year-old male with gradual diminishing vision in both eyes show compression of optic chiasma by right A1 segment superiorly (arrow) and by left PCOM from the inferior aspect (dotted arrow) resulting in distortion of chiasma

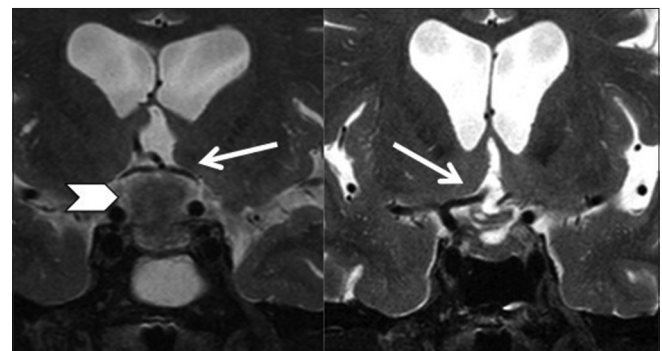


Figure 29: Traumatic optic neuropathy. Preoperative scan showing tuberculum sella meningioma (arrowhead) and elevation of optic chiasma (arrow) in a 68-year-old male with bitemporal hemianopsia. Postoperative scan shows gliosis of optic chiasma (right > left). Postoperatively, the patient had complete right monocular vision loss with severe reduction in left vision

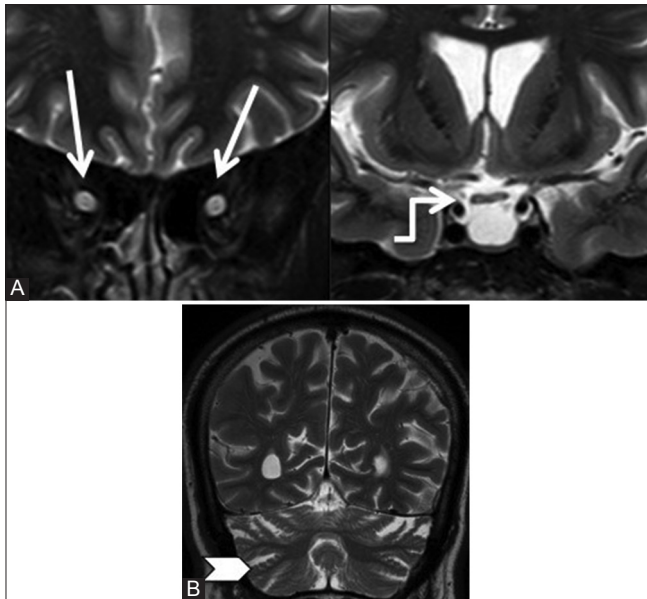


Figure 30 (A and B): Toxic (alcohol) optic neuropathy. Coronal STIR (A) images of a 42-year-old alcoholic male with gradual loss of vision for 6 months showing hyperintense signal with atrophy of both optic nerves (arrow) and chiasma (elbow arrow). Also note on coronal T2W (B) image the prominence of cerebellar fissures (arrowhead) and cortical sulci suggestive of atrophy

occur secondary to surgery when the optic nerve or chiasma is located close to the tumor [Figure 29].

Toxic optic neuropathy

Various toxins affect the optic nerves resulting in visual problems [Figure 30]. The common toxins include ethanol, methanol, ethylene glycol, tobacco, and drugs like ethambutol, isoniazid, chloroquine, quinine, sulfonamides, linezolid, amiodarone, and digitalis.

The diagnosis is often delayed when optic nerve pallor has already set in and vision is severely affected. These usually cause central or cecentral scotomas due to selective involvement of maculopapillary bundle. With tobacco-alcohol amblyopia, genetic and nutritional factors like deficiency of vitamin B complex increase the susceptibility of injury to the optic nerves.^[76]

Intraocular pathologies resulting in optic nerve atrophy

Glaucoma is associated with elevated intraocular pressure and affects the intraocular segment of the optic nerve; phthisis bulbi, etc., can also result in optic atrophy [Figure 31].

Conclusion

Various pathologies affect the optic nerves, either isolated or associated with intracranial abnormalities. A clear understanding of MR imaging protocols, key anatomical structures, onset of symptoms, along with familiarity with various pathologies is fundamental for a radiologist to arrive

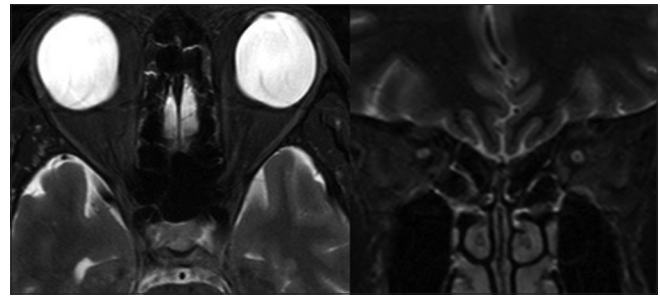


Figure 31: Intraocular pathology resulting in optic nerve atrophy. Axial T2 fat-saturated and coronal STIR images show bupthalmos (arrowhead) due to high myopia with bilateral optic nerve signal and optic atrophy (arrow)

at an accurate diagnosis and guide the referring clinician in patient care.

References

1. Grainger RG, Allison DJ, Dixon AK. Grainger and Allison's Diagnostic Radiology: A Textbook of Medical Imaging: 5th ed. Philadelphia: Elsevier Churchill Livingstone; 2001. p. 1395.
2. Montaleone P. The optic nerve: A clinical perspective. *Univ West Ont Med J* 2010;79:37-9.
3. Campbell WW, DeJong RN, Haerer AF. DeJong's the Neurologic Examination. 6th ed. Philadelphia: Lippincott Williams and Wilkins; 2005. p. 120.
4. Griessenauer CJ, Raborn J, Mortazavi MM, Tubbs RS, Cohen-Gadol AA. Relationship between the pituitary stalk angle in prefixed, normal, and postfixed optic chiasmata: An anatomic study with microsurgical application. *Acta Neurochir (Wien)* 2014;156:147-51.
5. Razeq AA, Elkhamary S. MRI of retinoblastoma. *Br J Radiol* 2011;84:775-84.
6. Mafee MF, Rapoport M, Karimi A, Ansari SA, Shah J. Orbital and ocular imaging using 3- and 1.5-T MR imaging systems. *Neuroimaging Clin N Am* 2005;15:1-21.
7. Brodsky MC. Anomalies of the optic disc. In: Miller NR, Newman NJ, editors. *Walsh and Hoyt's Clinical Neuro-Ophthalmology*. Vol. 1. 5th ed. Baltimore: Williams and Wilkins; 1998. p. 799-800.
8. Brodsky MC. Congenital optic disc anomalies. In: Taylor D, Hoyt G, editors. *Pediatric Ophthalmology and Strabismus*. 3rd ed. Edinburgh: Elsevier-Saunders; 2005. p. 637-8.
9. Azuma N, Yamaguchi Y, Handa H, Tadokoro K, Asaka A, Kawase E, *et al*. Mutations of the PAX6 gene detected in patients with a variety of optic-nerve malformations. *Am J Hum Genet* 2003;72:1565-70.
10. Denis D, Girard N, Levy-Mozziconacci A, Berbis J, Matonti F. Ocular coloboma and results of brain MRI: Preliminary results. *J Fr Ophthalmol* 2013;36:210-20.
11. Kalra VB, Gilbert JW, Levin F, Malhotra A. Spectrum of MRI findings in morning glory syndrome. *Neurographics* 2014;4:56-60.
12. Ellika S, Robson CD, Heidary G, Paldino MJ. Morning glory disc anomaly: Characteristic MR imaging findings. *AJNR Am J Neuroradiol* 2013;34:2010-4.
13. Borchert M, Garcia-Filion P. The syndrome of optic nerve hypoplasia. *Curr Neurol Neurosci Rep* 2008;8:395-403.
14. Haddad NG, Eugster EA. Hypopituitarism and neurodevelopmental abnormalities in relation to central nervous system structural defects in children with optic nerve hypoplasia. *J Pediatr Endocrinol Metab* 2005;18:853-8.

15. Kelberman D, Dattani MT. Genetics of septo-optic dysplasia. *Pituitary* 2007;10:393-407.
16. Webb EA, Dattani MT. Septo-optic dysplasia. *Eur J Hum Genet* 2010;18:393-7.
17. Al-Senawi R, Al-Jabri B, Al-Zuhaibi S, Al-Azri F, Al-Yarubi S, Harikrishna B, *et al.* Septo-optic dysplasia complex: Clinical and radiological manifestations in Omani children. *Oman J Ophthalmol* 2013;6:193-8.
18. Dempsey MA, Torres-Martinez W, Walsh LE. Two cases further delineating the Sakoda complex. *Am J Med Genet A* 2007;143A: 370-6.
19. Yu-Wai-Man P, Chinnery PF. Leber hereditary optic neuropathy. In: Pagon RA, Adam MP, Ardinger HH, Bird TD, Dolan CR, Fong CT, *et al.*, editors. *GeneReviews*[®]. Seattle, WA: University of Washington; 1993-2015. .
20. Viswanathan V, Medempudi S, Kadiri M. Wolfram syndrome. *J Assoc Physicians India* 2008;56:197-9.
21. Hittmair K, Wimberger D, Wiesbauer P, Zehetmayer M, Budka H. Early infantile form of Krabbe disease with optic hypertrophy: Serial MR examinations and autopsy correlation. *AJNR Am J Neuroradiol* 1994;15:1454-8.
22. Bernal OG, Lenn N. Multiple cranial nerve enhancement in early infantile Krabbe's disease. *Neurology* 2000;54:2348-9.
23. Jones BV, Barron TF, Towfighi J. Optic nerve enlargement in Krabbe's disease. *AJNR Am J Neuroradiol* 1999;20:1228-31.
24. Shetty SB, Mehta C. Langerhans cell histiocytosis of the orbit. *Indian J Ophthalmol* 2001;49:267-8.
25. Zimmerman LE. Ocular lesions of juvenile xanthogranuloma. Nevoxanthoendothelioma. *Am J Ophthalmol* 1965;69:1011-35.
26. Miller NR. Primary tumours of the optic nerve and its sheath. *Eye (Lond)* 2004;18:1026-37.
27. Lin YC, Wang AG, Yen MY, Hsu WM. Leukaemic infiltration of the optic nerve as the initial manifestation of leukaemic relapse. *Eye (Lond)* 2004;18:546-50.
28. Jacquemin C, Bosley TM, Liu D, Svedberg H, Buhaliqa A. Reassessment of sphenoid dysplasia associated with neurofibromatosis type 1. *AJNR Am J Neuroradiol* 2002;23:644-8.
29. Jacquemin C, Bosley TM, Svedberg H. Orbit deformities in craniofacial neurofibromatosis type 1. *AJNR Am J Neuroradiol* 2003;24:1678-82.
30. Osborn A. *Diagnostic Neuroradiology*. 4th ed. St.Louis, Missouri: Mosby; 1994. p. 72-84.
31. Beck RW, Trobe JD, Moke PS, Gal RL, Bhatti MT, *et al.* High- and low-risk profiles for the development of multiple sclerosis within 10 years after optic neuritis: Experience of the optic neuritis treatment trial. *Arch Ophthalmol* 2003;121:944-9.
32. Beck RW, Smith CH, Gal RL, Xing D, Bhatti MT, Brodsky MC, *et al.*; Optic Neuritis Study Group. Neurologic impairment 10 years after optic neuritis. *Arch Neurol* 2004;61:1386-9.
33. Cleary PA, Beck RW, Anderson MM Jr, Kenny DJ, Backlund J, Gilbert PR. Design, methods, and conduct of the Optic Neuritis Treatment Trial. *Control Clin Trials* 1993;14:123-42.
34. Plant GT, Sibtain NA, Thomas D. Hyperacute corticosteroid treatment of optic neuritis at the onset of pain may prevent visual loss: A case series. *Mult Scler Int* 2011;2011:815068.
35. Beck RW, Trobe JD. What we have learned from Optic Neuritis Treatment Trial. *Ophthalmology* 1995;102:1504-8.
36. Cohen JA. Emerging therapies for relapsing multiple sclerosis. *Arch Neurol* 2009;66:821-8.
37. Osborne BJ, Volpe NJ. Optic neuritis and risk of MS: Differential diagnosis and management. *Cleve Clin J Med* 2009;76:181-90.
38. Levin LA, Lessell S. Risk of multiple sclerosis after optic neuritis. *JAMA* 2003;290:403-4.
39. Visual function 5 years after optic neuritis: Experience of the Optic Neuritis Treatment Trial. The Optic Neuritis Study Group. *Arch Ophthalmol* 1997;115:1545-52.
40. Sapuan S, Basri H. Acute disseminated encephalomyelitis (ADEM) presenting with bilateral optic neuritis. *Malays J Med Sci* 2007;14:71-4.
41. Gean-Marton AD, Vezina LG, Marton KI, Stimac GK, Peyster RG, Taveras JM, *et al.* Abnormal corpus callosum: A sensitive and specific indicator of multiple sclerosis. *Radiology* 1991;180:215-21.
42. Kazi AZ, Joshi PC, Kelkar AB, Mahajan MS, Ghawate AS. MRI evaluation of pathologies affecting the corpus callosum: A pictorial essay. *Indian J Radiol Imaging* 2013;23:321-32.
43. Wingerchuk DM, Lennon VA, Lucchinetti CF, Pittock SJ, Weinshenker BG. The spectrum of neuromyelitis optica. *The Lancet Neurology* 2007;6:805-15.
44. Kim W, Kim SH, Huh SY, Kim HJ. Brain abnormalities in neuromyelitis optica spectrum disorder. *Mult Scler Int* 2012;2012:735486.
45. Purvin V, Kawasaki A, Jacobson DM. Optic perineuritis: Clinical and radiographic features. *Arch Ophthalmol* 2001;119:1299-306.
46. Raghobi A, Hitam WH, Noor RA, Embong Z. Optic perineuritis secondary to tuberculosis: A rare case presentation. *Asian Pac J Trop Biomed* 2012;2(Suppl 2):S1206-8.
47. Purvin V, Kawasaki A. Optic perineuritis secondary to Wegener's granulomatosis. *Clin Experiment Ophthalmol* 2009;37:712-7.
48. Parker SE, Pula JH. Neurosyphilis presenting as asymptomatic optic perineuritis. *Case Rep Ophthalmol Med* 2012;2012:621872.
49. Osman SS, Ahem A. Value of MRI in diagnosis of giant cell arteritis. *Neurol Asia* 2012;17:369-72.
50. Huchzermeyer C, Mardin C, Holbach L, Zwerina J, Schett G, Rech J. Successful remission induction with a combination therapy of rituximab, cyclophosphamide, and steroids in a patient with refractory optic neuritis in Wegener's granulomatosis. *Clin Rheumatol* 2013;32(Suppl 1):S97-101.
51. Agbogu BN, Stern BJ, Sewell C, Yang G. Therapeutic considerations in patients with refractory neurosarcoidosis. *Arch Neurol* 1995;52:875-9.
52. Yu-Wai-Man P, Crompton DE, Graham JY, Black FM, Dayan MR. Optic perineuritis as a rare initial presentation of sarcoidosis. *Clin Experiment Ophthalmol* 2007;35:682-4.
53. Palejwala H, Walia H, Yeh S. Ocular manifestations of systemic lupus erythematosus: A review of the literature. *Autoimmune Dis* 2012;2012:290898.
54. Lin YC, Wang AG, Yen MY. Systemic lupus erythematosus-associated optic neuritis: Clinical experience and literature review. *Acta Ophthalmol* 2009;87:204-10.
55. Chaudhry IA, Shamsi FA, Arat YO, Riley FC. Orbital pseudotumor: Distinct diagnostic features and management. *Middle East Afr J Ophthalmol* 2008;15:17-27.
56. Shah R, Roberson GH, Curé JK. Correlation of MR imaging findings and clinical manifestations in neurosarcoidosis. *AJNR Am J Neuroradiol* 2009;30:953-61.
57. Smith JK, Matheus MG, Castillo M. Imaging manifestations of neurosarcoidosis. *AJR Am J Roentgenol* 2004;182:289-95.
58. Kornreich L, Blaser S, Schwarz M, Shuper A, Vishne TH, Cohen IJ, *et al.* Optic pathway glioma: Correlation of imaging findings with the presence of neurofibromatosis. *AJNR Am J Neuroradiol* 2001;22:1963-9.
59. Turbin RE, Pokorny K. Diagnosis and treatment of orbital optic nerve sheath meningioma. *Cancer Control* 2004;11:334-41.
60. Kanamalla US. The optic nerve tram-track sign. *Radiology* 2003;27:718-9.

61. Johnson MD, Aulino JP, Jagasia M, Mawn LA. Erdheim-Chester disease mimicking multiple meningiomas syndrome. *AJNR Am J Neuroradiol* 2004;25:134-7.
62. Fox B, Pacheco P, DeMonte F. Carcinoma of the breast metastatic to the optic nerve mimicking an optic nerve sheath meningioma: Case report and review of the literature. *Skull Base* 2005;15:281-9.
63. Rauschecker AM, Patel CV, Yeom KW, Eisenhut CA, Gawande RS, O'Brien JM, *et al.* High-resolution MR imaging of the orbit in patients with retinoblastoma. *Radiographics* 2012;32:1307-26.
64. Hayreh SS. Orbital vascular anatomy. *Eye (Lond)* 2006;20:1130-44.
65. Miller NR, Newman NJ, Bioussé V, Kerrison JB. Walsh and Hoyt's Clinical Neuro-Ophthalmology. 6th ed. Philadelphia: Lippincott Williams and Wilkins; 2005. p. 30-32.
66. Al-Shafai LS, Mikulis DJ. Diffusion MR imaging in a case of acute ischemic optic neuropathy. *AJNR Am J Neuroradiol* 2006;27:255-7.
67. Srinivasan S, Moorthy S, Sreekumar K, Kulkarni C. Diffusion-weighted MRI in acute posterior ischemic optic neuropathy. *Indian J Radiol Imaging* 2012;22:106-7.
68. Degnan AJ, Levy LM. Pseudotumor cerebri: Brief review of clinical syndrome and imaging findings. *AJNR Am J Neuroradiol* 2011;32:1986-93.
69. Naheedy MH, Haag JR, Azar-Kia B, Mafee MF, Elias DA. MRI and CT of sellar and parasellar disorders. *Radio Clin North Am* 1987;25:819-47.
70. Gulsen S, Dinc AH, Unal M, Cantürk N, Altınors N. Characterization of the anatomic location of the pituitary stalk and its relationship to the dorsum sellae, tuberculum sellae and chiasmatic cistern. *J Korean Neurosurg Soc* 2010;47:169-73.
71. Gonçalves AC, Gebrim EM, Monteiro ML. Imaging studies for diagnosing Graves' orbitopathy and dysthyroid optic neuropathy. *Clinics (Sao Paulo)* 2012;67:1327-34.
72. Purvin V, Kawasaki A, Zeldes S. Dolichoectatic arterial compression of the anterior visual pathways: Neuro-ophthalmic features and clinical course. *J Neurol Neurosurg Psychiatry* 2004;75:27-32.
73. Piché SL, Haw CS, Redekop GJ, Heran MK. Rare intracranial ophthalmic aneurysm: Endovascular treatment and review of the literature. *AJNR Am J Neuroradiol* 2005;26:1929-31.
74. Day AL. Aneurysms of the ophthalmic segment. A clinical and anatomical analysis. *J Neurosurg* 1990;72:677-91.
75. Zoumalan CI, Kim JW, Gigantelli JW, Ramadan HH, Talavera F, Batuello SG, *et al.* Traumatic Optic Neuropathy Treatment and Management. Available from: <http://www.emedicine.medscape.com/article/868129>. [Last accessed on 10th Oct 2014].
76. Behbehani R. Clinical approach to optic neuropathies. *Clin Ophthalmol* 2007;1:233-46.

Cite this article as: Gala F. Magnetic resonance imaging of optic nerve. *Indian J Radiol Imaging* 2015;25:421-38.

Source of Support: Nil, **Conflict of Interest:** None declared.