



Contents lists available at ScienceDirect

International Journal of Surgery Case Reports

journal homepage: www.casereports.com

A Case Series of diffuse large B-cell lymphoma and burkitt lymphoma presenting with peritoneal lymphomatosis



Everardo Flores, Nail Aydin (MD)*, Duy Vu, Subhasis Misra (MD)

Department of Surgery, Texas Tech University Health Sciences Center, 1400 South Coulter Street, Amarillo, TX, 79106-1786, USA

ARTICLE INFO

Article history:

Received 15 June 2016

Received in revised form 3 October 2016

Accepted 3 October 2016

Available online 8 October 2016

Keywords:

Non-Hodgkin lymphoma

Diffuse large B-cell lymphoma

Burkitt lymphoma

Peritoneal lymphomatosis

ABSTRACT

INTRODUCTION: Non-Hodgkin lymphoma (NHL) can occur at any site of the body, however diffuse and extensive involvement of the peritoneal cavity occurs rarely. Diffuse large B-cell lymphoma (DLBCL) is one of the dominant histological subtypes in extra nodal lymphoma involving the peritoneal cavity while Burkitt lymphoma is seen less commonly. We report two cases of DLBCL and one case of Burkitt lymphoma presenting with peritoneal lymphomatosis (PL).

PRESENTATION OF CASE: A retrospective review of two cases involving DLBCL and one case of Burkitt lymphoma with PL was conducted. Findings in all patients were consistent with peritoneal carcinomatosis at initial evaluation. Symptoms included longstanding vague abdominal pain and weight loss. CT imaging along with biopsies showed DLBCL in two cases and Burkitt lymphoma in one case. All three patients were treated with chemotherapy and responded very well.

DISCUSSION: We report three cases of non-Hodgkin lymphoma presenting with peritoneal lymphomatosis, a rare phenomena. Due to its nonspecific presentation, laparoscopic biopsies with subsequent pathology analysis should be undertaken as quickly and efficiently as possible to accurate diagnose and treat this condition.

CONCLUSION: DLBCL with PL may have variable and non-specific presentations. It may resemble peritoneal carcinomatosis or other neoplastic and inflammatory conditions. Focused clinical awareness, high level of suspicion, and complementary approach can lead towards accurate diagnosis. Diagnostic laparoscopy plays a crucial role in facilitating diagnosis and treatment.

© 2016 The Author(s). Published by Elsevier Ltd on behalf of IJS Publishing Group Ltd. This is an open access article under the CC BY-NC-ND license (<http://creativecommons.org/licenses/by-nc-nd/4.0/>).

1. Introduction

In the United States, the incidence rate of non-Hodgkin lymphoma (NHL) for adults was 19.7 per 100,000 per year with a total of 549,625 patients living with NHL [1]. The gastrointestinal (GI) tract is the most common extranodal organ system that is affected [2,3], however involvement of the peritoneum occurs only very rarely [4,5]. Of the 60 subtypes of NHL [6], diffuse large B-cell lymphoma (DLBCL) is the most common [7,8] with Burkitt lymphoma presenting as one of the least common [1]. DLBCL is predominantly seen as one ages [7,9] with the majority of individuals being diagnosed between ages 50–70 [1]. Like in DLBCL, Burkitt lymphoma has a higher predilection for males than females but a bimodal age of distribution is seen with an initial peak in the adolescent years and the subsequent peak in middle adulthood [7,9]. Both of these subtypes of NHL present with similar symptoms such as abdominal

pain, fever, fatigue, night sweats, and weight loss. These symptoms are nonspecific as they may also occur in various other cancers as well as in nonmalignant infectious or inflammatory conditions. Appropriate workup is thus necessary to facilitate quick and efficient diagnosis of the presenting patient and to effectively manage and treat the condition. (Figs 1–3)

2. Presentation of case

Case #1: A 29-year-old male presented with nausea, vomiting, diarrhea, abdominal pain localized in the upper abdomen, weight loss of 10–15 pounds within the three weeks of presentation, and increased sweating particularly in the evenings, which were all preceded by diplopia. Vitals were within normal physiological limits except for an O₂ saturation of 92%. Abdominal examination showed epigastric tenderness with moderated abdominal distension and occasional high-pitched bowel sounds. Decreased inward gaze of the left eye along with miosis was noted. The remainder of the physical exam was normal along with laboratory values except for a white blood cell count of 12,800/mm³ and a platelet count of 582,000/mm³. CT imaging of the abdomen and pelvis showed irregular thickening of the gastric wall with involvement of the body

* Corresponding author.

E-mail addresses: everardo.flores@ttuhsc.edu (E. Flores), nail.aydin@ttuhsc.edu, naydin@icloud.com, nailaydin@gmail.com (N. Aydin), duy.vu@ttuhsc.edu (D. Vu), subhasis.misra@ttuhsc.edu (S. Misra).

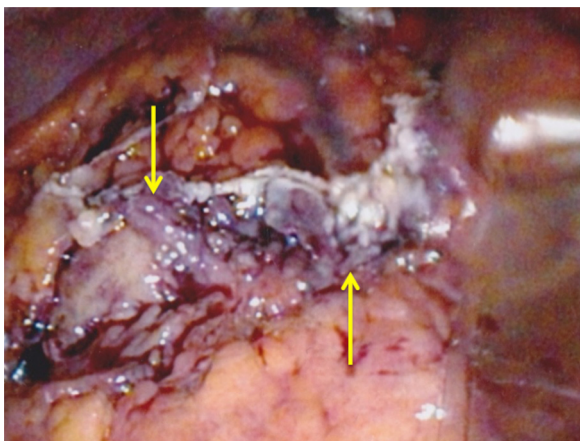


Fig. 1. Arrows showing omental caking with hemorrhage in case 1.

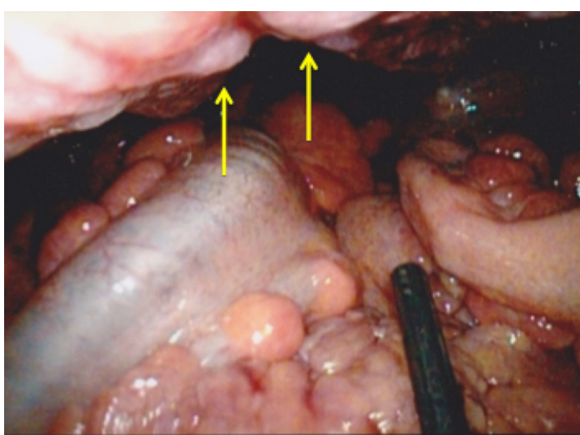


Fig. 2. Arrows showing peritoneal nodules in case 1.

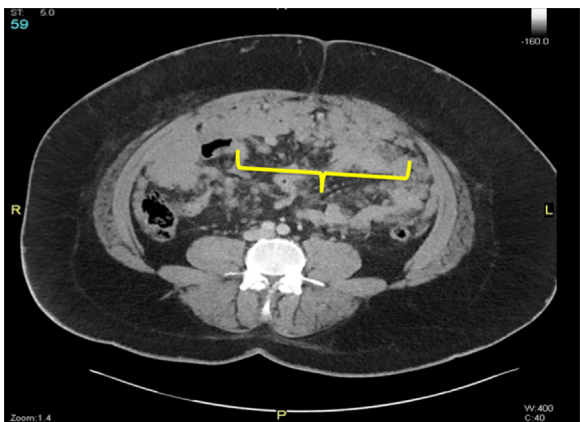

Fig. 3. Arrows showing extensive infiltrate and nodules within the peritoneum and omentum in case 2.

and antrum, an exophytic mass at the gastric fundus, and extensive nodularity on the omentum. An esophagogastroduodenoscopy (EGD) showed an ulcerative tumor at the distal stomach. Subsequent biopsy undertaken showed high-grade malignant B-cell NHL – DLBCL or Burkitt lymphoma. Immunohistochemistry staining showed: pankeratin-, CD20+, CD10+, MUM1+, BCL6+, BCL2-, CD3+, CD5+, EBER ISH-, and Ki67 near 100%. Laparoscopy with biopsy conducted verified c-MYC translocation confirming Burkitt lymphoma. Other procedures included a CT guided bone marrow biopsy and X-Ray (XR) guided spinal tap that were negative for malignancy, and

a magnetic resonance imaging (MRI) of the brain and a whole body PET scan showed no abnormalities.

Case # 2: A 46-year-old male presented with abdominal pain localized in his left lower quadrant (LLQ) of ten days duration and weight loss of 100 pounds for the past nine months. On examination the patient was in mild distress with mild tenderness on the LLQ and dyspnea at times. Laboratory examination was within normal limits. CT imaging of the abdomen and pelvis was suggestive for diffuse peritoneal involvement with subsequent CT guided core needle biopsy confirming DLBC—germinal type. Immunohistochemistry staining showed: GCET1+, FOXP1+, CD10+, CD20+, BCL6+, BCL2-, CD3- pankeratin-, MUM1-, and EBER ISH-. A CT guided thoracentesis was conducted for dyspnea due to pleural effusion. The cytology showed few atypical cells and reactive mesothelial cells.

Case # 3: A 67-year-old female presented with severe abdominal pain localized in the LLQ, bloating, distension, flank pain, unintentional weight loss, nausea, vomiting, diarrhea, fatigue, and decreased appetite. Physical exam showed diffuse tenderness in the LLQ, a fluid thrill/shifting dullness, and palpable irregular nodularities localized in the LLQ. CT of the abdomen and pelvis showed diffuse omental and mesenteric carcinomatosis with metastatic implants extending into the posterior mediastinum via diaphragmatic hiatus, and an irregular satellite mass of 7.9 cm. A CT guided core biopsy showed malignancy consistent with DLBCL – germinal type. Subsequent XR spinal tap with cerebrospinal fluid cytology times two showed no evidence of malignancy.

All three patients were started on Rituximab, Cyclophosphamide, Doxorubicin, Vincristine, and Prednisone (R-CHOP) therapy, the standard of care for DLBCL. Methotrexate and Cytarabine administration was interspersed throughout these cycles. In the end, the patient in case two and three received a total of eight cycles of treatment. In case one, the patient received an initial single treatment dose of R-CHOP therapy. After confirmation of Burkitt lymphoma, the patient was switched to Rituximab – hyperfractionated Cyclophosphamide, Vincristine, Doxorubicin, and Dexamethasone with alternating Methotrexate and Cytarabine (R-HCVAD/MA). A total of 4 cycles was administered for this patient.

During treatment, patients encountered mild side effects from the drugs such as nausea, vomiting, and fatigue. Abdominal symptoms in all three cases subsided, no resistance to the chemotherapeutic regimen was reported, and no other major side effects were noted. All patients completed treatment with documentation of complete regression of disease along with improvement of quality of life.

3. Discussion

PL, a form of extranodal lymphoma, is a rare condition that mimics peritoneal carcinomatosis but occurs less frequently [10]. Extranodal lymphoma has an incidence of approximately 40% of patients with lymphoma and can occur in any site of the body. However, involvement of the peritoneal cavity is exceedingly rare [10,11]. Extranodal lymphoma is generally a poor prognostic factor and more common with intermediate- to high-grade NHL [10,11]. PL from secondary involvement of visceral lymphoma occurs more frequently than primary lymphoma of the peritoneum [12]. The GI tract accounts for 5–20% of all lymphoma cases [10] and 10–30% of NHL patients [11]. DLBCL is the dominant subtype of NHL presenting as extranodal lymphoma and thus the most commonly reported with PL [10,11]. On the other hand, Burkitt lymphoma is a rare subtype with conservative estimates accounting for less than 1–2% of all NHL [8].

The omentum is not commonly involved with lymphoma because it does not contain lymphoid tissue [11,13]. Therefore,

Table 1
Table of timeline for presentation and intervention for each case.

Timeline for Presentation and Intervention		
Case #:	Date:	Description:
1	08/10/2015	Patient presented with symptoms of nausea, vomiting, diarrhea, abdominal pain, sweating, and weight loss to his general practitioner.
	08/28/2015	CT imaging of the abdomen and pelvis showed irregular thickening of the gastric wall and extensive nodularity on the omentum.
	08/29/2015	High-grade malignant B-cell NHL – DLBCL or Burkitt lymphoma confirmed via EGD.
	09/01/2015	Laparoscopy with biopsy conducted.
	09/03/2015	R-CHOP therapy started.
2	Week of 09/24/2015	Confirmation of Burkitt lymphoma.
	09/28/2015	R-CHOP therapy discontinued; Hyper-CVAD/MA therapy started.
	10/18/2015	Patient presented with symptoms of abdominal pain and weight loss. CT imaging of the abdomen and pelvis suggested diffuse peritoneal metastatic disease.
3	10/20/2015	CT guided biopsy was consistent with diffuse large B-cell lymphoma.
	10/28/2015	R-CHOP therapy started.
	August 2015	Patient presented with symptoms of abdominal pain, weight loss, nausea, vomiting, and diarrhea.
	08/22/2015	CT imaging of the abdomen and pelvis showed probable omental and mesenteric carcinomatosis with metastatic implants.
	09/08/2015	CT guided biopsy consistent with diffuse large B-cell lymphoma.
	09/16/2015	R-CHOP therapy started.

the route of dissemination is unclear although propagation is presumed to occur via pathways like the visceral peritoneal surfaces, gastrocolic ligament, and transverse mesocolon [10,11,13]. In contrast, dissemination to the omentum commonly occurs from metastatic carcinoma of the ovary, colon, and stomach [11]. Three cell lines may affect the peritoneal surface from secondary malignancies: epithelial (carcinomatosis), mesenchymal (sarcomatosis), and lymphoid (lymphomatosis) [11]. In contrast to peritoneal carcinomatosis, treatment of PL is usually by chemotherapy versus surgery [14]. Unless there is a complication of lymphoma, surgery should be the last resort.(Table 1)

Our patients presented clinically with vague abdominal discomfort that included pain and swelling. The imaging studies between the cases showed similarities as well. Typical CT findings of PL include omental caking with peritoneal enhancement, thickening, and nodularity with ascites, which are indistinguishable from peritoneal carcinomatosis [12]. However, there are other signs on CT that may help differentiate PL from peritoneal carcinomatosis: lymph node involvement, splenomegaly, and tumors in GI tract [14]. Definitive diagnosis can only be made through histological confirmation [12].

In the literature it has been shown that there is an established relationship between lymphoma and specific markers. There are laboratory techniques such as immunohistochemistry that can be employed to help identify the type of neoplasm. Once proper identification is complete, medications can be tailored toward that specific subtype. There are various markers throughout the B-cell lifecycle that can be specifically stained to provide confirmation. In Burkitt lymphoma and DLBCL, staining of markers within the B-cell lineage is useful in this endeavor. Of the series of markers stained in case one, CD20 is of clinical significance since it is of B-cell origin [15,16]. The remaining markers can have positivity in both T-cells and B-cells producing some confusion whilst narrowing the differential diagnosis. The translocation gene marker c-MYC is also very helpful in that it is seen in about 90% of cases of Burkitt lymphoma [15]. In case two, CD20 positivity was present along with other helpful markers that not only confirmed a neoplasm of B-cells but also categorized it as germinal center subtype (MUM1 negative and GCET1 positive), which is seen with DLBCL [16]. Although these markers assist us in developing a diagnosis, diagnostic confirmation is done through the combination of symptoms on presentation, physical examination, imaging studies, immunohistochemistry staining, and histological reports.

4. Conclusion

PL usually manifests as aggressive histological subtypes of high-grade lymphomas that lead to rapid progression and deterioration. It is therefore crucial to be aware of this rare entity to provide early diagnosis and optimal treatment that may prolong life. It has been reported that cytology has been used as an invaluable method to establish a diagnosis of PL from ascites with time limitation [10,5]. However, cases with inconclusive cytology require laparoscopic or image-guided needle biopsy for a definitive diagnosis. If image guided biopsy is unavailable or inconclusive laparoscopy is recommended. It is important to note that unless there is a complication of lymphoma, surgery should be refrained as it may lead to progression and deterioration [10].

Conflict of interest

None.

Sources of funding

None.

Ethical approval

Not applicable.

Consent

Consent was obtained from each patient.

Author contribution

Dr. Nail Aydin: Treatment of patient, conceived case report, involved in analysis of patients and literature, manuscript preparation, and approval of final form of manuscript.

Dr. Subhasis Misra: Involved in treatment of patient, analysis of patient and literature, manuscript preparation, and approval of final form of manuscript.

Mr. Everardo Flores: Analysis of patients, literature, and manuscript preparation.

Registration of research studies

Not applicable.

Guarantor

Dr. Nail Aydin.

Acknowledgement

None.

References

- [1] Surveillance, Epidemiology, and End Results Program. (n.d.). Retrieved January 10, 2016, from <http://seer.cancer.gov/statfacts/html/nhl.html>.
- [2] C. Freeman, J. Berg, S. Cutler, Occurrence and prognosis of extranodal lymphomas, *Cancer* (2016) 252–260 (n.d.).
- [3] F. D'amore, B. Christensen, H. Brincker, N. Pedersen, K. Thorling, J. Hastrup, et al., Clinicopathological features and prognostic factors in extranodal non-Hodgkin lymphomas, *Eur. J. Cancer Clin. Oncol.* (2016) 1201–1208.
- [4] B. Runyon, Peritoneal lymphomatosis with ascites. A characterization, *Arch. Intern. Med.* (1986) 887–888.
- [5] S. Weng, C. Wu, Lymphoma presenting as peritoneal lymphomatosis with ascites, *J. Chin. Med. Assoc.* (2016) 646–650 (n.d.).
- [6] E. Campo, S. Swerdlow, N. Harris, S. Pileri, H. Stein, E. Jaffe, The 2008 WHO classification of lymphoid neoplasms and beyond: evolving concepts and practical applications, *Blood* (2011) 5019–5032.
- [7] L. Morton, Lymphoma incidence patterns by WHO subtype in the United States, 1992–2001, *Blood* (2006) 265–276.
- [8] A Clinical Evaluation of the International Lymphoma Study Group Classification of Non-Hodgkin's Lymphoma, *Blood*. 89(11)(1997), 3909–3918. <http://dx.doi.org/>.
- [9] A. Smith, D. Howell, R. Patmore, A. Jack, E. Roman, Incidence of hematological malignancy by sub-type: a report from the Hematological Malignancy Research Network, *Br. J. Cancer Br. J. Cancer* (2011) 1684–1692.
- [10] E. Curakova, M. Genadieva-Dimitrova, J. Misevski, V. Caloska-Ivanova, V. Andreevski, B. Todorovska, et al., NonHodgkin's lymphoma with peritoneal localization, *Case Reports Gastrointestinal Med.* 2014 (2014) 1–8.
- [11] Fernanda C. Cabral, Katherine M. Krajewski, Kyung Won Kim, Nikhil H. Ramaiya, Jyothi P. Jagannathan, Peritoneal lymphomatosis: CT and PET/CT findings and how to differentiate between carcinomatosis and sarcomatosis, *Cancer Imaging* 13 (2) (2013) 162–170.
- [12] Sia Sy, J. Kapur, Yi Thian, Peritoneal lymphomatosis mimicking peritoneal carcinomatosis: important imaging clues for correct diagnosis, *Singapore Med. J.* (2013).
- [13] M. Sharifah, N. Zamzami, T. Rafeah, Diffuse peritoneal lymphomatosis simulating peritoneal carcinomatosis, *Med. J. Malaysia* 66 (3) (2011) 270–272.
- [14] A. Diop, M. Fontarensky, P.-F. Montoriol, D. Da Ines, CT imaging of peritoneal carcinomatosis and its mimics, *Diagn. Interventional Imaging* 95 (9) (2014) 861–872.
- [15] A. Chan, E. Enwere, M. Gupta, G. Johnson, R. Obeng, N. Pernick, S. Younes, Stains and molecular markers, Retrieved April 24, 2016, from <http://www.pathologyoutlines.com/stains.html>.
- [16] MeSH Browser. (n.d.). Retrieved April 24, 2016, from <https://www.nlm.nih.gov/mesh/2011/mesh.browser/MBrowser.html>.

Open Access

This article is published Open Access at sciendo.com. It is distributed under the [IJSCR Supplemental terms and conditions](#), which permits unrestricted non commercial use, distribution, and reproduction in any medium, provided the original authors and source are credited.