



Review

A Literature Review of Cannabis and Myocardial Infarction—What Clinicians May Not Be Aware Of

Kimesh Chetty, MBBS, BSc,^a Andrea Lavoie, BSc, MD, FRCPC,^b and Payam Deghani, MD^b

^a University of Calgary, Calgary, Alberta, Canada

^b Department of Cardiology, University of Saskatchewan, Saskatoon, Saskatchewan, Canada

ABSTRACT

Increasing legalization and expanding medicinal use have led to a significant rise in global cannabis consumption. With this development, we have seen a growing number of case reports describing adverse cardiovascular events, specifically, cannabis-induced myocardial infarction (MI). However, there are considerable knowledge gaps on this topic among health care providers. This review aims to provide an up-to-date review of the current literature, as well as practical recommendations for clinicians. We also focus on proposed mechanisms implicating cannabis as a risk factor for MI. We performed a

RÉSUMÉ

Depuis la légalisation du cannabis et l'élargissement de son utilisation à des fins médicales, la consommation de cannabis a beaucoup augmenté dans le monde, et l'on observe de plus en plus de cas de manifestations cardiovasculaires indésirables induites par le cannabis, notamment des cas d'infarctus du myocarde (IM). Les professionnels de la santé manquent toutefois de connaissances à ce sujet. Nous présentons donc une revue à jour de la littérature récente, ainsi que des recommandations pratiques à l'intention des cliniciens. Nous traitons également des mécanismes qui pourraient expliquer pourquoi

Cannabis is the most widely abused illicit substance in the world.¹ In 2013, the World Health Organization estimated that over 180 million people used cannabis for recreational purposes worldwide.¹ Current estimates are expected to be much higher as more countries head toward legalization, and medicinal use continues to grow.

In recent decades, the mean delta-9-tetrahydrocannabinol (THC) content within cannabis has increased. In the United States, the level was reportedly less than 2% in 1980 and had increased to over 20% in some instances by 2015. The current THC content is likely much higher.¹⁻³

In parallel with increasing cannabis consumption and rising THC concentrations, a growing number of published case reports have described cannabis-induced adverse cardiovascular events such as myocardial infarction (MI).⁴ Such cases have been predominantly reported in young, otherwise healthy adults who present shortly after use.⁵

Despite these statistics, there is a perception that cannabis is “safe” for public consumption.⁶ But in fact, there is a paucity of data on the short- and long-term effects of

cannabis, especially with regard to the cardiovascular system. Canada legalized cannabis in 2018, yet reports no information on the Canadian national website about the potential cardiovascular side effects of cannabis use.⁷ As a result, physicians and other health care professionals have very little information on this topic and are thus unable to appropriately counsel their patients.

With the current trend toward decriminalization and increased use for medicinal or recreational purposes, health care professionals are going to encounter more patients in their practice who are active cannabis users. Although previous published reviews have broadly highlighted the cardiovascular implications of cannabis use,^{4,5,8-12} few studies have focused on cannabis-induced MI. Thus, this review provides an in-depth analysis of cannabis-induced MI, highlighting age of presentation, method and timing of cannabis ingestion, clinical outcomes, and proposed pathophysiological mechanisms. This review implicates cannabis as a risk factor for MI and provides practical recommendations for health care professionals in their day-to-day practice. This review does not focus on other previously described cardiovascular effects, including ischemic stroke, acute heart failure, and peripheral vascular disease.⁵

Received for publication July 7, 2020. Accepted September 1, 2020.

Ethics Statement: The research reported in this review has adhered to the relevant ethical guidelines.

Corresponding author: Kimesh Chetty, University of Calgary, 1628 18th Avenue, NW Calgary, Alberta, T2M0X1, Canada. Tel.: +1-289-925-7359.

E-mail: kchetty441@gmail.com

See page 18 for disclosure information.

Methodology

A comprehensive literature search of the MEDLINE, Cochrane, Cumulative Index to Nursing and Allied Health Literature (CINAHL), and Turning Research into Practice

comprehensive literature search using the MEDLINE, Cochrane, Cumulative Index to Nursing and Allied Health Literature (CINAHL), and Turning Research into Practice (TRIP) PRO databases for articles published between 2000 and 2018. A total of 92 articles were included. We found a significant number of reports describing cannabis-induced MI. This was especially prevalent among young healthy patients, presenting shortly after use. The most commonly proposed mechanisms included increased autonomic stimulation, altered platelet function, vasospasm, and direct toxic effects of smoke constituents. However, it is likely that the true pathogenesis is multifactorial. We should increase our pretest probability for MI in young patients presenting with chest pain. We also recommend against cannabis use in patients with known coronary artery disease, especially if they have stable angina. Finally, if patients are adamant about using cannabis, health care providers should recommend against smoking cannabis, avoidance of concomitant tobacco use, and use of the lowest delta-9-tetrahydrocannabinol dose possible. Data quality is limited to that of observational studies and case report data. Therefore, more clinical trials are needed to determine a definitive cause-and-effect relationship.

(TRIP) PRO databases was conducted for English-language and human-only studies conducted between 2000 and 2018. Search terms for cannabis included the following: cannabis, marijuana, cannabinoids, weed, THC, delta-9-tetrahydrocannabinol, tetrahydrocannabinol, CBD (for cannabidiol), and cannabidiol. Search terms for myocardial infarction included the following: myocardial infarction, MI, acute coronary syndrome, ACS (for acute coronary syndrome), and heart attack. A total of 237 publications were identified. After exclusion of duplicate and nonrelevant articles (eg, studies examining noncardiovascular or non-MI cardiovascular adverse events), 92 articles were included in this scoping review. These included 1 randomized control trial, 4 systematic reviews, 19 literature reviews, 11 large database reviews, and 42 case reports/series; the remaining articles were focused largely on *in vitro* lab studies and cross-sectional data.

Cannabis, Cannabinoid Receptors, and the Endocannabinoid System

Cannabis, also known as marijuana, is a naturally growing plant from the family *Cannabaceae*. Currently, there are 3 naturally growing strains of cannabis that have been recognized—cannabis *sativa*, *indica*, and *ruderalis*.¹ In recent years, there has been significant inbreeding among *sativa*, *indica*, and *ruderalis* that has resulted in numerous hybrid strains. Each strain differs in its content level of THC and cannabidiol (CBD), the 2 main active ingredients in cannabis.² There are also numerous synthetic cannabinoids (SCs) that are biochemically manufactured, adding to the overall high number of formulations currently available to the public (Fig. 1).

le cannabis pourrait être un facteur de risque d'IM. Nous avons effectué une recherche documentaire exhaustive dans les bases de données MEDLINE, Cochrane, CINAHL (*Cumulative Index to Nursing and Allied Health Literature*) et TRIP (*Turning Research into Practice*) PRO afin de relever les articles pertinents publiés entre 2000 et 2018. Au total, 92 publications ont été retenues. Nous avons relevé un grand nombre de cas d'IM induit par le cannabis. Ce phénomène était particulièrement répandu chez les patients jeunes et en santé, et survenait peu de temps après la consommation. Les mécanismes les plus souvent proposés pour expliquer ce type d'IM comprenaient l'augmentation de la stimulation du système nerveux autonome, une altération de la fonction plaquettaire, l'induction d'un vasospasme et les effets toxiques directs des constituants de la fumée. Il est toutefois probable que la véritable pathogenèse soit multifactorielle. Il conviendrait de soupçonner un IM avant même d'effectuer des tests chez les patients jeunes présentant une douleur thoracique. Nous déconseillons en outre l'usage du cannabis chez les patients ayant reçu un diagnostic de coronaropathie, en particulier s'ils souffrent d'angine stable. Enfin, si un patient tient absolument à consommer du cannabis, les professionnels de la santé devraient lui recommander de ne pas le fumer, d'éviter de fumer la cigarette en concomitance et de prendre la dose de delta 9-transtétrahydrocannabinol la plus faible possible. La qualité des données présentées est limitée étant donné qu'il s'agit de données tirées d'études observationnelles et d'exposés de cas; d'autres essais cliniques s'imposent donc afin de déterminer avec plus de certitude l'existence d'une relation de cause à effet.

When cannabis is consumed, exogenous cannabinoids—primarily CBD and THC—bind to similar endogenous cannabinoid receptors within the body. This biologic system is termed the endocannabinoid system.¹³ This system is involved in certain physiological processes, including memory, appetite, mood, cognition, pain sensation, and more.¹³ THC specifically is responsible for the psychotropic effects of cannabis that many users associate with the “high” feeling after consumption. THC has been implicated as the potential culprit in many of the adverse cardiac effects and is therefore the focus of the current review.

THC binds to the G-coupled protein receptors carbonyl reductase 1 and 2 (CBR1 and CBR2) that are widely expressed within the body. CBR1 predominates in the central nervous system, being primarily responsible for the psychoactive effects of cannabis. CBR2 is found largely within the immune system (eg, spleen, thymus, tonsils, and immune cells) and plays an anti-inflammatory role through immune modulation. THC is also capable of exerting effects independent of CBR1 and CBR2.⁸

Specifically, with respect to the cardiovascular system, CBR1 and CBR2 are both found within cardiac myocytes and vascular endothelium. CBR1 is proinflammatory and results in the upregulation of reactive oxygen species (ROS). Within the myocardium, it has been shown to exert negative inotropic effects.¹⁴ In the coronary and cerebral vasculature, they mediate vasodilation. On the contrary, CBR2 is largely anti-inflammatory and anti-atherogenic.^{9,15} CBR1 and CBR2 are found within cardiac myocytes where they act via immune cells to limit inflammation and activate cardioprotective mechanisms.

Due to the proinflammatory nature of CBR1, it was hypothesized that CBR1 antagonists could help improve

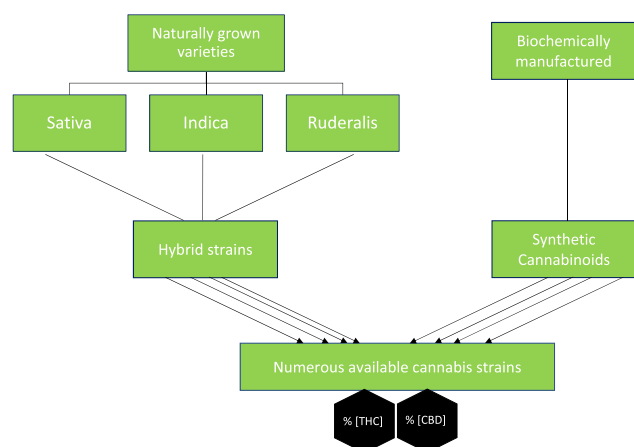


Figure 1. Flowchart demonstrating consumable cannabis strains. CBD, cannabidiol; THC, delta-9-tetrahydrocannabinol.

vascular outcomes by reducing inflammation and improving the overall metabolic profile. This hypothesis was examined by the **Comprehensive Rimonabant Evaluation Study of Cardiovascular Endpoints and Outcomes (CRESCENDO)** trial, which was published in the *Lancet* in 2010.¹⁶ Rimonabant (a CBR1 inverse agonist) was compared against placebo in over 18,000 participants at increased risk of vascular disease. Unfortunately, the study was terminated prematurely due to increased serious neuropsychiatric effects in the treatment arm. The **Effect of Rimonabant on Progression of Atherosclerosis in Patients With Abdominal Obesity and Coronary Artery Disease (STRADIVARIUS)** trial also examined the effect of rimonabant in obese subjects. In this trial, rimonabant reduced total coronary atheroma volume (using intravascular ultrasound) compared with placebo. These 2 studies illustrate that blocking the CBR1 receptor may actually have some benefit on vascular outcomes. Extrapolating from this finding, CBR1 agonism may have harmful effects on our vasculature, but more studies are needed to evaluate this theory.

SCs (commonly sold under the trade names “Spice” and “K2”) are structurally and biochemically very similar to THC, and they therefore bind analogous receptors. However, these drugs have a greater affinity and binding potential to CBR1 compared to THC. This difference leads to a stronger effect of SCs, and therefore a theoretically increased risk of major adverse events. In addition, although they are structurally like THC, they are not equivalent. Therefore, standard drug-screening methods do not always detect SCs, and consequently a negative drug screen does not rule out SC use. There are now specialized tests available for some of the common synthetic formulations, but interpretation is increasingly difficult.^{17,18}

The effect of cannabis on our bodies is also driven largely by the method of intake, which has become more extensive. The most common method of intake is inhalation via smoking or vaporization. However, there are also edibles, transdermal patches, sublingual sprays, suppositories, and more. Each method differs in the onset of action, the duration of effect, and the amount of active metabolite that reaches our systemic circulation.² Inhalation produces a rapid rise in plasma THC levels, followed by a rapid decline. This process

creates a more intense receptor activation, and thus a stronger effect on our bodies.⁴ Oral consumption has a slow and unpredictable absorption rate, and a lower bioavailability, creating a prolonged and sustained response that varies considerably by edible. The primary factor that dictates the effect is the concentration, or the amount of THC. The higher the THC concentration, the greater the likelihood of receptor activation and subsequent physiological effects.⁴

Discussion

Evidence supporting cannabis-induced MI

To date, there have been 51 reported cases describing cannabis-related MI.¹⁹⁻⁶¹ The first case was reported in 2003, with a significant rise in the number of cases in recent years. Jouanjus et al.⁶² published a review on cannabinoid-related adverse events between 2006 and 2010 in the south of France. They reported a tripling of cardiovascular complications, from 1.1% to 3.6%. The majority of these cases resulted from MI, or peripheral arteriopathy.⁶² In our scoping review, we highlight the strong prevalence of cannabis-induced MI among young healthy patients. The mean age of presentation was 31 years (range: 15–56 years). Most patients were male (94%), presenting with chest pain within 6 hours of cannabis use (80%). A total of 75% of patients had no other traditional coronary risk factors, including hypertension, hyperlipidemia, diabetes, previous coronary artery disease, or a positive family history (Table 1).

When examined for MI type, 71% of patients suffered from ST elevation MI (STEMI). Of these, two-thirds were revascularized with either percutaneous coronary intervention or coronary artery bypass grafting. In the one-third of patients who had no revascularization, the STEMI was hypothesized secondary to coronary vasospasm or slowed coronary flow (as discussed below).

With regard to clinical outcome, 22% of patients had either presented with an out-of-hospital cardiac arrest, or had had an arrest prior to intervention. Half of these patients died. We discuss 2 cases that illustrate the severity of clinical presentations and their outcomes. Casier et al.¹⁹ reported the case of a young healthy 23-year-old man with a history known for only heavy regular cannabis use. He presented with a short out-of-hospital cardiac arrest, and was subsequently found to have widespread ST elevation. Angiogram demonstrated total occlusion of the ostial left anterior descending (LAD) artery and proximal right coronary artery, which were both stented. Due to a poor ejection fraction (12%) and refractory cardiogenic shock, the patient had a biventricular assist device implanted. Three months later, the patient went on to have a cardiac transplant.¹⁹ Velibey et al.²⁰ reported the case of a healthy 27-year-old man with a history of only regular heavy cannabis use. He presented with acute central chest pain and was found to have a non-ST elevation MI. An angiogram demonstrated total occlusion of his left main coronary artery with retrograde perfusion of his left ventricle via a nondominant right coronary artery. He went on to have urgent coronary artery bypass grafting surgery.²⁰ There are other similar cases within the literature that highlight the potential negative clinical outcomes that can be associated with cannabis use.

Table 1. Case report data illustrating patient demographics, pattern of cannabis use, and clinical outcome

Reference/first author	Year	Age, y	Gender	CV RFs (HTN, DYS, DM, FamHx)	Tobacco	Regular user	Recent use <6 h ago	Synthetic	Other illicit	STEMI	Intervention (PCI/CABG)	Cardiac arrest	Death
Rezkalla ³¹	2003	34	M	N	Y	Y	Y	N	N	N	N	Y	N
Caldicott ²²	2005	21	M	N	N	N	Y	N	N	Y	Y	N	N
Lindsay ⁴³	2005	48	M	Y	N	Y	Y	N	N	Y	Y	Y	N
Lindsay ⁴³	2005	22	M	N	Y	Y	Y	N	N	Y	Y	N	N
Tatli ⁵⁶	2007	24	M	N	Y	Y	Y	N	N	Y	Y	N	N
Kotsalou ⁴²	2007	53	M	Y	Y	Y	N	N	N	N	N	N	N
Cappelli ²⁵	2008	26	M	N	Y	Y	Y	N	N	Y	Y	N	N
Dwivedi ¹⁰	2008	23	M	Y	N	Y	N	N	N	N	N	N	N
Dwivedi ⁸⁷	2008	50	M	N	Y	Y	N	N	N	N	N	N	N
Montisci ⁴⁸	2008	31	M	N	N	Y	U	N	Y	N	N	Y	Y
Kocabay ⁴⁰	2009	32	M	N	Y	Y	Y	N	N	Y	Y	N	N
Bailly ³⁴	2010	36	F	N	N	Y	Y	N	N	Y	N	N	N
Karabulut ³⁰	2010	35	M	N	Y	Y	Y	N	N	N	N	N	N
Canga ²⁴	2011	28	M	N	Y	Y	Y	N	N	Y	Y	N	N
Mir ⁴⁷	2011	16	M	N	N	N	Y	Y	N	Y	N	N	N
Mir ⁴⁷	2011	16	M	N	N	N	N	N	Y	N	N	N	N
Mir ⁴⁷	2011	16	M	N	N	N	N	Y	N	Y	N	N	N
Pratap ⁵¹	2011	19	M	N	U	Y	Y	N	N	Y	N	N	N
Safaa ⁵³	2011	40	M	Y	Y	Y	Y	N	N	N	N	N	N
Arora ²³	2012	37	M	Y	N	U	Y	N	N	Y	N	N	N
Renard ⁵²	2012	33	M	N	Y	Y	Y	N	N	N	N	N	N
Yurtdas ⁴⁹	2012	26	M	N	Y	Y	Y	N	N	Y	Y	N	N
Deharo ³⁵	2013	24	M	N	Y	Y	Y	N	N	Y	Y	N	N
Sayin ⁵⁴	2013	30	M	Y	Y	Y	U	N	N	N	Y	N	N
Ayhan ²⁷	2014	33	M	N	Y	Y	Y	Y	N	Y	Y	N	N
Casier ⁵⁹	2014	52	M	Y	Y	Y	Y	N	N	Y	N	Y	Y
Casier ⁵⁹	2014	23	M	N	N	Y	Y	N	N	Y	Y	Y	N
Casier ⁵⁹	2014	28	M	N	N	N	Y	N	N	Y	Y	Y	Y
Gunawardena ³²	2014	29	M	N	U	U	Y	N	U	Y	N	N	N
Hodcroft ²⁹	2014	21	M	N	Y	Y	Y	N	N	Y	Y	N	N
Ibrahim ²⁸	2014	56	M	Y	N	N	Y	Y	N	N	N	Y	N
Tse ⁵⁷	2014	45	M	Y	Y	Y	Y	Y	N	N	N	Y	Y
Jehangir ³³	2015	27	F	Y	Y	Y	N	N	N	Y	Y	N	N
Koklu ⁴¹	2015	31	M	N	U	Y	Y	Y	N	Y	Y	N	N
Marchetti ⁴⁴	2015	50	M	N	Y	N	Y	N	N	N	N	Y	Y
McKeever ⁴⁵	2015	16	M	N	Y	Y	Y	Y	N	Y	N	N	N
Velibey ²⁰	2015	27	M	N	N	Y	Y	N	N	Y	Y	N	N
Walsh ⁵⁸	2015	26	M	N	N	Y	Y	Y	N	Y	N	N	N
Yilmaz ⁵⁹	2015	29	M	N	Y	N	Y	Y	N	Y	Y	Y	N
Keskin ³⁹	2016	15	M	N	N	Y	Y	Y	N	Y	N	N	N
Mcllroy ⁴⁷	2016	39	M	N	Y	Y	Y	Y	N	Y	Y	Y	N
Orsini ⁵⁰	2016	40	M	N	Y	U	U	N	Y	Y	N	Y	Y
Shah ⁵⁵	2016	24	M	N	Y	Y	Y	Y	N	N	Y	N	N
Tirkey ³⁸	2016	25	M	N	N	Y	Y	N	N	N	N	N	N
Ul Haq ³⁷	2017	31	M	N	N	U	Y	Y	N	Y	Y	N	N
Ul Haq ³⁷	2017	26	M	Y	U	U	Y	Y	N	Y	Y	N	N
Ul Haq ³⁷	2017	47	M	Y	U	U	Y	Y	N	Y	Y	N	N
Hamilton ²⁷	2017	50	M	U	U	U	Y	Y	U	Y	Y	N	N
Mehta ²¹	2017	16	M	N	N	N	Y	Y	N	N	N	N	N

Continued

Table 1. Continued.

Reference/first author	Year	Age, y	Gender	CV RFs (HTN, DYS, DM, FamHx)				Tobacco	Regular user	Recent use <6 h ago	Synthetic	Other illicit	STEMI	Intervention (PCI/CABG)	Cardiac arrest	Death
				N	Y	U	N									
Kumar ⁶⁰	2018	35	M	N	Y	U	N	N	N	N	N	Y	N	N	N	
Mills ³⁶	2018	30	F	N	Y	Y	N	Y	Y	Y	N	Y	Y	N	N	
Averages	38	31	M = 48(94%)	N = 38	Y = 35 (69%)	Y = 41	Y = 25	Y = 19	Y = 36	Y = 2	Y = 36	Y = 25	Y = 11	Y = 6	Y = 6	
	(75%) >2010	(15-56)		(75%)	(69%)	(80%)	(49%)	(37%)	(71%)	(3.9%)	(71%)	(49%)	(22%)	(11.7%)		

CABG, coronary artery bypass grafting; CV, cardiovascular; DM, diabetes mellitus; DYS, FamHx, family history; F, female; HTN, hypertension; M, male; MI, myocardial infarction; N, no; PCI, percutaneous coronary intervention; RE, STE, U, unknown; Y, yes.

An analysis of the methods and patterns of cannabis use highlights some interesting findings. Although the majority of cases reported inhalation use via smoking or vaporization, there were case reports of MI following edible cannabis use. More recently, the incidence of MI following the use of SCs has increased, accounting for 37% of cases. This increase is likely due to the growth in SC availability. Similarly, although 69% of patients reported regular cannabis use prior to their presentation of MI, 31% of patients had not used cannabis regularly. In fact, a few cases described patients who presented with chest pain shortly after their first cannabis ingestion. Mehta et al.²¹ outlined a case of an obese 16-year-old boy with a positive family history for coronary artery disease (MI in father at age 50 years). He had acute left-sided chest pain, shortly after using a vape pen for the first time, that presented as non-STEMI. An echocardiogram revealed distal septal and apical wall hypokinesis that was thought to be secondary to LAD coronary vasospasm.²¹ Caldicot et al.²² reported a case of a healthy 21-year-old man who presented to the emergency department in the early morning with central chest and epigastric pain. He admitted to consuming a large amount of alcohol and marijuana the night before. He had smoked marijuana once, 6 months before, and did not use any tobacco. He was found to have ST elevation in II, III, and arteriovenous fistula. A subsequent angiogram demonstrated a large proximal clot and 100% distal blockage of his LAD artery. Percutaneous coronary intervention was performed, and the patient was discharged on day 5. Such cases illustrate that the risk of cannabis-induced MI may not always result from the additive effect from prolonged use, as we see with tobacco use, but may occur at any time following use.

With respect to additional substance use, 2 cases reported concomitant cocaine use, and a significant proportion of cases (49%) reported additional tobacco use (in the form of cigarettes, or mixed in with cannabis). Concomitant substance use was a potential confounding factor, suggesting, for instance, that some of the cardiac risk may be attributable to tobacco use. Given that the patients were young and otherwise healthy, tobacco use itself may not explain all of this risk. The potential for harmful amplification when tobacco and cannabis are used together requires further exploration.

Several larger studies have also demonstrated a probable link between cannabis use and MI. Mittleman and colleagues⁶³ examined for the self-reported acute effects of marijuana in over 3800 patients. They found an 4.8-fold increase in the likelihood of having an MI in the hour following cannabis ingestion. A similar analysis by Mittleman et al. on cocaine use found a 24-fold increased risk of having an MI after intake.⁶⁴ Although cannabis use accounts for only one-fifth of the risk of MI, it should still pose significant clinical concern. In a multicentre database of over 10 million patients in the United States, Chami and Kim showed that the 5-year incidence of MI was significantly higher among cannabis users.⁶⁵ This outcome was found even when analyses were adjusted for age, hypertension, smoking, diabetes, alcohol use, and cocaine use. The highest relative risk was seen in young adults aged 25-34 years. Desai et al. showed similar results using the national inpatient sample (NIS) database which includes more than 2 million patients.⁶⁶ They found that marijuana use was a significant risk factor for acute MI after adjusting for age, sex, race, smoking, and cocaine use.

Lee and colleagues⁶⁷ retrospectively examined patients from 2013-2017 who presented to the coronary care unit at an urban city in the United States. They found that among patients with MI, those who smoked marijuana were younger and had significantly fewer cardiovascular risk factors than those who did not smoke marijuana. They concluded that marijuana use may be a risk factor itself, and/or may accelerate other traditional risk factors in the pathogenesis of MI. Afshar et al.⁶⁸ looked at all patients aged younger than 55 years who were admitted to a New York hospital between 2012 and 2014. In those with a primary diagnosis of acute coronary syndrome, they found no difference in incidence of MI between marijuana users and nonusers. However, when they substratified groups according to age, they found that users aged 18-36 years had a significantly increased risk for acute coronary syndrome compared to nonusers, with an odds ratio of more than 5, illustrating that young patients may have an increased risk.

Pathogenic mechanisms contributing to cannabis-induced MI

There have been many proposed mechanisms of how cannabis leads to acute coronary syndrome. The most commonly reported mechanisms include increased autonomic stimulation, altered platelet function, direct toxic effect of smoke constituents, and vasospasm/altered coronary flow.

Many studies have shown that increased autonomic stimulation—namely increased heart rate and blood pressure—may play a pivotal role in the pathogenesis of MI. Weiss et al. found that after administering THC, there was an increase in both urine and plasma catecholamine levels. Hemodynamic assessment showed an acute increase in heart rate as well as mean arterial blood pressure after administration.⁶⁹ Johnson and Domino⁷⁰ examined a small sample of young healthy volunteers. They found a dose-related increase in heart rate shortly after cannabis use. The maximum heart rate was attained 30 minutes after use, and it persisted for 90 minutes. One subject who was a daily chronic user seemed extremely tolerant of the psychic effects; however, his heart rate increased from 55 to 120 beats per minute after a 30-mg dose.⁷⁰ Benowitz et al.⁷¹ exposed subjects to intravenous THC and found a similar increase in heart rate following exposure. Using pretreatment with regimens of propranolol and atropine, they concluded that the rise in heart rate was likely secondary to autonomic stimulation.⁷¹ The effect on systemic blood pressure appeared to be slightly more complex. There is a modest rise in supine systolic blood pressure shortly after use. However, some studies suggest that there is also a transient orthostatic decrease in mean pressure that can lead to pre-syncope in some individuals.^{69,72,73} This finding again indicates that there is likely some autonomic dysfunction as a result of cannabis use. Finally, Aronow and Cassidy demonstrated that smoking marijuana, compared to placebo, resulted in a 48% decreased exercise time in patients with stable angina,⁷⁴ emphasizing a significant increase in cardiac workload following marijuana use.

A second proposed mechanism was altered platelet function. Deusch et al.⁷⁵ examined the effect of THC on human platelets *in vitro*. They found that CBR1 and CBR2 were normally present on platelet membranes. In the presence of

THC, there was increased expression of glycoprotein IIb/IIIa, and of P selectin receptors in a concentration-dependent manner. These receptors normally act to stimulate platelets to aggregate. Deusch et al. therefore concluded that THC may have a pro-coagulatory effect through platelet activation.⁷⁵ There have also been case reports describing platelet aggregation as a possible cause of MI.^{29,76,77} Hodcroft et al.²⁹ described a young male patient who presented with STEMI shortly after using cannabis. Subsequent angiogram and intravascular ultrasound demonstrated complete thrombus with no underlying atherosclerosis, suggesting that platelet aggregation may have played a central role.

A third potential contributor described in the literature is altered coronary blood flow. Quercioli et al. found that elevated levels of endocannabinoids within the plasma were associated with significantly impaired myocardial blood flow, specifically in obese individuals.⁷⁸ There have also been several case reports demonstrating this potential phenomenon. Karabulut and Cakmak reported a case of a young man known for only regular cannabis use who presented with an inferior STEMI. An angiogram showed slow coronary flow in the absence of any epicardial stenosis.³⁰ Rezkalla et al.³¹ reported another case of a young man with a similar profile who presented with ventricular tachycardia (VT). An angiogram demonstrated slowed coronary flow and inducible VT in the electrophysiological lab. Upon cessation of marijuana use, and treatment with verapamil, his coronary flow normalized, and VT was no longer inducible.³¹

There have also been reports of cannabis use leading to an increase in carbon monoxide exposure. Wu et al. looked at a small sample of young men and measured their carboxyhemoglobin level after they smoked cigarettes, compared to marijuana.⁷⁹ They found a nearly 5-fold increase in carboxyhemoglobin levels after marijuana smoking compared to tobacco smoking. They also showed that inhalation techniques differed quite substantially between the 2 substances. With marijuana smoking, they noted a greater depth of inhalation, a larger puff volume, and a significantly longer breath-holding time, which they believed may have accounted for the differences observed. Moir et al. examined the chemical composition of both marijuana and cigarette smoke.⁸⁰ Apart from the obvious nicotine difference, marijuana smoke contained many of the same compounds that cigarette smoke contained. Surprisingly, marijuana also contained significantly more ammonia, hydrogen cyanide, and aromatic amines compared to cigarettes. These compounds have been implicated as some of the carcinogenic particles in smoke.⁸⁰ Given this, it is likely that marijuana smoke is at least as toxic as cigarette smoke to the coronary vasculature. Therefore, it may lead to similar effects of acute plaque rupture and thrombosis.

Finally, an increase in ROS has also been implicated as a cause for myocardial injury. The ROS system has been shown to have a significant interaction within the endocannabinoid system. Lipina et al. found that endocannabinoid-induced ROS signalling can be both stimulatory and inhibitory depending on the cell stimulus, and cell type.⁸¹ Although the interaction is quite complex and not fully understood, they concluded that if CBR1 was upregulated more than CBR2 within a cell, it would induce ROS formation. This result is compared to CBR2 being activated more than CBR1,

resulting in inhibition of ROS, and overall decreased inflammation. Given the many proposed mechanisms for cannabis-induced MI, it is likely that the true pathogenesis is complex and multifactorial in nature, with more research in the area required.

The role of cannabis in post-infarct outcomes

It is evident from the literature that cannabis may have a critical role in precipitating MI. However, there were a few studies that also examined the effect of cannabis on outcomes post-MI. ‘The determinants of MI onset’ (MIOS) database enrolled patients with MI from 45 US hospitals during 1989-1996. Mukamal et al. initially followed these patients for 3.8 years, and they found that there was an increased mortality rate associated with marijuana users compared to nonusers.⁸² Frost et al.⁸³ then continued this study and followed these patients for a total of 18 years. Although they found a higher mortality in marijuana users, the mortality difference was no longer statistically significant.

Johnson-Sasso et al. published a large database review in the United States comprising over 1.2 million patients admitted with acute MI.⁸⁴ Their primary finding was contrary to their hypothesis. They found that marijuana users had better short-term outcomes than nonusers in the post-MI setting. Specifically, they had lower in-hospital mortality. They also found that marijuana users on average were 10 years younger and had fewer comorbidities than nonusers. Therefore, they concluded that this finding may have been secondary to the fact that patients in the marijuana group were younger and healthier and thus had better outcomes. This concept is very similar to the “smoker’s paradox,” a well documented phenomenon.^{85,86} This paradox refers to the improved short-term outcomes seen in smokers post-MI. On the same basis, many believe this result is due to initially healthier patients on presentation.

There have been a few studies looking at the potential therapeutic role of cannabis post-MI. This idea has come largely from the possible benefit of CBR2, which has been shown to have significant anti-inflammatory effects.¹⁵ There have been studies to suggest that CBR2 contributes to ischemic preconditioning and thus protects against ischemic reperfusion injury.^{87,88} There also may be a beneficial effect on atherogenesis, through control of inflammation and tissue injury.¹⁵ Although these data have come largely from laboratory and animal studies, this area could be a potential target for therapeutic options to be considered in the future. As CBD has a higher affinity for CBR2, it has been studied more in this area.¹⁵

Limitations

This review identified a number of gaps within the published literature, with a major limitation being the overall quality of data. First, as most studies are observational in nature, it is difficult to establish a true cause-and-effect relationship between cannabis use and MI. Second, many of the studies did not state explicitly how cannabis use was measured or how MI was diagnosed. Given that most studies used self-reported cannabis use (rather than laboratory drug-screening methods), and most studies were published when cannabis use was illegal and more socially unacceptable, it is

likely there was significant underreporting of overall cannabis use, which in turn may have affected any positive result observed. Third, concomitant tobacco use was very prevalent, and therefore may be a potential confounding factor in the analysis. Lastly, the extensive variability in the method of intake, the amount of THC used, the type of strain involved, and whether it was synthetic all make the analysis of the true risk of cannabis use more difficult to discern.

Conclusion

We are now within an era of rapidly growing recreational and medicinal cannabis use. However, there remains a paucity of knowledge on the adverse effects of cannabis use, specifically as it relates to the cardiovascular system. Rising THC concentrations, and a substantial increase in the number of strains available to the public, pose a significant health concern.

The literature suggests that cannabis use plays a role in inducing MI, particularly in young, otherwise healthy adults who present shortly after use. Increased autonomic stimulation, altered platelet aggregation, vasospasm, and toxic smoke constituents have all been proposed as explanations of this effect. However, it is likely that the true pathogenesis is multifactorial.

Based on the current evidence, there is definite need for concern regarding cannabis use and risk of MI. As a result, we make the following recommendations. First, we as health care providers need to recognize the potential risk for MI among cannabis users. Therefore, a higher pretest probability for MI should be sought when cannabis users present with chest pain. Second, in patients with a history of coronary artery disease, especially those with stable angina, providers should recommend against cannabis use. Third, when counselling about potential cardiovascular side effects, health care workers should provide the evidence we have thus far, and together with the patient, weigh the risk versus benefit. If patients are adamant about continued use, emphasis should be focused on using the lowest possible dose of THC, recommendation to avoid smoking cannabis, and recommendation against concomitant tobacco and cannabis use.

Further large-scale clinical trials are needed to determine the full impact of cannabis use as a risk factor for MI. With increasing legalization and decriminalization, these studies will now be much more feasible. There should also be *in vivo* trials done to elucidate concrete pathophysiological mechanisms of cannabis use that may lead to MI.

Funding Sources

The authors have no funding sources to declare.

Disclosures

The authors have no conflicts of interest to disclose.

References

1. Saxena S/World Health Organization. Management of substance abuse: the health and social effects of nonmedical cannabis use. Available at: https://www.who.int/substance_abuse/publications/cannabis_report/en/index1.html. Accessed September 1, 2019.

- World Health Organization. WHO Expert Committee on Drug Dependence: thirty-seventh report. Available at: <https://apps.who.int/iris/handle/10665/206452>. Accessed September 1, 2019.
- Madras BK. Update of cannabis and its medical use. Available at: http://www.who.int/medicines/access/controlled-substances/6_2_cannabis_update.pdf?ua=1. Accessed September 1, 2019.
- Pacher P, Steffens S, Haskó G, Schindler TH, Kunos G. Cardiovascular effects of marijuana and synthetic cannabinoids: the good, the bad, and the ugly. *Nat Rev Cardiol* 2017;15:151-66.
- Desbois AC, Cacoub P. Cannabis-associated arterial disease. *Ann Vasc Surg* 2013;27:996-1005.
- McKiernan A, Fleming K. Canadian Youth Perceptions on Cannabis—Ottawa: Canadian Centre on Substance Use and Addiction; 2017.
- Government of Canada. Cannabis health warning messages. Available at: <https://www.canada.ca/en/health-canada/services/drugs-medication/cannabis/laws-regulations/regulations-support-cannabis-act/health-warning-messages.html>. Accessed October 1, 2019.
- Jouanjus E, Raymond V, Lapeyre-Mestre M, Wolff V. What is the current knowledge about the cardiovascular risk for users of cannabis-based products? A systematic review. *Curr Atheroscl Rep* 2017;19:26.
- Singla S, Sachdeva R, Mehta JL. Cannabinoids and atherosclerotic coronary heart disease. *Clin Cardiol* 2012;35:329-35.
- Singh A, Saluja S, Kumar A, et al. Cardiovascular complications of marijuana and related substances: a review. *Cardiol Ther* 2017;7:45-59.
- Thomas G, Kloner RA, Rezkalla S. Adverse cardiovascular, cerebrovascular, and peripheral vascular effects of marijuana inhalation: what cardiologists need to know. *Am J Cardiol* 2014;113:187-90.
- Franz CA, Frishman WH. Marijuana use and cardiovascular disease. *Cardiol Rev* 2016;24:158-62.
- Pacher P. The endocannabinoid system as an emerging target of pharmacotherapy. *Pharmacol Rev* 2006;58:389-462.
- Bonz A, Laser M, Kullmer S, et al. Cannabinoids acting on CB1 receptors decrease contractile performance in human atrial muscle. *J Cardiovasc Pharmacol* 2003;41:657-64.
- Zubrzycki M, Liebold A, Janecka A, Zubrzycka M. A new face of endocannabinoids in pharmacotherapy. Part II: role of endocannabinoids in inflammation-derived cardiovascular diseases. *J Physiol Pharmacol* 2014;65:183-91.
- Topol EJ, Bousser MG, Fox KA, et al. Rimonabant for prevention of cardiovascular events (CRESCENDO): a randomised, multicentre, placebo-controlled trial. *Lancet* 2010;376:517-23.
- Tait RJ, Caldicott D, Mountain D, Hill SL, Lenton S. Asystematic review of adverse events arising from the use of synthetic cannabinoids and their associated treatment. *Clin Toxicol* 2015;54:1-13.
- Tournebise J, Gibaja V, Kahn JP. Acute effects of synthetic cannabinoids: update. *Substance Abuse* 2015;38:344-66.
- Casier I, Vanduynehoven P, Haine S, Vrints C, Jorens PG. Is recent cannabis use associated with acute coronary syndromes? An illustrative case series. *Acta Cardiol* 2014;69:131-6.
- Velibey Y, Sahin S, Tank O, et al. Acute myocardial infarction due to marijuana smoking in a young man: guilty should not be underestimated. *Am J Emerg Med* 2015;33:1114.e1-e3.
- Mehta J, Mahendran A, Bajaj R, Doshi A. Myocardial ischemia with cannabinoid use in an adolescent. *Cureus* 2017;9:e1899.
- Caldicott DGE, Holmes J, Roberts-Thomson KC, Mahar L. Keep off the grass: marijuana use and acute cardiovascular events. *Eur J Emerg Med* 2005;12:236-44.
- Arora S, Goyal H, Aggarwal P, Kukar A. ST-segment elevation myocardial infarction in a 37-year-old man with normal coronaries—it is not always cocaine! *Am J Emerg Med* 2012;30:2091.e3-e5.
- Canga Y, Osmonov D, Karatas MB, et al. Cannabis: a rare trigger of premature myocardial infarction. *Anatol J Cardiol* 2011;11:271-5.
- Cappelli F, Lazzeri C, Gensini GF, Valente S. Cannabis: a trigger for acute myocardial infarction? A case report. *J Cardiovasc Med* 2008;9:725-8.
- Ayhan H, Aslan AN, Süygün H, Durmaz T. Bonsai induced acute myocardial infarction: a case report. *Turk Kardiyol Dern Ars* 2014;42:560-3.
- Hamilton RJ, Keyfes V, Banka SS. Synthetic cannabinoid abuse resulting in ST-segment elevation myocardial infarction requiring percutaneous coronary intervention. *J Emerg Med* 2017;52:496-8.
- Ibrahim S, Al-Saffar F, Wannenburg T. A unique case of cardiac arrest following K2 abuse. *Case Rep Cardiol* 2014;2014:120607.
- Hodcroft CJ, Rossiter MC, Buch AN. Cannabis-associated myocardial infarction in a young man with normal coronary arteries. *J Emerg Med* 2014;47:277-81.
- Karabulut A, Cakmak M. ST segment elevation myocardial infarction due to slow coronary flow occurring after cannabis consumption. *Kardiol Pol* 2010;68:1266-8.
- Rezkalla SH, Sharma P, Kloner RA. Coronary no-flow and ventricular tachycardia associated with habitual marijuana use. *Ann Emerg Med* 2003;42:365-9.
- Gunawardena M, Rajapakse S, Herath J, Amarsena N. Myocardial infarction following cannabis-induced coronary vasospasm. *BMJ Case Rep* 2014:bcr2014207020.
- Jehangir W, Stanton M, Khan R, Sahgal P, Yousif A. Did cannabis precipitate a STEMI in a young woman? *Cardiol Res* 2015;6:283-5.
- Bailly C, Merceron O, Hammoudi N, Dorent R, Michel PL. Cannabis induced acute coronary syndrome in a young female. *Int J Cardiol* 2010;143:e4-6.
- Deharo P, Massoure PL, Fourcade L. Exercise-induced acute coronary syndrome in a 24-year-old man with massive cannabis consumption. *Acta Cardiol* 2013;68:425-8.
- Mills B, Dishner E, Velasco CE. Acute myocardial infarction triggered by use of synthetic cannabis. *Proc (Bayl Univ Med Cent)* 2018;31:2002.
- Ul Haq E, Shafiq A, Khan A, et al. "Spice" (synthetic marijuana) induced acute myocardial infarction: a case series. *Case Rep Cardiol* 2017:1-4.
- Tirkey N, Gupta S. Acute antero-inferior wall ischemia with acute ischemic stroke caused by oral ingestion of cannabis in a young male. *J Assoc Phys India* 2016;64:93-5.
- Keskin M, Hayiroglu M, Keskin U, Eren M. Acute myocardial infarction and ischemic stroke coexistence due to marijuana abuse in adolescent. *Anatol J Cardiol* 2016;16:542-6.
- Kocabay G, Yildiz M, Duran NE, Ozkan M. Acute inferior myocardial infarction due to cannabis smoking in a young man. *J Cardiovasc Med* 2009;10:669-70.
- Koklu E, Yuksel IO, Bayar N, Ureyen CM, Arslan S. A new cause of silent myocardial infarction: Bonsai. *Anatol J Cardiol* 2015;15:69-70.

42. Kotsalou I, Georgoulis P, Karydas I, et al. A rare case of myocardial infarction and ischemia in a cannabis-addicted patient. *Clin Nucl Med* 2007;32:130-1.
43. Lindsay AC, Foale RA, Warren O, Henry JA. Cannabis as a precipitant of cardiovascular emergencies. *Int J Cardiol* 2005;104:230-2.
44. Marchetti D, Spagnolo A, De Matteis V, et al. Coronary thrombosis and marijuana smoking: a case report and narrative review of the literature. *Drug Test Anal* 2015;8:56-62.
45. McKeever RG, Vearrier D, Jacobs D, et al. K2—not the spice of life; synthetic cannabinoids and ST elevation myocardial infarction: a case report. *J Med Toxicol* 2015;11:129-31.
46. McLroy G, Ford L, Khan JM. Acute myocardial infarction, associated with the use of a synthetic adamantyl-cannabinoid: a case report. *BMC Pharmacol Toxicol* 2016;17:2.
47. Mir A, Obafemi A, Young A, Kane C. Myocardial infarction associated with use of the synthetic cannabinoid K2. *Pediatrics* 2011;128:e1622-7.
48. Montisci M, Thiene G, Ferrara SD, Basso C. Cannabis and cocaine: a lethal cocktail triggering coronary sudden death. *Cardiovasc Pathol* 2008;17:344-6.
49. Yurtdas M, Aydin M. Acute myocardial infarction in a young man; fatal blow of marijuana. A case report. *Korean Circ J* 2012;42:641-5.
50. Orsini J, Blaak C, Rajayer S, et al. Prolonged cardiac arrest complicating a massive ST-segment elevation myocardial infarction associated with marijuana consumption. *J Community Hosp Intern Med Perspect* 2016;6:31695.
51. Pratap B, Korniyenko A. Toxic effects of marijuana on the cardiovascular system. *Cardiovasc Toxicol* 2011;12:143-8.
52. Renard D, Taieb G, Gras-Combe G, Labauge P. Cannabis-related myocardial infarction and cardioembolic stroke. *J Stroke Cerebrovasc Dis* 2012;21:82-3.
53. Safaa AM, Markham R, Jayasinghe R. Marijuana-induced recurrent acute coronary syndrome with normal coronary angiograms. *Drug Alcohol Rev* 2011;31:91-4.
54. Sayin MR, Akpınar I, Cetiner MA, Karabag T. Diffuse coronary ectasia and acute coronary syndrome in a young man. Who is guilty? Cannabis, smoking or dyslipidemia? *Anatol J Cardiol* 2013;13:606-20.
55. Shah M, Garg J, Patel B, Guthier J, Freudenberg RS. Can your heart handle the spice: a case of acute myocardial infarction and left ventricular apical thrombus. *Int J Cardiol* 2016;215:129-31.
56. Tatli E, Yilmaztepe M, Altun G, Altun A. Cannabis-induced coronary artery thrombosis and acute anterior myocardial infarction in a young man. *Int J Cardiol* 2007;120:420-2.
57. Tse R, Kodur S, Squires B, Collins N. Sudden cardiac death complicating acute myocardial infarction following synthetic cannabinoid use. *Intern Med J* 2014;44:934-6.
58. Walsh J, Harris B, Ossei-Gerning N. MI with multiple distal occlusions associated with use of the synthetic cannabinoid 5F-AKB48. *Brit J Cardiol* 2015;22:40.
59. Yilmaz S, Unal S, Kuyumcu MS, Balci KG, Balci MM. Acute anterior myocardial infarction after “Bonzai” use. *Anatol J Cardiol* 2015;15:265-6.
60. Kumar S, Srinivasamurthy R, Karasik O, Javid A. Marijuana-associated ST-elevation myocardial infarction: is this a benign drug. *BMJ Case Rep* 2018;11:e226894.
61. Dwivedi S, Kumar V, Aggarwal A. Cannabis smoking and acute coronary syndrome: two illustrative cases. *Int J Cardiol* 2008;128:e54-7.
62. Jouanjus E, Lapeyre-Mestre M, Micallef J. Cannabis use: signal of increasing risk of serious cardiovascular disorders. *J Am Heart Assoc* 2014;3:e000638.
63. Mittleman MA, Lewis RA, Maclure M, Sherwood JB, Muller JE. Triggering myocardial infarction by marijuana. *Circulation* 2001;103:2805-9.
64. Mittleman MA, Mintzer D, Maclure M, et al. Triggering of myocardial infarction by cocaine. *Circulation* 1999;99:2737-41.
65. Chami AT, Kim C. Cannabis abuse and risk for myocardial infarction: a population based study. *J Am Coll Cardiol* 2017;69:6.
66. Desai R, Patel U, Sharma S, et al. Recreational marijuana use and acute myocardial infarction: insights from nationwide inpatient sample in the United States. *Cureus* 2017;9:e1816.
67. Lee J, Sharma N, Aponte CS, et al. Clinical characteristics and angiographic findings of myocardial infarction among marijuana users and non-users. *SciFed J Cardiol* 2017;1:1000008.
68. Afshar M, Karki N, Cherek P, et al. Relationship between marijuana use and hospitalization for acute coronary syndrome. *J Am Coll Cardiol* 2017;69:84.
69. Weiss JL, Watanabe AM, Lemberger L, Tamarkin NR, Cardon PV. Cardiovascular effects of delta-9-tetrahydrocannabinol in man. *Clin Pharmacol Therapeut* 1972;13:671-84.
70. Johnson S, Domino EF. Some cardiovascular effects of marijuana smoking in normal volunteers. *Clin Pharmacol Therapeut* 1971;12:762-8.
71. Benowitz NL, Rosenberg J, Rogers W, Bachman J, Jones RT. Cardiovascular effects of intravenous delta-9-tetrahydrocannabinol: autonomic nervous mechanisms. *Clin Pharmacol Therapeut* 1979;25:440-6.
72. Alshaarawy O, Elbaz HA. Cannabis use and blood pressure levels. *J Hypertens* 2016;34:1507-12.
73. Malinowska B, Baranowska-Kuczko M, Schlicker E. Triphasic blood pressure responses to cannabinoids: Do we understand the mechanism? *Brit J Pharmacol* 2012;165:2073-88.
74. Aronow WS, Cassidy J. Effect of marijuana and placebo-marijuana smoking on angina pectoris. *N Engl J Med* 1974;291:65-7.
75. Deusch E, Kress HG, Kraft B, Kozek-Langenecker SA. The procoagulatory effects of delta-9-tetrahydrocannabinol in human platelets. *Anesth Analg* 2004;99:1127-30.
76. Dahdouch Z, Roule V, Lognoné T, Sabatier R, Grollier G. Cannabis and coronary thrombosis: What is the role of platelets? *Platelets* 2011;23:243-5.
77. Golcuk Y, Golcuk B, Sozen S. Effect of regular marijuana smoking on platelet function. *Am J Emerg Med* 2015;33:721-2.
78. Quercioli A, Pataky Z, Vincenti G, et al. Elevated endocannabinoid plasma levels are associated with coronary circulatory dysfunction in obesity. *Eur Heart J* 2011;32:1369-78.
79. Wu TC, Tashkin DP, Djahed B, Rose JE. Pulmonary hazards of smoking marijuana as compared with tobacco. *N Engl J Med* 1988;318:347-51.
80. Moir D, Rickert WS, Levasseur G, et al. A comparison of mainstream and sidestream marijuana and tobacco cigarette smoke produced under two machine smoking conditions. *Chem Res Toxicol* 2008;21:494-502.

81. Lipina C, Hundal HS. Modulation of cellular redox homeostasis by the endocannabinoid system. *Open Biol* 2016;6:150276.
82. Mukamal KJ, Maclure M, Muller JE, Mittleman MA. An exploratory prospective study of marijuana use and mortality following acute myocardial infarction. *Am Heart J* 2008;155:465-70.
83. Frost L, Mostofsky E, Rosenbloom JI, Mukamal KJ, Mittleman MA. Marijuana use and long-term mortality among survivors of acute myocardial infarction. *Am Heart J* 2013;165:170-5.
84. Johnson-Sasso CP, Tompkins C, Kao DP, Walker LA. Marijuana use and short-term outcomes in patients hospitalized for acute myocardial infarction. *PLoS One* 2018;13:e0199705.
85. Aune E, Roislien J, Mathisen M, Thelle DS, Otterstad JE. The “smoker’s paradox” in patients with acute coronary syndrome: a systematic review. *BMC Med* 2011;9:97.
86. Gupta T, Kolte D, Khera S, et al. Smoker’s paradox in patients with ST-segment elevation myocardial infarction undergoing primary percutaneous coronary intervention. *J Am Heart Assoc* 2016;5:e003370.
87. Zubrzycki M, Liebold A, Janecka A, Zubrzycka M. A new face of endocannabinoids in pharmacotherapy. Part I: protective role of endocannabinoids in hypertension and myocardial infarction. *J Physiol Pharmacol* 2014;65:171-81.
88. Moris D, Georgopoulos S, Felekouras E, Patsouris E, Theocharis S. The effect of endocannabinoid system in ischemia-reperfusion injury: a friend or a foe? *Expert Opin Therapeut Targets* 2015;19:1261-75.