
MORPHOLOGY AND PATHOMORPHOLOGY

Reaction of the Hippocampal Microglia to Hyperbaric Oxygen

O. V. Kirik¹, O. S. Alekseeva^{1,2}, D. L. Tsyba¹, and D. E. Korzhevskii¹

Translated from *Byulleten' Eksperimental'noi Biologii i Meditsiny*, Vol. 173, No. 5, pp. 626-631, May, 2022
Original article submitted March 4, 2022

We studied the reaction of rat hippocampal microglia to hyperbaric oxygen at a pressure of 5 ata (absolute atmosphere). Immunohistochemical analysis with selective macrophage marker CD68 (ED1) and microglial marker Iba-1 allowed separate analysis of these two cell populations. It was shown that macrophages do not significantly contribute to reactive changes in the total pool of Iba-1⁺ hippocampal cells induced by hyperbaric oxygen.

Key Words: *hyperbaric oxygen; microglia; macrophages; hippocampus; rat*

In modern medicine, oxygen is used to treat diseases accompanied by impaired tissue gas exchange. Hyperbaric oxygenation used for these purposes allows saturating the blood with oxygen more efficiently than oxygen therapy at atmospheric pressure. Some clinical studies were focused on assessing the prospects of using hyperbaric oxygenation for the treatment of traumatic brain injuries [1], ischemic and reperfusion disorders of CNS [2,3], malignant neoplasms [4], and COVID-19 [5]. Despite high efficiency and a wide range of indications, hyperbaric oxygen (HBO₂) along with physiological and therapeutic effects can produce acute toxic effects manifested in induction of seizure activity and damage to neurons [6,7]. The mechanisms of these processes are not clear enough, and the study of the circumstances and consequences of hyperbaric oxygenation is a necessary condition for its safe and effective use.

Experimental modeling of epilepsy in animals showed that the hippocampus can be a key center for triggering seizure activity [8,9]. In this regard, it seems relevant to study the cellular reactions of this brain

structure in response to the action of HBO₂. Microglia, a part of the most important protective elements of the nervous tissue mediating the damaging effects of various factors, can play the key role in triggering the cellular response to HBO₂ [10,11]. At present, a large body of evidence has been accumulated on the reactions of microglia/macrophages to experimental exposures, but in most studies, the researchers did not separate the populations of microglia and macrophages [10,11]. This was probably due to the use of nonspecific markers of these cells.

The aim of this work was to determine the response of hippocampal microglia to oxygen exposure at elevated pressure and to assess possible contribution of macrophages to this response.

MATERIALS AND METHODS

The study was performed on awake mature male Wistar rats weighing 200-250 g. The experimental protocol was approved by the Ethics Committee of the I. M. Sechenov Institute of Evolutionary Physiology and Biochemistry. The experiments were performed in accordance with the International Guidelines for Biomedical Research Using Animals (CIOMS, Geneva, 1985).

The animals ($n=12$) were divided into two groups: intact controls ($n=4$) and animals exposed to HBO₂

¹Institute of Experimental Medicine, St. Petersburg, Russia; ²I. M. Sechenov Institute of Evolutionary Physiology and Biochemistry, Russian Academy of Sciences, St. Petersburg, Russia. **Address for correspondence:** olga_kirik@mail.ru. O. V. Kirik

($n=8$). The experiments were carried out in an oxygen pressure chamber (volume 107 liters). Compression was performed with medical oxygen to a pressure of 5 ata (absolute atmospheres) at a rate of 1 ata/min. HBO₂ exposure lasted 60 min and decompression 7 min. During HBO₂ exposure, behavioral reactions of animals were videorecorded.

After decompression the brain was isolated and fixed in zinc-ethanol-formaldehyde. In 24 h, the brain was transferred to 96% ethanol; further dehydration and embedding in paraffin were carried out using a Microm STP 120 spin tissue processor (Microm). For morphological analysis, 5- μ m coronal sections were prepared (at the level of -2.92 to -3.60 mm from bregma) [12]. Nissl staining with cresyl violet was used for common assessment of brain tissue. Microglia and macrophages were detected in brain structures with immunocytochemical markers. After routine procedure of deparaffinization and rehydration, the sections were thermally retrieved. Then endogenous peroxidase was blocked. Microglia and macrophages were marked using rabbit polyclonal anti-Iba-1 antibodies (1:1000; Biocare Medical) and mouse monoclonal anti-CD68 antibodies (clone ED1, Abcam). Reveal Polyvalent HRP DAB Detection System (Abcam) was used as secondary reagent. The peroxidase label was detected with diaminobenzidine chromogen (Thermo Scientific). After immunocytochemical reactions, some sections were counterstained with hematoxylin. Microscopic examination of the preparations in transmitted light and photography were performed using a Leica DM750 microscope and a Leica ICC50 digital camera.

ImageJ software was used for image processing. To estimate the area occupied by Iba-1⁺ structures, the images were binarized and the relative area was measured using the Selection tool. Morphometric analysis was carried out according to the Avtandilov method using the Grid tool with a cell area of 100 μ m² and calculating the percentage of grid nodes occupied by immunopositive structures relative to the total number of nodes. CD68⁺ cells were counted visually. The length of the meninges in the micrographs was measured using the Freehand Line tool.

Statistical processing of the results of performed measurements was carried out using the Rstudio program (<https://www.rstudio.com>). The data are presented as Me (IQR). The nonparametric Mann–Whitney U test was used to compare the experimental and control groups. The differences were significant at $p<0.05$.

RESULTS

Morphological changes of the hippocampal neurons. No signs of dystrophic processes and neurodegeneration were observed in the brain tissue on Nissl

stained sections. The bodies of hippocampal neurons in the areas of the cornu ammonis (CA), hilus, and dentate fascia were stained evenly, the initial parts of the processes had a smooth shape. In all animals exposed to HBO₂, brain sections showed no signs of classical inflammatory process. In CA3, hilus, and dentate fascia, single neurons appeared with pronounced hyperchromic perinuclear staining, which was diffuse in nature and made it difficult to visualize the nucleus. In some cells, the initial parts of the dendrites had a convoluted “corkscrew” shape.

Iba-1 expression. In intact animals, the immunohistochemical reaction to the Iba-1 protein, a non-selective marker of microglia and macrophages [13], revealed cells with thin processes typical of resting (ramified) microglia (Fig. 1, *a, c, e*) evenly distributed throughout the section. In addition, Iba-1 was detected in round cells located in close proximity to the vessels, and in the meninges, on the surface of the choroid plexus in the ventricles. In all animals exposed to HBO₂, immunohistochemical reaction to Iba-1 protein was also detected in dendritic cells evenly distributed over the section area. No focal accumulations of microglia were detected. Visually, these cells had thicker processes than in control animals, and a smaller number of processes of the second order (Fig. 1, *b, d, f*). Cell bodies were not enlarged. Analysis of binarized microphotographs of the hippocampus showed that in experimental animals, Iba-1⁺ structures of the CA1, hilus occupy larger section area than in the control (CA1: $U=22$, $p=0.049$; hilus: $U=3$, $p=0.08$), however, in the hilus, these differences did not reach significance. In the area of the CA3 stratum radiatum, microglia in the control animals occupied larger area than in the experimental ones ($U=23$, $p=0.02$) (Fig. 2). In the morphometric analysis of images using the Avtandilov grid, Iba-1⁺ structures in the brain of experimental animals had lower number of nodes compared to the control ($U=5$, $p=0.19$ for CA1; $U=5$, $p=0.19$ for CA3 and $U=13.5$, $p=0.84$ for the hilus). Despite the absence of significant differences, the general trend indirectly indicates an increase in the total area of Iba-1⁺ structures due to thickening and shortening of microglia processes in the CA1 and hilus areas, rather than changes in the number of cells.

CD68 expression. In immunohistochemical detection of the CD68 antigen, which is predominantly characteristic of macrophages and monocytes [8], a positive reaction in both intact and experimental animals was observed only in rounded cells with bean-shaped nuclei in the lumen of blood vessels (monocytes) and single perivascular cells of the amoeboid form in the choroid plexuses, meninges and adventitia of large vessels. The number of these cells in animals subjected to HBO₂ significantly exceeded the control

values (6.2 (IQR 6.6) cells/mm vs 2.1 (IQR 2.8) cells/mm, $U=30$, $p=0.016$) (Fig. 3). CD68⁺ perivascular cells in the hippocampus were extremely rare in all animals, while microglial cells were not detected. The distribution of these cells was diffuse.

Exposure to increased oxygen pressure of 5 ata for 60 min leads to the appearance of the toxic ef-

fects of HBO₂ and the development of seizures [14]. According to published data, the CA1 and CA3 regions of the hippocampus are sensitive to epileptiform brain activity. In these areas, convulsive activity is recorded when modeling status epilepticus on animals [8,9]. This can be due to the fact that at elevated oxygen pressure, the pool of ROS increases significantly,

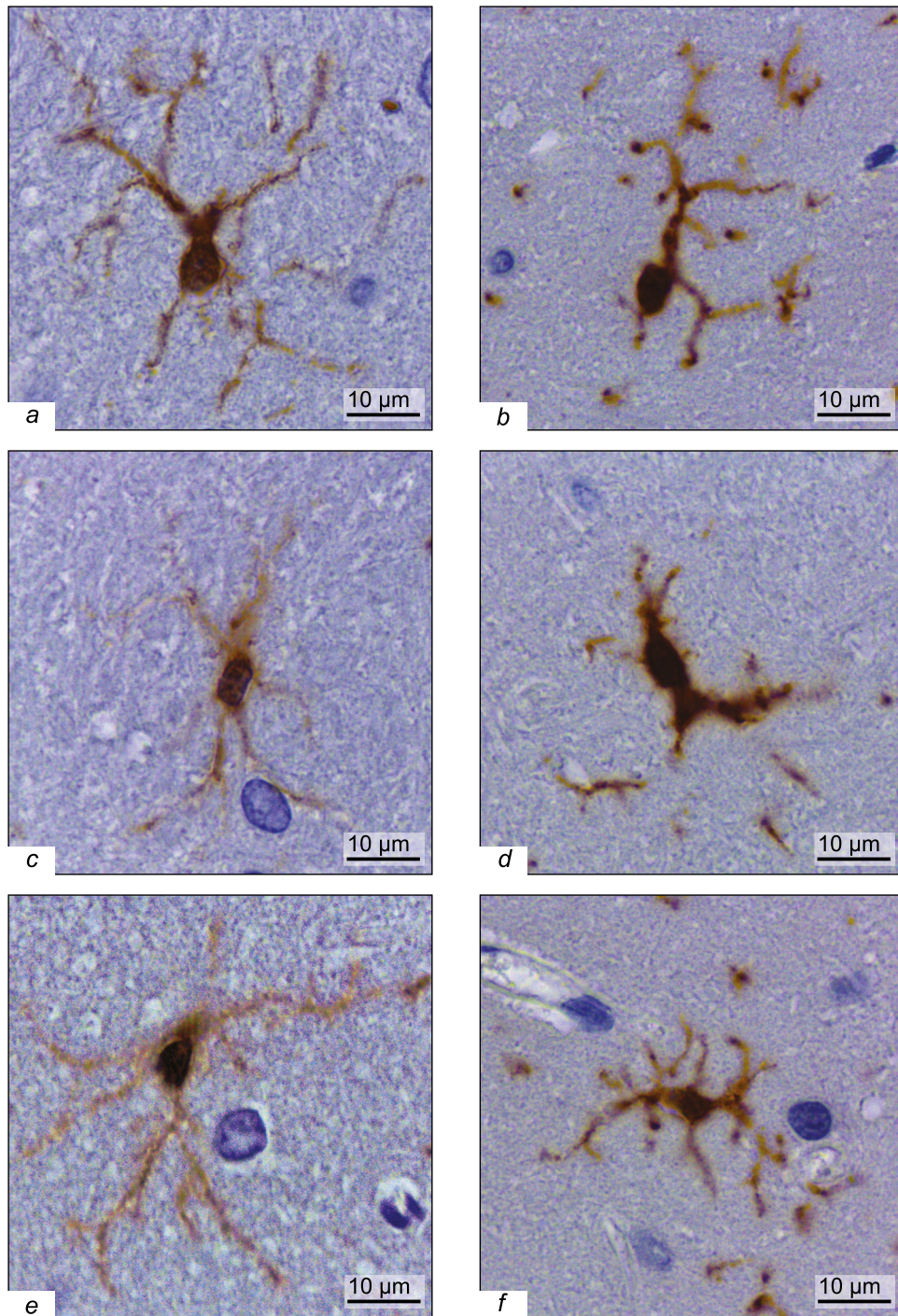


Fig. 1. Microglia of hippocampal stratum radiatum in intact and experimental animals: CA1 (a, b), CA3 (c, d), and hilus (e, f). Immunocytochemical reaction for Iba-1. The nuclei are counterstained with hematoxylin.

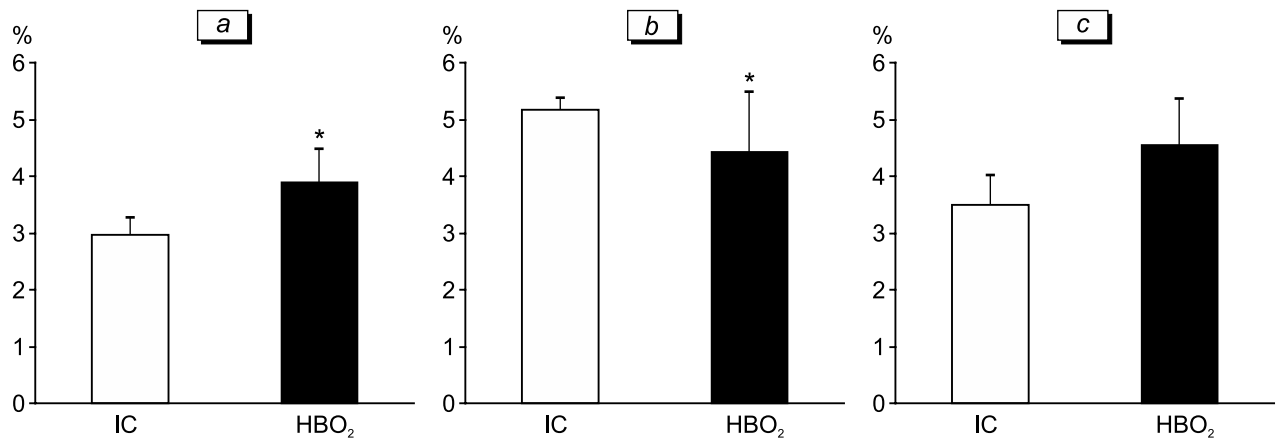


Fig. 2. Relative area occupied by Iba-1⁺ structures of the stratum radiatum CA1 (a) and CA3 (b) regions and hilus (c) in rat hippocampus. IC: intact control. * $p < 0.05$.

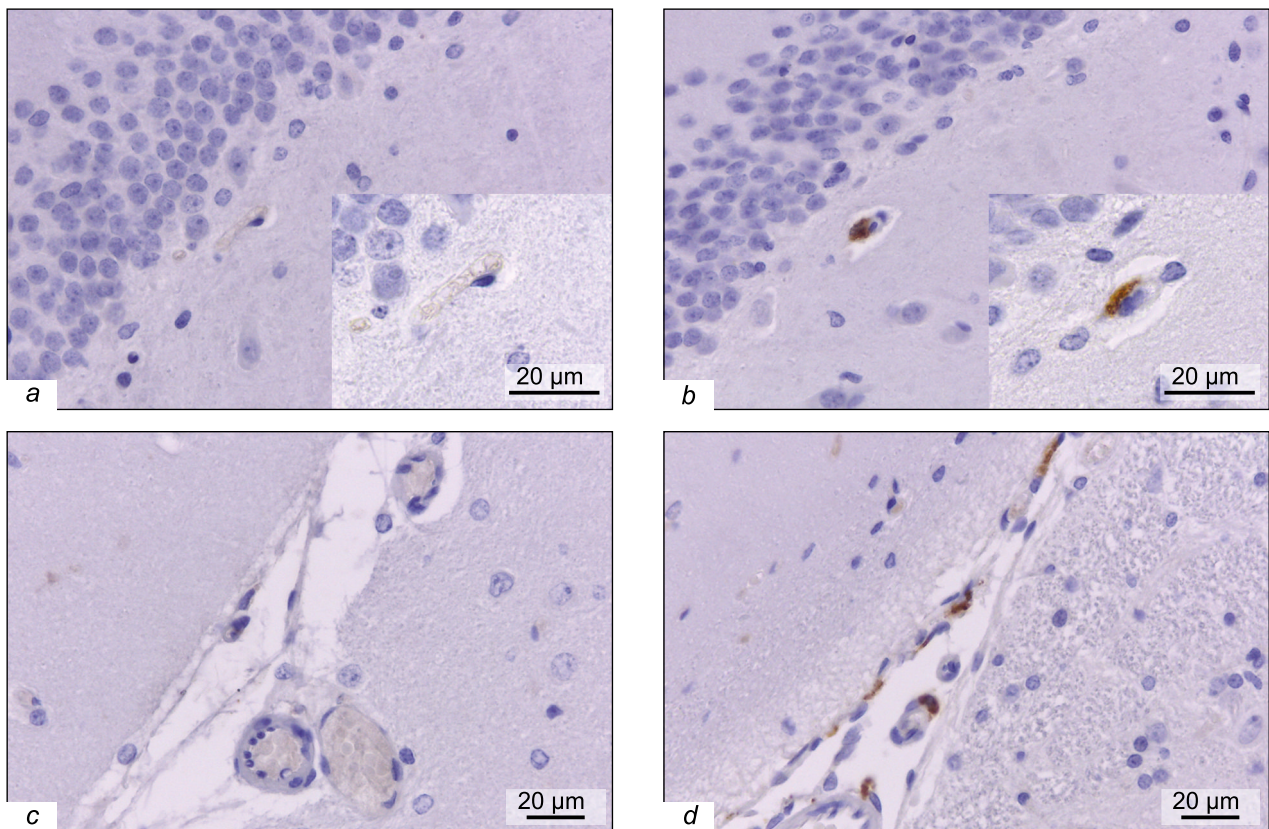


Fig. 3. CD68-immunopositive perivascular cells of the subgranular zone of the dentate fascia (a, b) and meninges of the hippocampal fissure (c, d). Immunocytochemical reaction to CD68. a, c) Intact control; b, d) HBO₂.

which leads to an increase in oxidative stress, disruption of intracellular processes in brain structures, and the onset of seizure activity. HBO₂ at 5 ata led to activation of hippocampal microglia; this effect was most pronounced in the CA3 zone, however, this cell activation was not accompanied by the formation of foci with an increased number of microglia. It is

likely that the CA3 region of the hippocampus is the most sensitive to such influences, while in “chemical” (lithium-pilocarpine, pentylene-tetrazol) models of epilepsy, primarily the CA1 zone is affected [9].

Unlike microglia, typical brain macrophages are presented in the hippocampus by single cells, and their contribution to the proinflammatory response

is not comparable to microglial. The detected reaction of macrophages from barrier structures (choroid plexus, meninges, and perivascular spaces) indicates the likelihood of damage to these structures, which is indirectly confirmed by published reports on increased permeability of the blood–brain barrier during hyperbaric oxygenation [15].

The use of the macrophage selective marker CD68 (ED1) and the microglial marker Iba-1 in the present study made it possible to analyze the state of each of the two cell populations and show that macrophages little contribute to the reactive changes in Iba1⁺ hippocampal cells during exposure to HBO₂.

The work was carried out within the framework of the State Assignments of the Institute of Experimental Medicine and the I. M. Sechenov Institute of Evolutionary Physiology and Biochemistry, Russian Academy of Sciences.

REFERENCES

- Deng Z, Chen W, Jin J, Zhao J, Xu H. The neuroprotection effect of oxygen therapy: A systematic review and meta-analysis. *Niger J. Clin. Pract.* 2018;21(4):401-416. doi: 10.4103/njcp.njcp_315_16
- Sun L, Zhou W, Mueller C, Sommer C, Heiland S, Bauer AT, Marti HH, Veltkamp R. Oxygen therapy reduces secondary hemorrhage after thrombolysis in thromboembolic cerebral ischemia. *J. Cereb. Blood Flow Metab.* 2010;30(9):1651-1660. doi: 10.1038/jcbfm.2010.50
- Thiankhaw K, Chattipakorn N, Chattipakorn SC. The effects of hyperbaric oxygen therapy on the brain with middle cerebral artery occlusion. *J. Cell. Physiol.* 2021;236(3):1677-1694. doi: 10.1002/jcp.29955
- Stępień K, Ostrowski RP, Matyja E. Hyperbaric oxygen as an adjunctive therapy in treatment of malignancies, including brain tumours. *Med. Oncol.* 2016;33(9):101. doi: 10.1007/s12032-016-0814-0
- Kirby J. Hyperbaric oxygen therapy for patients with COVID-19. *Emerg. Med. J.* 2022;39(2):86-87. doi: 10.1136/emmermed-2021-212015
- Demchenko IT, Gasier HG, Zhilyaev SY, Moskvina AN, Krivchenko AI, Piantadosi CA, Allen BW. Baroreceptor afferents modulate brain excitation and influence susceptibility to toxic effects of hyperbaric oxygen. *J. Appl. Physiol.* (1985). 2014;117(5):525-534. doi: 10.1152/jappphysiol.00435.2014
- Koch AE, Kähler W, Wegner-Bröse H, Weyer D, Kuhtz-Buschbeck J, Deuschl G, Eschenfelder CC. Monitoring of CBFV and time characteristics of oxygen-induced acute CNS toxicity in humans. *Eur. J. Neurol.* 2008;15(7):746-748. doi: 10.1111/j.1468-1331.2008.02158.x
- Kobylarek D, Iwanowski P, Lewandowska Z, Limphai-bool N, Szafranek S, Labrzycka A, Kozubski W. Advances in the potential biomarkers of epilepsy. *Front. Neurol.* 2019;10:685. doi: 10.3389/fneur.2019.00685
- Vasilev DS, Tumanova NL, Kim KK, Lavrentyeva VV, Lukomskaya NY, Zhuravin IA, Magazanik LG, Zaitsev AV. Transient morphological alterations in the hippocampus after pentylenetetrazole-induced seizures in rats. *Neurochem. Res.* 2018;43(8):1671-1682. doi: 10.1007/s11064-018-2583-y
- Qiu M, Xu E, Zhan L. Epigenetic regulations of microglia/macrophage polarization in ischemic stroke. *Front. Mol. Neurosci.* 2021;14:697416. doi: 10.3389/fnmol.2021.697416
- Xiong XY, Liu L, Yang QW. Functions and mechanisms of microglia/macrophages in neuroinflammation and neurogenesis after stroke. *Prog. Neurobiol.* 2016;142:23-44. doi: 10.1016/j.pneurobio.2016.05.001
- Paxinos G, Watson C. *The Rat Brain in Stereotaxic Coordinates*. San Diego, 1998.
- Korzhevskii DE, Kirik OV. Brain microglia and microglial markers. *Neurosci. Behav. Physiol.* 2016;46(3):284-290. doi:10.1007/s11055-016-0231-z
- Alekseeva OS, Zhilyaev SYu, Platonova TF, Tsyba DL, Kirik OV, Korzhevskii DE, Demchenko IT. Involvement of glutamine synthetase in the development of hyperbaric oxygen seizures. *Russ. Fiziol. Zh.* 2022;108(1):109-120. Russian. doi: 10.31857/S0869813922010022
- Cevik NG, Orhan N, Yilmaz CU, Arican N, Ahishali B, Kucuk M, Kaya M, Toklu AS. The effects of hyperbaric air and hyperbaric oxygen on blood-brain barrier integrity in rats. *Brain Res.* 2013;1531:113-121. doi: 10.1016/j.brainres.2013.07.052